



OPEN ACCESS

Flagellate dermatitis in bleomycin chemotherapy: a causality?

Niken Indrastuti,^{1,2} Sri Mariyani ,^{1,2} Prima Meidiyanti^{1,2}

¹Department of Dermatology and Venereology, Faculty of Medicine, Public Health and Nursing, Universitas Gadjah Mada, Yogyakarta, Daerah Istimewa Yogyakarta, Indonesia
²Dr. Sardjito General Hospital, Yogyakarta, Indonesia

Correspondence to
dr Sri Mariyani;
echi1206@gmail.com

Accepted 5 July 2022

SUMMARY

Flagellate dermatitis is a relatively rare reaction to toxicity. It appears as skin lesions with erythematous patches or papules of linear, multiple, flagellate structures. Flagellate dermatitis can be triggered by several causes, which are most commonly associated with bleomycin. This paper reports two cases of flagellate dermatitis, one in a patient with germ cell carcinoma and another in a patient with osteosarcoma who were both diagnosed with flagellate dermatitis after the administration of bleomycin.

BACKGROUND

Bleomycin is a cytotoxic agent which contains glycopeptides. It is isolated from the *Streptomyces verticillus* strain and was first developed in Japan by Umezawa in 1966. It has been used to treat various cancers such as squamous cell carcinoma, lymphoma, germ cell tumour, testicular carcinoma and malignant pleural effusions. It is also used by dermatologists to treat recalcitrant warts, hypertrophic scars and keloids. The use of bleomycin is currently limited due to several side effects that have been reported such as pulmonary fibrosis, Raynaud's phenomenon, alopecia, onychodystrophy, gangrene, oedema and flagellate dermatitis.^{1,2}

Flagellate dermatitis is a rare toxic reaction to bleomycin with 8%–66% incidence rate.^{1,3–5} The term 'flagellate' is derived from the Latin word 'flagellum', which means a whip-like appearance.¹ While flagellate dermatitis is most commonly linked to bleomycin, it can also be caused by the chemotherapy agents peplomycin and docetaxel as well as shiitake mushroom toxin, and is sometimes found on patients with dermatomyositis.^{6,7} This paper describes two cases of flagellate dermatitis, one in a patient with germ cell carcinoma and another in a patient with osteosarcoma who were both diagnosed with flagellate dermatitis after the administration of bleomycin. The aim of this paper is to provide an overview of how this unique toxic reaction to bleomycin manifests on the skin so that clinicians can take it into consideration when administering this chemotherapy drug. In addition to that, this paper also intends to explore other causes of flagellate dermatitis besides bleomycin.

CASE PRESENTATION

Case 1

A man in his 20s was referred to the dermatology department with rashes and itchy patches on the body. Lesions first appeared the previous day as

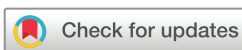itchy hives in the form of irregular lines on the stomach and red spots which spread to the back and legs. The patient did not experience any muscle weakness. He had no history of similar conditions, allergies, atopy or hives. The patient had not been using topical medication, consuming mushrooms or inflicting self-injury using sharp objects. Family history also had no record of similar reports.

A month prior, the patient was diagnosed with mixed germ cell intra-abdominal malignant tumour along with cerebral metastases. He had received the first cycle of BEC chemotherapy regimen which consisted of bleomycin (30 U/m² intravenously on days 1, 8 and 15), etoposide (150 mg/m² on days 1–5) and cisplatin (30 mg/m² on days 1–5). The skin lesions appeared after the administration of bleomycin on day 15. Vital signs were within normal limits and there was no evidence of muscle weakness. The dermatological status on the abdomen, back and waist showed erythematous patches that were linear in shape with a flagellate arrangement (figure 1).

Case 2

A woman in her teens was referred to the dermatology department with whiplash-like pattern marks and scratch mark-like hyperpigmentation on the body. The lesions appeared the week before as itchy hives in the form of irregular lines on the abdomen and waist. Two days later, the patient's parents noted dark brown-coloured hyperpigmentation resembling scratch mark on some areas and marks of whiplashes on others. The patient did not experience any muscle weakness. Similar to the first patient, the second patient also never suffered from similar conditions. She did not have allergies, atopy or hives. There were no history of topical medication use, mushroom consumption, mental disorders and self-inflicted injury using sharp weapons. Family history also did not have any record about similar reports.

The second patient was diagnosed with osteosarcoma 10 months prior. She received osteosarcoma chemotherapy protocol, which included high-dose methotrexate (HDMTX) (8 g/m² intravenously in weeks 3, 4, 8, 9, 13, 14, 18, 19, 23 and 24), bleomycin (30 mg/m²), cyclophosphamide (500 mg/m²) and actinomycin D (0.75 mg/m² in week 15). Doxorubicin (90 mg/m²) and cisplatin (75 mg/m²) were administered in weeks 5 and 10. After the administration of HDMTX, cyclophosphamide, doxorubicin and cisplatin, the patient did not experience any lesions on the skin. The patient mentioned the lesions appeared after the



© BMJ Publishing Group Limited 2022. Re-use permitted under CC BY-NC. No commercial re-use. See rights and permissions. Published by BMJ.

To cite: Indrastuti N, Mariyani S, Meidiyanti P. *BMJ Case Rep* 2022;**15**:e249704. doi:10.1136/bcr-2022-249704

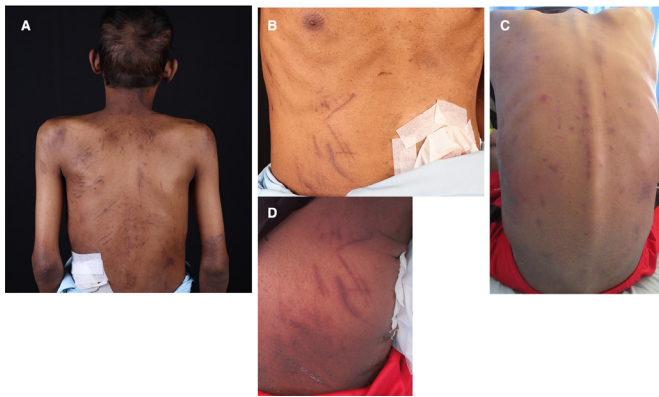


Figure 1 (A) Linear erythematous patch with flagellate arrangement on the abdomen. (B) Confluent erythematous papules form a linear line. (C) Linear, multiple hyperpigmented patches with flagellate arrangement on the abdomen and back. (D) Linear erythematous patch with flagellate arrangement on the waist.

administration of bleomycin in week 15. Vital signs were within normal limits and there was no evidence of muscle weakness. The dermatological status on the abdomen and waist showed erythematous-hyperpigmented patches that were linear in shape with a flagellate arrangement (figure 2).

Investigations

Dermatographism was not found on both patients. Laboratory tests showed normal level of creatine kinase and creatine kinase myocardial band. The diagnosis was based on the connection between bleomycin and skin lesions. A skin biopsy was not performed.

Differential diagnosis

The differential diagnosis of flagellate erythema includes bleomycin flagellate dermatitis, shiitake mushroom intake, dermatomyositis, adult-onset Still's disease and dermatitis artefacta.^{8 9} Skin manifestations which appear following bleomycin administration and hyperpigmentation which occurs after drug suspension are associated with bleomycin-induced skin disorders. The patients did not experience any skin complaints after the administration of other chemotherapy agents.

Treatment

The first patient was given one dose of 16 mg of methylprednisolone daily for 3 days and 10 mg of cetirizine also once per day. In the second patient, cetirizine and desoximetasone ointment in oleum cocos was applied topically two times per day.

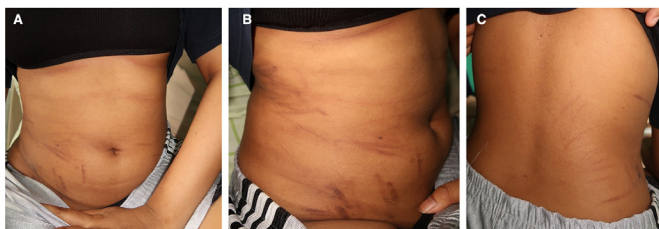


Figure 2 Linear, multiple erythematous and hyperpigmented patches with flagellate arrangement on the (A) abdomen, (B) waist and (C) back.

Outcome and follow-up

After a week of treatment, the lesion turned into linear hyperpigmentation with flagellate arrangement and the patients no longer complained about itching. The first patient died while undergoing treatment so the therapy was discontinued. The second patient was still given bleomycin considering there was only one administration left.

Discussion

The diagnosis in these two cases was based on clinical diagnosis which discovered a temporal relationship between the use of bleomycin and the appearance of skin lesions. Skin lesions in the first case appeared on the body after the third bleomycin administration, while in the second case it appeared after the first bleomycin administration. In the first case, some of the lesions on the body initially took the form of urticaria which turned into erythematous patches and then became hyperpigmented patches. In the second case, the lesion first appeared as an erythematous patch which then became a hyperpigmented patch. Dermatological examination on the body showed erythematous patches and hyperpigmented patches, linear in shape, multiple, with flagellate arrangement.^{1 7 10 11} Various other case reports have also mentioned the occurrence of flagellate dermatitis after the administration of bleomycin (table 1).^{1 2 4 6 8 9 11}

Bleomycin-induced flagellate dermatitis is a rare toxic response to bleomycin.¹ The condition typically appears as skin lesions which begin as urticarial lesions that progress into erythematous patches or papules in the form of linear, multiple, flagellate arrays and, in most cases, are accompanied by pruritus, although it may also be non-pruritic.^{1 2 12} Lesions usually appear on the trunk.¹³ The residual lesion is hyperpigmented. Flagellate dermatitis may appear 24 hours to 6 months after the initial exposure to bleomycin and occur within 12 hours after subsequent drug re-exposure.¹¹

The postulated pathophysiological mechanism for cutaneous manifestations is assumed to be due to lack of bleomycin hydrolase enzyme in the skin, which inactivates bleomycin. This results in an accumulation of bleomycin in the skin. Furthermore, the pruritus that is caused by these alterations may trigger excoriations, resulting in abrasions and microtrauma, which can lead to vasodilation and increased bleomycin deposition.¹¹ Bleomycin damages endothelial cells by upregulating TGF- β (tumour necrosis factor beta), triggering keratinocyte death, and causing a cytotoxic effect on melanocytes, among other mechanisms for cutaneous inflammation and pigmentation.⁹

Bleomycin-induced flagellate dermatitis is a dose-dependent reaction that usually occurs with cumulative doses above 200 IU.⁸ However, there are several case reports indicting otherwise. These reports state that the occurrence of these lesions is an idiosyncratic reaction that is independent regardless of the dose and can manifest after the administration of various doses of bleomycin ranging from 5 IU to 465 IU.^{11 14}

Bleomycin-induced flagellate dermatitis has no absolute or characteristic histopathological appearance. In the acute phase, there is inconspicuous spongiosis, vacuolisation of the stratum basale of the epidermis, a superficial lymphocytic infiltrate with neutrophils and eosinophilic granulocytes, dermal oedema and scattered dyskeratotic keratinocytes. In later stages, only a few post-inflammatory changes were found such as pigment incontinence, melanophages in the papillary dermis and increased melanin pigmentation in the stratum basale are present.⁴

In majority of the cases, these lesions resolve spontaneously after the discontinuation of bleomycin and leave

Table 1 Reported cases of bleomycin flagellate dermatitis^{1 2 4 6 8 9 11}

Reference	Age (year)	Sex	Location	Symptom (s)	Malignancy and therapy	Treatment
Case 1	27	M	Abdomen and back	Pruritic and erythematous linear	Mixed germ cell intra-abdominal malignant tumour	Bleomycin, etoposide and cisplatin Methylprednisolone and cetirizine
Case 2	17	F	Abdomen, waist and back	Pruritic, erythematous and hyperpigmentation linear	Osteosarcoma	HDMTX, bleomycin, cyclophosphamide, doxorubicin and cisplatin Cetirizine and desoximetasone
Grynszpan et al ¹	40	F	Lower limb and back	Pruritic, erythematous lesion and hyperpigmentation	Hodgkin's lymphoma	Adriamycin, vinblastine, dacarbazine and bleomycin —
Boussios et al ²	20	F	Chest and upper back	Striking linear configuration and post-inflammatory hyperpigmentation	Ovarian cyst	Bleomycin, etoposide and cisplatin —
Adjade et al ⁴	37	M	Trunk	Linear flagellate erythema	Testicular seminoma	Bleomycin, etoposide and cisplatin Oral corticoid and antihistamine
Turan Erkek ⁶	24	F	Back, shoulders and trunk	Papules and plaques remarkable whip-like mark formation	Hodgkin lymphoma	Doxorubicin, bleomycin, vincristine, cyclophosphamide, etoposide, prednisone and procarbazine —
Krajewski et al ⁸	33	M	Back and shoulders	Pruritic and linear hyperpigmentation	Seminoma	Bleomycin, etoposide and cisplatin —
Cullingham et al ⁹	32	M	Back	Pruritic and linear rash	Seminoma	Bleomycin, etoposide and cisplatin Hydroxyzine and replace bilastine, desoximetasone
Biswas et al ¹¹	13	M	Trunk and upper extremities	Linear erythematous	Thalamic mixed germ cell tumour	Bleomycin, etoposide and cisplatin Cetirizine and betametasone topical

hyperpigmentation marks. In other cases, flagellate hyperpigmentation may persist even after a year of therapy.¹⁵ Managing symptoms is the main treatment to limit trauma to the skin. This can be done by administering antihistamines and topical corticosteroids or oral corticosteroids. Short-term oral corticosteroids have been used in patients with extensive lesions. Discontinuation of bleomycin can be an option in the case of severe lesions. On the other hand, re-exposure to bleomycin can cause recurrence and spread of lesions.^{13 16 17}

In conclusion, this paper describes bleomycin-induced flagellate dermatitis found on two patients undergoing bleomycin chemotherapy. Flagellate dermatitis itself is a rare form of side effect of this drug. The aetiology and diagnosis of these two patients were based on (1) anamnesis, namely in the form of a temporal connection between the use of bleomycin and the appearance of skin lesions and (2) physical examination on the flagellate-shaped lesions.

Learning points

- ▶ Flagellate dermatitis is a rare form of side effect from bleomycin.
- ▶ Clinicians should be more vigilant about the use of the chemotherapy drug bleomycin.
- ▶ There are other causes of flagellate dermatitis apart from bleomycin.

Contributors SM: writing and drafting the paper; KE: drafting the work or revising it critically for important intellectual content; NI: drafting the work or revising it critically for important intellectual content. All authors: final approval of version to be published and agreement to be accountable for all aspects of the work.

Funding The authors have not declared a specific grant for this research from any funding agency in the public, commercial or not-for-profit sectors.

Competing interests None declared.

Patient consent for publication Consent obtained from parent(s)/guardian(s).

Provenance and peer review Not commissioned; externally peer reviewed.

Open access This is an open access article distributed in accordance with the Creative Commons Attribution Non Commercial (CC BY-NC 4.0) license, which permits others to distribute, remix, adapt, build upon this work non-commercially, and license their derivative works on different terms, provided the original work is properly cited and the use is non-commercial. See: <http://creativecommons.org/licenses/by-nc/4.0/>.

Case reports provide a valuable learning resource for the scientific community and can indicate areas of interest for future research. They should not be used in isolation to guide treatment choices or public health policy.

ORCID iD

Sri Mariyani <http://orcid.org/0000-0001-9561-6948>

REFERENCES

- 1 Grynszpan R, Niemeyer-Corbellini JP, Lopes MSS, et al. Bleomycin-Induced flagellate dermatitis. *BMJ Case Rep* 2013;2013. doi:10.1136/bcr-2013-009764. [Epub ahead of print: 27 Jun 2013].
- 2 Boussios S, Moschetta M, McLachlan J, et al. Bleomycin-Induced flagellate erythema in a patient diagnosed with ovarian yolk sac tumor. *Case Rep Oncol Med* 2015;2015:1–2.
- 3 Rademaker M, Thomas RH, Meyrick Lowe DG, et al. Linear streaking due to bleomycin. *Clin Exp Dermatol* 1987;12:457–9.
- 4 Adjade G, El Fadli M, Afani L. Bleomycin-Induced flagellate erythema in a patient with germ cell tumor. *Our Dermatology Online* 2020;11:18–20.
- 5 Cortina P, Garrido JA, Tomas JF. 'Flagellate' Erythema from Bleomycin. *Dermatology* 1990;180:106–9.
- 6 Turan Erkek E, Karaali CN, Yilmaz G, et al. Bleomycin-Induced flagellate dermatitis. *Turk J Haematol* 2019;36:138–40.
- 7 Loo HV, Oon HH. Flagellate dermatitis following consumption of shiitake mushroom. *Dermatol Reports* 2011;3:e21:21.
- 8 Krajewski PK, Matusiak Łukasz, Szepletowski JC. Flagellate dermatitis due to bleomycin intake. *Acta Dermatovenerol Croat* 2021;29:102–4.
- 9 Cullingham K, Kost G. A case of bleomycin-induced flagellate dermatitis: a case report. *SAGE Open Med Case Rep* 2021;9:2050313X2110394–3.
- 10 Rodríguez Pichardo A, García Bravo B, Rodríguez PGB B. Dermatitis Artefacta: a review. *Actas Dermosifiliogr* 2013;104:854–66.

- 11 Biswas A, Julka PK. Bleomycin induced flagellate erythema in a patient with thalamic mixed germ cell tumour: report of a rare adverse effect. *J Egypt Natl Canc Inst* 2016;28:129–32.
- 12 Chen Y-B, Rahemtullah A, Breeden E, *et al.* Bleomycin-Induced flagellate erythema. *J Clin Oncol* 2007;25:898–900.
- 13 Lee H-Y, Lim K-H, Ryu Y, *et al.* Bleomycin-Induced flagellate erythema: a case report and review of the literature. *Oncol Lett* 2014;8:933–5.
- 14 Biswas A, Chaudhari PB, Sharma P, *et al.* Bleomycin induced flagellate erythema: revisiting a unique complication. *J Cancer Res Ther* 2013;9:500–3.
- 15 Abess A, Keel DM, Graham BS. Flagellate hyperpigmentation following intralesional bleomycin treatment of verruca plantaris. *Arch Dermatol* 2003;139:337–9.
- 16 Le A, Farmakiotis D, Reagan JL. Pruritic rash in a patient with Hodgkin's lymphoma. *Cureus* 2018;10:e2450.
- 17 Chungal KH, Raina H, Chungal QH, *et al.* Bleomycin-Induced flagellate erythema: a rare and unique drug rash. *West Indian Med J* 2014;63:807–9.

Copyright 2022 BMJ Publishing Group. All rights reserved. For permission to reuse any of this content visit <https://www.bmj.com/company/products-services/rights-and-licensing/permissions/>
BMJ Case Report Fellows may re-use this article for personal use and teaching without any further permission.

Become a Fellow of BMJ Case Reports today and you can:

- ▶ Submit as many cases as you like
- ▶ Enjoy fast sympathetic peer review and rapid publication of accepted articles
- ▶ Access all the published articles
- ▶ Re-use any of the published material for personal use and teaching without further permission

Customer Service

If you have any further queries about your subscription, please contact our customer services team on +44 (0) 207111 1105 or via email at support@bmj.com.

Visit casereports.bmj.com for more articles like this and to become a Fellow