

# Choledochal Cyst – Presentation and Treatment in an Adult

Ferat Sallahu, Antigona Hasani, Dalip Limani, Skender Shabani, Fadil Beka, Skender Zatriqi, Skender Murati, Hysni Jashari  
Clinic of Surgery, University Clinical Centre of Kosovo, Prishtina, Kosovo

Corresponding author: Ferat Sallahu, MD, PhD. Lagja e Spitalit pp, 10000 Prishtina, Kosovo. E-mail: feratsa@yahoo.com

## Case report ABSTRACT

Choledochal cyst is a congenital cystic dilation of a part of bile duct that occurs most commonly in the main part of common bile duct. Diagnosis of choledochal cyst is concluded upon disproportionate expansion of extrahepatic bile duct. Symptom trias are: abdominal

pain, jaundice and abdominal mass represent clinical guideline signs of diagnosis. Furthermore, hepato-biliary diseases in adults can conceal the primary condition. In addition to this, ultrasound, CT, MRI, cholangiopancreatography (ERCP), transhepatic percutane cholangiography (PTC) guide us for a detailed examination in order to verify the diagnosis.

Active endoscopic cholangiography represents an important technique that provides needed anatomic solution and details in diagnosis of choledochal cyst.

Key words: Choledochal cyst, Magnetic resonance imaging, Computerised tomography, abdomen, holangiography.

## 1. INTRODUCTION

Choledochal cyst is a congenital cystic dilation of a part of bile duct that occurs most commonly in the main portion of common bile duct (1). Diagnosis of choledochal cyst is made based on a disproportionate dilation of extrahepatic biliary duct, without ruling out the possibility of a tumor, stone, or inflammation as a cause of this dilation.

Incidence of diagnosis of choledochal cyst is much higher in children (80%) than in adults (20%) (2). Symptom trias are: abdominal pain, jaundice and abdominal mass represent clinical guideline signs of diagnosis.

Furthermore, hepato-biliary diseases in adults can conceal the primary condition. In addition to this, ultrasound, CT, MRI, cholangiopancreatography (ERCP), transhepatic percutane cholangiography (PTC) guide us for a detailed examination in order to verify the diagnosis.

Surgical options in treatment of choledochal cyst are excision/removal of the cyst together with a part of bile duct achieved through *Roux-en-Y hepatico-jejunostomy*. Our case reports of a 57 year old patient on whom we performed surgery with a *Roux-en-Y hepatico-jejunostomy*.

## 2. CASE REPORT

Our patient was a 57 year old women that presented at our clinic with abdominal pain, vomiting, fever and jaundice. The patient presented with a history of moderate abdominal pain lasting for 3 months in the right higher quadrant of the abdomen and jaundice. The patient had previous history of abdominal pain without jaundice, and was treated by a pulmologist with the suspicion of pulmonary infiltration. In our department, during the physical examination, the patient complained of pain in the right hypocondrium radiating to her back.

No abdominal mass was palpated. The bilirubine level was 3.8 mg/dl. Ultrasound showed thickening of the gall blader, masses of stones in different diameters and a cystic dilation of common bile duct (diameter of CBD was 4.5 cm). MRCP revealed a fusiform dilation of CBD and oedema of the wall of the gall blader, common bile duct dilation, while the liver presented to be normal. Intraoperative exploration revealed a type Ic cyst; cholecystectomy and resection of the cyst with surgical *Roux-en-Y jejunio-hepatic anasto-*

mosis. The patient had a steady post-operative course.

## 3. DISCUSSION

Incidence of the choledochal cyst in western countries is 1 in 100,000-150,000 individuals.

Rate of incidence is higher in Asia and more common in women (1m : 6f). Alonso described classification of choledochal cysts as in 3 types, which were later modified by Todani et al. presented in Table 1 (1977).

This is the most commonly used classification. A type of cyst is a fusiform dilation of common bile duct. An isolated diverticulum that protrudes through the wall is considered to be a type II of choledochal cyst. Type III is also known as *choledocho-*

Type I	Dilation of extrahepatic biliary ducts. Type I of dilation is further classified according to the segment in type Ia: cystic dilation; type Ib: focal dilation of the segment; type Ic fusiform dilation.
Type II	Diverticular dilation of extrahepatic biliary ducts.
Type III	Cystic dilation of intraduodenal portion of common bile duct ( <i>choledochocele</i> )
Type IVa	Extrahepatic and intrahepatic dilation of bile ducts.
Type IVb	Dilation of many poertions of extrahepatic biliary ducts.
Type V	Limited dilation of intrahepatic biliary ducts ( <i>Caroli disease</i> ).

**Table 1.** Classification of choledochal cysts – modified by Todani and Alonso-Lej

cele because it originates from the intraduodenal portion of the common bile duct.

Multiple dilations of extrahepatic and intrahepatic origin are considered as type IVa, while type IVb includes extrahepatic bile ducts. Type V is also known as Caroli disease and it involves many dilations of bile ducts.

Ethiology of choledochal cysts is unknown. An anomalous pancreaticobiliary junction resulting in a joint extremely long common bile duct has been suggested to result in antenatal pancreatico-hepatic reflux and leads to infection and dilation of the biliary tree. Choledochal cysts occur most commonly in women. Adults with initial manifestation of choledochal cysts have non-specific symptoms in the right upper abdominal region, jaundice, pancreatitis or cholangitis. A palpable mass is rare and usually associated with children.

**4. CONCLUSION**

The two basic treatments of choledochal cysts are enterostomy of the cyst and hepatico-jejuno incision. Enterotomy of the cyst is technically easy to perform, but it is related to complications like anastomosis stricture, residual calculosis and malignant alteration of the wall of cyst. Hepatico-duodenostomy is technically demanding, but is linked with associated morbidity. Cholecystectomy is performed on regular basis every time when the cyst needs to be removed completely. In difficult situations, when the cyst wall is attached to the wall of hepatic artery and Portal vein, Lilly technique is used for removing the cyst. With this technique, we enter the cyst through anterior opening and we perform incision on the mucosa of the cyst in the external portion of the cyst attached to blood vessels.

Procedure of removing the cyst

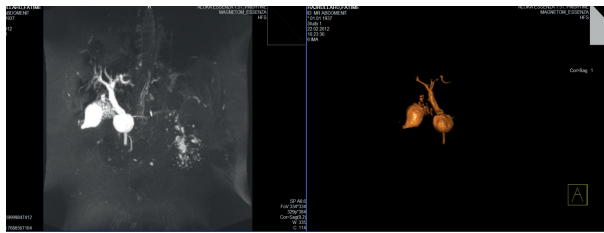


Figure 1. MRCP imaging shows a fusiform dilation of type Ic common bile duct with biligranine contrast (a, b)

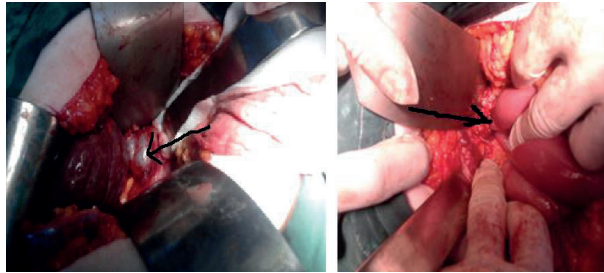


Figure 2. Identification of the cyst (a) and surgical solution (b)

reduces the risk of biliary tree inflammation and reduces the chances of development of cholangiocarcinoma and it's dissemination which is reported to be from 9% to 28%. Due to the high risk of a well documented cancer, cholecystectomy and resection of cysts with Roux-en-Y hepatico-jejuno anastomosis is the best solution for the patient. Choledochal cysts in adults should be considered separate entities from those in children.

**REFERENCES**

1. Sugiyama M, Haradome H, Takahara T. et al. Anomalous pancreaticobiliary junction shown on multidetector CT. *AJR Am J Roentgenol.* 2003; 180: 173-175.
2. Çerekçi R, Uzunkulao lu T, Ertan N. Koledok kisti olgusu: US, BT ve MR kolanjyografi bulguları. *Türk Tanısal ve Giri imsel Radyoloji Dergisi.* 2002; 8: 589-590.
3. Park DH, Kim MH, Lee SK, et al. Can MRCP replace the diagnostic role of ERCP for patient with koledokal cisteve? *Gastrointest Endosc.* 2005; 62: 360-366.
4. Liu YB, Wang JW, Devkota KR. et al. Congenital choledochal cisteve in adults: twenty-five-year experience. *Chin Med J.* 2007; 120: 1404-1407.
5. De Backer AI, Van den Abbeele K, De Schepper AM, Van Baarle A. Choledochocoele: diagnosis by magnetic resonance imaging. *Abdom Imaging.* 2000; 25: 508-510.
6. Dinsmore JE, Murphy JJ, Jamieson D. MRCP evaluation of koledokal cisteve. *J*

7. Srimurthy KR, Ramesh S. Laparoscopic management of pediatric koledokal cisteve in developing countries: review of ten cases. *Pediatr Surg Int.* 2006; 22: 144-149.
8. Karnak İ, Tanyel FC, Büyükpamukçu N, Hiçsönmez A. Spontaneous rupture of koledokalcyst: an unusual cause of acute abdomen in children. *J Pediatr Surg.* 1997; 32: 736-738.
9. De Kerckhove L, De Meyer M, Verbaandert C. et al. The place of liver transplantation in Caroli's disease and syndrome. *Transpl Int.* 2006; 19: 381-388.
10. Karim AS. Caroli's disease. *Indian Pediatr.* 2004; 41: 848-850.
11. Pinto RB, Lima JP, da Silveira TR. et al. Caroli's disease: report of 10 cases in children and adolescents in southern Brazil. *J Pediatr Surg.* 1998; 33: 1531-1535.
12. Harjai MM, Lal BK. Caroli disease. *Pediatr Surg Int.* 2000; 16: 431-432.
13. Wu KL, Changchien CS, Kuo CM. et al. Caroli's disease - a report of two siblings. *Eur J Gastroenterol Hepatol.* 2002; 14: 1397-1399.
14. Ros E, Navarro S. Ursodeoxycholic acid treatment of primary hepatolithiasis in Caroli's syndrome. *Lancet.* 1993; 342: 404-406.
15. Naga MI, Suleiman DN. Endoscopic management of koledokal cyst. *Gastrointest Endosc.* 2004; 59: 427-432.
16. Harris M, Angus P, Davis ID. Koledokal cyst and squamous-cell carcinoma of the biliary tract. *Intern Med J.* 2002; 32: 491.
17. Benjamin IS. Biliary cystic disease: the risk of cancer. *J Hepatobiliary Pancreat Surg.* 2003; 10: 335-339.
18. Jordan PH, Goss JA, Rosenberg WR, et al. Some considerations for management of koledokal cisteve. *Am J Surg.* 2004; 187: 790-795.
19. Patel YD, Sarwar U, Morehouse HT, et al. Radiological management of an inoperable cholangiocarcinoma arising from a koledokal cyst. *Clin Radiol.* 2001; 56: 503-519.
20. Wu DQ, Zheng LX, Wang QS, et al. Koledokal cists in pregnancy: case management and literature review. *World J Gastroenterol.* 2004; 10: 3065-3069.
21. Chen CP, Cheng SJ, Sheu JC, et al. Third-trimester evaluation of koledokal cyst using magnetic resonance imaging. *Prenat Diagn.* 2004; 24: 838-839.