



¹Dept of Paediatric Respiratory and Sleep Medicine, Royal Hospital for Sick Children, Edinburgh, UK.

²Dept of Paediatric Cardiac, Respiratory and Sleep Physiology, Royal Hospital for Sick Children, Edinburgh, UK.

The curious incident of groaning in the night-time

Case report

Introduction

Catathrenia (from the Greek *kata*, meaning “below”, and *threnia*, meaning “to lament”) is a rare sleep disorder with very few cases reported in children [1]. The principal feature of catathrenia is a monotonic expiratory groaning noise that may or may not be associated with an altered respiratory pattern. It is now classified amongst the sleep-related breathing disorders [2].

We report an interesting case of catathrenia in a 5-year-old boy who has been symptomatic from birth.

sleep, which had been present from around birth. His parents had not observed any apnoeas but had noted that the noise was exacerbated by upper respiratory tract infections. The noise had gradually improved over time but continued to impact other family members. He was an otherwise healthy boy who was developing normally and had normal speech. He had good sleep hygiene with no symptoms of hyperactivity or daytime somnolence reported. There was no past medical history of note and he was on no regular medications. Clinical examination was normal with grade 3 tonsils and a patent nasal airway noted.

Cite as: Langley RJ, Hill L, Hill EA, *et al*. The curious incident of groaning in the night-time. *Breathe* 2017; 13: 123–126.

Case report

A 3-year-old boy was referred for a sleep study *via* the otolaryngology team. He was initially referred after his parents reported a groaning noise during

Task 1

What investigation(s) would you consider?

- 1 Polysomnography
- 2 Cardiorespiratory polygraphy
- 3 Actigraphy



@ERSpublications

The first report of catathrenia in a child who has been symptomatic from birth

<http://ow.ly/XcY830bevOH>



© ERS 2017

Answer 1

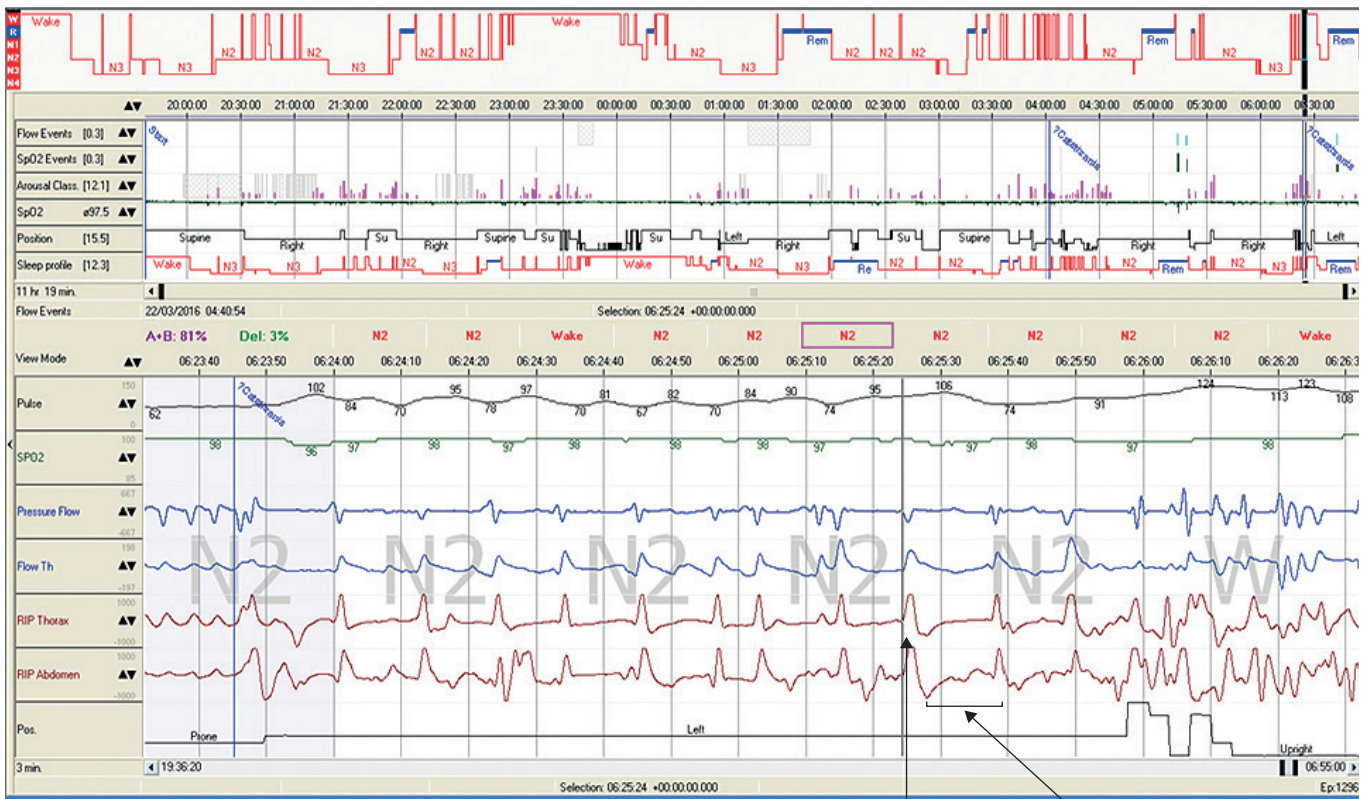
- 1 Indicated to screen for sleep-related breathing disorder but also to investigate parasomnia
- 2 Would screen for sleep-related breathing disorder but would not exclude parasomnia
- 3 No indication as no evidence of behavioural sleep problem

The study included electroencephalography (EEG), electro-oculography and electromyography monitoring, along with measures of airflow *via* nasal cannula and oronasal thermistor, respiratory effort *via* inductance plethysmography bands, and oxygen saturations by pulse oximetry. Sound and video were also recorded for the duration of the PSG.

Task 2

Interpret the PSG in figure 1 and the accompanying video in the supplementary material

At 5 years of age, an overnight in-patient polysomnography (PSG) was carried out (SOMNOScreen Plus PSG; S-MED, Birmingham, UK) in accordance with current international standards [3].



Deep inspiration
Prolonged expiration + groaning

Figure 1 PSG showing period of prolonged expiratory wailing during N2 sleep preceded by deep inspiratory effort.

Answer 2

The PSG showed two periods of wailing/groaning arising from non-REM stage 2 (N2) sleep, each preceded by an EEG arousal (arousal index 11.7 h^{-1}) (figure 1). This groaning was associated with deep inspiratory effort followed by prolonged expiration, though no oxygen desaturations were noted. Furthermore, study data demonstrated stable respiration and oxygenation (apnoea/hypopnoea index 0.4 h^{-1} ; oxygen desaturation index 0.3 h^{-1}) with normal sleep architecture.

Discussion

This is the first report of catathrenia in a child who has been symptomatic from birth. Catathrenia can be classified as either a respiratory disorder (type 1) or as a parasomnia (type 2) (table 1).

It may be that such a distinction between respiratory aetiology and parasomnia is unhelpful.

Table 1 Features associated with type 1 and type 2 catathrenia

Features	Type 1: respiratory disorder	Type 2: parasomnia
Likened to	“Sirens of the night”	“Elephant”
Duration of sound s	2–49	1–3
Intensity	Soft	Very loud
Sleep stage	Mainly REM	Non-REM and REM
Association with sleep disorders	Central apnoea/dysrhythmia	Normal/obstructive hypopnoea
CPAP response	No	Yes

Reproduced and modified from [4] with permission from the publisher.

The case described does not easily fit into one or the other category, having features of both type 1 (duration of sound 30 s to 1 min] and type 2 (very loud sound, exclusively in non-REM sleep) catathrenia noted.

Task 3

What treatment options would you consider?

Answer 3

The role of treatment for catathrenia is controversial, with reports of continuous positive airway pressure (CPAP) use during sleep having been described [5–7]. In the absence of obstruction, the role for CPAP is purely in obliterating the noise and groaning that occurs. On discussion with the parents of our case, they were happy simply to have an explanation for their child's problems and did not wish to pursue a trial of treatment.

Previous reports in children have not described catathrenia from birth. This report confirms the important role of PSG with video and audio recording in differentiating catathrenia from a wide differential diagnoses, including moaning during epileptic seizures, somniloquy, sleep apnoea, sleep-related laryngospasm and expiratory snoring or stridor.

Supplementary material

This article has supplementary material available from breathe.ersjournals.com

Conflict of interest

None declared.

References

1. Bar C, Pedespan JM, Ghoraveb I. Catathrenia in a four year old boy: a first case report. *Sleep Med* 2016; 20: 131–133.
2. American Academy of Sleep Medicine. International Classification of Sleep Disorders (ICSD-3). 3rd Edn. Darien, AASM, 2014.
3. American Academy of Sleep Medicine. AASM Manual for the Scoring of Sleep and Associated Events: Rules, Terminology and Technical Specifications Version 2.2. Darien, AASM, 2015.
4. Iriarte J, Campo A, Alegre M, *et al.* Catathrenia: respiratory disorder or parasomnia? *Sleep Med* 2015; 16: 827–830.
5. Ortega-Albás JJ, Diaz JR, Serrano AL, *et al.* Continuous positive airway pressure as treatment for catathrenia (nocturnal groaning). *Neurology* 2006; 67: 1103.
6. Pevernagie DA, Boon PA, Mariman AN, *et al.* Vocalization during episodes of prolonged expiration: a parasomnia related to REM sleep. *Sleep Med* 2001; 2: 19–30.
7. Abbasi AA, Morgenthaler TI, Slocumb NL, *et al.* Nocturnal moaning and groaning – catathrenia or nocturnal vocalisations. *Sleep Breath* 2012; 16: 367–373.