

Late recognition and transcatheter closure of ventriculopulmonary artery shunts in Fontan patients

 Mohamed Kasem,  Grazia Delle Donne,  Tommaso Generali,
 Antogni Deri,  John Thomson,  Jamie Bentham
 Yorkshire Heart Centre, Leeds General Infirmary; Leeds-United Kingdom

Introduction

In Fontan patients, the persistence of ventriculopulmonary flow is known to cause Fontan circuit pressure elevation and early failure (1, 2). Recognizing this issue can be challenging, until the failure is heralded. Early closure of the shunt may restore the hemodynamics. Here we describe the natural history of untreated ventriculopulmonary shunts in the circulation and the clinical benefits derived from transcatheter closure.

Case Report

This was a single center case-control study of all patients with total cavopulmonary connection (TCPC) at the Yorkshire Heart Centre between 2008 and 2017. In total, 111 TCPC's were isolated. Four patients with a persistent ventriculopulmonary shunt were identified.

The anatomy in patients 1, 2, and 3 was double-inlet left ventricle with transposed great arteries. Patient 4 had tricuspid atresia and transposed great arteries.

During the procedure, we accessed the right internal jugular vein under ultrasound guidance. Initial hemodynamics were obtained on 21% inspired oxygen, followed by an angiogram to delineate the defect. The defect was then crossed from the pulmonary artery. A Le Maitre balloon (Le Maitre Aortic Occlusion Catheter, Le Maitre Vascular, Inc. Burlington, USA) was used to balloon size at the narrowest point of the shunt. The elimination of the shunt was confirmed with a simultaneous ventriculogram (Fig. 1). We reassessed the hemodynamics during balloon occlusion.

An ADO I device (Amplatzer ductal occlude I, Abbott Medical, Plymouth, MN, USA) was deployed in all four cases. The size of the device was 2–3 mm larger than the size of the defect. The devices used were ADOI 10/8 mm in three patients and ADOI 14/12 mm in one patient (Table 1). No residual flow was detected on angiogram post-deployment.

All patients had impaired exercise tolerance [New York Heart Association (NYHA) class III]. One patient had liver disease, two had protein-losing enteropathy (PLE), one had significant cyanosis secondary to free regurgitation in diastole from the pulmonary arteries (PAs) tree to the single ventricle. A surveillance magnetic

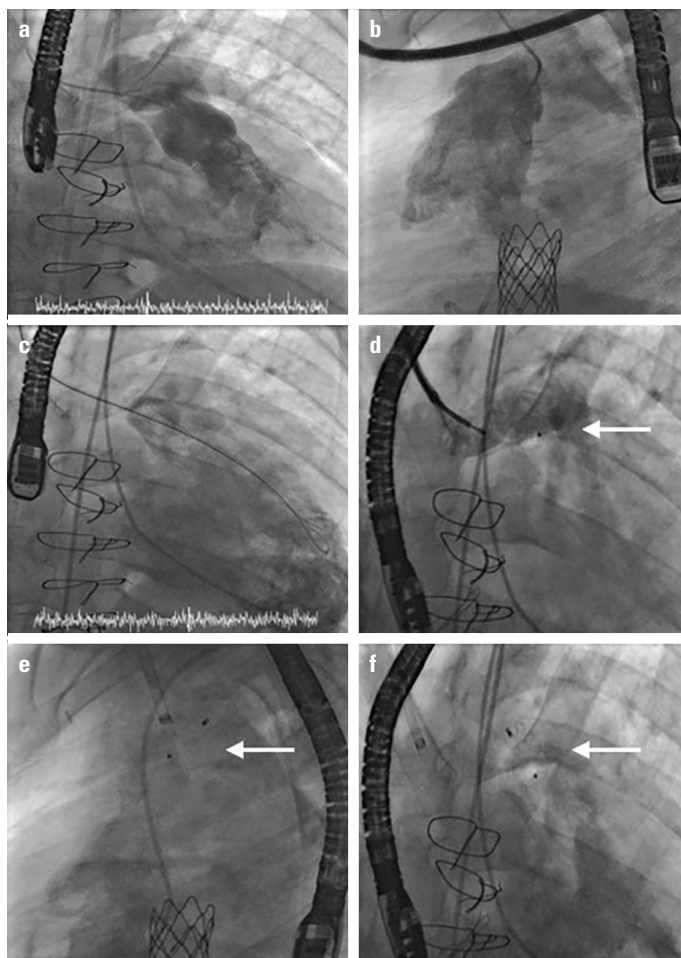


Figure 1. (a) The ventriculopulmonary shunt on posteroanterior projection. (b) The ventriculopulmonary shunt on lateral projection. (c) Balloon sizing of the ventriculopulmonary connection with simultaneous ventriculogram and transoesophageal echocardiogram. (d) Pre-deployment angiogram of the left pulmonary artery. (e) Post deployment angiogram on lateral projection with ventriculogram. (f) Post deployment angiogram on posteroanterior projection with ventriculogram

resonance imaging (MRI) scan showed the defect in three patients. In one patient, we diagnosed the defect during cardiac catheterization to stent the TCPC conduit and confirmed it on MRI scan.

The mean follow-up period was 3 years. At 1-year postoperatively, the NYHA class of all patients improved from class III to II. We demonstrated significant change in the hemodynamics (Table 1). Both patients with PLE showed improvement in serum albumin levels (pre-procedure 20 & 23 g/L to 25 & 43 g/L at 1 year). The fourth patient referred for cyanosis and exercise intolerance exhibited increase in saturations from 80% to 95%.

Discussion

In Fontan patients, the persistence of the ventriculopulmonary shunt during the early postoperative period can result in

Table 1. Patient's anatomy and condition

Anatomy	Age at procedure (years)	Interval since indication last surgery (years)	Condition pre-catheter	Condition post-catheter	PA/PCW pressure pre- (mm Hg)	PA/PCW pressure post- (mm Hg)	Device used size of shunt		
DILV, TGA	28	12	Liver disease	NYHA3, liver disease, sats 94%	NYHA2	20/15	15/11	14/12 ADOI	8 mm 2:1
TGA, VSD, PS	6	5	Facial plethora, cyanosis	Failing Glenn	TCPC	24/14	15/10	12/10 ADOI	9 mm
DILV, TGA	25	10	PLE	Hypoalbuminaemia (20g/dl), mild ascites	Albumin increased, ascites resolved	13/10	11/8	10/8 ADOI	7 mm
DILV, TGA	20	10	PLE, Liver failure	NYHA3, ascites, oesophageal varicies	No change	14/9	13/8	10/8 ADOI	7 mm
TGA, VSD, DORV	6	0	Desaturations, facial swelling	Ventilated, iNO, inotrops, oxygen saturations 60% failing Glenn	Died	25/15	22/9	8/6 ADOI	5 mm
TA, TGA	27	22	Cyanosis exertional dyspnoea	Sats low 80s, NYHA3, atrial dysrhtymia	NYHA2, sats 92%, dysrhtymia	15/8	13/7	10/8 ADOI	

DILV, TGA, PA band, TCPC: Double inlet ventricle, transposed great arteries, Pulmonary artery band, and Total Cavopulmonary connection.
 TA, TGA, PA band, classical Fontan: Tricuspid atresia, transposed great arteries, Pulmonary artery band and classical Fontan.
 PLE - protein losing enteropathy, NYHA: New York Hear Association, Alb - albumin, O₂ - Oxygen, AF - atrial fibrillation, PAP/PCWP - pulmonary artery pressure/pulmonary capillary wedge pressure, ADOI - Amplatzer Ductal Occluder I.

persistent pleural effusions or ventricular failure. Treatment of this problem has rarely been reported in the literature (3) and has not been adequately reported in adult congenital patients some years after Fontan completion.

Out of the 111 TCPC patients, 58 had the diagnosis of transposed great arteries; four patients from this group attracted our attention due to persistent ventriculopulmonary connection. The posterior and short main pulmonary artery, coupled with previous operations and adhesions, could understandably pose a challenge to the surgeon to divide the main pulmonary artery safely in all cases. While ligation could be adequate to stop the forward flow, the flow may re-establish over the years, in our experience.

Some adult congenital patients have very limited imaging windows on transthoracic echocardiography, highlighting the importance of surveillance MRI scans and consideration of invasive hemodynamic assessment for Fontan patients (4, 5).

Transcatheter closure of the residual ventriculopulmonary shunt is a relatively uncomplicated procedure. Transesophageal echocardiography and angiography to assess the morphology and size of the defect were reportedly effective in a pediatric group (4). In adults where imaging can be more challenging, we have found that a Le Maitre balloon is very effective at sizing the defect and is less likely to cause any dilatation of the ventriculopulmonary connection compared with other sizing methods. There was a significant hemodynamic improvement in all patients in our study.

Conclusion

Ventriculopulmonary connections may resurface during adult life years after Fontan completion in a select group of pa-

tients. It is important to recognize this rare, but treatable, cause of hemodynamic disturbance in Fontan patients using surveillance MRI and vigilance. Transcatheter closure of ventriculopulmonary shunt proved to be safe and effective clinically and hemodynamically.

Informed consent: Not applicable.

References

- Gewillig M. The Fontan circulation. *Heart* 2005; 91: 839-46.
- Gewillig M, Brown SC. The Fontan circulation after 45 years: update in physiology. *Heart* 2016; 102: 1081-6.
- Desai T, Wright J, Dhillon R, Stumper O. Transcatheter closure of ventriculopulmonary artery communications in staged Fontan procedures. *Heart* 2007; 93: 510-3.
- Ebeid MR, Gaymes CH, Joransen JA. Catheter closure of accessory pulmonary blood flow after bidirectional Glenn anastomosis using Amplatzer duct occluder. *Catheter Cardiovasc Interv* 2002; 57: 95-7.
- Di Maria MV, Brown DW, Cetta F, Ginde S, Goldberg D, Menon SC, et al. Surveillance Testing and Preventive Care After Fontan Operation: A Multi-Institutional Survey. *Pediatr Cardiol* 2019; 40: 110-5.

Address for Correspondence: Mohamed Kasem, MD,
 Yorkshire Heart Centre,
 Leeds General Infirmary,
 Great George Street LS13EX,
 Leeds-United Kingdom
 Phone: +0044 113 3927639
 Fax: +0044 113 3927633

E-mail: mohamed.kasem@doctors.org.uk

©Copyright 2019 by Turkish Society of Cardiology - Available online at www.anatoljcardiol.com

DOI:10.14744/AnatolJCardiol.2019.33581

