

## Multiple pulmonary arterial aneurysms in a young male patient with incomplete Behçet's syndrome

Sir,

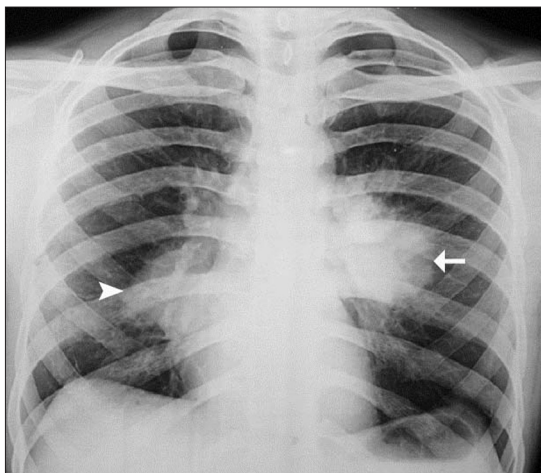
We read with interest the case report of Hugh Stovin syndrome by Choh *et al*,<sup>[1]</sup> a condition in which pulmonary arterial aneurysms (PAA) are associated with deep venous thrombosis and is considered to be a forme fruste of Behçet's syndrome. We would like to share our experience with a patient who had incomplete Behçet's syndrome and multiple PAA.

An eighteen year old gentleman presented with six-month duration of low-grade fever, dry cough, anorexia and significant weight loss. Three months back, he was started on empirical anti-tubercular therapy elsewhere without any improvement of symptoms. Since last one month, patient also developed small quantity hemoptysis. He was again evaluated elsewhere and was found to have leucocytosis and high ESR. His chest radiograph showed bilateral hilar opacities [Figure 1] and contrast enhanced CT angiography revealed multiple pulmonary arterial aneurysms (PAAs) [Figure 2]. A diagnosis of vasculitis was considered, and patient was started on 1 mg/kg/day of prednisolone. Although constitutional symptoms including fever subsided, patient developed left sided chest pain and mild dyspnoea fifteen days later. The chest radiography repeated showed a significant increase in the size of left sided pulmonary arterial aneurysm [Figure 3] and he was then referred to us in January 2010. We discovered that his past had been remarkable for recurrent oral ulcerations since one year without any history of genital ulcers,

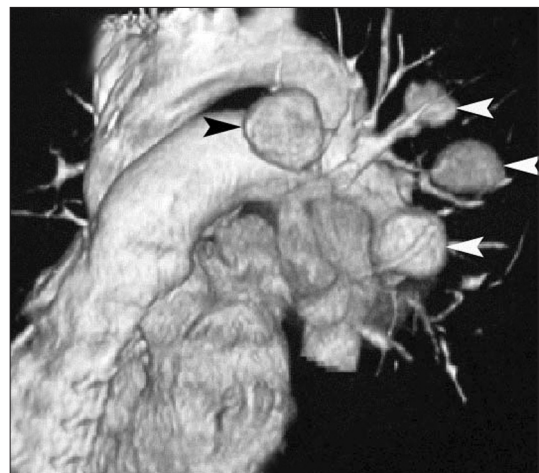
uveitis, thrombophlebitis, skin rash, arthritis or cardiac disease. Pathergy test was positive. Hence we made a diagnosis of incomplete Behçet's syndrome with PAA and initiated the patient on monthly intravenous pulse cyclophosphamide therapy. High-dose corticosteroids were continued. However, patient was reluctant to undergo any endovascular or surgical intervention. Eventually, patient met with sudden death three months later at home while on immunosuppressive therapy.

PAA in Behçet's syndrome occurs due to vasculitis and the inflammatory process is located primarily in the vasa vasorum.<sup>[2]</sup> The vasculitis of Behçet's syndrome is typical in that it involves both arteries and veins of all sizes and has a distinctive tendency for aneurysm formation. Male sex and young age at onset are associated with higher risk for vascular involvement, including PAA. PAAs are often multiple and bilateral involving large and medium-sized pulmonary arteries and are associated with venous thrombosis in 77-81% of patients with BS.<sup>[3,4]</sup> Hemoptysis is the most common symptom and is due to rupture of PAA lesions into bronchi which can be massive and fatal. Pulmonary vasculitis in Behçet's disease can also result in stenosis, thrombosis or occlusion of pulmonary vessels.

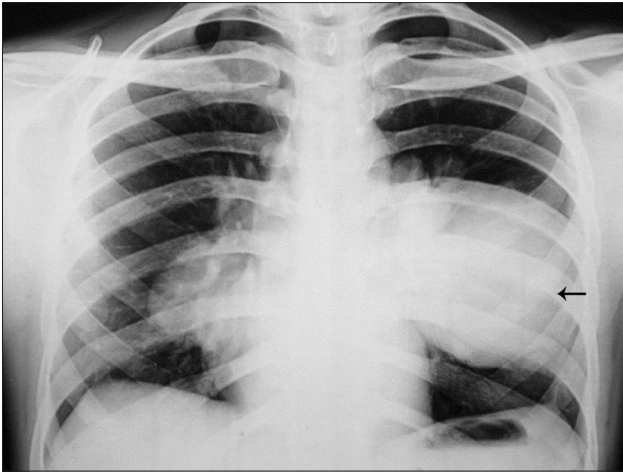
PAA is a major cause of mortality in Behçet's syndrome with one-year mortality reported as high as 50% in 1992.<sup>[5]</sup> Recently a more favorable survival rate of 62-74% at five years was found, mainly due to early diagnosis and initiation of aggressive treatment.<sup>[3,4]</sup> The standard treatment includes



**Figure 1:** Chest Radiograph shows a round shaped homogenous opacity at left main hilum (arrow) and a curvilinear shadow at inferior pole of right hilum (arrow head)



**Figure 2:** Contrast enhanced CT angiography with three-dimensional (3D) image reconstruction revealed multiple saccular pulmonary arterial aneurysms (arrow heads)



**Figure 3:** The chest radiography repeated fifteen days later shows a significant increase in the size of left sided pulmonary arterial aneurysm (arrow)

high-dose corticosteroids and cyclophosphamide. The protocol currently used by Cerrahpasa group from Istanbul includes three 1000 mg pulses of methylprednisolone followed by prednisolone 1 mg/kg/day, which is gradually tapered and discontinued according to clinical response.<sup>[6]</sup> Intravenous cyclophosphamide 1000 mg, is given monthly for the first year and then every other month for the second year. Following this, the treatment is either stopped or maintained with azathioprine, 2.5 mg/kg/day according to clinical response. There are reports of successful treatment of PAA with anti-TNF alpha agents when the initial treatment with immunosuppressive agents has failed.<sup>[7]</sup> Although surgery carries a high risk of mortality in emergencies, endovascular embolization has been tried with greater success in terms of cumulative survival.<sup>[8]</sup> However, Vena cava thrombosis may preclude the use of these life-saving techniques in some patients.

Usually described five years after disease onset, PAA may occur earlier in the disease course and even precede the disease onset.<sup>[9]</sup> PAA may occasionally develop in a young male patient with incomplete form of Behçet's syndrome.<sup>[9]</sup> PAA may be misdiagnosed as pulmonary tuberculosis,

especially in tropical countries endemic for tuberculosis, which can lead to a delay in appropriate treatment. To conclude, early diagnosis and prompt initiation of aggressive immunosuppressive therapy supported by endovascular interventional techniques may result in improved survival of these patients.

**Suresh Kanchinadham, Damodaram Potikuri**

*Department of Rheumatology, Nizam's Institute of Medical Sciences, Punjagutta, Hyderabad India  
E-mail: sureshkanchinadham@gmail.com*

## REFERENCES

1. Choh NA, Jehangir M, Mir KM, Kuchay S, Wani NA. Hughes-Stovin syndrome: A rare cause of hemoptysis. *Lung India* 2011;28:285-6.
2. Kobayashi M, Ito M, Nakagawa A, Matsushita M, Nishikimi N, Sakurai T, et al. Neutrophil and endothelial cell activation in the vasa vasorum in vasculo-Behçet disease. *Histopathology* 2000;36:362-71.
3. Hamuryudan V, Er T, Seyahi E, Akman C, Tüzün H, Fresko I, et al. Pulmonary artery aneurysms in Behçet syndrome. *Am J Med* 2004;117:867-70.
4. Seyahi E, Melikoglu M, Akman C, Hamuryudan V, Ozer H, Hatemi G et al. Pulmonary artery involvement and associated lung disease in Behçet disease: A series of 47 patients. *Medicine (Baltimore)* 2012;91:35-48.
5. Hamuryudan V, Yurdakul S, Moral F, Numan F, Tüzün H, Tüzüner N, et al. Pulmonary arterial aneurysms in Behçet's syndrome: A report of 24 cases. *Br J Rheumatol* 1994;33:48-51.
6. Calamia KT, Schirmer M, Melikoglu M. Major vessel involvement in Behçet's disease: An update. *Curr Opin Rheumatol* 2011;23:24-31.
7. Lee SW, Lee SY, Kim KN, Jung JK, Chung WT. Adalimumab treatment for life threatening pulmonary artery aneurysm in Behçet disease: A case report. *Clin Rheumatol* 2010;29:91-3.
8. Uzun O, Akpolat T, Erkan L. Pulmonary vasculitis in Behçet's disease: A cumulative analysis. *Chest* 2005;127:2243-53.
9. Uzun O, Erkan L, Akpolat I, Findik S, Atici AG, Akpolat T. Pulmonary involvement in Behçet's disease. *Respiration* 2008;75:310-21.

### Access this article online

#### Quick Response Code:



#### Website:

www.lungindia.com

#### DOI:

10.4103/0970-2113.106121