

Ptosis induced by topical steroid eye drops

Two cases reports

Yanan Zhu, PhD, Chaohui Sun, MD, Xin Zhang, MM, Xingchao Shentu, MD*

Abstract

Rationale: Ptosis is a rare complication of periocular steroid use. Studies report that local injections of steroids produce ptosis. We describe the first 2 cases of ptosis because of long-term treatment with topical steroid eye drops.

Patient concerns: Two cases admitted to our hospital because of ptosis of their right eye after long-term treatment with topical steroid eye drops. Both of them had uncontrolled Posner–Schlossman syndrome.

Diagnosis: Two cases were diagnosed as steroid-related ptosis.

Interventions: Regulatory anti-inflammation therapy was prescribed for case 1, and after inflammation control, phacoemulsification was done for her. Six months after steroid withdrawal, the levator resection of the right eye was performed. Case 2 refused our advice of steroid reduction and ptosis surgery.

Outcomes: After surgery, case 1 retained a symmetrical appearance during a 1-year follow-up. In the surgery, we found thin levator muscles and slack levator palpebrae superioris aponeurosis (LPSA) in the affected eye. Postoperative transmission electron microscopy revealed typical signs of apoptosis in levator muscle cells.

Lessons: We suggest topical application of steroids induces levator muscle apoptosis and LPSA weakness, and results in ptosis.

Abbreviations: LPS = levator palpebrae superioris, LPSA = levator palpebrae superioris aponeurosis, TEM = transmission electron microscopy.

Keywords: Apoptosis, eye drop, ptosis, steroid, transmission electron microscopy

1. Introduction

Corticosteroids are widely used in the treatment of eye diseases, especially ocular inflammation, such as uveitis, macular-edema, Posner–Schlossman syndrome, keratitis, inflammatory lesions of the eyelid, and orbit.^[1–3] However, there are a variety of adverse ocular and systemic side effects associated with the use of periocular steroids. These include cataracts, decreased wound healing, orbital fat atrophy, and ptosis.^[4–6] Steroid-induced ptosis is a rare complication, and the mechanism of steroid-induced ptosis remains unexplained. We herein describe the first

cases of ptosis because of long-term treatment with topical steroid eye drops and explore the mechanism of steroid-induced ptosis. The Research Ethics Committee of Zhejiang University approved the case report. The patients were informed and signed his consent according to the institutional guidelines and in compliance with the Helsinki Declaration.

1.1. Case 1

The patient was a 62-year-old woman with Posner–Schlossman syndrome of the right eye who had used 1% Prednisolone acetate eye drops (Pred Forte, Allergan, Ireland) for almost 16 months. Attempts to decrease the steroid usage included administering a combination of bromfenac sodium hydrate and carteolol hydrochloride. However, these attempts failed, and the ocular pressure increased once the steroid dose was reduced. After 11 months of the steroid treatment, the patient developed mild ptosis of the right eye, which gradually worsened. A neurological examination excluded neurogenic diseases. Owing to the long-term use of the steroid, the patient also developed a cataract.

After controlling the inflammation, phacoemulsification was performed 13 months after the commencement of the steroid treatment. The first week after the surgery, the patient was treated with topical antibiotics (levofloxacin) and steroid eye drops (1% Prednisolone acetate). The antibiotic treatment was stopped, but steroid was continuously prescribed. At the 1-month follow-up, corneal binocular muscle-fat keratic precipitates had become pigmented. The steroid dose was gradually decreased and stopped 3 months postoperatively. After withdrawal of the steroid treatment, the intraocular pressure was normal, and the ptosis of the right eye was stable. Six months later, the ptosis remained stable, and levator resection of the right eye was

Editor: Lok-Hou Pang.

This work was supported by Zhejiang Provincial Natural Science Foundation of China (No. LQ15H120002), Program of National Natural Science Foundation of China (No. 81500704; 81670834; 81371000), and the Foundation from Health and Family Planning Commission of Zhejiang Province (No. 201347434).

The authors report no conflicts of interest.

Eye Center, 2nd Affiliated Hospital of Medical College, Zhejiang University, Hangzhou, Zhejiang, China.

* Correspondence: Xingchao Shentu, Eye center, 2nd Affiliated Hospital of Medical College, Zhejiang University, Hangzhou, Zhejiang, 310009, China (e-mail: stxc@zju.edu.cn).

Copyright © 2017 the Author(s). Published by Wolters Kluwer Health, Inc. This is an open access article distributed under the terms of the Creative Commons Attribution-Non Commercial License 4.0 (CCBY-NC), where it is permissible to download, share, remix, transform, and build up the work provided it is properly cited. The work cannot be used commercially without permission from the journal.

Medicine (2017) 96:51(e9288)

Received: 7 May 2017 / Received in final form: 22 November 2017 / Accepted: 27 November 2017

<http://dx.doi.org/10.1097/MD.0000000000009288>

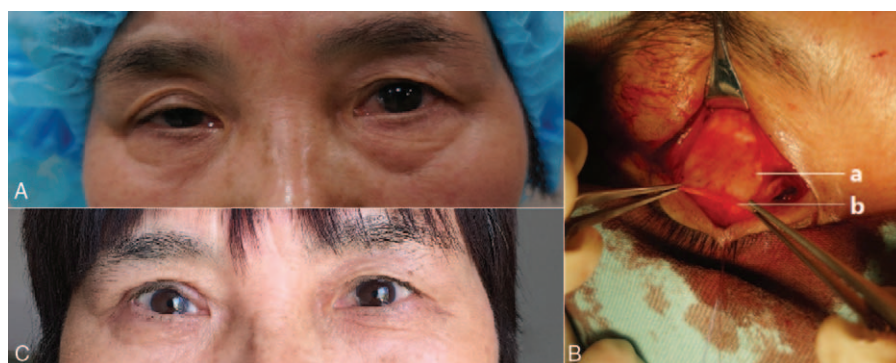


Figure 1. (A) Case 1. A 62-year-old man who developed ptosis of the right upper eyelid after topical application of 1% Prednisolone acetate eye drops for 16 months. (B) Visualization of poor texture of the levator palpebrae superioris muscle (a) and slack levator palpebrae superioris aponeurosis (b). (C) Case 1. Symmetrical appearance of both eyes after surgery.

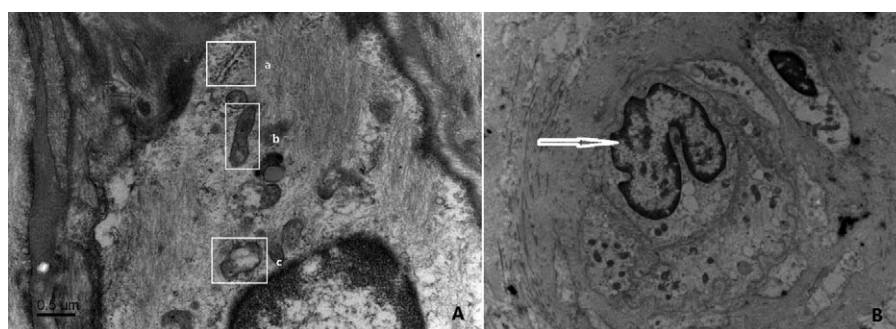


Figure 2. (A) Transmission electron microscopy showing swelling of the endoplasmic reticulum (a), mitochondria (b), and mitochondria vacuoles (c) in levator muscle cells. (B) Transmission electron microscopy revealed nucleus shrinkage and chromatin aggregation (arrow) in levator muscle cells.

performed. Preoperatively, ptosis of the upper right eyelid was 5 mm. The levator function of the right eye was 8 mm, which was weaker than that of the left eye (12 mm). The eyelid fold position was higher in the right eye (Fig. 1A). At surgery, the levator palpebrae superioris (LPS) muscle was thin, and the levator palpebrae superioris aponeurosis (LPSA) was slack (Fig. 1B). Subsequently, a 4-mm levator resection, with hang-back sutures was successfully performed. Postoperatively, transmission electron microscopy (TEM) revealed typical signs of apoptosis, including nucleus shrinkage and chromatin aggregation, in addition to swelling of the mitochondria, endoplasmic reticulum, and mitochondria vacuoles in levator muscle cells (Fig. 2). After the surgery, both eyes retained a symmetrical appearance during a 1-year follow-up (Fig. 1C).

1.2. Case 2

The patient was a 30-year-old male who presented to our outpatient because he was unable to open his right eye. Five years earlier, the patient had been diagnosed with Posner–Schlossman syndrome in another hospital. He had been treated with tobramycin/dexamethasone (TobraDex, Alcon, Belgium), but the treatment failed to control the disease. When the steroid dose was reduced, the patient's intraocular pressure increased, and corneal keratic precipitates appeared. In the past 2 years, he had used tobramycin/dexamethasone four times each day. One month earlier, he had noticed an abnormality in his right eye. An examination revealed ptosis (3 mm) of the right upper eyelid. The levator function of the right eye was 8 mm, which was

weaker than that of the left eye (12 mm), as shown in Figure 3. The eyelid fold position was higher in the right eye. After excluding neurogenic etiologies, the patient was advised that he should reduce the frequency of the steroid treatment and that surgery could be performed when his ptosis was stable. However, because of the fear of recurrence of Posner–Schlossman syndrome, the patient did not agree.

2. Discussion

Ptosis is a rare complication of steroid use. Studies reported that local injections of steroids, including posterior sub-Tenon's, intracameral, and subconjunctival injections of corticosteroids produced ptosis.^[6–9] According to previous studies, ptosis occurred 0 to 49 months after local injections.^[6,9] Triamcinolone and dexamethasone, which were used in local injections are the 2 principal drugs known to induce ptosis. Herein, the present case

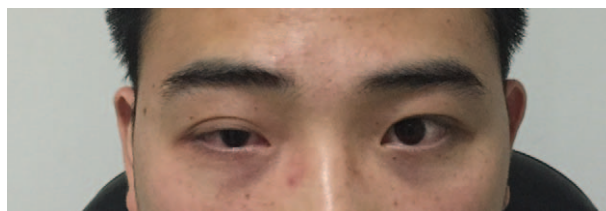


Figure 3. Case 2. A 30-year-old man with ptosis of the right upper eyelid after 5 years of topical dexamethasone application.

is the first report of this side effect owing to topical application of eye drops.

A few studies have investigated the mechanism of steroid-related ptosis.^[6–11] However, the mechanism of steroid-induced or steroid vehicle-induced ptosis is unknown. Some researchers hypothesized that topical steroids may have direct effects on levator muscles or Müller muscle.^[6,10] Others hypothesized that the vehicle used in steroid preparations may cause acute myopathic ptosis.^[7–9] At present, there is insufficient evidence to support either of these hypotheses. In a study by Song et al,^[6] a histopathological examination did not reveal any significant inflammation or structural differences in the levator muscles or aponeurotic eyelid tissues. An animal study only observed minimal polymorphonuclear leukocyte infiltration in rabbit periocular tissues up to 2 months after subconjunctival and retrobulbar injections of cortisone.^[11]

Our study revealed signs of apoptosis in the levator muscles, including nucleus shrinkage and chromatin aggregation, in addition to swelling of mitochondria, endoplasmic reticulum, and mitochondria vacuoles. We suggest that the long-term use of the steroid drops may explain these pathological changes. Our results were similar to those found in a study by Lee et al^[12] of steroid-induced myopathy, in which skeletal muscle apoptosis developed. In that study, biopsies of skeletal muscle showed variations in muscle fibers size, atrophy, and necrosis. The lesions observed in the present study suggested steroid-induced apoptosis in the levator muscle.

Previous studies of steroid-induced myopathy proposed that Fas-Fas ligand signals may trigger steroid-induced apoptosis, with initiator caspase 8, execution caspase 9, Bax, Bad, and Bid promoting apoptosis, and that apoptotic signals resulted in changes in mitochondrial permeability.^[12,13] In the present study, the swelling of mitochondria and swelling of the endoplasmic reticulum indicated abnormal protein catabolism and mitochondrial dysfunction, which may result in steroid-induced myopathic ptosis.

Corticosteroids have also been reported to weaken tendons. Hugate et al^[14] reported that local injections of a corticosteroid, both within the tendon and into the retrocalcaneal bursa, adversely affected the biomechanical properties of rabbit Achilles tendons. Anderson and Dixon suggested that aponeurotic ptosis should be considered when the levator function was 8 mm or stronger in ptosis cases. And in aponeurotic ptosis cases, the eyelid fold position was always higher in the affected eye.^[15] In the present study, the levator function was 8 mm in both patients, indicating slight levator muscle weakness. In addition, the eyelid fold position of the right eye was higher than that of the left one. Furthermore, we found the slack LPSA in the first case.

According to a previous study^[15] and the surgical observation, aponeurotic ptosis was thought to be coexistent in these 2 cases. Aponeurotic ptosis is the most frequent type of acquired ptosis owing to senescence, dehiscence, or disinsertion of the LPSA, which overlies the Müller muscle and is located beneath orbital septum adipose tissue.^[16] We suggest that aponeurotic ptosis might be an additional cause of steroid-related ptosis. However, more histopathological evidence is needed to support our hypothesis.

In summary, topical application of steroids induced levator muscle apoptosis and LPSA weakness, and finally resulted in ptosis. Surgery can be used to treat steroid-induced ptosis.

References

- [1] Zhang L, Wang W, Gao Y, et al. The efficacy and safety of current treatments in diabetic macular edema: a systematic review and network meta-analysis. *PLoS One* 2016;11:e0159553.
- [2] Fardeau C, Champion E, Massamba N, et al. Uveitic macular edema. *Eye (Lond)* 2016;30:1277–92.
- [3] Haeck IM, Rouwen TJ, Timmer-de Mik L, et al. Topical corticosteroids in atopic dermatitis and the risk of glaucoma and cataracts. *J Am Acad Dermatol* 2011;64:275–81.
- [4] Uchiyama E, Papaliodis GN, Lobo AM, et al. Side-effects of anti-inflammatory therapy in uveitis. *Semin Ophthalmol* 2014;29:456–67.
- [5] Al Dhibi HA, Arevalo JF. Clinical trials on corticosteroids for diabetic macular edema. *World J Diabetes* 2013;4:295–302.
- [6] Song A, Carter KD, Nerad JA, et al. Steroid-induced ptosis: case studies and histopathologic analysis. *Eye (Lond)* 2008;22:491–5.
- [7] Newsome DA, Wong VC, Cameron TP, et al. ‘Steroid-induced’ mydriasis and ptosis. *Invest Ophthalmol* 1971;10:424–9.
- [8] Viola F, Morescalchi F, Ratiglia R, et al. Ptosis following an intravitreal injection of triamcinolone acetonide. *Eye (Lond)* 2007;21:421–3.
- [9] Morley AM, Tumuluri K, Meligoni G, et al. Myopathic ptosis following posterior sub-Tenon’s triamcinolone acetonide injection. *Eye (Lond)* 2009;23:741–2.
- [10] McGhee CN, Ellerton CR. Complications of excimer laser photorefractive surgery. *Excimer Lasers in Ophthalmology, Principles and Practice*. London: Martin Dunitz; 1997; pp. 380–402 Chapter 23.
- [11] Leopold IH, Purnell JE, Cannon EJ, et al. Local and systemic cortisone in ocular disease. *Am J Ophthalmol* 1951;34:361–71.
- [12] Lee MC, Wee GR, Kim JH. Apoptosis of skeletal muscle on steroid-induced myopathy in rats. *J Nutr* 2005;135:1806S–8S.
- [13] Stasio GO, Lemke BN, Wallow IH, et al. Levator aponeurosis elastic fiber network. *Ophthalm Plast Reconstr Surg* 1993;9:1–0.
- [14] Hugate R, Pennypacker J, Saunders M, et al. The effects of intra-tendinous and retrocalcaneal intrabursal injections of corticosteroid on the biomechanical properties of rabbit Achilles tendons. *J Bone Joint Surg Am* 2004;86-A:794–801.
- [15] Anderson RL, Dixon RS. Aponeurotic ptosis surgery. *Arch Ophthalmol* 1979;97:1123–8.
- [16] Mitsui T, Azuma H, Nagasawa M, et al. Chronic corticosteroid administration cause mitochondrial dysfunction in skeletal muscle. *J Neurol* 2002;249:1004–9.