

A unique case of split cord malformation type 1 with three different types of bony spurs

Kanwaljeet Garg, Vivek Tandon, Ashok Kumar Mahapatra¹

Department of Neurosurgery, All India Institute of Medical Sciences, New Delhi, ¹All India Institute of Medical Sciences, Bhubaneswar, Odisha, India

ABSTRACT

Split cord malformation (SCM) is a rare congenital anomaly. The presence of bony spurs seen in type 1 SCM are usually partial and unequivocally are found attached to the dorsal surface of the vertebral body. We present here a unique case of SCM where the bony spur was found attached to the ventral aspect of the posterior arch and there were three different types of spurs (Type 1A, 1B and 1C) in the same patient.

Key words: Diastematomyelia, hemicord, split cord malformation

Introduction

Split cord malformation (SCM) is a rare congenital anomaly, in which the cord is split over a portion of its length to form double dural tubes (SCM type 1) or two hemicords in a single dural sheath (SCM type 2). Understanding the embryogenesis of SCMs has increased considerably in the recent years, especially after the proposal by Pang *et al.* and Pang of the unified theory on the embryogenesis of SCM.^[1-3] Mahapatra and Gupta in 2005 reclassified SCM type 1 into three subtypes, type 1A, 1B and 1C.^[4] The bony spurs seen in type 1 SCM are usually partial and are unequivocally found attached to the dorsal surface of the vertebral body. We present here a unique case of SCM where the bony spur was attached to the ventral aspect of the posterior arch and there were three different types of spurs (Type 1A, 1B and 1C) in the same patient.

Case Report

A 16-month-old boy presented to us with a hernia over the lower part of right chest cavity. He was the second child in

the family and the product of a full term normal vaginal delivery. There was no swelling, tuft of hair or any other cutaneous stigmata over the lower back. He had scoliosis with convexity toward the left side. There was no weakness in either of the lower limbs. Bladder and bowel functions were not impaired.

Examination revealed absent lower ribs on the right side and hernia over the lower part of the right side of the chest cavity which appeared on coughing/crying [Figure 1a]. There was no swelling over the back in the midline in the lumbo-sacral region and his head size was appropriate for his age. Chest X-ray revealed absent right sided lower ribs with scoliosis. Non-contrast computed tomography spine confirmed the absence of ribs with D11 and D12 hemivertebra [Figure 1b] and showed a type 1 SCM at D11 to L3 level [Figure 2a] with widened spinal canal [Figure 2a]. At D11 there was a complete spur dividing the spinal canal into two equal parts and below this level there was a partial "Y" shaped dorsal spur with its two limbs attached to the ventral surface of the posterior arch [Figure 2b]. Magnetic resonance imaging spine revealed spinal dysraphism in the dorsolumbar region with SCM type 1 with syrinx in both the hemicords [Figure 3] and the cord ending at L4 level, with a thickened filum terminale [Figure 3].

This is an open access article distributed under the terms of the Creative Commons Attribution-NonCommercial-ShareAlike 3.0 License, which allows others to remix, tweak, and build upon the work non-commercially, as long as the author is credited and the new creations are licensed under the identical terms.

For reprints contact: reprints@medknow.com

Access this article online	
Quick Response Code:	Website: www.asianjns.org
	DOI: 10.4103/1793-5482.149981

Address for correspondence:

Dr. Kanwaljeet Garg, Department of Neurosurgery, Cardio-Neuro Centre, Room No 720, All India Institute of Medical Sciences, New Delhi, India.
E-mail: gargneuro@hotmail.com

How to cite this article: Garg K, Tandon V, Mahapatra AK. A unique case of split cord malformation type 1 with three different types of bony spurs. Asian J Neurosurg 2017;12:305-8.

The child was operated and a D11 to L5 laminectomy was done. The D11 and D12 vertebra were hemivertebra with absent lower ribs on the right side. Intraoperatively there was type 1 split with two hemicords in separate dural sheaths. Interestingly, there were three spurs separating the two hemicords. There was a type 1B (as per the classification

given by Mahapatra and Gupta) at D11 level, type 1A split at L1 level and type 1C at L3 level. All the spurs were excised microsurgically using high speed drill and smallest diamond burr and both the dural envelopes were opened and sutured into one sheath. The filum was thickened (1.8 cm) and a portion of filum was excised to prevent traction on the conus. As there was extensive handling of the spinal cord and the conus, the patient was given injection Methylprednisolone intravenously intraoperatively and continued for 48 hours after surgery. Patient had an uneventful recovery with no new deficit.

Discussion

The SCM is a rare congenital anomaly, only few large series are reported. SCM was first described by Ollivier, in 1837, which he termed as diastematomyelia.^[5] He used this term to describe an abnormality of the spinal cord in which the dura is separated by a bone spur or rigid fibrous bands to create two sleeves, each containing a portion of spinal cord divided sagittally into two parts. Bruce *et al.* used the term diastematomyelia to describe a spinal cord split by a midline bony spur, reserving the term “diplomyleia” for a true doubling of the spinal cord, without a spur.^[6] Feller and Stenberg first implicated a notochordal cleft caused by persistence of a midline cell rest as the cause of diastematomyelia.^[7]

Several authors have proposed theories to explain the genesis of SCM. Gardner had proposed the hydromyelic theory, advocating rupture of an intact neural tube by cerebrospinal fluid as the cause of spina bifida defects.^[8] Primary mesodermal abnormality theory was advocated by Lichtenstein.^[9] Hendrick insisted on the accessory neurenteric canal hypothesis.^[10]

Initially, diplomyleia and diastematomyelia were thought to two different entities. Diplomyleia was thought to be a true duplication of the spinal cord at certain segments and diastematomyelia was thought to be caused by the bony spur,

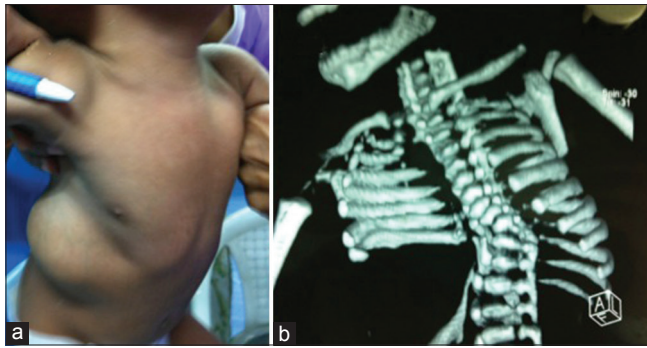


Figure 1: (a) Hernia over the lower part of right side of chest cavity, (b) Non-contrast computed tomography spine showing the absent lower ribs with D11 and D12 hemi vertebra with scoliosis

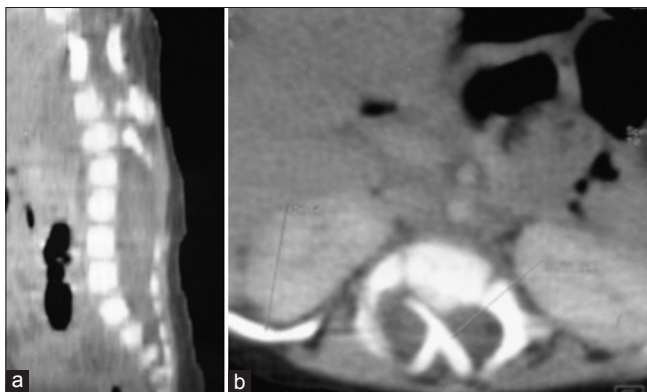


Figure 2: (a) Sagittal section of non-contrast computed tomography (CT) spine showing enlarged spinal canal, (b) Axial section of non-contrast CT spine showing a Y shaped dorsal spur attached to ventral surface of posterior arch

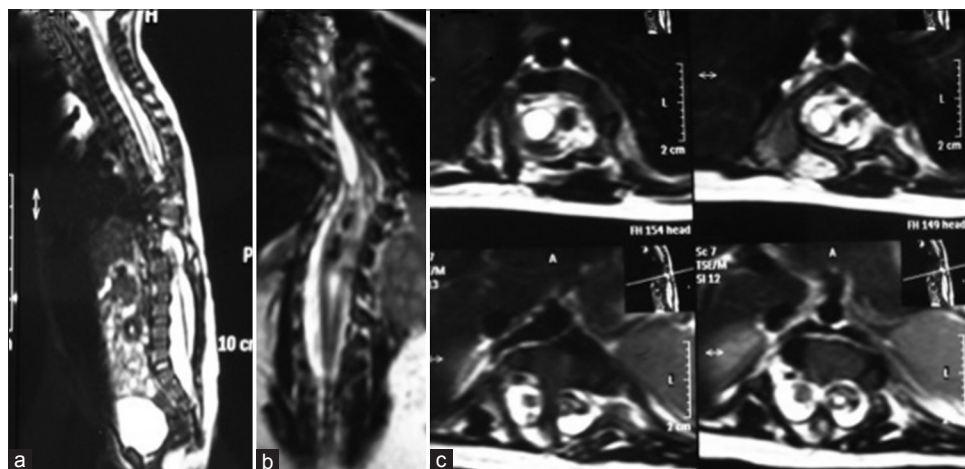


Figure 3: (a) Sagittal section of magnetic resonance imaging (MRI) showing the cord ending at L4, (b) Coronal section of MRI showing split at 3 levels, (c) Axial sections of MRI showing type 1 SCM with syrinx in both the hemicords

which suggested that it resulted from mesodermal invasion of the neural tube.^[11-13] This was effectively disproved by Pang *et al.* and Pang, who proposed a unified theory of embryogenesis and advocated a new classification recommending the term “SCM” for all double spinal cords.^[1,3] The unified theory proposes that all SCMs originate from one basic ontogenetic error occurring around the time when the primitive neurenteric canal closes. This basic error leads to the formation of an “accessory neurenteric canal” through the midline embryonic disc that maintains communication between yolk sac and amnion and enables continued contact between ectoderm and endoderm within the canal. Depending on the timing of the formation of the endomesenchymal tract and subsequent mesenchymal infiltration, the neural tube may split into two separate components with an intervening fibrocartilaginous or bony septum (diastematomyelia), or remain a single dural tube with a split cord by fibrous tissues (diplomylelia). This would also explain the presence of commonly associated spinal abnormalities such as dermal sinus tracts, spinal lipomas, dermoids, neurenteric cysts and even a meningocele or myelomeningocele as these abnormalities can arise from various ectodermal or endodermal remnants.

Pang *et al.* and Pang divided SCM into two classes.^[1,3] A type 1 SCM consists of two hemicords, each contained within its own dural tube and separated by a dura-sheathed rigid osseocartilaginous median septum. A type 2 SCM consists of two hemicords housed in a single dural tube separated by a non-rigid, fibrous median septum.

Mahapatra and Gupta in 2005, based on their intraoperative findings regarding the level of the spur and its relation to the split cord, proposed subclassification of the existing Pang’s split cord type 1 into 4 subtypes (a-d); 1a, a bone spur in the center with an equally duplicated cord above and below the spur; 1b, a bone spur at the superior pole of the split with no space above it and a large duplicated cord lower down; 1c, a bone spur of the lower pole with a large duplicated cord above; and 1d, a bone spur straddling the bifurcation with no space above or below the spur.^[4]

Various combinations of type 1 and type 2 SCM, and multiple type 1 SCM in the same patient have been reported in literature.^[14-16] However until date no single case is described with three different types of bony spur in a single patient. Our patient is unique in being having type 1a, 1b and 1c spurs in one split (D11-L3). Khandelwal *et al.* described a patient with SCM type 1a at D7-8 and SCM type 1c at L2-3, but these spurs were located at different locations, unlike our case where the spurs were adjacent to each other and at the same split.^[17]

Another unique feature of our case was the presence of a “Y” shaped dorsal spur, in which two limbs attached to the ventral surface of posterior arch. The presence of bony spurs seen in type 1 SCM are usually partial and unequivocally are found attached to the dorsal surface of the vertebral body.

Few cases of dorsal spur have been reported in literature.^[18,19] Chandra *et al.* tried to explain this unusual finding by two hypotheses: (1) Passage of an abnormal cell population dorsally and subsequently loss of contact with ventrally situated cell population; (2) migration of cells first around the hemicords and then passing between them in a dorsoventral direction. In both cases, the presence of a larger cell population close to the dorsal arch conveniently explains the hypertrophied dorsal arch and the bony spur attached to the former.

Right sided lower ribs were absent in our patient. Reported prevalence of rib abnormalities is 10.23% in a large series reported by the senior author.^[4] Hemivertebrae were seen in 5.9% of patients in the same series.

Conclusion

Even though SCM is rare, we have collected a large series. The present case is unique in many respects. Our patient had three types (Type 1a, 1b and 1c split) at three different levels. The lowest level septum was a posterior spur. There was syrinx in both the hemicords (right being large than left). There were many associated anomalies seen in our patient including D11 and D12 hemivertebra with absent right sided lower ribs.

Financial support and sponsorship

Nil.

Conflicts of interest

There are no conflicts of interest.

References

1. Pang D, Dias MS, Ahab-Barmada M. Split cord malformation: Part I: A unified theory of embryogenesis for double spinal cord malformations. *Neurosurgery* 1992;31:451-80.
2. Pang D. Split cord malformations. In: Pang D, editor. *Disorders of the Pediatric Spine*. New York: Raven Press; 1995. p. 203-52.
3. Pang D. Split cord malformation: Part II: Clinical syndrome. *Neurosurgery* 1992;31:481-500.
4. Mahapatra AK, Gupta DK. Split cord malformations: A clinical study of 254 patients and a proposal for a new clinical-imaging classification. *J Neurosurg* 2005;103:531-6.
5. Ollivier C. *Traité des Maladies de la Moelle Épineière*. Paris: Mequignon-Marvis; 1837.
6. Bruce A, M'Donald S, Pirie JH. A second case of partial doubling of the spinal cord. *Rev Neurol Psychiatry* 1906;4:6-19.
7. Feller A, Stenberg H. Zur Kenntnis der Fehlbildungen der Wirbelsäule. I. Die Wirbelkörperspalte und ihre formale Genese. *Virchows Arch [A]* 1929;272:613-40.
8. Gardner WJ. Myelocoele: Rupture of the neural tube? *Clin Neurosurg* 1968;15:57-79.
9. Lichtenstein BW. “Spinal dysraphism”— Spina bifida and myelodysplasia. *Arch Neurol Psychiatry* 1929;44:792-810.
10. Hendrick EB. On diastematomyelia. *Prog Neurol Surg* 1971;4:277-88.
11. Cohen J, Sledge CB. Diastematomyelia. An embryological interpretation with report of a case. *Am J Dis Child* 1960;100:257-63.
12. Müller F, O’Rahilly R. The development of the human brain, the closure of the caudal neuropore, and the beginning of secondary neurulation at stage 12. *Anat Embryol (Berl)* 1987;176:413-30.
13. Beardmore HE, Wiglesworth FW. Vertebral anomalies and alimentary duplications; clinical and embryological aspects. *Pediatr Clin North Am* 1958;5:457-74.

14. Izci Y, Gurkanlar D, Gönül E. An unusual type of split cord malformation. *J Clin Neurosci* 2007;14:383-6.
15. Akay KM, Erşahin Y, Cakir Y. Tethered cord syndrome in adults. *Acta Neurochir (Wien)* 2000;142:1111-5.
16. Ailawadhi P, Mahapatra AK. An unusual case of spinal dysraphism with four splits including three posterior spurs. *Pediatr Neurosurg* 2011;47:372-5.
17. Khandelwal A, Tandon V, Mahapatra AK. An unusual case of 4 level spinal dysraphism: Multiple composite type 1 and type 2 split cord malformation, dorsal myelocystocele and hydrocephalous. *J Pediatr Neurosci* 2011;6:58-61.
18. Chandra PS, Kamal R, Mahapatra AK. An unusual case of dorsally situated bony spur in a lumbar split cord malformation. *Pediatr Neurosurg* 1999;31:49-52.
19. Akay KM, Izci Y, Baysefer A. Dorsal bony septum: A split cord malformation variant. *Pediatr Neurosurg* 2002;36:225-8.