

## Report of a Case and Review of Literature of Internal Hernia through Peritoneal Defect in Pouch of Douglas: A Rare Occurrence

### Abstract

Intestinal obstruction attributable to internal hernia as a cause is a rare phenomenon with a reported incidence of 0.6%–5.8%. Internal hernias ensuing as a result of defect in the pouch of Douglas is extremely rare with only six such cases reported so far in the literature. We present a case of 74-year-old posthysterectomy status female who presented with features of intestinal obstruction. Intraoperatively, the site of obstruction was found to be a rent in the peritoneum of the pouch of Douglas through which a loop of ileum was found herniating. The viability of the bowel was confirmed, and the defect was closed. The postoperative course was uneventful. This report presents an extremely rare type of internal hernia caused by defect in the pouch of Douglas and review of the literature so far available.

**Keywords:** Internal hernia, intestinal obstruction, peritoneal defect, pouch of Douglas

**Vamseedharan Muthukumar, Sarveswaran Venugopal, Sures Kumar Subramaniam**

Department of General Surgery,  
Sri Ramakrishna Hospital,  
Coimbatore, Tamil Nadu, India

### Introduction

Internal hernia is a rare entity wherein herniation of the viscus occurs through large fovea, fossa or defects in mesentery and peritoneum but remain within the cavity and merely a fraction of such hernias lead to intestinal obstruction.<sup>[1]</sup> Very infrequently, they are diagnosed preoperatively due to nonspecific symptoms, signs, imaging findings, and lack of suspicion. Internal hernias ensuing as a result of the defect in the pouch of Douglas is extremely sporadic. A rummage into the available literature revealed only six such cases reported so far. We describe here a case of internal hernia through a rent in the pouch of Douglas presenting with intestinal obstruction.

### Case Report

A 74-year-old female patient presented to our emergency department with the complaints of abdominal distension and persistent vomiting which started about 10 h ago. The symptoms had progressively worsened since the onset. She had undergone a hysterectomy 12 years back. She had similar complaints a year ago for which she was managed conservatively and was asymptomatic later. On examination, the patient was dehydrated and vitals were stable; abdomen was distended and

diffusely tender with increased bowel sounds. Blood tests revealed leukocytosis (15,600 cells/cumm) with neutrophilia (9360 cells/cumm), hemoglobin of 9 g/dl, hematocrit of 27% and deranged renal parameters (urea - 60 mg/dl, creatinine - 2.2 mg/dl). Abdominal radiography revealed dilated small bowel loops with air-fluid levels suggestive of small bowel obstruction [Figure 1a]. The patient was started on the conservative line of management with intravenous fluids and nasogastric decompression. After 12 h of conservative management, the patient showed no improvement and repeated abdominal radiograph showed worsening of the intestinal obstruction [Figure 1b]. Hence, exploratory laparotomy through a midline vertical incision was performed which showed herniation of a loop of ileum about 75 cm oral to ileocecal junction through a 2.5 cm × 3 cm sized rent in the pouch of Douglas with proximal dilated and distal collapsed small bowel [Figure 2]. Perineal musculature was intact with no evidence of weakness. After reducing the bowel loop and confirming the viability, the rent was closed and surgery completed [Figure 3]. Postoperatively, she demonstrated satisfactory recovery and was discharged on the 10<sup>th</sup> postoperative day with normal renal parameters. The Patient is doing well on follow-up visits after 3 months.

Received: 24 July, 2016.  
Accepted: 07 May, 2017.

**Address for correspondence:**  
Dr. Vamseedharan Muthukumar,  
Department of General  
Surgery, Sri Ramakrishna  
Hospital, 395, Sarojini  
Naidu Road, Sidhapudur,  
Coimbatore - 641 044,  
Tamil Nadu, India.  
E-mail: drvamseedharan@  
gmail.com

#### Access this article online

**Website:**  
www.ijabmr.org

**DOI:**  
10.4103/ijabmr.IJABMR\_297\_16

#### Quick Response Code:



**How to cite this article:** Muthukumar V, Venugopal S, Subramaniam SK. Report of a case and review of literature of internal hernia through peritoneal defect in pouch of douglas: A rare occurrence. Int J App Basic Med Res 2017;7:196-8.

This is an open access article distributed under the terms of the Creative Commons Attribution-NonCommercial-ShareAlike 3.0 License, which allows others to remix, tweak, and build upon the work non-commercially, as long as the author is credited and the new creations are licensed under the identical terms.

For reprints contact: reprints@medknow.com

**Discussion**

Intestinal obstruction attributable to internal hernia as a cause is a rare phenomenon with a reported incidence of 0.6%–5.8%.<sup>[2]</sup> Paraduodenal hernias accounts for about 53% of all internal hernias.<sup>[3]</sup> Other sites for internal hernia include defects in parts of the greater omentum, mesentery of the small intestine, foramen of Winslow, mesentery of the colon, pericecal region or retroanastomotic region. The incidence of internal hernia occurring in the pelvis is approximately 7% and is anatomically classified into the obturator, the sciatic and the perineal hernias based on the location of the defects.<sup>[3]</sup> The perineal hernia is herniation of the viscus through the pelvic diaphragm into the perineum due to the frailty of the musculature. These may occur primarily due to congenital defects or secondary to extensive pelvic surgery. The perineal hernia encompasses ischiorectal hernias, subpubic hernias, pudendal hernias, vaginal hernias, posterior labial hernias, and hernias of the pouch of Douglas.<sup>[4]</sup> Our case contrasts from the hernia of the pouch of Douglas in the fact that it was associated only with a rent in the peritoneum of the pouch of Douglas and there was

no weakness of the pelvic diaphragm [Figure 4]. A search for analogous cases in the literature revealed only six such cases, making this an exceedingly scarce occurrence.<sup>[1,2,5-8]</sup>

The minutiae of six case reports are prepared in Table 1. The hypothesized causes of pelvic hernia are congenital abnormalities and trauma resulting from pelvic surgery, pregnancy, or delivery.<sup>[9,10]</sup> All these cases were described in females and age of presentation and history of pregnancy varied in the reported cases. In the described cases, the basis of the hernia was assumed to be hysterectomy in three cases,<sup>[2,7,8]</sup> congenital in two cases<sup>[1,5]</sup> and in one case cause was undetermined.<sup>[6]</sup> As our patient had a hysterectomy 12 years earlier, the plausible cause of hernia would be hysterectomy.

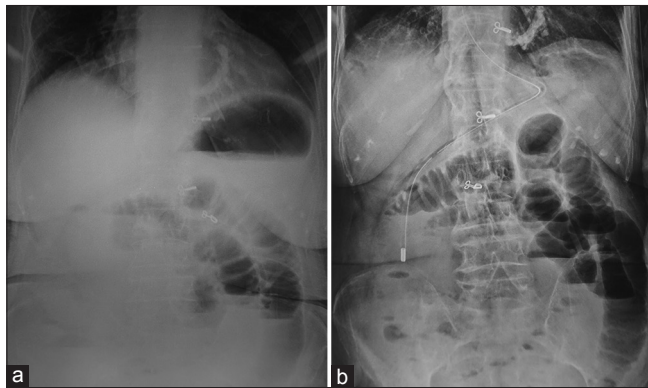


Figure 1: Abdominal radiography: (a) On admission showing dilated small bowel loops with air fluid levels suggestive of small bowel obstruction. (b) Twelve hours later showing increased and prominent air-fluid levels indicating worsening of the small bowel obstruction

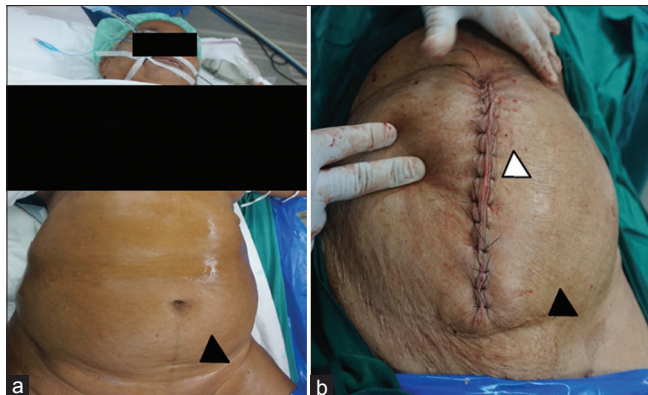


Figure 3: Patient photographs: (a) Preoperative abdomen photograph showing the hysterectomy pfannenstiell (black arrow head). (b) Post-operative abdomen photograph showing the old hysterectomy pfannenstiell scar (black arrow head) and current lower midline laparotomy wound (solid white arrow)

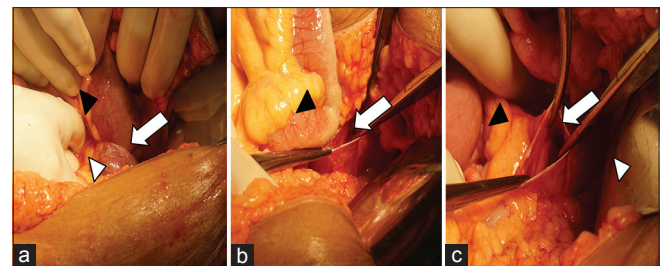


Figure 2: Intraoperative photographs: (a) The point of transition (solid white arrow) of the proximal dilated (black arrow head) and distal collapsed (white arrow head) small bowel loops (b) The loop of bowel (black arrow head) that had herniated through the rent (solid white arrow) in the peritoneum of the pouch of Douglas (c) The rent (solid white arrow) in the peritoneum of the pouch of Douglas, rectum (black arrow head) and bladder (white arrow head) retracted by the instrument

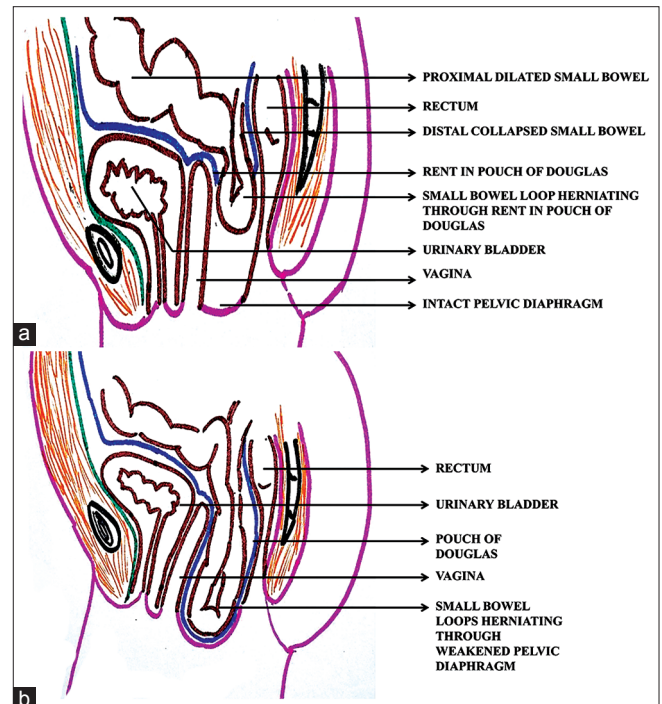


Figure 4: Artistic line diagram: (a) Our case-internal hernia through a rent in the pouch of Douglas presenting with intestinal obstruction (b) Hernia of the pouch of Douglas – Perineal hernia

**Table 1: The minutiae of reports of internal hernia occurring through a peritoneal defect of the pouch of Douglas**

Author (year)	Age	History of pelvic surgery	Probable cause of hernia	Operational approach
Fiirgaard and Agertoft (1988) <sup>[5]</sup>	17	None	Congenital	Open primary closure
Inoue <i>et al.</i> (2002) <sup>[2]</sup>	80	Hysterectomy	Previous hysterectomy	Open primary closure
Bunni <i>et al.</i> (2012) <sup>[6]</sup>	77	None	Undetermined	Lap prosthetic repair
Yang <i>et al.</i> (2012) <sup>[7]</sup>	60	Hysterectomy	Previous hysterectomy	Not mentioned
Suwa <i>et al.</i> (2013) <sup>[1]</sup>	28	None	Congenital	Open primary closure
Apturkar <i>et al.</i> (2013) <sup>[8]</sup>	50	Hysterectomy	Previous hysterectomy	Open primary closure
Our case	74	Hysterectomy	Previous hysterectomy	Open primary closure

As far as investigations are concerned for the diagnosis of this uncommon entity, most of them are nonspecific. Abdominal radiography would show air-fluid levels, suggesting intestinal obstruction and in cases of perforation following gangrene of the involved bowel, free air may be noted. Ultrasonography may show features of dilated bowel loops with to and fro peristalsis indicating an intestinal obstruction. However, hypothetically trans-vaginal or rectal ultrasonography would reveal the abnormally low-lying bowel loops and in experienced hands may also disclose the defect in the peritoneum of the pouch of Douglas, though there is no clinical evidence to support this statement. There have been retrospective reports that, computed tomography findings might show the presence of this rare type of hernia. One such finding was, cluster of loops of small bowel seen between the uterine cervix and the rectum protruding through a peritoneal defect.<sup>[2]</sup> Without a high index of suspicion about the diagnosis, this hernia would be impossible to diagnose even in experienced hands due to its rarity. Almost always the diagnosis would be intraoperative rather than preoperative; during the laparotomy or laparoscopy for intestinal obstruction the rent and the internal hernia are diagnosed as it was in the majority of the cases reported so far.

As far as treatment for this hernia is concerned a primary closure of the rent is often sufficient and mesh repair is often not required, as the cause for this hernia is the rent in the peritoneum rather than the weakness of musculofascial tissues. The approach to the surgery may be open or laparoscopic, and there is very little data to favor either. As in other types of hernia one should be ready to face a strangulated or a gangrenous loop of bowel in this type of hernia as well.

## Conclusion

This report presents an extremely rare type of internal hernia caused by a defect in the pouch of Douglas and

review of the literature so far available. Furthermore, to gain better insight into this unusual entity all diagnosed cases however trivial should be published.

## Financial support and sponsorship

Nil.

## Conflicts of interest

There are no conflicts of interest.

## References

1. Suwa K, Yamagata T, Hanyu K, Suzuki T, Okamoto T, Yanaga K. Internal hernia through a peritoneal defect in the pouch of Douglas: Report of a case. *Int J Surg Case Rep* 2013;4:115-7.
2. Inoue Y, Shibata T, Ishida T. CT of internal hernia through a peritoneal defect of the pouch of Douglas. *AJR Am J Roentgenol* 2002;179:1305-6.
3. Ghahremani GG. Internal abdominal hernias. *Surg Clin North Am* 1984;64:393-406.
4. Carter JE. Sciatic, obturator, and perineal hernias: A view from the gynecologist. In: Fitzgibbons RJ, editor. *Nyhus & Condon's Hernia*. 5<sup>th</sup> ed. Philadelphia: Lippincott Williams & Wilkins; 2002. p. 539-49.
5. Fiirgaard B, Agertoft A. Internal Richter's hernia due to congenital peritoneal defect. Case report. *Acta Chir Scand* 1988;154:537.
6. Bunni J, Teichmann D, Berstock JR. Pouch of Douglas pelvic hernia: A rare entity managed laparoscopically. *Hernia* 2012;16:601-3.
7. Yang D, Cho SH, Shin HW, Kim TE, Kim BY, Kim HJ. Internal hernia through the pouch of Douglas after hysterectomy: A case report. *J Korean Soc Radiol* 2012;66:469-72.
8. Apturkar DK, Dandekar KB, Jorwekar GJ, Baviskar PK, Bhargale KD. A rare case of internal hernia through a rent in pouch of Douglas, six years after abdominal hysterectomy. *Int J Biomed Adv Res* 2013;4:258-60.
9. Barbier Brion B, Daragon C, Idelcadi O, Manton G, Kastler B, Delabrousse E. Small bowel obstruction due to broad ligament hernia: Computed tomography findings. *Hernia* 2011;15:353-5.
10. Langan RC, Holzman K, Coblenz M. Strangulated hernia through a defect in the broad ligament: A sheep in wolf's clothing. *Hernia* 2012;16:481-3.