

Multifocal *Rhizopus microsporus* lung infection following brush clearing



Artsiom V. Tsyrukunou^{a,*}, Richard T. Ellison III^{b,1}, Ali Akalin^{c,2}, Nathan Wiederhold^{d,3},
Deanna A. Sutton^{d,4}, Jonathan Lindner^{d,5}, Hongxin Fan^{d,6}, Stuart M. Levitz^{e,7}, Iva Zivna^{b,8}

^a Infectious Disease and Immunology Department, University of Massachusetts Medical School, 55 Lake Avenue North, Worcester, MA 01655, USA

^b UMass Memorial Medical Center – Memorial Campus, 119 Belmont Street, Worcester, MA 01605, USA

^c Department of Pathology, University of Massachusetts Medical School, 55 Lake Avenue North, Worcester, MA 01655, USA

^d Fungus Testing Laboratory, University of Texas Health Science Center at San Antonio, 7703 Floyd Curl Drive, San Antonio, TX 78229, USA

^e University of Massachusetts Medical School, 364 Plantation Street, LRB 317, Worcester, MA 01605, USA

ARTICLE INFO

Article history:

Received 23 July 2014

Received in revised form

1 August 2014

Accepted 3 August 2014

Keywords:

Rhizopus microsporus

Molecular diagnostics

Multifocal pneumonia

Environmental exposure

ABSTRACT

We report a case of pulmonary *Rhizopus microsporus* infection in a patient with untreated diabetes following brush clearing. The patient was successfully treated with a combined medical and surgical approach with complete resolution of the lung lesions and remains asymptomatic at 11-month follow-up.

© 2014 International Society for Human and Animal Mycology. International Society for Human and Animal Mycology Published by Elsevier B.V. This is an open access article under the CC BY-NC-ND license

(<http://creativecommons.org/licenses/by-nc-nd/3.0/>).

1. Introduction

Pulmonary *Rhizopus* infection has only rarely been described in immunocompetent hosts [1,2]. The major risk factor is neutropenia in the setting of hematological malignancy. Less common risk factors include immunosuppression to prevent transplant rejection and uncontrolled diabetes [1,3]. In a large epidemiological study of patients with mucormycosis infection, the predominant clinical manifestation in diabetics was involvement of orbits and sinuses in 66% [1]. Pulmonary infection with mucormycosis was reported in 16% of patients, with most cases seen in patients with lung cancer [1]. Herein we report a very rare case of invasive pulmonary *Rhizopus*

microsporus infection in a patient without evidence of immunodeficiency, except untreated diabetes and a short course of steroids for chronic obstructive pulmonary disease exacerbation. This case of multifocal pneumonia due to *R. microsporus* infection was likely linked to environmental exposure during brush clearing of dead leaves, glass, and branches of the fallen trees. Our case report emphasizes the importance of considering fungal infections in patients with very common diseases, such as chronic obstructive pulmonary disease and poorly controlled diabetes mellitus in the setting of environmental exposure to organic matter.

2. Case

A 61-year-old man presenting to the hospital (day 0) with progressive shortness of breath and a productive cough for 3 weeks was found to have multiple new bilateral nodular and cavitary lesions in his lungs. On day –18 he had been seen at a local Emergency Department with a history of several days of cough, and at that time had had a chest X-ray, showed only hyperinflation. He was diagnosed with a chronic obstructive pulmonary disease (COPD) exacerbation and received intravenous corticosteroids, followed by an oral taper. Azithromycin dose pack was prescribed for 5 days and the patient was sent home. Despite a course of steroids and azithromycin, he experienced worsening of his cough and noted moderate amounts of yellow phlegm along

* Corresponding author. Tel.: +1 508 856 3158; fax: +1 508 856 5981.

E-mail addresses: artsiom.tsyrukunou@umassmemorial.org (A.V. Tsyrukunou), richard.ellison@umassmemorial.org (R.T. Ellison III), ali.akalin@umassmemorial.org (A. Akalin), wiederholdn@uthscsa.edu (N. Wiederhold), suttonond@uthscsa.edu (D.A. Sutton), lindnerj@uthscsa.edu (J. Lindner), fanh@uthscsa.edu (H. Fan), stuart.levitz@umassmed.edu (S.M. Levitz), iva.zivna@umassmemorial.org (I. Zivna).

¹ Tel.: +1 508 856 3158; fax: +1 508 856 5981.

² Tel.: +1 508 793 6152.

³ Tel.: +1 210 567 4086.

⁴ Tel.: +1 210 567 4032.

⁵ Tel.: +1 210 567 4102.

⁶ Tel.: +1 210 567 4151.

⁷ Tel.: +1 508 856 1525.

⁸ Tel.: +1 508 334 6053; fax: +1 508 334 6412.

with progressive worsening of shortness of breath. He also reported a new onset of left-sided pleuritic chest pain.

His past medical history was significant for a 40 pack-year history of smoking, untreated diabetes mellitus type II, and occasional alcohol use. The patient was born in the United States and denied international travel. He lived with his wife in a rural area in the Central Massachusetts and spent much of his spare time clearing trees from multiple acres of wooded land that he owned.

On examination, he had mildly elevated temperature of 37.7 °C; otherwise, he had stable vital signs with an oxygen saturation of 94% on room air. There was no tenderness over his sinuses; no conjunctivitis or tenderness of the abdomen. Examination of mucosa in the mouth and nasopharynx did not show purulent discharge, erythema, or necrotic changes. Auscultation of the lungs was significant for bilateral crackles. Laboratory studies showed a total white count of 13,200 per mm³ with 78% neutrophils. His blood glucose level was elevated to 257 mg/dL and the bicarbonate level was 28 mmol/L. On hospital day +1 a chest computed tomography (CT) scan showed multifocal pneumonia with central cavitation (Fig. 1). There was a trace left pleural effusion. Borderline enlarged bilateral hilar, lower paratracheal, subcarinal, and periaortic lymph nodes were present.

He was started on treatment with intravenous vancomycin and piperacillin-tazobactam. His sputum cultures showed normal respiratory flora and blood cultures performed prior to antibiotics remained negative after 5 days of incubation. Results of human immunodeficiency virus antibodies, anti-neutrophil antibodies, serum *Aspergillus* galactomannan and serum beta-D-glucan tests were negative. On hospital day +4 the patient underwent bronchoscopy which showed minimal secretions and no endobronchial lesions. Rare fungal hyphae were seen on microscopy of bronchoalveolar lavage specimens. Empiric liposomal amphotericin B at a dose of 5 mg/kg per day was initiated on day +8. A fine needle aspiration of the lung lesion adjacent to the chest wall was performed and subsequently on hospital day +15 the patient underwent open thoracotomy with left upper lobe resection. It was not possible to resect all the cavitary lesions due to the wide distribution of the lesions throughout both lungs.

All microbiological samples from induced sputum, bronchoalveolar lavage and lung tissue grew a *Rhizopus* sp. Further characterization of the fungus was performed by the Fungus Testing Laboratory at the University of Texas Health Science Center at San

Antonio. Macroscopic and microscopic features were noted on a potato flakes agar (PFA) plate and a water agar plate, respectively, incubated at 25 °C for 7 days. Colonies were Light Gull Gray to Gull Gray to Mouse Gray centrally [4] and woolly with a short nap (Fig. 2A). Some subcultures, however, demonstrated somewhat taller growth. Microscopic features included ramified nodal rhizoids, short (less than 500 µm) pale to medium brown sporangiophores, pyriform to ellipsoidal-shaped columella (Fig. 2B and C), and pale brown, subglobose to slightly angular sporangiospores (approximately 4 µm in diameter), lacking noticeable striations (Fig. 2D). Numerous intercalary chlamydospores were also present. Luxurious growth was noted at 37 °C, 40 °C, and 45 °C; reduced growth occurred at 50 °C.

Molecular identification was consistent with *Rhizopus microsporus* in clinical samples. Template DNA was prepared by subculturing the isolate onto PFA and incubating at 30 °C. Hyphal elements were scraped from the agar surface and suspended in CPL-100 Buffer (VWR International INC, Radnor, PA). The specimen was then lysed by bead beating, and DNA was isolated manually by the chloroform extraction method. Extracted DNA was used for PCR amplification of ITS and D1/D2 regions as described with slight modification [5]. PCR products were then sequenced using the ITS1 and ITS4 primers as well as NL1 and NL4 primers at the UTHSCSA Molecular Diagnostics Laboratory [6]. Sequences were assembled and analyzed using DNASTAR software (DNASTAR, Inc., Madison, WI) and queried in GenBank using the BLASTn algorithm at the NCBI site (www.ncbi.nlm.nih.gov). Sequences were also compared to those available in the CBS-KNAW Fungal Biodiversity Centre database (www.cbs.knaw.nl). The ITS sequence demonstrated 100% identity to *R. microsporus* (GenBank Accession No. JN561253.1; base pair match 696/696), and the D1/D2 sequence also showed 100% identity to *R. microsporus* (CBS Accession No. 343.29; base pair match 699/699). The ITS and D1/D2 nucleotide sequences of the isolate were deposited into GenBank under accession numbers KM103772 and KM103773, respectively. The isolate (UTHSCSA DI 14-206) has been deposited into the University of Alberta Microfungus Collection and Herbarium under UAMH accession number 11833.

Pathological examination of the resected left upper lung lobe revealed a lung abscess with an internal surface showing necrosis, abundant mixed inflammatory cells, nuclear debris and the presence of broad, empty-looking fungal hyphae consistent with *Rhizopus* (Fig. 3). The wall of the abscess cavity and surrounding

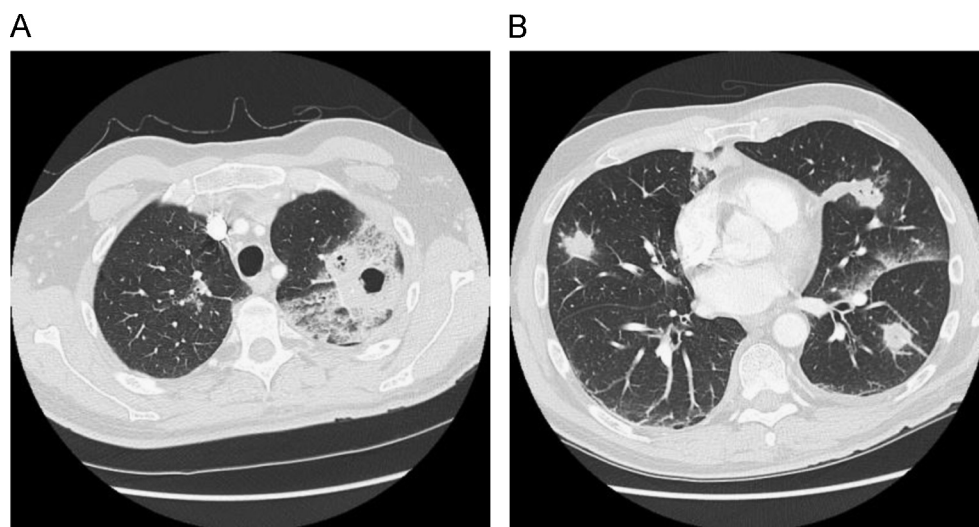


Fig. 1. A. CT scan (with intravenous contrast) image of upper lobes of the lungs demonstrating an extensive area of consolidation of the apical-posterior segment of the left upper lobe with a large area of central cavitation. B. CT scan image of the lower lobes of the lungs showing numerous smaller foci of consolidation throughout the lungs bilaterally (18 nodular lesions in both lungs), some with central necrosis and some with central cavitation.

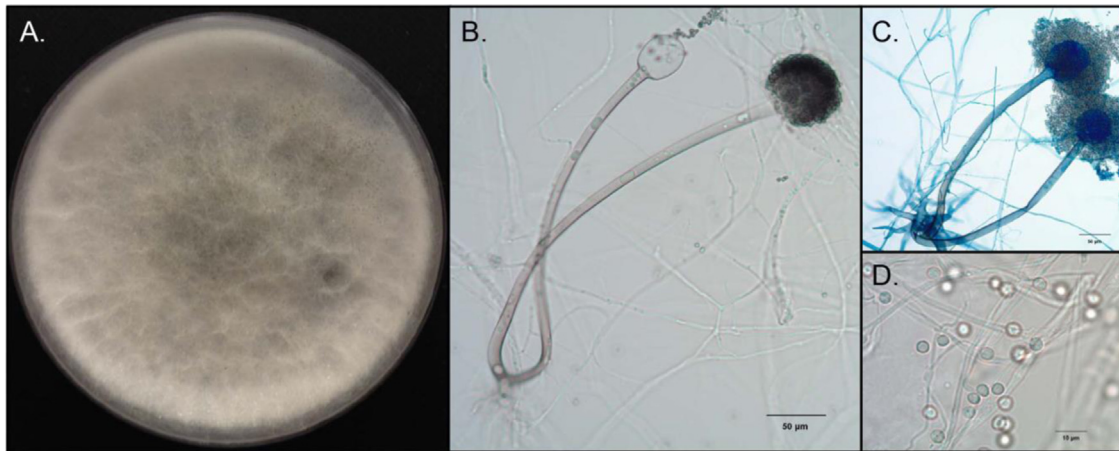


Fig. 2. A. Potato flakes agar plate (60 mm) after 7 days incubation at 25 °C, demonstrating a gray, woolly colony with a flat nap; B. Two short, pale brown sporangiophores arising from nodal rhizoids; one sporangium is intact containing sporangiospores, while the other demonstrates a pyriform ellipsoid-shaped columella; C. Nodal rhizoids, short, brown sporangiophores and sporangia; D. Subglobose and slightly angular sporangiospores lacking noticeable striations. Mounting medium 85% lactic acid, B and D; lactophenol cotton blue, C. (For interpretation of the references to color in this figure legend, the reader is referred to the web version of this article.)

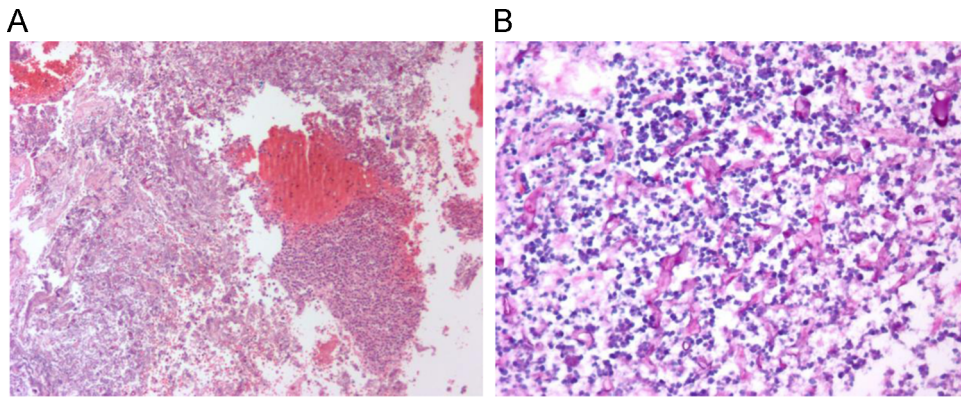


Fig. 3. A. Left lung upper lobe abscess cavity with necrotic lung tissue, abundant mixed acute and chronic inflammatory cells and nuclear debris (H&E stain, 100 ×). B. Periodic acid Schiff (PAS) stain demonstrated numerous wide, ribbon-like, thin-walled hyphae with folding and twisting. The hyphae revealed irregular branching and rare septation (pauciseptate). There were abundant admixed neutrophils and nuclear debris (PAS fungal stain, 400 ×).

lung parenchyma also revealed some granulomas as well as evidence of organizing pneumonia with features of acute fibrinous and organizing pneumonia (AFOP). No vasculitis was seen. Additional screening studies for disseminated fungal infection were negative for lesions in the brain and sinuses.

Antifungal susceptibility testing was performed at ARUP Laboratories, Salt Lake City, Utah, according to the CLSI M38-A2 methods [7]. The minimal inhibitory concentrations (MIC) were 2 µg/mL for amphotericin, 2 µg/mL for itraconazole, and 1 µg/mL for posaconazole.

After recovery from the lung surgery on hospital day +22, the patient was started on posaconazole oral suspension, 200 mg four times a day. After 1 week of treatment with posaconazole, serum concentrations were 1.4 µg/mL. Subsequent levels were 1.6 µg/mL and 2.1 µg/mL. Liposomal amphotericin B was stopped on day +30 and patient was discharged home on day +32 on posaconazole treatment. He was also begun on anti-diabetic medications with diet modification and tight glucose control. After 8 weeks of therapy, a repeat CT scan of the chest showed marked improvement in the size and number of lung opacities. Posaconazole therapy was stopped after finishing a 12-week course. His hemoglobin A1c decreased from 14.7% on his initial presentation to 7.3% at the end of therapy. Subsequent chest X-ray performed 4 weeks after he finished posaconazole showed complete resolution of the infiltrates in the lungs. The patient remains asymptomatic at 11-month follow-up.

3. Discussion

Members of the Order *Mucorales* are ubiquitous in the environment and can be found on decaying organic material and soil [8]. They are characterized by broad irregularly-branched hyphae with rare septations [9,10]. Members of the *R. microsporus* group were previously separated into several varieties based upon different morphologic characteristics, and included *R. microsporus* var. *microsporus*, *R. microsporus* var. *rhizopodiformis*, *R. microsporus* var. *chinensis*, *R. microsporus* var. *azygosporus*, *R. microsporus* var. *oligosporus*, and *R. microsporus* var. *tuberosus* [11]. However, a recent study that evaluated 48 isolates of different varieties demonstrated that despite variable phenotypic features the isolates were identical by sequence analysis and therefore should be reported under the name *R. microsporus* without assignment of a varietal status [12].

It has been shown that airborne spores of *Rhizopus microsporus* are frequently found in filter samples of wood trimmers [13]. There was also a correlation found between the level of exposure to mold spores and the level of specific immunoglobulin G to *R. microsporus* and *Paecilomyces variotii* in newly employed wood trimmers and those who had already worked in the trimming department [13]. No cases of infection due to *R. microsporus* were reported in that study. However, in another study from Norway, the mean level of specific immunoglobulin G antibodies to *R. microsporus* in sawmill workers was the best predictor of

respiratory symptoms, such as mucous membrane irritation, chronic nonspecific lung disease, allergic alveolitis, and organic dust toxic syndrome. This suggests that exposure to spores from *Rhizopus microsporus* may cause several types of respiratory symptoms in wood trimmers [14].

The clinical picture of pulmonary *Rhizopus* infection is non-specific. Patients frequently have fever, cough, shortness of breath, weight loss, and hemoptysis, which may suggest the presence of invasive fungal infection [2]. Chest radiographs show involvement of the upper part of the chest in nearly half of the patients [2]. The multiple lesions in both lungs noted in our patient could have been a result of the inhalation of a large number of spores as he was engaged in tree work although a contribution from endobronchial spread should also be considered.

Diagnostic evaluation for *Rhizopus* infection frequently requires an invasive procedure to obtain tissue samples. Treatment of pulmonary *Rhizopus* infection is complex and often managed by multiple specialists. It is important to consider surgical debridement or resection early in the disease course as the outcome in patients treated with a combined medical and surgical approach tends to be better [1,15]. Medical management includes an induction phase until clinical and radiographic response and subsequent consolidation therapy until the resolution of the symptoms and clearance of radiographic changes [16]. Most authors recommend continuing therapy until clinical resolution of signs and symptoms of infection and improvement in imaging studies as was done in our patient [16,17].

Conflict of interest statement

There is none.

Acknowledgments

We thank the patient for allowing his case to be reported.

References

- [1] Roden MM, Zaoutis TE, Buchanan WL, Knudsen TA, Sarkisova TA. Epidemiology and outcome of zygomycosis: a review of 929 reported cases. *Clin Infect Dis* 2005;41:634–53.
- [2] Lee FY, Mossad SB, Adal KA. Pulmonary mucormycosis. *Arch Intern Med* 1999;159:1301–9.
- [3] Chakrabarti A, Marak RS, Shivaprakash MR, Gupta S, Garg R, Sakhuja V, et al. Cavitary pulmonary zygomycosis caused by *Rhizopus homothallicus*. *J Clin Microbiol* 2010;48(5):1965–9.
- [4] Ridgeway R. Color standards and color nomenclature. Baltimore, MD: A. Hoen and Company; 1912.
- [5] Romanelli AM, Sutton DA, Thompson EH, Rinaldi MG, Wickes BL. Sequence-based identification of filamentous basidiomycetous fungi from clinical specimens: a cautionary note. *J Clin Microbiol* 2010;48:741–52.
- [6] White TJ, Bruns TD, Lee SB, Taylor JW. Amplification and direct sequencing of fungal ribosomal RNA genes for phylogenetics. In: Innis MA, Gelfand DH, Sninsky JJ, White TJ, editors. PCR protocols: a guide to methods and applications. New York: Academic Press, Inc.; 1990. p. 315–22.
- [7] CLSI. Reference method for broth dilution antifungal susceptibility testing of filamentous fungi: approved standard. (Document M38-A2). 2nd ed. Wayne, Pennsylvania: Clinical and Laboratory Standards Institute; 2008.
- [8] Petrikos G, Skiada A, Lortholary O, Roilides E, Walsh TJ, Kontoyiannis DP. Epidemiology and clinical manifestations of mucormycosis. *Clin Infect Dis* 2012;54(S1):S23–34.
- [9] Chandler F, Kaplan W, Awjello L. A color atlas and textbook of the histopathology of mycotic diseases. London: Wolfe Medical Publishing, Ltd; 1980.
- [10] Chayakulkeeree M, Ghannoum MA, Perfect JR. Zygomycosis: the re-emerging fungal infection. *Eur J Clin Microbiol Infect Dis* 2006;25:215–29.
- [11] Walther G, Pawlowska J, Alastruey-Izquierdo A, Wrzosek M, Rodriguez-Tudela JL, Dolatabadi S, et al. DNA barcoding in *Mucorales*: an inventory of biodiversity. *Persoonia* 2013;30:11–47.
- [12] Dolatabadi S, Walther G, van den Ende AH, deHoog GS. Diversity and delimitation of *Rhizopus microsporus*. *Fungal Divers* 2014;64:145–63.
- [13] Eduard W, Sandven P, Levy F. Relationships between exposure to spores from *Rhizopus microsporus* and *Paecilomyces variotii* and serum IgG antibodies in wood trimmers. *Int Arch Allergy Immunol* 1992;97(4):274–82.
- [14] Eduard W, Sandven P, Levy F. Serum IgG antibodies to mold spores in two Norwegian sawmill populations: relationship to respiratory and other work-related symptoms. *Am J Ind Med* 1993;24(2):207–22.
- [15] Tedder M, Spratt JA, Anstadt MP, Hegde SS, Tedder DS, Lowe JE. Pulmonary mucormycosis: results of medical and surgical therapy. *Ann Thor Surg* 1994;57:204–11.
- [16] Kontoyiannis D, Lewis RE. How I treat mucormycosis. *Blood* 2011;118:1216–24.
- [17] Chamilos G, Macapinlac HA, Kontoyiannis DP. The use of 18F-fluorodeoxyglucose positron emission tomography for the diagnosis and management of invasive mould infections. *Med Mycol* 2008;46(1):23–9.