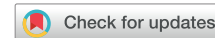

# Successful transseptal puncture and cryoballoon ablation of symptomatic paroxysmal atrial fibrillation via jugular access in a patient with bilateral thrombotic femoral vein occlusion



Thomas Kox, MD,\* Florin Laubenthal, MD, PhD,\* Guram Imnadze, MD<sup>†</sup>

From the \*Department of Cardiology, Evangelic Hospital Oberhausen, Oberhausen, Germany, and

<sup>†</sup>Department of Arrhythmia Management, Klinikum Osnabrueck, Osnabrueck, Germany.

## Introduction

Pulmonary vein isolation (PVI) is the cornerstone of interventional treatment for atrial fibrillation. Radiofrequency (RF) ablation using 3-dimensional navigation systems, as well as cryoballoon ablation, are the recommended ablation techniques under the current guidelines.<sup>1</sup> Cryoballoon ablation has become the preferred technique in many institutions as the first-line ablation approach because it leads to significantly fewer repeat ablations, direct-current cardioversions, all-cause rehospitalizations, and cardiovascular rehospitalizations during follow-up.<sup>2</sup> PVI is usually performed via common femoral vein access. However, there are a few situations where the inferior approach is not feasible—for example, the interruption of the inferior vena cava (IVC) with continuation of the azygos vein draining the blood from the IVC to the upper part of the right atrium via the superior vena cava.<sup>3</sup>

Transseptal puncture (TP) and the isolation of pulmonary veins (PV) via the internal jugular vein has been described as feasible but challenging, requiring several modifications of standard equipment.<sup>4–7</sup> Here we report cryoballoon ablation of the PV via the superior approach using a steerable sheath and standard equipment in a patient with symptomatic paroxysmal atrial fibrillation and bilateral thrombotic occlusion of the common femoral veins after intravenous drug abuse.

## Case report

A 35-year-old male patient was referred to our institution with symptomatic (EHRA IV) atrial fibrillation. The patient, whose antiarrhythmic therapy with beta-blockers failed, was also flecainide intolerant. The patient also presented with bilateral occlusion of the common femoral vein after bilateral

## KEY TEACHING POINTS

- The use of a steerable sheath with a long transseptal needle is a safe and effective alternative for transseptal puncture once superior access has been determined.
- The cryoballoon technique can be considered as an alternative to pulmonary vein isolation due to the right jugular vein approach.
- Because of the high amount of fluoroscopy time, special attention should be paid to proper radiation protection.

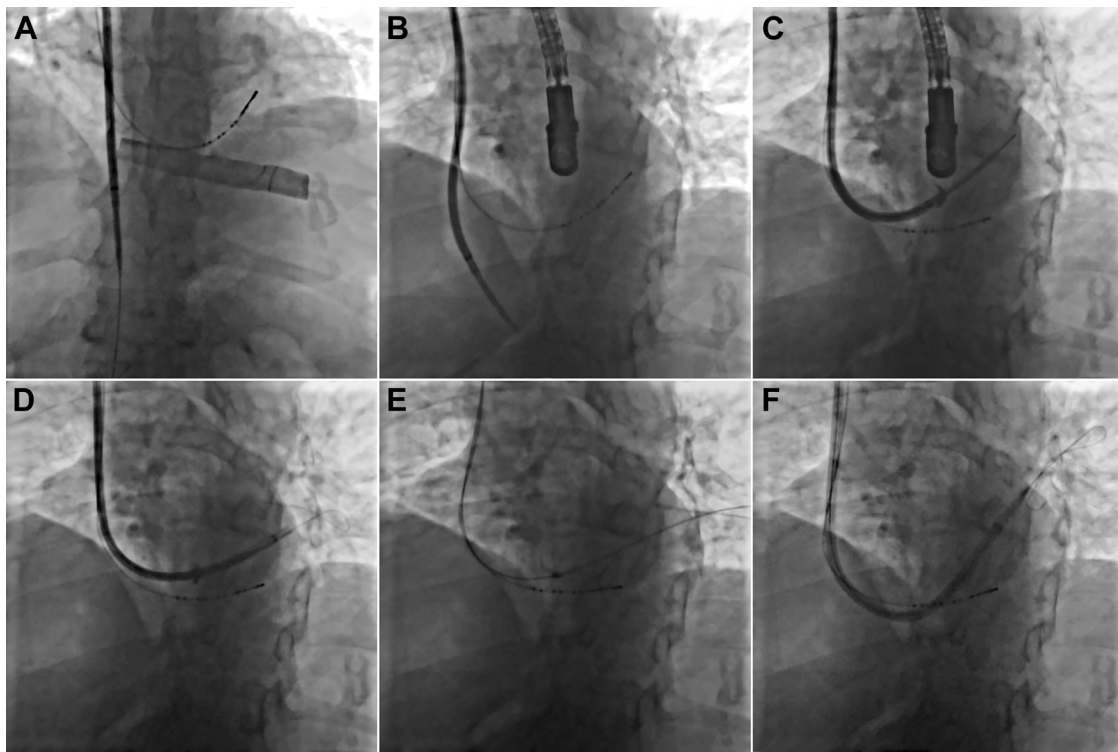
deep vein thrombosis owing to intravenous drug abuse. This was documented by means of duplex ultrasound and computed tomography angiography. The patient signed the written informed consent for this special case. For the assessment of the anatomy of the PV, magnetic resonance imaging was performed before the procedure. Four PV separately draining to the left atrium (LA) were presented. The PV anatomy was considered optimal for cryoballoon ablation. The procedure was performed under general anesthesia using propofol and midazolam. A steerable decapolar diagnostic catheter (Inquiry, 5F, Abbott, Chicago, IL) was inserted into the coronary sinus via cannulation using right internal jugular vein access with a short 6F sheath.

## Transseptal puncture from the jugular vein

Additional access to the right internal jugular vein was obtained using a second short 6F sheath, which was replaced by an 8.5F steerable sheath (Agilis NXT Steerable Introducer, 71 cm, large curve, Abbott) with a long transseptal needle (BRK1-XS, 98 cm, Abbott). The TP was successfully performed under fluoroscopy, transesophageal echocardiographic guidance, and continuous pressure monitoring, without any difficulty. The sheath was then inserted into the IVC position.

**KEYWORDS** Atrial fibrillation; Cryoballoon technique; Pulmonary vein isolation; Superior access; Transseptal puncture (Heart Rhythm Case Reports 2019;5:347–350)

**Address reprint requests and correspondence:** Dr Guram Imnadze, Department of Arrhythmia Management, Klinikum Osnabrück, D – 49076 Osnabrück, Germany. E-mail address: [imnadze@web.de](mailto:imnadze@web.de).



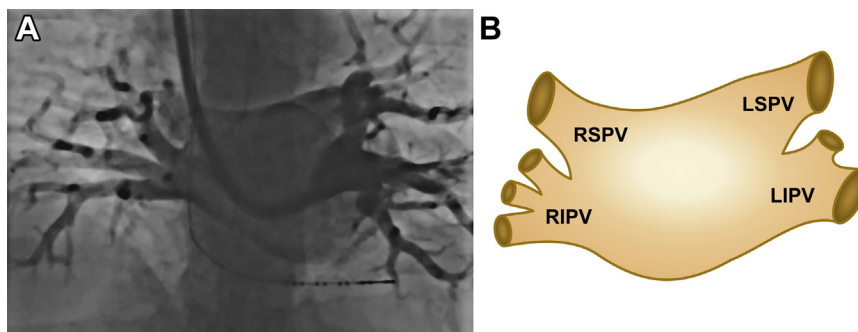
**Figure 1** A: The decapolar diagnostic catheter placed in the coronary sinus, and the deflectable (Agilis-L, Abbott, Chicago, IL) sheath placed in the inferior vena cava over the wire (the shadow below the coronary sinus catheter is the tissue on the surface). B: Under transesophageal echocardiography the sheath was deflected and pulled back until the tenting of the interatrial septum occurred. C: Transseptal puncture with the long XS BRK1 needle (Abbott). D, E: Positioning of the sheath in the left inferior pulmonary vein for the angiography (shown in Figure 2) and for the cryo-sheath exchange. F: The cryo-sheath placed in the left superior pulmonary vein.

After curving and pulling of the sheath, the tip of the sheath reached the desired segment of the atrial septum. Tenting of the intraatrial septum was verified via transesophageal echocardiography (Video 1). The sheath was then pushed forward slightly so the curve of the sheath lay down toward the tricuspid valve annulus and allowed better support and high puncture. Once the proper position was reached, the long transseptal needle was inserted carefully into the introducer. After the puncture was done, the needle was removed and a 0.32-inch, 260-cm wire was inserted and positioned in the left inferior pulmonary vein (LIPV), followed by placement of the tip of the Agilis sheath into the LIPV ostium. The steerable decapolar catheter was then moved from the coronary sinus into the right ventricular apex. Angiography of the LA was performed

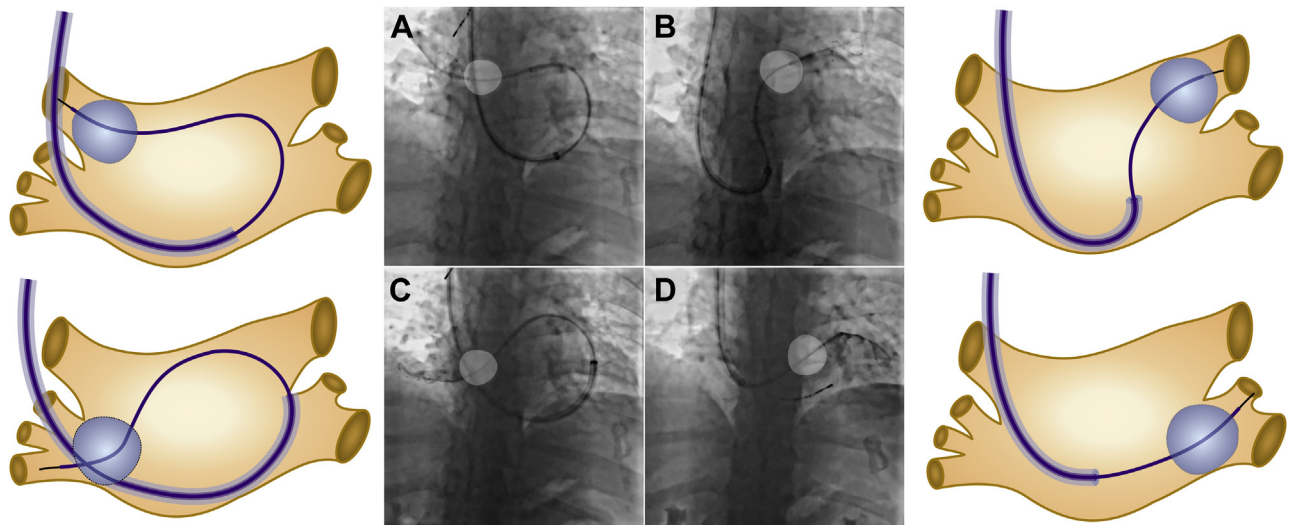
during rapid right ventricular apex pacing (300 ms), using a 50 mL syringe for the manual contrast injection. The technique was modified from the angiography method published previously.<sup>8</sup> The 8.5F steerable sheath was exchanged for the 12F steerable cryoballoon sheath (FlexCath, Medtronic, Quebec, Canada) (Figures 1 and 2).

### Cryoablation

A 28-mm Arctic Front Advance cryoballoon was inserted. The FlexCath enabled cannulation of all PV. For the “real-time” monitoring of PV potentials, the Achieve circular mapping catheter (Medtronic) was inserted via the inner lumen of the cryoballoon catheter. The angiographic and schematic



**Figure 2** A: The diagnostic catheter placed in the right ventricle for the rapid pacing (S1 300 ms). The angiography was performed manually using the 50 mL syringe with the pure contrast medium. B: Schematic illustration of the left atrium and the ostia of the pulmonary veins in this case. LIPV = left inferior pulmonary vein; LSPV = left superior pulmonary vein; RIPV = right inferior pulmonary vein; RSPV = right superior pulmonary vein.



**Figure 3** The angiographic and schematic illustration of the cryoballoon position during the application in all pulmonary veins (PV). **A:** The cryoballoon is placed in the right superior PV using the loop technique. **B:** The cryoballoon placed in the left superior PV. **C:** The cryoballoon is placed in the right inferior PV using the loop technique. **D:** The cryoballoon is placed into the left inferior PV (the “pull up” maneuver was used during this application).

illustration of the cryoballoon position during the application in all pulmonary veins is presented in [Figure 3](#). The characteristics of the cryo applications are presented in [Table 1](#).

After 30 minutes of waiting time, an exit and entry block of all PV was presented. Total ablation time came to 180 minutes. Total fluoroscopy time was 72.5 minutes and the air kerma dose was 713 mGy. The sheaths were removed after the procedure without reversing the heparin with protamine. After hemostasis was obtained (a Z-suture was used), the patient was transferred to the intensive cardiac unit. The patient was discharged from the hospital on day 4. During the 12-month follow-up, the patient did not experience any episodes of palpitation. Repeated 12-lead electrocardiograms and Holter electrocardiograms did not register any episodes of atrial fibrillation.

## Discussion

The bilateral occlusion of the common femoral vein after bilateral deep vein thrombosis in the present case was presumably due to the patient’s drug abuse. Administering drugs into a deep vein—usually in the groin—results in such

vascular complications as thrombophlebitis and thrombosis with further occlusion.<sup>9</sup> There is a 13.9% prevalence of previous deep vein thrombosis in users of opioids, with an annual incidence rate of 3.2% reported recently.<sup>10</sup>

In previously published cases using the RF ablation technique for atrial fibrillation ablation via superior access, together with jugular vein, the subclavian vein was cannulated. The TP was done using an SL3 sheath in these cases. However, in the first case using cryoballoon, TP was produced with an SL0 sheath.<sup>4–7</sup> It should be mentioned that systems specifically designed for superior TP for left ventricular pacing are currently available.<sup>11</sup>

In our case, we used a double puncture of the right jugular vein without any complications at the access site. The Z-suture was successfully used for hemostasis. The TP was performed under fluoroscopy, transesophageal echocardiographic guidance, and continuous pressure monitoring using the 8.5F steerable sheath and a long transeptal needle. Using this technique, we were able to deflect the sheath to the desirable place and insert the intraatrial septum at a maximally higher level.

Another important aspect of the success in this case was the position of the operator. As described in the first case

**Table 1** Characteristics of cryo applications

PV	Degree of occlusion	Minimal temperature (°C)	Total freezing time (seconds)	Time to isolation (seconds)*	Number of aborted applications
LIPV	3	−41	240	70	3
LSPV	3/4/4	−44/−48/−48	300/180/180	-	1
RSPV	4	−48	240	110	2
RIPV	3	−44	300	-	1

LIPV = left inferior pulmonary vein; LSPV = left superior pulmonary vein; PV = pulmonary vein; RIPV = right inferior pulmonary vein; RSPV = right superior pulmonary vein.

Degrees of occlusion were defined as follows: 4 = full occlusion; 3 = with the small lack of contrast.

\*Because of the deep position of the Achieve catheter, the time to isolation was not registered in LSPV and RIPV.

series, compared with the femoral venous approach, catheter manipulation (clockwise and counterclockwise rotations) via the superior approach is reversed.<sup>4</sup> Moreover, in our case we have also identified the importance of the proper position for the operator. After the operator moved to the head side of the patient, the maneuvering of the balloon catheter became similar to a femoral approach. However, the operator should keep in mind that the head-side position is associated with the highest exposure during the intervention, and maximal attention should be paid to radiation protection.

Although a contact leak below the balloon exists during femoral access, the “pulling down” technique is recommended.<sup>12</sup> In the present case, as in the first report using the cryoballoon, the reverse “pulling up” technique was required to achieve LIPV isolation (Video 2).

Baszko and colleagues<sup>7</sup> reported a total procedural time and fluoroscopy time using the cryoballoon of 210 minutes and 78 minutes, respectively. In our case, the procedure time was 180 minutes with a fluoroscopy time of 72.5 minutes. In our opinion, this was owing to a lack of experience and the limited number of case reports. The RF ablation and 3-dimensional navigation systems are used in most cases (5 cases described in the literature), but the duration of the procedure and radiation levels were not stated in those reports.<sup>4–6</sup> This was one of the reasons why we leaned toward the cryoballoon technique. Moreover, in recent years, experience with PVI using the cryoballoon has grown extensively in our institution. The fluoroscopy time in our case was a bit shorter than reported previously but is still high, and we hope it can be decreased gradually through increased experience and detailed reports of such cases.

It should be noted that retrograde access of the left atrium for PVI using a magnetic navigation system (if available at the clinic) is a feasible and safe alternative in patients for whom the classic transseptal approach is impossible.<sup>13</sup> Fortunately we did not face any complications in our case, but with regard to this kind of intervention, the operator should keep in mind that in patients who have undergone cryoballoon ablation, the incidence of iatrogenic atrial septal defect is frequent in comparison to the RF ablation technique<sup>14</sup> and potentially could be even more so because of superior access.

## Conclusion

This is the second successful case of PVI using the cryoballoon owing to the right jugular vein approach. The steerable

sheath with the use of a long transseptal needle is a safe and effective alternative to TP using superior access.

## Appendix Supplementary data

Supplementary data associated with this article can be found in the online version at <https://doi.org/10.1016/j.hrcr.2019.02.008>.

## References

1. Kirchhof P, Benussi S, Kotecha D, et al. 2016 ESC Guidelines for the management of atrial fibrillation developed in collaboration with EACTS. *Europace* 2016;18:1609–1678.
2. Kuck KH, Fünkrantz A, Chun KR, et al. FIRE AND ICE Investigators. Cryoballoon or radiofrequency ablation for symptomatic paroxysmal atrial fibrillation: re-intervention, rehospitalization, and quality-of-life outcomes in the FIRE AND ICE trial. *Eur Heart J* 2016;37:2858–2865.
3. Koc Z, Oguzkurt L. Interruption or congenital stenosis of the inferior vena cava: prevalence, imaging, and clinical findings. *Eur J Radiol* 2007;62:257–266.
4. Lim HE, Pak HN, Tse HF, Lau CP, Hwang C, Kim YH. Catheter ablation of atrial fibrillation via superior approach in patients with interruption of the inferior vena cava. *Heart Rhythm* 2009;6:174–179.
5. Kato H, Kubota S, Yamada Y, et al. Circumferential pulmonary vein ablation of atrial fibrillation via superior vena cava approach in a patient with interruption of the inferior vena cava. *Europace* 2010;12:746–748.
6. Kato H, Kubota S, Goto T, et al. Transseptal puncture and catheter ablation via the superior vena cava approach for persistent atrial fibrillation in a patient with polysplenia syndrome and interruption of the inferior vena cava: contact force–guided pulmonary vein isolation. *Europace* 2017;19:1227–1232.
7. Baszko A, Kałmucki P, Dankowski R, Łanocha M, Siminiak T, Szyszka A. Transseptal puncture from the jugular vein and balloon cryoablation for atrial fibrillation in a patient with azygos continuation of an interrupted inferior vena cava. *Europace* 2015;17:1153–1156.
8. Imnadze G, Kranig W, Grove R, Wolff E, Thale J. The ABC of a Simple Method for Pulmonary Vein Angiography. *Indian Pacing Electrophysiol J* 2014;14:53–59.
9. Mackenzie A, Laing R, Douglas J, Greaves M, Smith C. High prevalence of ilio-femoral venous thrombosis with severe groin infection among injecting drug users in North East Scotland: successful use of low molecular weight heparin with antibiotics. *Postgrad Med J* 2000;76:561–565.
10. Cornford CS, Mason JM, Inns F. Deep vein thromboses in users of opioid drugs: incidence, prevalence, and risk factors. *Br J Gen Pract* 2011;61:e781–786.
11. Morgan JM, Biffi M, Gellér L, et al. ALSYNC Investigators. ALternate Site Cardiac ResYNChronization (ALSYNC): a prospective and multicentre study of left ventricular endocardial pacing for cardiac resynchronization therapy. *Eur Heart J* 2016;37:2118–2127.
12. Chun KR, Schmidt B, Metzner A, et al. The ‘single big cryoballoon’ technique for acute pulmonary vein isolation in patients with paroxysmal atrial fibrillation: a prospective observational single centre study. *Eur Heart J* 2009;30:699–709.
13. De Roeck L, Riahi L, Wijchers S, Stockman D, De Greef Y, Schwagten B. Retrograde access of the left atrium for pulmonary vein isolation using magnetic navigation after closure of an atrial septum defect. *Neth Heart J* 2015;23:368–369.
14. Naksuk N, Asirvatham SJ. Iatrogenic atrial septal defect: reassurance or inquisitiveness. *J Interv Card Electrophysiol* 2018;52:137–140.