

Hypertensive iridocyclitis associated with delayed onset biopsy proven Cytomegalovirus retinitis

David M Squirrel, Sudipto Bhatta¹,
Hardeep S Mudhar², Ian G Rennie¹

We describe a case of primary hypertensive iridocyclitis with biopsy-proven Cytomegalovirus retinitis. It is an observational case report of a 69-year-old diabetic gentleman on azathioprine for Crohn's disease who presented with recurrent episodes of hypertensive iridocyclitis. On the 4th attendance in 5 months, a granular white lesion was noted in the temporal periphery of the mid-peripheral fundus and a chorioretinal and vitreous biopsy performed. Vitreous PCR was positive for Cytomegalovirus (CMV). Hematoxylin and eosin staining revealed cytomegalic-like inclusions within necrotic neural retina. Transmission electron microscopy revealed herpes family virus particles and immunohistochemistry demonstrated CMV protein. This case provides further evidence implicating CMV infection in the etiology of hypertensive iridocyclitis. With hindsight, the cumulative effect of diabetes and azathioprine on the immune surveillance system proved sufficient to render the patient susceptible to CMV retinitis.

Key words: Cytomegalovirus retinitis, hypertensive iridocyclitis, vitreous polymerase chain reaction

Posner-Schlossman syndrome (PSS) is recognized as a distinct clinical entity, comprising unilateral recurrent attacks of glaucoma where the intraocular pressure rise is out of proportion to the associated cyclitis.^[1] Although it was initially hypothesized that PSS may have an allergic etiology,^[1] more recently positive polymerase chain reaction (PCR) for Cytomegalovirus (CMV) has been described in anterior chamber isolates from immunocompetent individuals presenting with PSS.^[2-4] These data suggest that at least in a subgroup of patients with presumed PSS, hypertensive iridocyclitis may actually be caused by a primary herpetic, particularly CMV infection of the eye, which individuals with a competent immune system limit to the anterior chamber.

We describe the case of a 69-year-old diabetic gentleman who presented with recurrent episodes of hypertensive iridocyclitis mimicking PSS. On the fourth attendance in 5 months, a granular white lesion was noted in the temporal periphery of the mid peripheral fundus and a chorioretinal and vitreous biopsy performed. This revealed an unexpected diagnosis of CMV retinitis. We suggest that this case provides further evidence to implicate CMV infection of the eye as a causative trigger for hypertensive iridocyclitis, which in our case, went on to cause posterior segment disease. It also serves to emphasize the need to maintain a high index of suspicion for unusual infections when managing patients with compromised immune systems, from whatever cause.

Case Report

A 69-year-old gentleman presented with a history of episodic blurred vision in his right eye. On examination, visual acuity was 6/12, the intraocular pressure was 48 mmHg, but aside a mild anterior chamber cellular reaction and fine stellate KPs, ocular examination was unremarkable. The patient's medical history included type 2 diabetes and terminal ileal Crohn's disease, for which he was prescribed Rosiglitazone and Azathioprine 150 mg od. There was no significant past ocular history.

A diagnosis of Posner-Schlossman Syndrome was made, and topical corticosteroids and timolol were prescribed. Following treatment, the ocular condition rapidly resolved with complete resolution of anterior chamber inflammation and normalization of IOP, but over the ensuing 3 months, the patient presented with 2 further episodes of presumed PSS. On each occasion, the condition was controlled with topical corticosteroids and timolol. On a further attendance 6 weeks later, the visual acuity was noticeably more reduced than previously (6/36), and in addition to a mild anterior chamber reaction and high intraocular pressure (42 mmHg), there was also a moderate vitritis. An examination of the posterior pole at this attendance revealed a small discrete area (2 disc diameters) of granular retinal pallor in the temporal periphery. There was no associated hemorrhage, and this was diagnosed as peripheral drusen. The patient was treated

Access this article online	
Quick Response Code:	Website: www.ijo.in
	DOI: 10.4103/0301-4738.97086

Department of Ophthalmology, Greenlane Clinical Centre, Auckland, New Zealand, ¹Ophthalmology, and ²Pathology, Royal Hallamshire Hospital, Sheffield, United Kingdom

Correspondence to: Mr. Sudipto Bhatta, Department of Ophthalmology, Royal Hallamshire Hospital, Sheffield, S10 2JF, United Kingdom. E-mail: sudiptobhatta@rediffmail.com

Manuscript received: 24.07.11; Revision accepted: 10.04.12

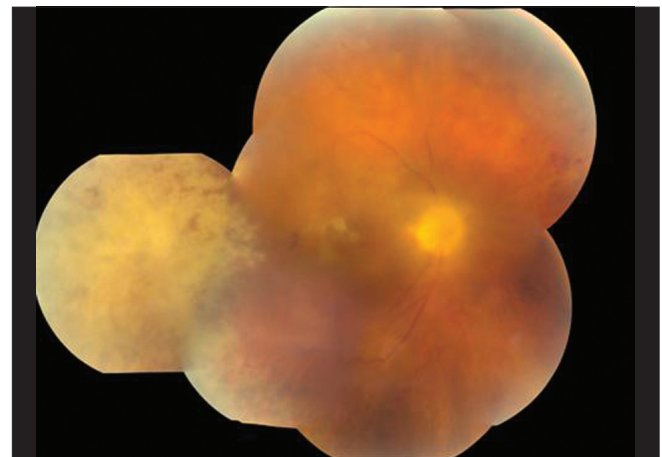


Figure 1: Color fundus photograph. There is an area of granular retinal pallor in the temporal periphery, which had enlarged over 4 months. There is a possible satellite lesion at the fovea, an associated vitritis and new vessels at the disc

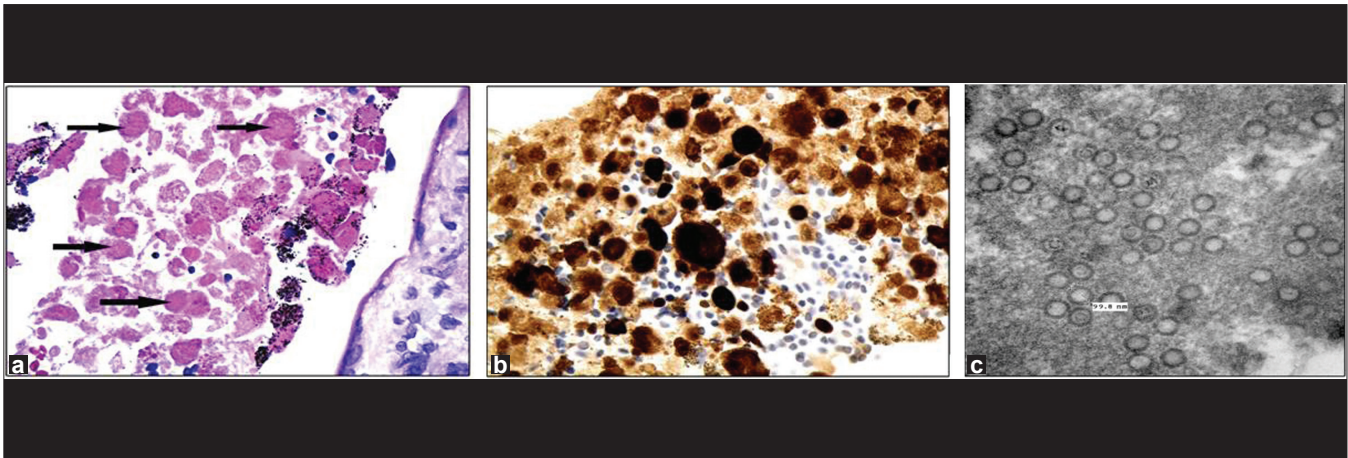


Figure 2: Chorioretinal biopsy (a) Hematoxylin and eosin stained chorioretinal biopsy. The black arrows point to cytomegalic-like inclusions within the eosinophilic, necrotic neural retina (Magnification, $\times 400$), (b) Immunohistochemistry: chorioretinal tissue stained with monoclonal antibodies to cytomegalovirus protein shows positive brown signal within the necrotic neural retina (Magnification, $\times 400$), (c) Transmission electron microscopy shows herpes family viruses particles within the necrotic neural retina (Magnification, $\times 20000$)

with topical and systemic prednisolone with resolution of the ocular inflammation and improved visual acuity. Over the ensuing 12 weeks, the systemic and topical steroids were tapered, but the ocular inflammation recurred as the dose was reduced. It was also noted that the previously noted white patch had enlarged [Fig. 1] and a chorioretinal and vitreous biopsy organized. Vitreous PCR [LightCycler[®] FRET technology (Roche)] was positive for Cytomegalovirus (CMV) and negative for HZV, HSV 1 and 2. Hematoxylin and eosin staining revealed cytomegalic-like inclusions within necrotic neural retina. Transmission electron microscopy revealed herpes family virus particles, and immunohistochemistry demonstrated CMV protein [Fig. 2]. The patient was investigated for other causes of immunocompromise without a positive result. In particular, 3rd generation HIV test (ELISA) was negative, his CD4 counts were consistently above 350, and his full blood count was normal. Despite treatment with intravenous ganciclovir and long-term oral valacyclovir (as per local guidelines), the retinitis progressed rapidly to involve the central macula. The patient's final visual acuity was "hand movements".

Discussion

Ocular CMV infection is most commonly known for the typical retinitis that is seen in those patients who are severely immunocompromised or receiving combination immunosuppressive therapy.^[5] It is however recognized that CMV infection may also be implicated in PSS/ 'hypertensive iridocyclitis'.^[3,4] Currently, the pathophysiology of CMV associated hypertensive iridocyclitis remains obscure.^[6] Anterior chamber involvement in patients with CMV retinitis secondary to AIDS is occasionally seen, but when present, is not typically a Posner-Schlossman like syndrome. The anterior chamber inflammation, observed in patients with AIDS, could be due to either primary anterior segment infection or it may also simply be an inflammatory response, secondary to posterior segment pathology.

The discovery of positive PCR for CMV in anterior chamber isolates from immunocompetent patients presenting with isolated PSS suggests that, at least in some patients,

hypertensive iridocyclitis may actually be caused by primary herpetic infection of the anterior chamber and thus mimics PSS.^[3,4] With the benefit of hindsight, it is likely that in the case we describe the CMV infection was unrecognized for some months. The fact that the patient had a moderate vitritis also caused confusion as CMV retinitis is typically associated with a quiet vitreous. Only one can assume that the vitritis represented an inadequate immunological response to the virus, a response that is often not generated in patients with low CD4 counts associated with HIV CMV retinitis. Therefore, although the presentation of PSS in our patient predated the definitive diagnosis of CMV retinitis by 6 months, it is tempting to speculate that the initial presentation of PSS in our case also coincided with the primary presentation of CMV in the eye. Whilst not conclusive, we suggest that our case provides further evidence that CMV infection of the eye can present with a clinical syndrome of hypertensive iridocyclitis, which without further diagnostic testing, is indistinguishable from PSS. The evolving clinical scenario presented a number of diagnostic difficulties. With hindsight, the cumulative effect of diabetes and azathioprine on the immune surveillance system proved sufficient to render the patient susceptible to CMV retinitis. In patients without HIV, it is regrettably not unusual for the diagnosis of CMV retinitis to be delayed.^[7] This case therefore also emphasizes the need to maintain a high index of suspicion for unusual infections when managing patients with compromised immune systems, from whatever cause.

References

1. Theodore FH. Observations on glaucomatocyclitic crises (Posner Schlossman syndrome). *Br J Ophthalmol* 1952;36:207-10.
2. Teoh SB, Thean L, Koay E. Cytomegalovirus in aetiology of Posner-Schlossman syndrome: Evidence from quantitative polymerase chain reaction. *Eye (Lond)* 2005;19:1338-40.
3. de Schryver I, Rozenberg F, Cassoux N, Michelson S, Kestelyn P, Lehoang P, *et al.* Diagnosis and treatment of cytomegalovirus iridocyclitis without retinal necrosis. *Br J Ophthalmol* 2006;90: 852-5.
4. Chee SP, Bacsal K, Jap A, Se-Thoe SY, Cheng CL, Tan BH. Clinical features of cytomegalovirus anterior uveitis in immunocompetent

- patients. *Am J Ophthalmol* 2008;145:834-40.
5. Yoser SL, Forster DJ, Rao NA. Systemic viral infections and their retinal and choroidal manifestations. *Surv Ophthalmol* 1993;37:312-52.
 6. Kim EC, Moargolis TP. Hypertensive iridocyclitis. *Br J Ophthalmol* 2006;90:812-3.
 7. Eid AJ, Bakri SJ, Kijpittayarit S, Razonable RR. Clinical features

and outcomes of cytomegalovirus retinitis after transplantation. *Transpl Infect Dis* 2008;10:13-8.

Cite this article as: Squirell DM, Bhatta S, Mudhar HS, Rennie IG. Hypertensive iridocyclitis associated with delayed onset biopsy proven Cytomegalovirus retinitis. *Indian J Ophthalmol* 2014;62:656-8.

Source of Support: Nil. **Conflict of Interest:** None declared.
