

## LETTER TO THE EDITOR

## Successful Treatment of Xanthoma Disseminatum with Combined Lipid Lowering Agents

Won-Jeong Kim, M.D.<sup>1</sup>, Hyun-Chang Ko, M.D.<sup>1,2</sup>, Byung-Soo Kim, M.D., Ph.D.<sup>1,2</sup>, Moon-Bum Kim, M.D., Ph.D.<sup>1,2</sup>

<sup>1</sup>Department of Dermatology, Pusan National University School of Medicine, <sup>2</sup>Biomedical Research Institute, Pusan National University Hospital, Busan, Korea

Dear editor:

Xanthoma disseminatum (XD) is a rare, benign, normolipidemic mucocutaneous xanthomatosis of unknown etiology<sup>1</sup>. Many therapeutic options such as surgical excision, laser ablation, electrodesiccation, systemic medications, and radiotherapy are available, but treatment is challenging<sup>2</sup>. We present a male XD patient who showed marked improvement with combination of lipid lowering agents.

A 37-year-old Asian male presented with 5-year history of numerous asymptomatic yellow-brownish papules distributed on face and flexural areas (Fig. 1). Laboratory investigations revealed normal lipid levels. Three years prior to visiting our clinic, he was diagnosed as XD associated with central diabetes insipidus in other hospital, and treated with daily cyclophosphamide and desmopressin acetate. However, while the diabetes insipidus improved, there was no effect on the XD. Intermittent CO<sub>2</sub> laser ablation and electrodesiccation reduced the number of lesions temporarily, but new lesions appeared continually. Owing to the persistence and spread of refractory cutaneous lesions, a combination of rosiglitazone 4 mg daily, simvastatin 10 mg daily and fenofibrate 200 mg daily treatment was initiated in our hospital. Eight weeks

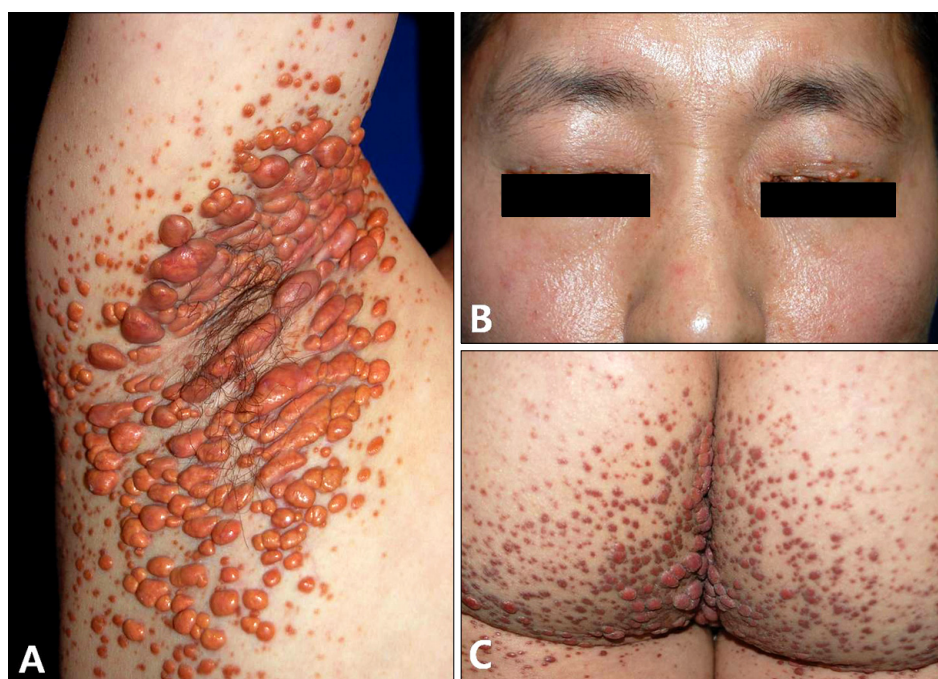
after beginning medication, the patient reported an improvement of cutaneous lesions such as notable reduction of size, brownish color change and flattening. After 1 year, the lesions improved more than a half and the marked improvement persisted 2 years since then (Fig. 2).

Most of xanthomatous disorders reflect elevated lipid levels. It is thought that lipoproteins permeate the vessel walls and then develop foam cells. However, contrary to other xanthomatous disorders, XD patients have normal serum lipid levels. One suggested hypothesis is that the secondary accumulations of cholesterol develop after primary proliferation of histiocytes<sup>1</sup>. This is supported by the histopathologic findings of XD in that the foam cells are rare and scalloped macrophages dominant in early stage, but well-developed lesions show a mixture of scalloped cells, foamy cells, and inflammatory cells<sup>3</sup>. Foamy cells could be induced by increased uptake, synthesis and decreased efflux of lipid, and the cytokines from the inflamed intima could also be triggering factors<sup>4</sup>. Therefore, reducing the inflammation of the lesion and inhibiting the subsequent formation of foam cells could be an important therapeutic goal in XD. For these reasons, we previously attempted to use lipid lowering agent monotherapy in a small number of XD patients, but we saw no improvement. Thus, we attempted to use a combination of three lipid lowering agents, PPAR  $\gamma$ , statins, and fenofibrate, modifying suggestions by Eisendle et al.<sup>5</sup>. PPAR  $\gamma$  inhibits the production of macrophage-induced inflammatory cytokines as well as reducing adipogenic action of macrophage by inducing reverse cholesterol transport<sup>6</sup>. Statins are known to decrease inflammation and to inhibit the production of precursors to cholesterol synthesis<sup>4</sup>. Fenofibrate, the final combination agent, activates PPAR  $\alpha$  and improves high density lipoprotein functions such as

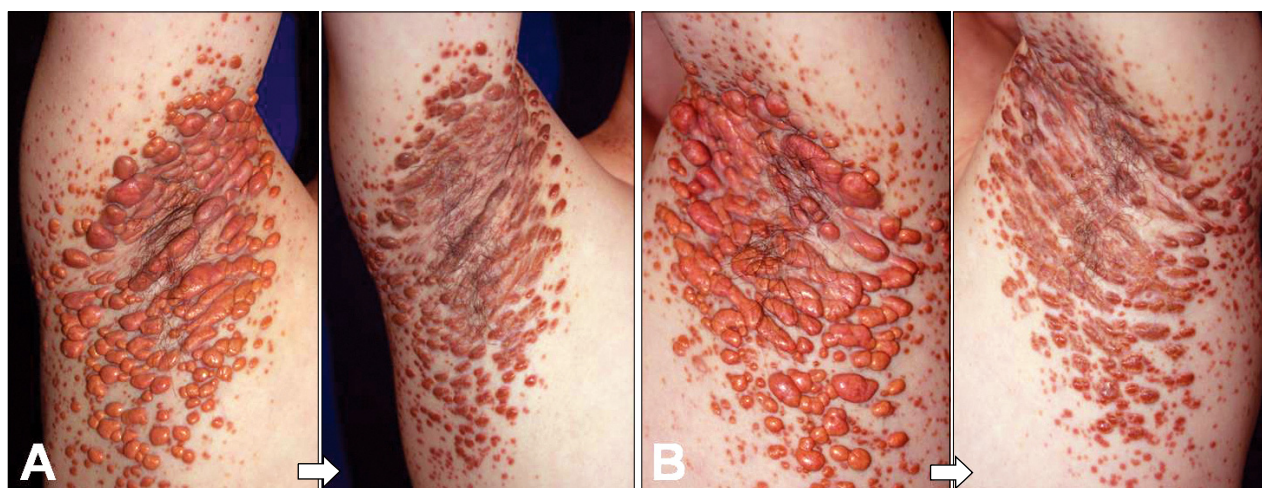Received October 18, 2011, Revised November 29, 2011, Accepted for publication November 30, 2011

**Corresponding author:** Moon-Bum Kim, M.D., Ph.D., Department of Dermatology, Pusan National University Hospital, Pusan National University School of Medicine, 179 Gudeok-ro, Seo-gu, Busan, 602-739, Korea. Tel: 82-51-240-7338, Fax: 82-51-245-9467, E-mail: drkmp@hanmail.net

This is an Open Access article distributed under the terms of the Creative Commons Attribution Non-Commercial License (<http://creativecommons.org/licenses/by-nc/3.0>) which permits unrestricted non-commercial use, distribution, and reproduction in any medium, provided the original work is properly cited.



**Fig. 1.** Multiple well-defined yellow-brownish various sized papulonodular skin lesions on right axilla (A), eyelids (B), and buttock (C).



**Fig. 2.** Markedly flattened yellow-brownish papulonodules on both axillae (A: right, B: left) after 1 year of lipid-lowering agents in combination.

reverse cholesterol transport and anti-inflammatory activity<sup>7</sup>. Though the use of combination therapy of lipid lowering agents is still rare in dermatologic fields except in one reported case in XD with partial remission<sup>5</sup>, there are several articles reporting a superior effect of combination therapy on the treatment of hyperlipidemia<sup>7,8</sup>. The mechanism of combination treatment of XD is still ambiguous; we thought it may result from decreased inflammation and reduced formation of foam cells. Before visiting our clinic, our patient's lesions showed

little change after treatment and new lesions appeared continually. However, after only 8 weeks of lipid lowering agents combination therapy, the lesions were flattened, decreased in the size, and no more new lesions appeared. Therefore, we thought this patient improved with combination therapy. To our knowledge, it is a unique case of a successful outcome with combination therapy of lipid lowering agents in the treatment of XD. In our opinion, this is a promising therapy for the treatment of XD recalcitrant to other treatments.

## ACKNOWLEDGMENT

---

This work was supported by a 2 Year Research Grant of Pusan National University.

## REFERENCES

---

1. Parker F. Xanthomas and hyperlipidemias. *J Am Acad Dermatol* 1985;13:1-30.
2. Kim JY, Jung HD, Choe YS, Lee WJ, Lee SJ, Kim do W, et al. A case of xanthoma disseminatum accentuating over the eyelids. *Ann Dermatol* 2010;22:353-357.
3. Burgdorf WH, Zelger B. The histiocytosis. In: Elder DE, Elenitsas R, Johnson BL Jr, editors. *Lever's histopathology of the skin*. 10th ed. Philadelphia: Lippincott Williams & Wilkins, 2009:667-688.
4. Joshi PH, Jacobson TA. Therapeutic options to further lower C-reactive protein for patients on statin treatment. *Curr Atheroscler Rep* 2010;12:34-42.
5. Eisendle K, Linder D, Ratzinger G, Zelger B, Philipp W, Piza H, et al. Inflammation and lipid accumulation in xanthoma disseminatum: Therapeutic considerations. *J Am Acad Dermatol* 2008;58(2 Suppl):S47-49.
6. Jiang C, Ting AT, Seed B. PPAR-gamma agonists inhibit production of monocyte inflammatory cytokines. *Nature* 1998;391:82-86.
7. Alagona P Jr. Fenofibric acid: a new fibrate approved for use in combination with statin for the treatment of mixed dyslipidemia. *Vasc Health Risk Manag* 2010;6:351-362.
8. Yiu KH, Cheung BM, Tse HF. A new paradigm for managing dyslipidemia with combination therapy: laropirant + niacin + simvastatin. *Expert Opin Investig Drugs* 2010;19:437-449.