




Since January 2020 Elsevier has created a COVID-19 resource centre with free information in English and Mandarin on the novel coronavirus COVID-19. The COVID-19 resource centre is hosted on Elsevier Connect, the company's public news and information website.

Elsevier hereby grants permission to make all its COVID-19-related research that is available on the COVID-19 resource centre - including this research content - immediately available in PubMed Central and other publicly funded repositories, such as the WHO COVID database with rights for unrestricted research re-use and analyses in any form or by any means with acknowledgement of the original source. These permissions are granted for free by Elsevier for as long as the COVID-19 resource centre remains active.



Contents lists available at ScienceDirect

# Interdisciplinary Neurosurgery: Advanced Techniques and Case Management

journal homepage: [www.elsevier.com/locate/inat](http://www.elsevier.com/locate/inat)

Case Reports &amp; Case Series

## Cerebral venous sinus thrombosis in COVID 19 patients: Report of 2 cases

Mahmoud M. Taha<sup>a</sup>, Mazen M. Taha<sup>b</sup>, Hassan A. Al Menshawy<sup>c</sup>, Ahmad M. Elsharkawy<sup>a,\*</sup><sup>a</sup> Department of Neurosurgery, Zagazig University, Zagazig, Egypt<sup>b</sup> Faculty of Medicine, Zagazig University, Zagazig, Egypt<sup>c</sup> Department of Neurosurgery, AlMokatam Insurance Hospital, Cairo, Egypt

## ARTICLE INFO

## Keywords:

Corona virus disease 2019 (COVID-19)  
Severe acute respiratory syndrome coronavirus 2 (SARS-CoV-2)  
Cerebral venous sinus thrombosis (CVST)  
Venous thrombotic events (VTE)  
Neurological manifestations

## ABSTRACT

**Background:** Initially, novel severe acute respiratory syndrome coronavirus (SARS-CoV-2) was considered primarily a respiratory pathogen. However, with time it has behaved as a virus with the potential to cause multi-system involvement, including neurological manifestations which varies from acute to subacute onset of headache, seizures, a decrease of consciousness, and paralysis.

**Case description:** Two cases of cerebral sinus venous thrombosis in COVID-19 patients were reported, following respiratory disorders, which was triggered by the SARS-CoV-2 infection. The first patient, presented with a decrease in level of consciousness and hemiparesis, was 23 years old female having no history of previous medical co-morbidities. The latter case, 21 years old woman showed less severe presentations of COVID-19 associated with headache, vomiting and papilledema. These two cases marvellously improved with no neurological deficit with aggressive course of anticoagulation.

**Conclusion:** CVST should be suspected in COVID-19 patients presenting with headache, paralysis, aphasia or seizures. The high mortality rate of CVST in COVID-19 infection warrants a high index of suspicion from physicians, and early treatment with anticoagulation should be initiated.

## 1. Introduction

Cerebral venous thrombosis (CVT) is a rare neurovascular emergency, and its incidence is estimated to be around 1.6 cases per 100,000 per year [1]. However, the true incidence of cerebral venous thrombosis occurrence in COVID-19 patients remains unknown [2]. Thromboembolic events of the nervous system with subsequent cerebrovascular stroke have been reported as an initial presentation in some cases of Corona virus disease 2019 (COVID-19), following very mild flu like symptoms, which is predominantly an acute respiratory disease caused by a single-stranded RNA virus known as severe acute respiratory syndrome corona virus 2 (SARS-CoV-2) [3,4]. SARS-CoV-2 infection related arterial and venous thrombosis was attributed to endothelial dysfunction [5–7], hyper inflammatory state [5,8], platelet activation [5,9], and vascular stasis [5,10] i.e., activation of the Virchow's triad [11]. The clinical presentation of cerebral venous sinus thrombosis (CVST) varies from acute to subacute headache, confusion, seizures, and/or focal neurological deficits. Magnetic resonance imaging (MRI) and magnetic resonance venography (MRV) is a reliable method for diagnosis.

However, computed tomography venography (CTV) is a good option when MRI is not feasible [12]. Given the pandemic of COVID-19 and the severity of CVST as a complication, it is mandatory to suspect their association, clinical manifestations, diagnosis and treatment strategies [12].

## 2. Illustrated case presentation

## 2.1. Case 1

A 23 years old, female was admitted to intermediate care unit in our isolation hospital with a history of fever, progressive cough, and discomfort during breathing for the last 5 days. There was no previous history of any medical problems, smoking, pregnancy or oral contraceptive pills. On admission she was conscious and alert, her O<sub>2</sub> saturation was 90%, body temperature 38.4, blood pressure 126/78 mmHg. Laboratory test showed significant leucocytosis (WBC  $41.89 \times 10^3/L$ ), fibrinogen 324 mg/Dl. Rt-PCR test for a nasopharyngeal swab showed positive result for SARS-CoV-2. Chest CT scan confirmed the diagnosis of

\* Corresponding author at: Department of Neurosurgery, Zagazig University, P.O.BOX 44512, Zagazig, Egypt.

E-mail addresses: [mahmoudlotfy1972@yahoo.co.uk](mailto:mahmoudlotfy1972@yahoo.co.uk) (M.M. Taha), [mazenmahmoud17@yahoo.co.uk](mailto:mazenmahmoud17@yahoo.co.uk) (M.M. Taha), [d.ahmad\\_elsharkawy@yahoo.com](mailto:d.ahmad_elsharkawy@yahoo.com) (A.M. Elsharkawy).

<https://doi.org/10.1016/j.inat.2022.101599>

Received 3 January 2022; Received in revised form 13 May 2022; Accepted 30 May 2022

Available online 6 June 2022

2214-7519/© 2022 The Author(s). Published by Elsevier B.V. This is an open access article under the CC BY-NC-ND license (<http://creativecommons.org/licenses/by-nc-nd/4.0/>).

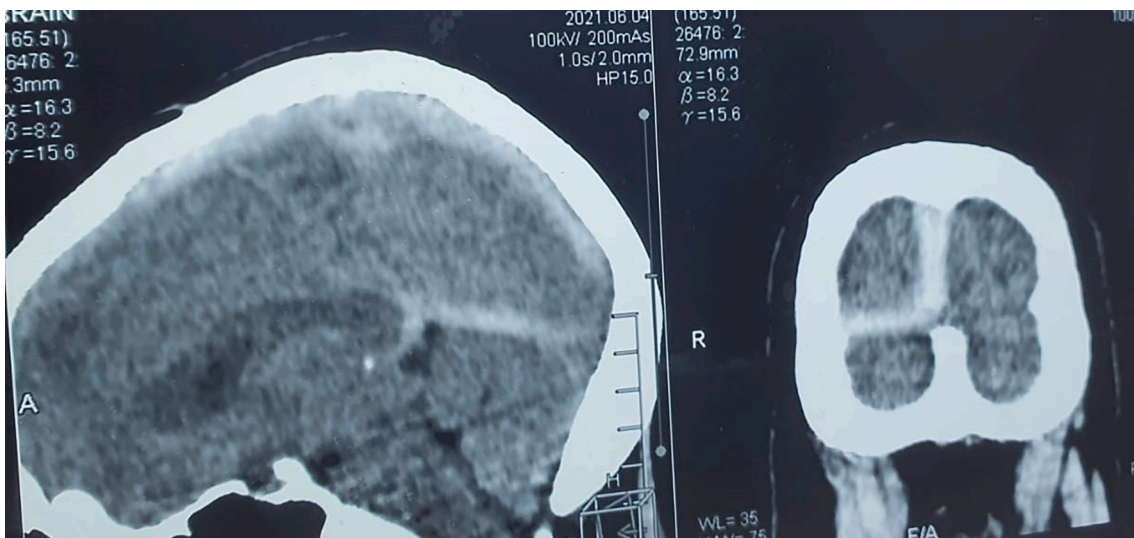


Fig. 1. CT brain showing hyperdensity at superior sagittal and right transverse sinuses indicating thrombosis (case I).

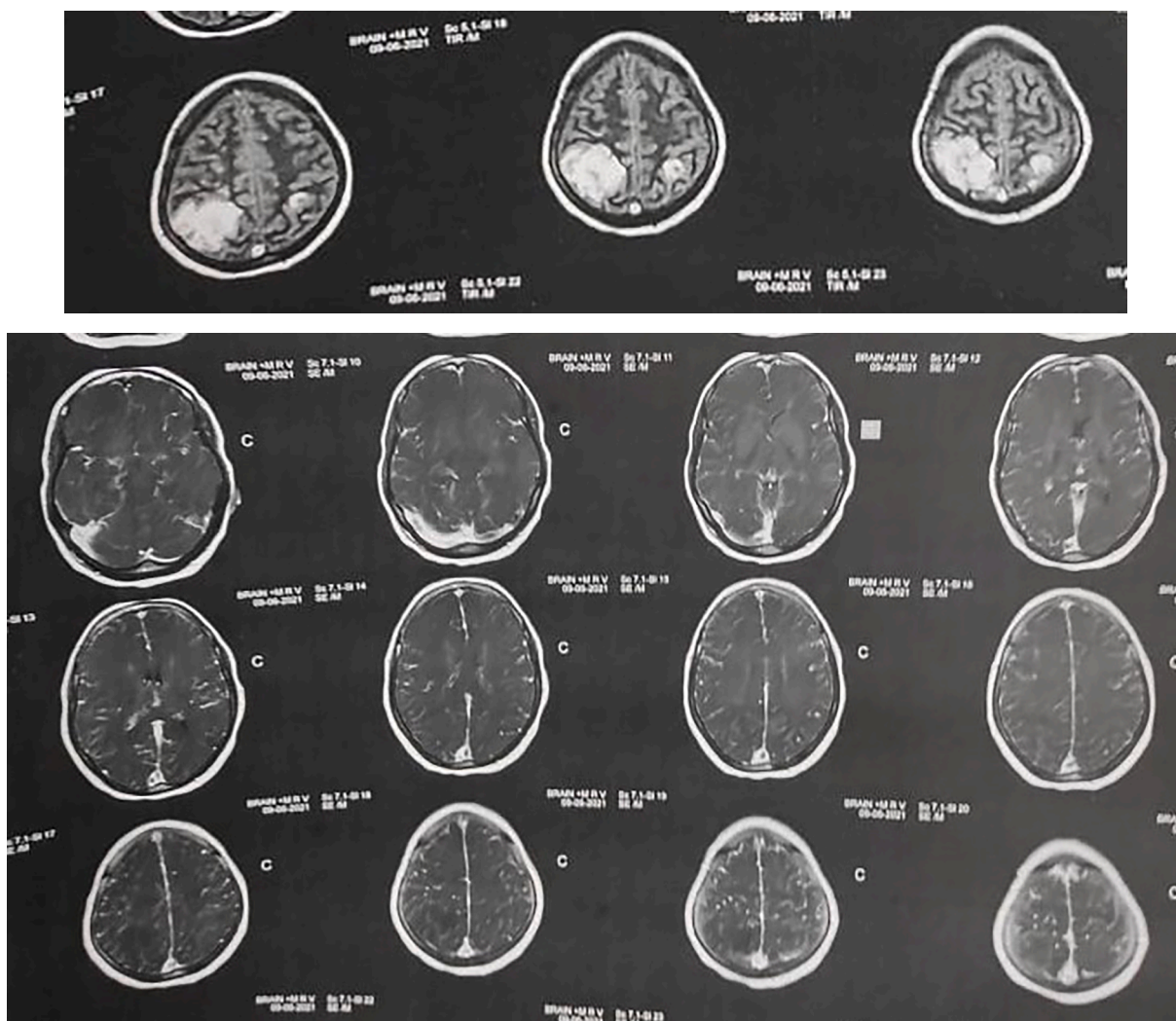


Fig. 2. MRI brain: (a) axial T2-weighted images, (b) axial T1-weighted images with IV contrast, (c) coronal T1-weighted images with IV contrast showing right cerebral venous infarction, thrombosed superior sagittal, right transverse and right sigmoid sinuses (case I).

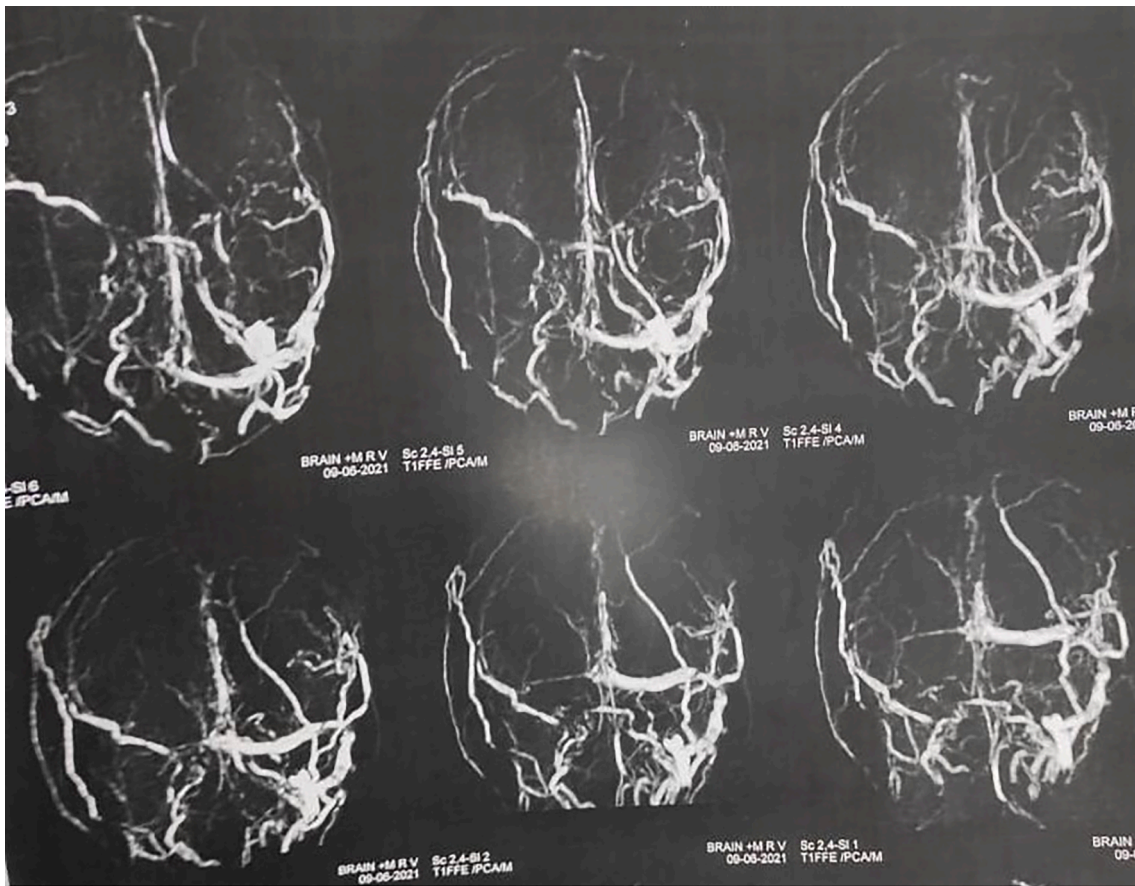

Fig. 3. MRV brain showing superior sagittal, right transverse, right sigmoid and right internal jugular vein thrombosis (case 1).

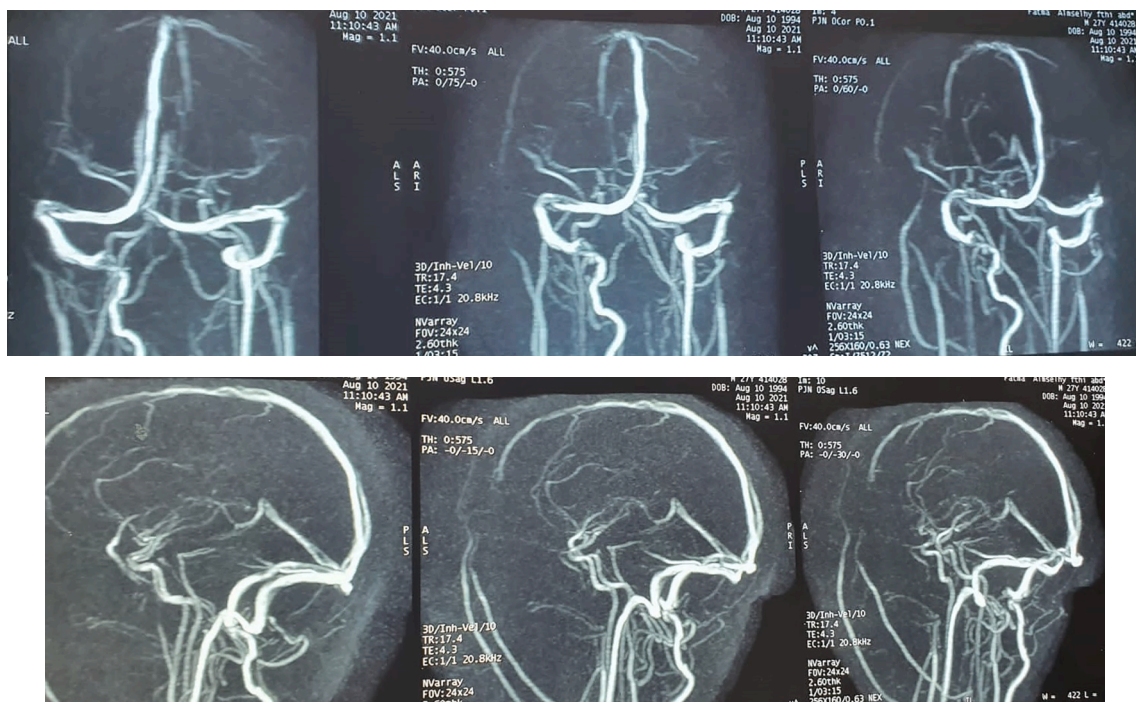


Fig. 4. Two months follow up MRV brain: (a) A-P image. (b) lateral image showing patent all venous sinuses with complete recanalization (case 1).

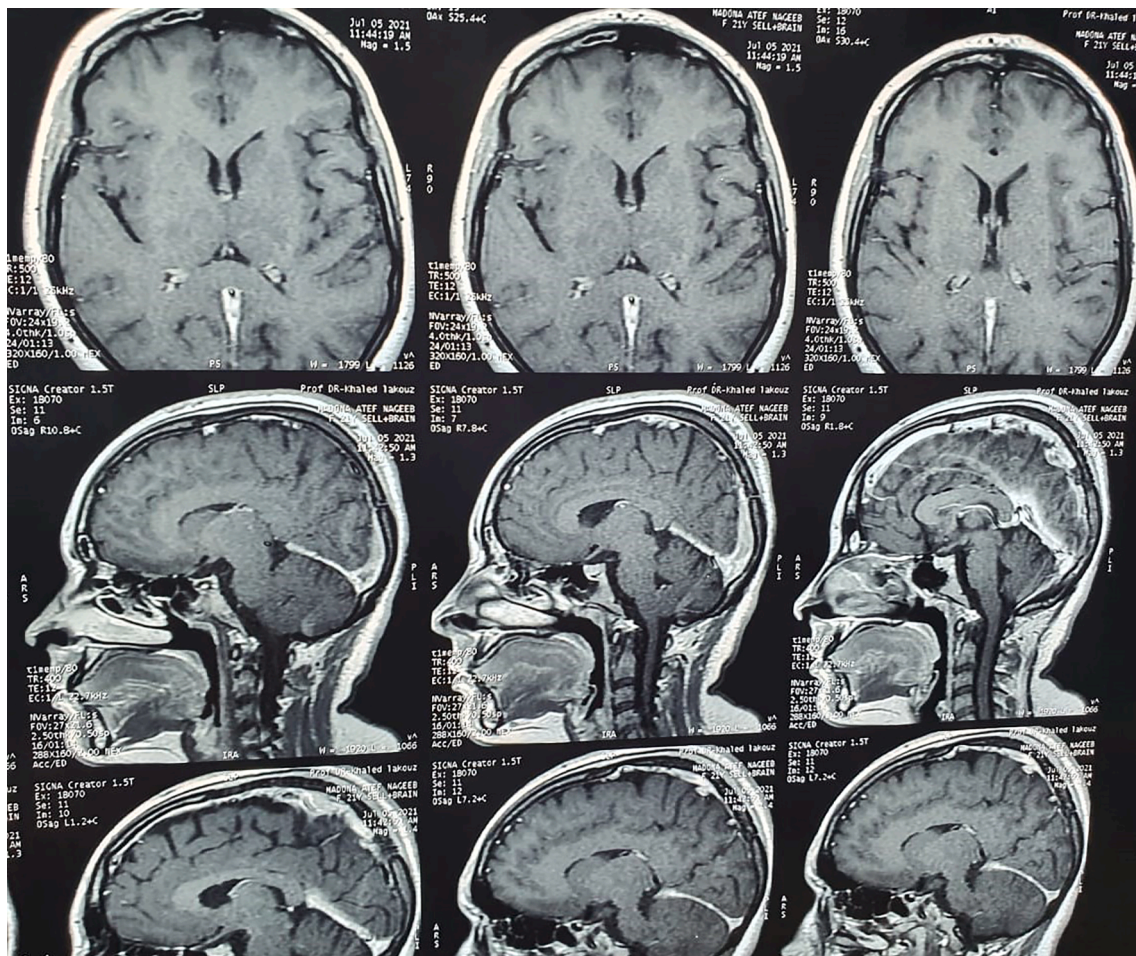


Fig. 5. MRI brain, axial and sagittal T1-weighted images thrombosed superior sagittal and straight sinuses (case II).

covid-19 infection as it showed multiple bilateral subpleural ground-glass opacities. Patient received immediate O<sub>2</sub> support through mask with a rate of 4 L/min that kept her O<sub>2</sub> saturation around 97%. COVID-19 protocol of medications was started including anticoagulation by intravenous heparin. Her general conditions started improvement, fever subsided and O<sub>2</sub> support was decreased to minimum with adequate O<sub>2</sub> saturation. On the 7th day, anticoagulation was stopped after improvement. Unfortunately, while preparing her for discharge on the 9th day of admission, she suddenly became unconscious with left side weakness, so she was intubated and transferred to ICU. Her Glasgow coma scale (GCS) score reached 5 + T. Urgent CT brain was done after stabilization of her conditions which showed hyperdensity at superior sagittal and right transverse sinuses (Fig. 1) associated with right parietal cortical and subcortical hypodense area, suggesting the picture of CVST with venous infarction. MRI brain was done which revealed right posterior parietal cerebral infarction (Fig. 2). MR venography (MRV) has also confirmed CVST at SSS, right TS, right sigmoid sinus and internal jugular vein (Fig. 3). Due to multi-sinus thrombosis and a very high D-dimer (4563 ng/mL), our decision was to start enoxaparin subcutaneously. After 3 days of this treatment, the patient regained her consciousness gradually, extubated on the 4th day of ICU admission, became fully conscious on 5th day. left hemiparesis started improvement during the next 2 days after regaining consciousness. Patient was discharged on 7th day of ICU admission after a negative Rt-PCR test for a nasopharyngeal swab. On discharge, enoxaparin was replaced by new oral anticoagulants (Apixaban) and patient was advised to start physiotherapy. 2 weeks from discharge patient came to our outpatient department (OPD) ambulating with no residual neurological deficit. The

patient came again after 2 months for follow up with no neurological symptoms or signs. MRI and MRV brain were done revealing patent all sinuses with complete recanalization as shown in Fig. 4.

## 2.2. Case II

A 21 years old, woman had a history of high fever, generalized muscle aches, and dry cough. She was screened for COVID-19 by rt-PCR test for a nasal swab on the 2nd day of her symptoms which was + ve, so she was advised for home isolation with medical symptomatic treatment as her symptoms were mild and O<sub>2</sub> saturation was 99%. Fever began to subside from 4th day and muscle aches gradually became better. Unfortunately, after 7 days from the start of her symptoms she developed a rapidly progressive severe headache, so she was presented to our emergency department asking for medical advice. Headache was described by the patient as bursting pain all over the head associated with repeated vomiting. There was no history of smoking, oral contraceptive pills or any medical problems. On examination, patient was conscious and alert (GCS = 15) but She had bilateral advanced papilloedema. Her vital sign were almost normal except mildly increased blood pressure (150/100 mmHg). Urgent CT brain was done showing hyperdense veins and sinuses at the right parietal lobe area, superior sagittal sinus (SSS), and straight sinus together with brain oedema which suggested the presence of CVST. So, she was admitted to isolation department where initial laboratory tests showed increased level of erythrocyte sedimentation rate (ESR) 67 mm/h, high leucocytic count ( $16 \times 10^3/L$ ) with neutrophil lymphocyte ratio (NLR) of 35, fibrinogen was 546 mg/dL and D-dimer 19546 ng/mL. MRI and MRV brain have

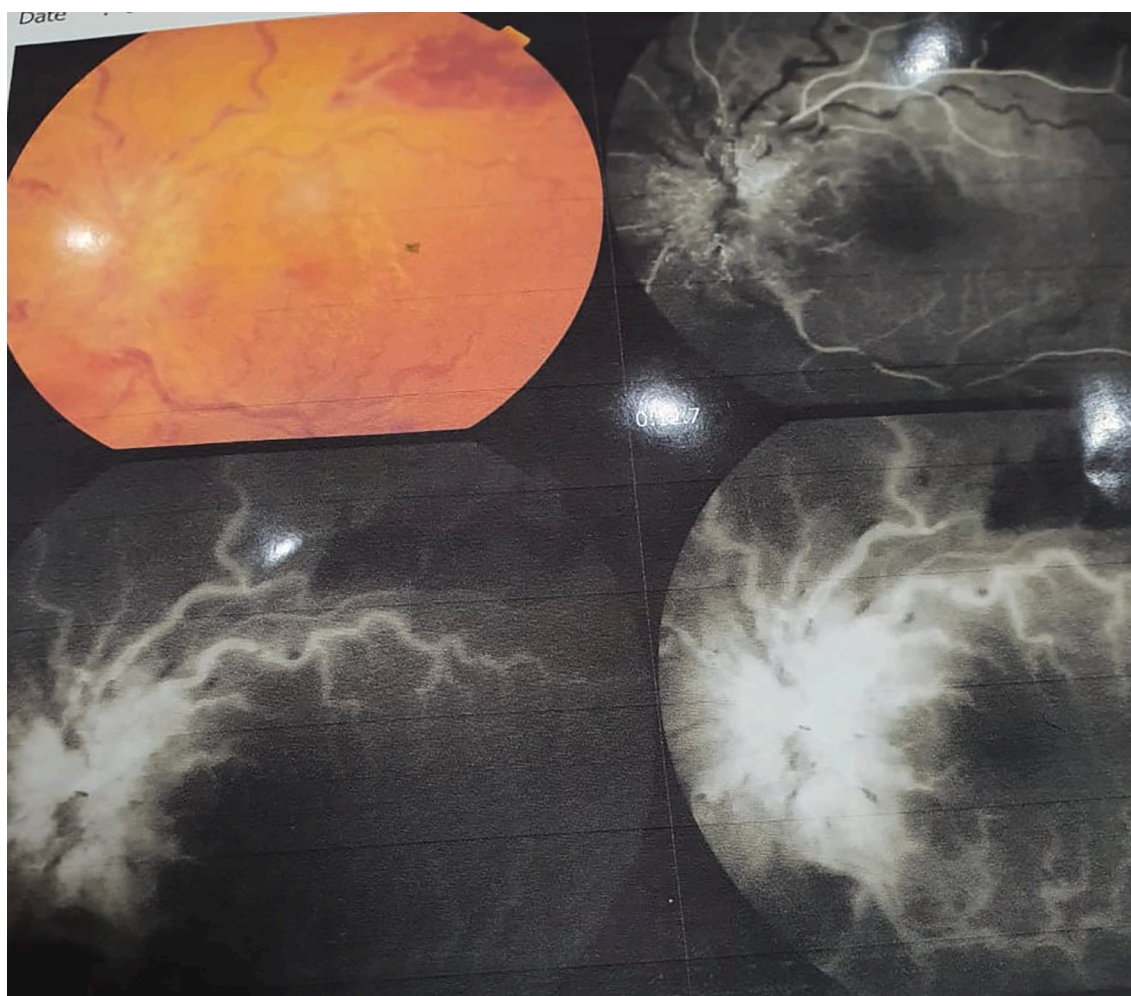


Fig. 6. Fundus camera showing advanced papilledema with retinal vein tortuosity and areas of micro-haemorrhages (case II).

confirmed CVST at SSS, straight sinus, bilateral TS, and bilateral sigmoid sinuses (Fig. 5). Fundus camera showed advanced bilateral papilledema with marked tortuosity of retinal veins and areas of haemorrhages (Fig. 6). Furthermore, the chest CT scan showed subpleural bilateral ground-glass opacities with a fibrotic appearance in the left lung. 80 mg subcutaneous enoxaparin was administered twice daily with acetazolamide TID for papilledema. After 7 days from admission, D-dimer decreased to 1985 ng/ml. So, we continued with enoxaparin until the D-dimer became normal and the patient showed negative rt-PCR test. Headache improved gradually and vomiting stopped. The patient was discharged from the hospital on the 14th day from admission on new oral anticoagulants (Apixaban). When she came for follow up after 2 months in our OPD she was conscious, alert with no neurological symptoms. MRI and MRV brain were done showing complete recanalization of all sinuses with normal brain.

### 3. Discussion

The outcome after CVST in COVID-19 patients has been recently better than before in the initial course of the pandemic due to better understanding of the pathogenesis of the virus behaviour in the human body, early detection of cases of arterial and venous thrombosis, and developing experience in management protocols. Several studies have reported significantly increased rates of venous and arterial thromboses in patients with COVID-19 despite administration of standard prophylaxis. However, CVST is still a rare cause of stroke, reported recently in context with SARS-CoV-2 [13–15]. COVID-19 infection and

hypercoagulability increases the risks of vein thromboembolism (VTE) especially pulmonary embolism (PE), stroke and disseminated intravascular coagulation (DIC) [2]. The presence of venous thromboembolism has been considered a main cause of death in COVID-19 patients [13,15].

There have been several proposed mechanisms of neurologic manifestations of CVST following infection with corona viruses in addition to mechanical ventilation, nutritional deficiencies, central venous access catheters, and immobilization as possible causes of hypercoagulability in critically ill patients [16,17].

Endothelial cells may initially be invaded by the virus through angiotensin converting enzyme (ACE) receptors [18]. The presence of viral elements within endothelial cells and an accumulation of inflammatory cells, with evidence of inflammatory cell death, have been discovered in patients with COVID-19 [17]. Inflammation of endothelial cells may cause cellular dysfunction, leading to either haemodynamic changes in vascular beds or disruption and fragmentation of stable atherosclerotic plaque through a thrombogenic microvascular environment, causing pulmonary embolism, myocardial infarction or stroke. Critical SARS-CoV-2 infection is almost always accompanied by a significant proinflammatory response, which can activate the coagulation cascade through various pathways, leading to a profound prothrombotic state. Furthermore, COVID-19 patients have diffuse inflammation, that activates the coagulation cascade with further consuming the clotting factors resulting in DIC [9]. This theory explains why some cases may be associated with brain haemorrhages.

SARS-CoV-2 infection has also been linked to alternative and lectin

complement cascade activation [19]. These complement complexes can deposit on endothelial cells, leading to cellular damage, and can initiate a thrombotic microangiopathy [20]. The presence of antiphospholipid antibodies and lupus antibodies has also been described in patients with COVID-19, though their clinical significance remains unknown [2].

Manifestations of CVST include symptoms and signs of increased intracranial pressure, encephalopathy or focal neurological deficit and can cause cerebral infarction and/or haemorrhage [21]. Because headache can be a common symptom of viral illnesses including COVID-19, diagnosis can often be elusive or delayed until symptoms worsen [22]. Patients with either no or minimal systemic and respiratory symptoms may first come to medical attention when they present with seizures or other symptoms attributed to the venous sinus thrombosis and are ultimately found to have COVID-19 infection [23]. As in second case in our report, CVST is an important diagnostic consideration in patients with headache and papilledema even without other neurological focal signs [24]. Headache, generally indicative of an increase in intracranial tension, is the most common symptom in CVST and was present in nearly 90% of patients [25].

Unlike non COVID-19 CVST, it is surprising that in a systematic review of patients with concomitant COVID-19 and CVST, a large majority were relatively young and healthy patients with relatively few co-morbidities [26].

Regarding neuroimaging features of patients with SARS-CoV-2 related CVST, most displayed hemorrhagic venous infarcts as the first imaging feature. Although it is quite a common finding even in other non-COVID-19-CVST cases [27].

Although, the treatment of COVID-19 associated CVST does not differ radically from therapy of CVST without the infection [27]. There is a great debate with the choice of proper anticoagulants in COVID-19 associated VTEs [28]. Both unfractionated heparin and low molecular weight heparins are used in the treatment of acute CVST. Emerging evidence suggests that various heparins can bind to the COVID-19 spike proteins, help downregulate IL-6, and directly dampen immune activation [5]. Theoretically this may be of clinical benefit. Alternative treatments that interact with the ACE2 receptors are also being postulated, although clinical trials have not yet occurred [29,30].

The mortality rate continues to decrease with the urgent use of anticoagulation therapy [31]. Pulmonary embolism, brain herniations due to brain edema, status epilepticus and medical complications are the main cause of early death after CVST [21].

#### 4. Conclusion

CVST is one of the serious neurological complications of COVID-19 infection, having a poor prognosis. Seizures, acute or subacute headache, encephalopathy or stroke-like symptoms in a patient with, or who has history of COVID-19, should prompt the treating physician to investigate for CVST. Early diagnosis by MRI and MRV and proper management may lead to better outcome.

#### 5. Declaration of patient consent

The authors certify that they have obtained all appropriate patient consent forms. In the form, the patient has given his consent for his images and other clinical information to be reported in the journal. The patient understands that his name and initials will not be published and due efforts will be made to conceal his identity, but anonymity cannot be guaranteed.

#### 6. Financial support and sponsorship

Nil.

#### Declaration of Competing Interest

The authors declare that they have no known competing financial interests or personal relationships that could have appeared to influence the work reported in this paper.

#### References

- [1] S. Devasagayam, B. Wyatt, J. Leyden, T. Kleinig, Cerebral venous sinus thrombosis incidence is higher than previously thought: a retrospective population-based study, *Stroke* 47 (9) (2016) 2180–2182.
- [2] Y. Zhang, M. Xiao, S. Zhang, P. Xia, W. Cao, W. Jiang, H. Chen, X. Ding, H. Zhao, H. Zhang, C. Wang, J. Zhao, X. Sun, R. Tian, W. Wu, D. Wu, J. Ma, Y.u. Chen, D. Zhang, J. Xie, X. Yan, X. Zhou, Z. Liu, J. Wang, B. Du, Y. Qin, P. Gao, X. Qin, Y. Xu, W. Zhang, T. Li, F. Zhang, Y. Zhao, Y. Li, S. Zhang, Coagulopathy and antiphospholipid antibodies in patients with COVID-19, *N. Engl. J. Med.* 382 (17) (2020) e38.
- [3] D.D. Cavalcanti, E. Raz, M. Shapiro, S. Dehkharghani, S. Yaghi, K. Lillemo, E. Nossek, J. Torres, R. Jain, H.A. Riina, A. Radmanesh, P.K. Nelson, Cerebral Venous Thrombosis Associated with COVID-19, *AJNR Am. J. Neuroradiol.* 41 (8) (2020) 1370–11136.
- [4] H.-Y. Wang, X.-L. Li, Z.-R. Yan, X.-P. Sun, J. Han, B.-W. Zhang, Potential neurological symptoms of COVID-19, *Ther. Adv. Neurol. Disord.* 13 (2020), 175628642091783.
- [5] B. Bikdeli, M.V. Madhavan, D. Jimenez, T. Chuich, I. Dreyfus, E. Driggin, et al., Global COVID-19 thrombosis collaborative group, *J. Am. Coll. Cardiol.* 75 (23) (2020 Jun 16) 2950–2973.
- [6] S. Nagashima, M.C. Mendes, A.P. Camargo Martins, N.H. Borges, T.M. Godoy, A.F. R.D.S. Miggiolaro, F. da Silva Dezidério, C. Machado-Souza, L. de Noronha, Endothelial dysfunction and thrombosis in patients with COVID-19—brief report, *Arterioscler. Thromb. Vasc. Biol.* 40 (10) (2020) 2404–2407.
- [7] D. Roy, R. Ghosh, S. Dubey, M.J. Dubey, J. Benito-Leon, R.B. Kanti, Neurological and neuropsychiatric impacts of COVID-19 pandemic, *Can. J. Neurol. Sci.* 48 (1) (2021) 9–24.
- [8] Q. Ye, B. Wang, J. Mao, The pathogenesis and treatment of the ‘Cytokine Storm’ in COVID-19, *J. Infect.* 80 (6) (2020) 607–613.
- [9] M. Levi, T. van der Poll, Inflammation and coagulation, *Crit. Care Med.* 38 (2) (2010) 26–34.
- [10] A.S. Manolis, T.A. Manolis, A.A. Manolis, D. Papatheou, H. Melita, COVID-19 infection: viral macro- and micro-vascular coagulopathy and thromboembolism/prophylactic and therapeutic management, *J. Cardiovasc. Pharmacol. Ther.* 26 (1) (2021) 12–24.
- [11] Kushner A, West WP. Triad PLSV 2020.
- [12] P.S. Idiculla, D. Gurala, M. Palanisamy, R. Vijayakumar, S. Dhandapani, E. Nagarajan, Cerebral venous thrombosis: a comprehensive review, *Eur. Neurol.* 83 (4) (2020) 369–379.
- [13] F.A. Klok, M.J.H.A. Kruip, N.J.M. van der Meer, M.S. Arbous, D.A.M.P.J. Gommers, K.M. Kant, F.H.J. Kaptein, J. van Paassen, M.A.M. Stals, M.V. Huisman, H. Endeman, Incidence of thrombotic complications in critically ill ICU patients with COVID-19, *Thromb. Res.* 191 (2020) 145–147.
- [14] C. Lodigiani, G. Iapichino, L. Carenzo, M. Cecconi, P. Ferrazzi, T. Sebastian, N. Kucher, J.-D. Studt, C. Sacco, A. Bertuzzi, M.T. Sandri, S. Barco, Venous and arterial thromboembolic complications in COVID-19 patients admitted to an academic hospital in Milan, Italy, *Thromb Res* 191 (2020) 9–14.
- [15] S. Middeldorp, M. Coppens, T.F. Haaps, M. Poppen, A.P. Vlaar, M.C.A. Müller, C.C. S. Bouman, L.F.M. Beenen, R.S. Kootte, J. Heijmans, L.P. Smit, P.I. Bonta, N. Es, Incidence of venous thromboembolism in hospitalized patients with COVID-19, *J. Thromb. Haemost.* 18 (8) (2020) 1995–2002.
- [16] M.Y. Abou-Ismaïl, A. Diamond, S. Kapoor, Y. Arafah, L. Nayak, The hypercoagulable state in COVID-19: incidence, pathophysiology, and management, *Thromb. Res.* 194 (2020) 101–115.
- [17] Y. Wu, X. Xu, Z. Chen, J. Duan, K. Hashimoto, L. Yang, C. Liu, C. Yang, Nervous system involvement after infection with COVID-19 and other coronaviruses, *Brain Behav. Immun.* 87 (2020) 18–22.
- [18] L. Chen, X. Li, M. Chen, Y.i. Feng, C. Xiong, The ACE2 expression in human heart indicates new potential mechanism of heart injury among patients infected with SARS-CoV-2, *Cardiovasc. Res.* 116 (6) (2020) 1097–1100.
- [19] C. Magro, J.J. Mulvey, D. Berlin, G. Nuovo, S. Salvatore, J. Harp, A. Baxter-Stoltzfus, J. Laurence, Complement associated microvascular injury and thrombosis in the pathogenesis of severe COVID-19 infection: a report of five cases, *Transl. Res.* 220 (2020) 1–13.
- [20] M. Noris, M. Galbusera, S. Gastoldi, P. Macor, F. Banterla, E. Bresin, C. Tripodo, S. Bettoni, R. Donadelli, E. Valoti, F. Tedesco, A. Amore, R. Coppo, P. Ruggenenti, E. Gotti, G. Remuzzi, Dynamics of complement activation in aHUS and how to monitor eculizumab therapy, *Blood* 124 (11) (2014) 1715–1726.
- [21] G. Saposnik, F. Barinagarrementeria, R.D. Brown Jr, C.D. Bushnell, B. Cucchiara, M. Cushman, G. deVeber, J.M. Ferro, F.Y. Tsai, Diagnosis and Management of Cerebral Venous Thrombosis: A Statement for Healthcare Professionals from the American Heart Association/American Stroke Association, *Stroke* 42 (4) (2011) 1158–1192.
- [22] Q. Ruan, K. Yang, W. Wang, L. Jiang, J. Song, Clinical predictors of mortality due to COVID-19 based on an analysis of data of 150 patients from Wuhan, China, *Intensive Care Med.* 46 (5) (2020) 846–848.

- [23] Y.C. Li, W.Z. Bai, T. Hashikawa, The neuroinvasive potential of SARSCoV2 may play a role in the respiratory failure of COVID-19 patients, *J. Med. Virol.* 92 (2020) 552–555.
- [24] S. Appenzeller, C.B. Zeller, J.M. Annichino-Bizzachi, L.T.L. Costallat, L. Deus-Silva, B. Voetsch, A.V. Faria, V.A. Zanardi, B.P. Damasceno, F. Cendes, Cerebral venous thrombosis: influence of risk factors and imaging findings on prognosis, *Clin. Neurol. Neurosurg.* 107 (5) (2005) 371–378.
- [25] J.M. Ferro, Patrícia Canhão, J. Stam, M.-G. Bousser, F. Barinagarrementeria, Prognosis of cerebral vein and dural sinus thrombosis: results of the International Study on Cerebral Vein and Dural Sinus Thrombosis (ISCVT), *Stroke* 35 (3) (2004) 664–670.
- [26] T.M. Tu, C. Goh, Y.K. Tan, A.ST. Leow, Y.Z. Pang, J. Chien, H. Shafi, B.PL. Chan, A. Hui, J. Koh, B.YQ. Tan, N.T. Umaphathi, L.LL. Yeo, Cerebral Venous Thrombosis in Patients with COVID-19 Infection: a Case Series and Systematic Review, *J. Stroke Cerebrovasc. Dis.* 29 (12) (2020), 105379.
- [27] R. Ghosh, D. Roy, A. Mandal, S.K. Pal, B. Chandra Swaika, D. Naga, A. Pandit, B. K. Ray, J. Benito-León, Cerebral venous thrombosis in COVID-19, *Diabetes Metab. Syndr.* 15 (3) (2021) 1039–1045.
- [28] J.M. Ferro, J.M. Coutinho, F. Dentali, A. Kobayashi, A. Alasheev, P. Canhão, D. Karpov, S. Nagel, L. Posthuma, J.M. Roriz, J. Caria, M. Frässdorf, H. Huisman, P. Reilly, H.-C. Diener, Safety and efficacy of dabigatran etexilate vs dose-adjusted warfarin in patients with cerebral venous thrombosis, *JAMA Neurol* 76 (12) (2019) 1457.
- [29] T. Jiang, L. Gao, J. Lu, Y.-D. Zhang, ACE2-Ang-(1–7)-Mas axis in brain: a potential target for prevention and treatment of ischemic stroke, *Curr. Neuropharmacol.* 11 (2) (2013) 209–217.
- [30] K. Kuba, Y. Imai, S. Rao, et al., A crucial role of angiotensin converting enzyme 2 (ACE2) in SARS coronavirus induced lung injury, *Nat. Med.* 11 (8) (2005) 875–879.
- [31] J.M. Coutinho, S.M. Zuurbier, M. Aramideh, J. Stam, The incidence of cerebral venous thrombosis: a cross-sectional study, *Stroke* 43 (12) (2012) 3375–3377.