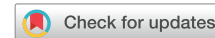

# Cardiac memory presenting as ST elevations following premature ventricular complex ablation



Asim Kichloo, MD,<sup>\*†1</sup> Abdul Qadir Haji, MD, FHRS,<sup>†1</sup> Khalil Kanjwal, MD, FHRS<sup>§1</sup>

From the <sup>\*</sup>Department of Internal Medicine, Samaritan Medical Center, Watertown, New York, <sup>†</sup>Department of Internal Medicine, Central Michigan University, Saginaw, Michigan, <sup>‡</sup>Department of Cardiology, Martinsburg VA Medical Center, Martinsburg, West Virginia, and <sup>§</sup>Department of Electrophysiology, McLaren Greater Lansing Hospital, Lansing, Michigan.

## Introduction

We report on a patient who developed electrocardiographic changes of cardiac memory (CM) presenting as ST elevations following ablation of premature ventricular complexes (PVC). In this report we attempt to explain the possible mechanism and causes of ST-segment elevation in patients during radiofrequency ablation. We believe this is a first reported case of CM presenting as ST elevation following ablation of PVC.

## Case report

A 69-year-old woman with a history of hypertension was evaluated in our arrhythmia clinic for palpitations and fatigue. She was having symptoms of palpitations and fatigue for 3 months. She was initially seen in her primary care physician's office and an electrocardiogram (ECG) performed revealed sinus rhythm and frequent PVC. She was referred to our arrhythmia clinic for management of PVC. Her complete blood count, comprehensive metabolic panel, and thyroid function tests were reported normal. She had an echocardiogram, which revealed ejection fraction of 45% and a stress test, which was reported normal. In our office her ECG showed ventricular bigeminy with PVC having morphology of inferior axis and qR pattern in V<sub>1</sub> with early transition (Figure 1). These ECG features were suggestive of left sided, outflow, or aortomitral continuity origin of PVC. A 24-hour Holter monitor revealed PVC burden of 33% (31,000/day). Given her high PVC burden and PVC-induced cardiomyopathy, she was offered PVC ablation. After explanation of the risks and benefits of the procedure, the patient decided to pursue ablation.

**KEYWORDS** Cardiac memory; ST elevation; T-wave inversion; Premature ventricular complex; PVC ablation (Heart Rhythm Case Reports 2021;7:52–55)

All the authors report no conflict of interest. This research did not receive any specific grant from funding agencies in the public, commercial, or not-for-profit sectors. <sup>1</sup>All authors contributed equally to the manuscript.

**Address reprint requests and correspondence:** Dr Khalil Kanjwal, Clinical Associate Professor of Medicine, Michigan State University, McLaren Greater Lansing Hospital, Lansing, MI 48901. E-mail address: [Khalil.kanjwal@mclaren.org](mailto:Khalil.kanjwal@mclaren.org).

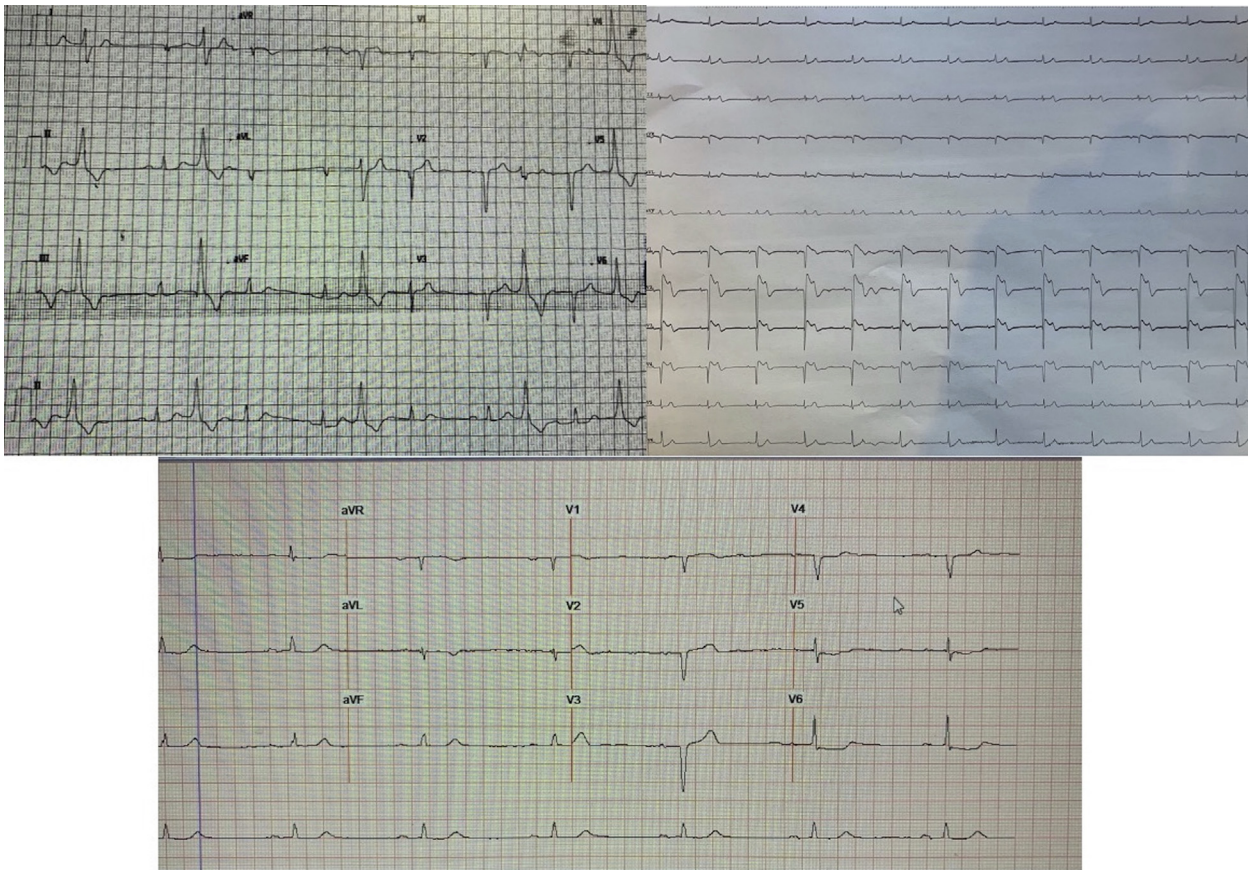
## KEY TEACHING POINTS

- Cardiac memory (CM) commonly presents as T-wave inversions and can be confused with ischemic T-wave changes.
- CM can also present as ST-segment elevation and can mimic acute myocardial infarction (AMI) when the clinical situation would not support AMI.
- ST-segment memory resolves much sooner when compared to T-wave memory.

## Procedure

After the informed consent was obtained, the patient was brought to the electrophysiology laboratory in the postabsorptive state. Using ultrasound guidance, the sheath and catheters were inserted into the femoral veins bilaterally and the right femoral artery. An electrode catheter was placed in the right ventricle and a CARTOSOUND mapping catheter (Biosense Webster, Diamond Bar, CA) was advanced in the right atrium. A sound map of the various cardiac structure including right ventricular outflow tract, left ventricular outflow tract, coronary cusps, and aortomitral continuity (AMC) was obtained. Heparin boluses were administered, and the ACT was maintained between 250 and 300 seconds throughout the case. Subsequently a PentaRay catheter (Biosense Webster) was advanced and a detailed activation map of the right ventricular outflow tract, coronary cusps, left ventricular outflow tract, and AMC was obtained. Activation map revealed a pre-QRS signal (>30 ms) with a QS pattern noted on a unipolar signal in the area of AMC (Figure 2). Ablation was performed using a 3.5 mm irrigated force sense catheter using 35 watts of power and the PVC was abolished immediately. The ablation was continued for 60 seconds, followed by an insurance burn for 30 seconds.

After the PVC were eliminated the patient had ST elevation mostly noted in anterior leads (Figure 1). The patient was awake and completely asymptomatic. An urgent cardiac



**Figure 1** **Top left:** Electrocardiogram (ECG) showed ventricular bigeminy with premature ventricular complexes (PVC) having morphology of inferior axis and qR pattern in  $V_1$  with early transition. **Top right:** Post-PVC ablation ECG, showing ST elevation mostly noted in anterior leads ( $V_1$ – $V_4$ ). **Bottom:** A repeat ECG 4 hours after the ablation, showing sinus bradycardia and complete resolution of ST elevations.

catheterization revealed normal coronary anatomy. An echocardiogram showed no wall motion abnormality.

The patient was subsequently started on high-dose isuprel (max 20 mcg/min). After a wait period of 60 minutes, the patient remained in sinus rhythm and without any PVC. A repeat ECG 4 hours later showed sinus bradycardia and complete resolution of ST elevations (Figure 1). The patient remained completely asymptomatic and was discharged from the hospital with a follow-up in the arrhythmia office in 1 month.

## Discussion

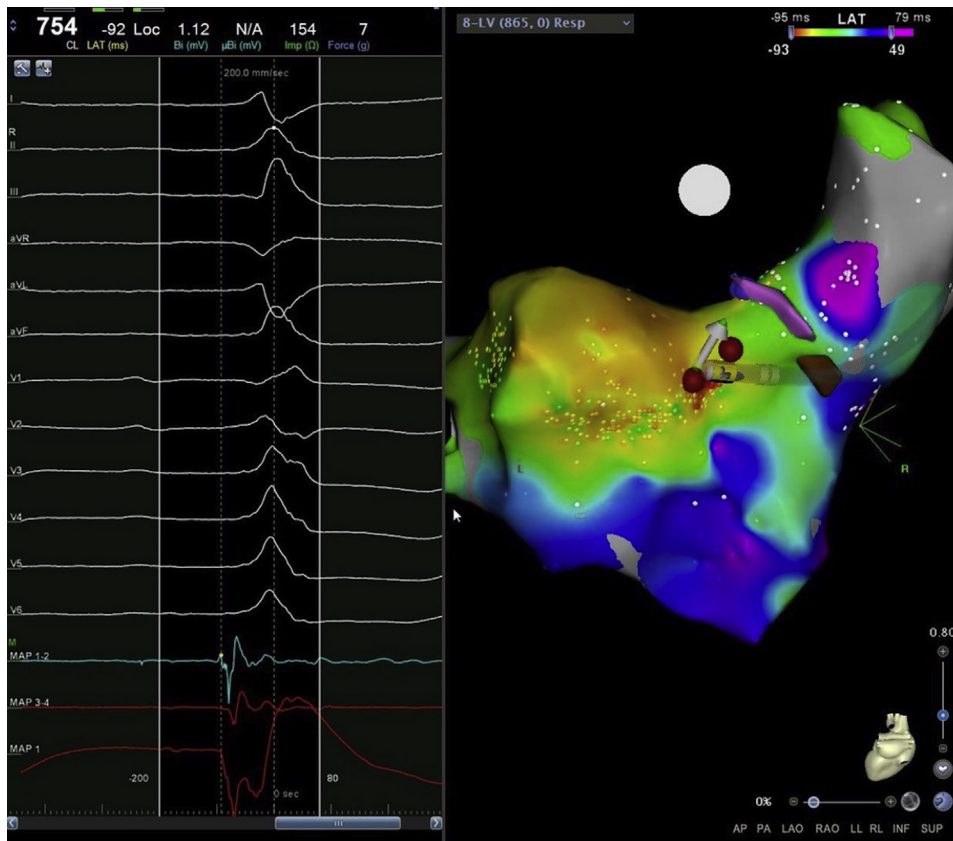
The term “cardiac memory” and its main attributes were formulated by Rosenbaum and colleagues<sup>1</sup> in 1982. During CM the T-wave vector in sinus rhythm aligns with the vector of the previous “abnormal,” usually wide, QRS complex; the amplitude of the memory T wave increases with increased duration of the prior abnormal activation; and after normalization of the T wave, repeated episodes of abnormal activation result in a faster and more marked appearance of CM changes.<sup>2</sup>

CM commonly presents as T-wave inversions (TWI), which is often confused as ischemic T-wave changes. Inability to recognize and distinguish CM from ischemia can lead to extensive but unnecessary cardiac and ischemic

diagnostic testing and prolonged hospital stays. There are various cardiac conditions that are associated with CM. Among those, CM is often due to ventricular paced rhythm, PVC, intermittent left bundle branch block, Wolff-Parkinson-White syndrome, and ventricular tachycardia.<sup>3,4</sup> However, White<sup>5</sup> in 1915 reported a first case of CM presenting as TWI following a single PVC.

CM presenting as ST elevation has been reported previously in a patient with paced rhythm, where the authors report the ST elevation and biphasic T waves in the inferior leads followed a preceding abnormal right ventricular paced rhythm.<sup>6</sup> In contrast, our patient had ventricular bigeminy on presentation to the electrophysiology laboratory. Like a T-wave memory, we believe there is an ST-segment memory as well. This became evident when PVC (wide QRS complexes) were eliminated and sinus rhythm was restored. These ST-segment elevations were worrisome, and a coronary angiogram was performed to rule out an injury to the coronary artery. There was no evidence of vasospasm, dissection, thrombus, or stenosis noted, making ablation-induced coronary artery injury unlikely. The patient remained completely asymptomatic and there was no wall motion abnormality noted on an echocardiogram.

ST elevation during radiofrequency ablations have been reported in the past following direct injury to right coronary



**Figure 2** Activation map of the left ventricular outflow tract and aortomitral continuity (AMC) was obtained and revealed a pre-QRS signal (>30 ms) with a QS pattern noted on unipolar signal in AMC area. Ablation in this area immediately eliminated the premature ventricular complexes.

artery during ablation of cavotricuspid isthmus and AV node reentry tachycardia, during transeptal puncture, during reversal of heparin with protamine, and during ablation in the area of the ganglionic plexus in the left atrium.<sup>7–10</sup> The other possibilities could have been air embolism or Brugada-like ECG changes. However, lack of chest pain in the setting of ST elevation lasting for 4 hours makes the diagnosis of air embolism unlikely. A normal transthoracic echocardiogram without any regional wall motion abnormality would also argue against the diagnosis of air embolism. Our patient had 24-hour Holter monitors both before and after the procedures. There was no evidence of any transient ST elevation noted on Holter monitoring. Usually, Brugada changes can be seen up to lead V<sub>3</sub>; however, in our patient ST elevation seen in lead V<sub>4</sub> as well.

As there was no other reasonably plausible explanation for the ST elevation, we believe that these abnormalities represented ST-segment memory. Also, resolution of these abnormalities over a period of a few hours would support CM as a likely reason for ST-segment elevation in our patient.

CM has been described as a remodeling phenomenon of cardiac repolarization in response to abnormal ventricular depolarization.<sup>11</sup> CM is associated with the phenomenon of “accumulation,” meaning that the severity and duration of preceding depolarization abnormality is proportional to repolarization abnormality. Depending on the duration, the

CM can be classified as short term or long term. The molecular mechanism for short-term CM has been linked to the mechanical stretch owing to abnormal depolarization, which is further mediated by angiotensin receptor II–induced changes in outward potassium (I<sub>to</sub>), the rectifier current (I<sub>kr</sub>), and L-type calcium currents (I<sub>ca</sub>).<sup>11–13</sup> As the ventricular depolarization abnormalities continue, there is gene expression and transcription of ion channels and gap junctions. These adaptive changes contribute to long term CM by causing action potential gradient between early and late activated areas of myocardium, which further causes altered T-wave vector, which may last weeks to months. The ST elevation subsided within a few hours; thus it represents a “short-term” form of a CM. In an earlier report on ST elevation presenting as CM, Bode and colleagues<sup>6</sup> also reported that compared to CM of TWI, ST elevation lasts only a few hours, which is consistent with the observations in our patient. The electrocardiographic manifestations of CM (ST elevation) in our case, as well as the earlier reported case mentioned above, were seen only when the depolarization abnormalities (PVC in our case) resolved.

To the best of our knowledge and the review of literature, we believe that this is the first case reported wherein CM presented as ST elevation rather than TWIs following ablation of PVC. We also noted that the ST-segment elevation CM resolved within a few hours only, unlike TWI memory, which can take more time (often weeks) to resolve.

## Conclusion

CM mimicking acute myocardial infarction–like ST elevations can follow ablation of PVC and should be considered if other ominous causes have been ruled out.

## Acknowledgments

Ethics Approval: Our institution does not require ethical approval for reporting individual cases or case series.

Informed Consent: Verbal informed consent was obtained from the patient for her anonymized information.

## References

1. Rosenbaum MB, Blanco HH, Elizari MV, et al. Electrotonic modulation of the T wave and cardiac memory. *Am J Cardiol* 1982;50:213–222.
2. Rakočević R, Thomas R, Oriscello RG. Clinical dilemma - cardiac memory vs myocardial ischemia. *Cureus* 2020;12:e7129.
3. Herweg B, Fisher JD, Ilercil A, et al. Cardiac memory after radiofrequency ablation of accessory pathways: the post-ablation T wave does not forget the pre-excited QRS. *J Interv Card Electrophysiol* 1999;3:263–272.
4. Gould L, Venkataraman K, Goswami MK, Gomprecht RF. Pacemaker-induced electrocardiographic changes simulating myocardial infarction. *Chest* 1973; 63:829–832.
5. White P. Alteration of the pulse: a common clinical condition. *Am J Med Sci* 1915;150:82–96.
6. Bode M, Bode W. Cardiac memory presenting as ST elevation. *J Am Coll Cardiol* 2018;71(11 Supplement):A2592.
7. Al Aloul B, Sigurdsson G, Can I, Li JM, Dykoski R, Tholakanahalli VN. Proximity of right coronary artery to cavotricuspid isthmus as determined by computed tomography. *Pacing Clin Electrophysiol* 2010;33:1319–1323.
8. Chacko M, Marrouche NF, Bhatt DL. Asymptomatic acute inferior ST elevation myocardial infarction from thermal injury complicating radiofrequency ablation for atrioventricular re-entrant tachycardia. *J Invasive Cardiol* 2004; 16:504–505.
9. Soos MP, Madala MC, Kanjwal K. Transient inferior lead ST elevation during radiofrequency ablation of atrial fibrillation. *J Atr Fibrillation* 2020;12:2293.
10. Kanjwal K, Mughal M, Shah I, Madala MC. Hypotension and transient ST elevation after reversal of heparin with protamine. *Am J Ther* 2019; 26:e646–e647.
11. Jeyaraj D, Ashwath M, Rosenbaum DS. Pathophysiology and clinical implications of cardiac memory. *Pacing Clin Electrophysiol* 2010;33:346–352.
12. Özgen N, Rosen MR. Cardiac memory: a work in progress. *Heart Rhythm* 2009; 6:564–570.
13. Shvilkin A, Huang HD, Josephson ME. Cardiac memory: diagnostic tool in the making. *Circ Arrhythm Electrophysiol* 2015;8:475–482.