

# Evaluation of skeletal maturation using mandibular third molar development in Indian adolescents

Nishit Mehta, Dolly Patel<sup>1</sup>,  
Falguni Mehta<sup>2</sup>,  
Bhaskar Gupta<sup>3</sup>,  
Grishma Zaveri<sup>4</sup>,  
Unnati Shah<sup>5</sup>

*Department of Orthodontics, Government Dental College, Ahmedabad, <sup>1</sup>Department of Orthodontics, AMC Dental College and Hospital, <sup>2</sup>Department of Orthodontics, Government Dental College and Hospital, Ahmedabad, Gujarat, <sup>3</sup>Department of Orthodontics, Jaipur Dental College and Hospital, Jaipur, Rajasthan, India, <sup>4</sup>DDS Student, University of Pacific, Arthur A Dugoni School of Dentistry, San Francisco, <sup>5</sup>DDS Student, UCLA School of Dentistry, Los Angeles, USA*

**Address for correspondence:**  
Dr. Nishit Mehta,  
1, Gyandip Society,  
Dhumketu Road, Paldi,  
Ahmedabad - 380 007,  
Gujarat, India.  
E-mail: drnishitmehta@yahoo.  
co.in

## Introduction

The optimal timing for treatment in dentofacial orthopedics is linked intimately to the identification of periods of accelerated or intense growth that contribute significantly to the correction of skeletal imbalances in an individual patient. Precise evaluation

## Abstract

**Objective:** This study was done with the following objectives: to estimate dental maturity using the Demirjian Index (DI) for the mandibular third molar; to investigate the relationship between dental maturity and skeletal maturity among growing patients; to evaluate the use of the mandibular third molar as an adjunctive tool for adolescent growth assessment in combination with the cervical vertebrae; to evaluate the clinical value of the third molar as a growth evaluation index. **Materials and Methods:** Samples were derived from panoramic radiographs and lateral cephalograms of 615 subjects (300 males and 315 females) of ages ranging 9-18 years, and estimates of dental maturity (DI) and skeletal maturity [cervical vertebrae maturation indicators (CVMI)] were made.

**Results:** A highly significant association ( $r = 0.81$  for males and  $r = 0.72$  for females) was found between DI and CVMI. DI Stage B corresponded to Stage 2 of CVMI (prepeak of pubertal growth spurt) in both sexes. In males, DI stages C and D represent the peak of the pubertal growth spurt. In females, stages B and C show that the peak of the pubertal growth spurt has not been passed. DI stage E in females and DI Stage F in males correlate that the peak of the pubertal growth spurt has been passed.

**Conclusion:** A highly significant association exists between DI and CVMI. Mandibular third molar DI stages are reliable adjunctive indicators of skeletal maturity.

**Key words:** Dental maturity, lateral cephalogram, mandibular third molar, orthopantomogram, skeletal maturity


of the developmental stage forms an integral part of both diagnosis and treatment plan for pediatric patients.<sup>[1]</sup> Different authors have advocated various methods of determining skeletal maturity based on radiographs of specific structures, such as epiphysis-diaphysis fusion of long bones,<sup>[2,3]</sup> medial extremity of the clavicle,<sup>[4]</sup>

This is an open access article distributed under the terms of the Creative Commons Attribution-NonCommercial-ShareAlike 3.0 License, which allows others to remix, tweak, and build upon the work non-commercially, as long as the author is credited and the new creations are licensed under the identical terms.

**For reprints contact:** reprints@medknow.com

**How to cite this article:** Mehta N, Patel D, Mehta F, Gupta B, Zaveri G, Shah U. Evaluation of skeletal maturation using mandibular third molar development in Indian adolescents. J Forensic Dent Sci 2016;8:112-3.

### Access this article online

<b>Website:</b> www.jfds.org	<b>Quick Response Code</b>
<b>DOI:</b> 10.4103/0975-1475.186372	

epiphyseal head of the first rib,<sup>[5]</sup> epiphyseal union of the anterior iliac crest,<sup>[6]</sup> and fusion of the sphenoid bone with the basilar part of the occipital bone.<sup>[7-9]</sup> However, these skeletal methods not only present some inconveniences in view of the variability of bone maturation, as influenced by environmental factors,<sup>[10]</sup> but necessitate additional radiographs as well. The hand-wrist radiograph has been one of the most commonly used methods for skeletal developmental assessment.<sup>[11]</sup>

Panoramic and lateral cephalometric radiographs form a part of essential diagnostic examination for the comprehensive diagnosis and treatment planning of an orthodontic patient. Apart from its use in studying skeletal, dental, and soft-tissue structures, the usefulness of lateral cephalometric radiographs for assessing maturation has also been studied.<sup>[12-24]</sup> A distinct advantage of cervical maturity evaluation is that it does not entail extra radiation exposure for the orthodontic patient. Hand-wrist and cervical maturation methods are highly correlated, therefore it does not justify to take an extra hand wrist radiograph for skeletal maturation determination.<sup>[15-18,23]</sup> Hassel and Farman<sup>[12]</sup> suggested six stages of classification of the cervical vertebrae based on the shape of the second to the fourth vertebrae on lateral cephalogram.

Apart from viewing maxillomandibular structures, an orthopantomogram can also be used to assess the dental maturity of the patient. Dental development can be assessed from either the phase of tooth eruption or the stage of tooth calcification, with the latter being more reliable.<sup>[25,26]</sup> Demirjian *et al.*<sup>[26]</sup> proposed a method for estimation of the subject's dental maturity based on eight calcification stages, which span from the first sign of tooth calcification to apex closure for the seven left permanent mandibular teeth. However, short time intervals between different developmental stages may adversely affect the possibility of identifying the relationship between tooth development and maturation.<sup>[27]</sup> The third molar offers a unique advantage over other teeth because its development tends to continue for a longer period and until a later age (8-18 years). Most patients undergoing orthodontic treatment belong to this group. The continuation of third molar development during adolescence provides a different point of reference from the other teeth. If a positive correlation between third molar development and general growth can be evaluated, it would be possible to use the third molar as a growth indicator in pubertal patients.

This study has been conducted to estimate dental maturity using the Demirjian Index (DI) for the mandibular third molar, to investigate the relationships between dental maturity and cervical vertebral skeletal maturity among growing patients, and to evaluate the clinical value of the third molar as a growth evaluation index.

## Aims and Objectives

The aims and objectives of this study were:

- To estimate dental maturity using the DI for the mandibular third molar
- To investigate the relationship between dental maturity and skeletal maturity among growing patients
- To evaluate the use of the mandibular third molar as an adjunctive tool for assessment of adolescent growth in combination with cervical vertebrae
- To evaluate the clinical value of the third molar as a growth evaluation index.

## Materials and Methods

The samples were derived from panoramic, lateral cephalometric radiographs of 300 male and 315 female subjects registered as patients at the Department of Orthodontics at Government Dental College and Hospital, Ahmedabad, Gujarat, India. The age range of the sample in females was 9-18 years with the mean age of 14 years, and in males was 10-18 years with the mean age of 13.4 years.

### Selection criteria

The following criteria in individuals were used for the selection of subjects:

- Well-nourished and free of any known serious disease
- Normal growth and dental development; no missing teeth or supernumerary teeth
- No congenital oral or maxillofacial anomalies such as cleft lip and palate.

### Dental maturity evaluation on panoramic radiograph

In this study, the lower left third molar has been used as a sample because of higher estimation errors in calculating the maturation of the upper molar than the lower molar. The root of the upper third molar may overlap with anatomic structures such as the palate, the inferior border of the zygomatic arch, or the maxillary sinus septum. Therefore, it can be difficult to observe the root. Cases in which the development of the left and right third molars differed remarkably or in which developmental anomalies were observed were excluded. Tooth calcification was rated according to the method described by Demirjian *et al.*,<sup>[26]</sup> in which one of eight stages of calcification (A to H) was assigned to the third molar tooth [Table 1 and Figure 1].

### Cervical vertebrae maturity evaluation on lateral cephalogram

The cervical vertebrae maturation indicators (CVMI) were evaluated by dividing the second, third, and fourth vertebrae into six groups depending on their maturation patterns on lateral cephalogram using the classification of Hassel and Farman<sup>[12]</sup> [Table 2 and Figure 2].

**Table 1: Dental calcification stages using DI**

Stage A	Calcification of single occlusal points without fusion of different calcifications
Stage B	Fusion of mineralization points; the contour of the occlusal surface is recognizable
Stage C	Enamel formation has been completed at the occlusal surface, and dentin formation has commenced. The pulp chamber is curved, and no pulp horns are visible
Stage D	Crown formation has been completed to the level of the cemento-enamel junction. Root formation has commenced. The pulp horns are beginning to differentiate, but the walls of the pulp chamber remain curved
Stage E	The root length remains shorter than the crown height. The walls of the pulp chamber are straight, and the pulp horns have become more differentiated than in the previous stage. In molars the radicular bifurcation has begun to calcify
Stage F	The walls of the pulp chamber now form an isosceles triangle, and the root length is equal to or greater than the crown height. In molars bifurcation has developed sufficiently to give the roots a distinct form
Stage G	The walls of the root canal are now parallel, but the apical end is partially open. In molars only the distal root is rated
Stage H	The root apex is completely closed (distal root in molars). The periodontal membrane surrounding the root and apex is uniform in width throughout

DI: Demirjian index

**Table 2: CVMI**

Initiation	Very significant amount of adolescent growth expected C2, C3, and C4 inferior vertebral body borders are flat Superior vertebral borders are tapered posterior to anterior
Acceleration	Significant amount of adolescent growth expected Concavities developing in lower borders of C2 and C3 Lower border of C4 vertebral body is flat C3 and C4 are more rectangular in shape
Transition	Moderate amount of adolescent growth expected Distinct concavities in lower borders of C2 and C3 C4 developing concavity in lower border of body C3 and C4 are rectangular in shape
Deceleration	Small amount of adolescent growth expected Distinct concavities in lower borders of C2, C3, and C4 C3 and C4 are nearly square in shape
Maturation	Insignificant amount of adolescent growth expected Accentuated concavities of inferior vertebral body borders of C2, C3, and C4 C3 and C4 are square in shape
Completion	Adolescent growth is completed Deep concavities are present in inferior vertebral body borders of C2, C3, and C4 C3 and C4 heights are greater than widths

CVMI: Cervical vertebrae maturation indicators

Each sample is assigned DI (A to H) based on the mandibular third molar development and cervical maturation stage based on skeletal maturation.

All the data thus compiled from the lateral cephalogram and panoramic radiographs of the samples were subjected to appropriate statistical analysis.

### Statistical analysis

We performed statistical analysis using Microsoft Office Excel 2007 (Microsoft) and IBM - SPSS version 22 software (IBM Inc.). The mean values of chronologic age in males and females were calculated at each stage of the DI. The median values of CVMI stages were calculated at each stage of the DI in males and females. To study the relationship between DI and the CVMI, the frequency and the percentage distribution of the stages of calcification were recorded for each tooth, and these were calculated separately for male and female subjects. Cross-tabular statistics were performed. The Pearson Chi-square test ( $\chi^2$ ) value and correlation coefficient ( $r$ ) were estimated to determine the relationships between DI and CVMI. Independent sample  $t$ -tests were performed for comparison of mean age at different stages of DI between males and females.

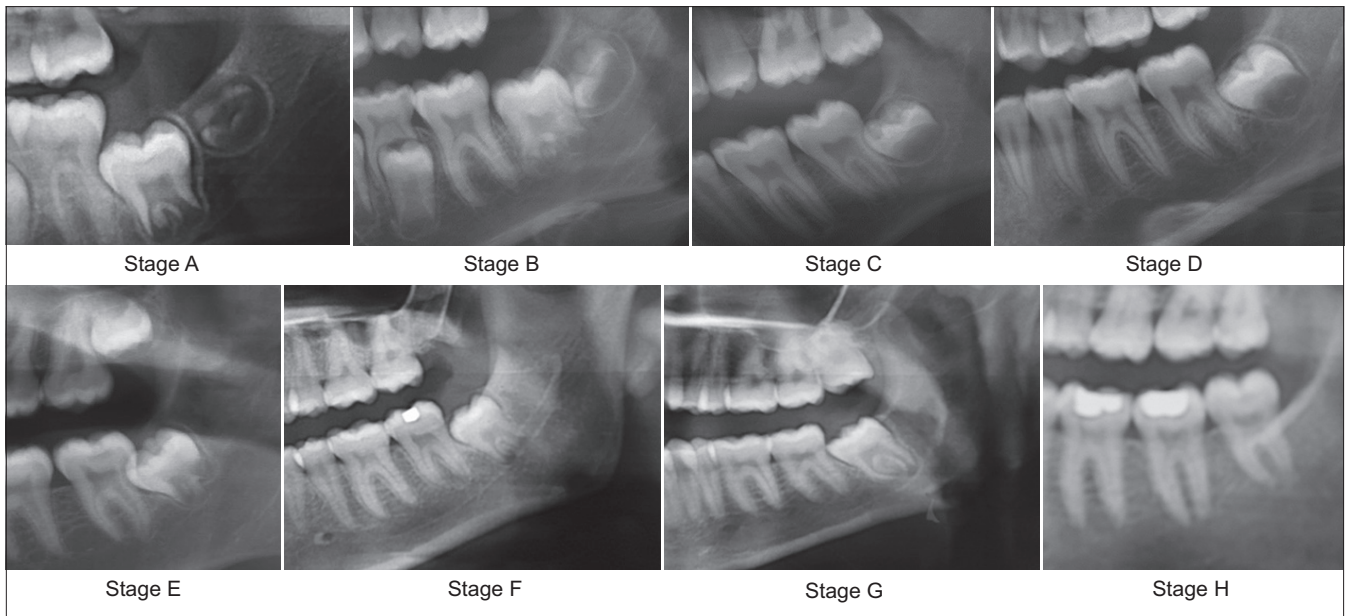
### Results

Tables 3 and 4 show the mean age for each stage of DI in males and females, respectively. Although the mean ages at different stages of DI individually indicate that lower third molar development is completed earlier in males than in females, it was statistically insignificant except in Stage D [Table 5].

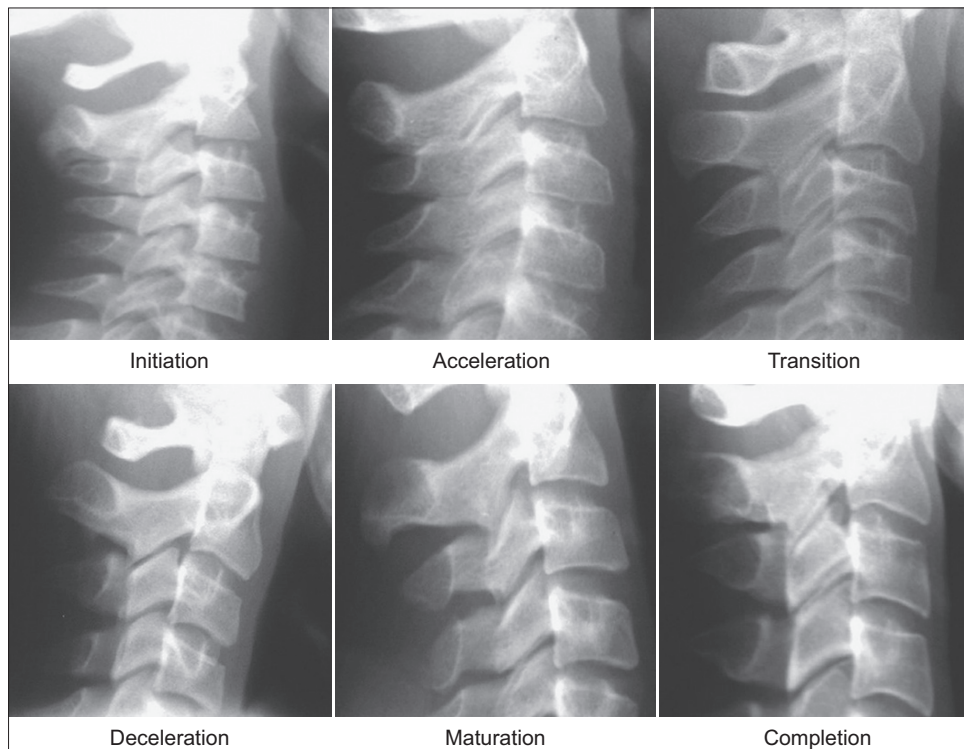
In this study, the results of the Chi-square test show the statistically significant interdependence of DI and CVMI in males ( $P < 0.0001$ ) [degree of freedom (df) = 35] [Table 6] as well as in females ( $P < 0.0001$ ) (df = 28) [Table 7].

There was found a statistically significant positive correlation between the development of the third molar (DI) and CVMI in both males ( $r = 0.81$ ) ( $P < 0.0001$ ) and females ( $r = 0.72$ ) ( $P < 0.0001$ ). DI and mean age also have a high positive correlation in both males ( $r = 0.79$ ) ( $P < 0.0001$ ) and females ( $r = 0.80$ ) ( $P < 0.0001$ ). In addition, CVMI and mean age have a high positive correlation in both males ( $r = 0.84$ ) ( $P < 0.0001$ ) and females ( $r = 0.84$ ) ( $P < 0.0001$ ) [Tables 8 and 9].

In males, distribution of CVMI to DI [Table 10] shows that DI Stage B is characterized by their concentration of CVMI Stage 2 (66.7%), DI Stage C is characterized by their concentration of CVMI Stage 3 (60.0%), and DI Stage D is characterized by their concentration of CVMI Stage 3 (40.9%) and Stage 4 (50%). In females, distribution of CVMI



**Figure 1:** Dental calcification stages using the DI



**Figure 2:** CVMI

stage to DI [Table 11] shows that DI Stage B is characterized by their concentration of CVMI Stage 2 (42.9%) and Stage 3 (42.9%), DI Stage C is characterized by their concentration of CVMI Stage 3 (53.3%) and Stage 4 (33.3%), DI Stage D is characterized by their concentration of CVMI Stage 4 (31.8%) and Stage 5 (43.2%), and DI Stage E is characterized by their concentration of CVMI Stage 5 (42.9%) and Stage 6 (42.9%).

## Discussion

Maturation indices have been proposed to evaluate skeletal maturity in the growing patient when planning orthodontic/orthopedic treatment or for clinical and research purposes. The ease of recognizing the stages of dental development and the availability of panoramic radiography are practical reasons for attempting to assess physiologic

**Table 3: Mean chronological age along with the development of the third molar (DI) (male)**

DI	N	Mean	Std. Deviation
A	6	11.4000	0.38471
B	54	12.1167	0.93016
C	120	12.8575	0.94732
D	66	13.8682	1.02103
E	39	15.3154	1.00434
F	9	15.8000	0.70887
G	3	17.3000	0.20000
H	3	17.9000	0.10000
Total	300	13.4200	1.55984

DI: Demirjian index

**Table 4: Mean chronological age along with the development of the third molar (DI) (female)**

DI	N	Mean	Std. Deviation
A	3	9.1000	0.30000
B	21	11.7286	0.99154
C	90	12.8400	0.77703
D	132	14.3364	1.14253
E	42	15.6929	1.16124
F	21	16.1571	0.70326
G	3	17.4000	0.10000
H	3	18.0000	0.20000
Total	315	14.0514	1.71747

DI: Demirjian index

**Table 5: Comparison of the mean age between males and females at different stages of DI**

DI	Male			Female			P value	Significance S/NS
	N	Mean	Std. Deviation	N	Mean	Std. Deviation		
A	6	11.40	0.38	3	9.10	0.30	<0.0001	S
B	54	12.12	0.93	21	11.73	0.99	0.115	NS
C	120	12.86	0.95	90	12.84	0.78	0.887	NS
D	66	13.87	1.02	132	14.34	1.14	0.005	S
E	39	15.32	1.00	42	15.69	1.16	0.123	NS
F	9	15.80	0.71	21	16.16	0.70	0.214	NS
G	3	17.30	0.20	3	17.40	0.10	0.482	NS
H	3	17.90	0.10	3	18.00	0.20	0.482	NS

S: Statistically significant, NS: Statistically not significant

maturity without resorting to hand-wrist radiograph. The “As Low As Reasonably Achievable” (ALARA) principle is especially important for children and young adults, and thus high-radiation methods should not be used frequently to assess growth.

Dental maturity, in particular, has an advantage of being easily evaluable during regular dental treatment.<sup>[28]</sup> Dental maturity is determined by the stage of tooth eruption or the stage of tooth formation. Chertkow<sup>[29]</sup> indicated that the completion of root formation in the mandibular canines prior to apical closure may be used clinically as a maturity indicator for pubertal growth spurts with the

**Table 6: Interdependence between DI and CVMI (male), Chi-square test**

	Value	df	P value
Pearson’s Chi-square	416.225	35	<0.0001

Level of significance 5%. DI: Demirjian index; CVMI: Cervical vertebrae maturation indicators

**Table 7: Interdependence between DI and CVMI (female), Chi-square test**

	Value	df	P value
Pearson’s Chi-square	296.161	28	<0.0001

Level of significance 5%. DI: Demirjian index; CVMI: Cervical vertebrae maturation indicators

**Table 8: Correlation between DI, CVMI, and chronological age (male), Pearson correlation statistical test**

	DI	CVMI	Age
Pearson correlation (r)			
DI	1	0.809	0.786
CVMI	0.809	1	0.840
Age	0.786	0.840	1
N	300	300	300

Level of significance 5%. DI: Demirjian index; CVMI: Cervical vertebrae maturation indicators

**Table 9: Correlation between DI, CVMI, and chronological age (female)**

	DI	CVMI	Age
Pearson correlation (r)			
DI	1	0.723	0.801
CVMI	0.723	1	0.845
Age	0.801	0.845	1
N	315	315	315

Level of significance 5%. DI: Demirjian index; CVMI: Cervical vertebrae maturation indicators

same degree of confidence as the indicators described for hand-wrist radiographs among white children. However, root formation and apex closure of mandibular canines are completed by the age of 13 years, and most children exhibit active growth up to the age of 16-17 years.<sup>[30]</sup> A study by Bolanos *et al.*<sup>[31]</sup> showed that the root formation of the third molar is complete at an average of 18.5 years. The third molar has a unique feature compared to other teeth in that its development tends to continue over a long period and until a later age. The continuation of third molar development during adolescence provides a different point of reference from the other teeth.<sup>[28]</sup> Recent studies have verified that Demirjian’s classification system shows the least intraexaminer and interexaminer errors and a high correlation with biological age.<sup>[28]</sup> Therefore, dental maturity in this study was determined by evaluating the stages of tooth formation of the third molar by Demirjian’s method.

The results also show a statistically significant positive correlation between dental maturity (DI) and skeletal

**Table 10: Frequency distribution of CVMI by DI (male)**

	CVMI						Total
	1	2	3	4	5	6	
DI							
A							
Count	0	6	0	0	0	0	6
% within DI	0.0	100.0	0.0	0.0	0.0	0.0	100.0
B							
Count	6	36	12	0	0	0	54
% within DI	11.1	66.7	22.2	0.0	0.0	0.0	100.0
C							
Count	0	39	72	9	0	0	120
% within DI	0.0	32.5	60.0	7.5	0.0	0.0	100.0
D							
Count	0	0	27	33	6	0	66
% within DI	0.0	0.0	40.9	50.0	9.1	0.0	100.0
E							
Count	0	0	9	12	12	6	39
% within DI	0.0	0.0	23.1	30.8	30.8	15.4	100.0
F							
Count	0	0	0	0	6	3	9
% within DI	0.0	0.0	0.0	0.0	66.7	33.3	100.0
G							
Count	0	0	0	0	0	3	3
% within DI	0.0	0.0	0.0	0.0	0.0	100.0	100.0
H							
Count	0	0	0	0	0	3	3
% within DI	0.0	0.0	0.0	0.0	0.0	100.0	100.0
Total							
Count	6	81	120	54	24	15	300
% within DI	2.0	27.0	40.0	18.0	8.0	5.0	100.0

DI: Demirjian index; CVMI: Cervical vertebrae maturation indicators

maturity (CVMI) consistent with the findings of Engstrom et al.,<sup>[27]</sup> Krailassiri et al.,<sup>[11]</sup> Uysal et al.,<sup>[32]</sup> and Kalinowska et al.,<sup>[1]</sup> who also have suggested a strong relationship between dental maturity and skeletal maturity.

For both sexes, DI Stage B showed the highest percentage distribution at Stage 2 of CVMI [Tables 10 and 11]. The relationship between skeletal maturity and peak height velocity (PHV) is well established.<sup>[33-35]</sup> Fishman<sup>[33]</sup> and Hagg and Taranger<sup>[34]</sup> found that the appearance of the adductor sesamoid of the thumb indicates the beginning of the pubertal growth spurt (onset of PHV), which corresponds to Stage 2 of CVMI.<sup>[24]</sup> In the present study, Stage 2 of CVMI corresponded with DI Stage B in both males and females. Hence, DI Stage B signifies the prepeak of the pubertal growth spurt or onset of PHV in both the sexes.

In the present study, for male subjects, stages C and D corresponded to CVMI Stage 3 [Table 10], while for female subjects, stages B and C corresponded to CVMI Stage 3 [Table 11]. Bjork and Helm<sup>[35]</sup> found that the MP3cap stage heralds the peak of the pubertal growth spurt, which

**Table 11: Frequency distribution of CVMI by DI (female)**

	CVMI					Total
	2	3	4	5	6	
DI						
A						
Count	3	0	0	0	0	3
% within DI	100.0	0.0	0.0	0.0	0.0	100.0
B						
Count	9	9	3	0	0	21
% within DI	42.9	42.9	14.3	0.0	0.0	100.0
C						
Count	9	48	30	3	0	90
% within DI	10.0	53.3	33.3	3.3	0.0	100.0
D						
Count	0	12	42	57	21	132
% within DI	0.0	9.1	31.8	43.2	15.9	100.0
E						
Count	0	0	6	18	18	42
% within DI	0.0	0.0	14.3	42.9	42.9	100.0
F						
Count	0	0	0	12	9	21
% within DI	0.0	0.0	0.0	57.1	42.9	100.0
G						
Count	0	0	0	0	3	3
% within DI	0.0	0.0	0.0	0.0	100.0	100.0
H						
Count	0	0	0	0	3	3
% within DI	0.0	0.0	0.0	0.0	100.0	100.0
Total						
Count	21	69	81	90	54	315
% within DI	6.7	21.9	25.7	28.6	17.1	100.0

DI: Demirjian index; CVMI: Cervical vertebrae maturation indicators

corresponds to Fishman's<sup>[33]</sup> skeletal maturity indicator 6 (stage 3 of the CVMI<sup>[24]</sup>). It can be inferred that DI stages C and D in males represent the peak of the pubertal growth spurt, while DI stages B and C in females show that the peak of the pubertal growth spurt has not been passed.

In this study in males, the samples in Demirjian stages E or above are predicted to occur at the stages higher than CVMI Stage 3, and the samples in Demirjian stages F are predicted to occur at the stages higher than CVMI Stage 4 [Table 10]. In females, the samples in Demirjian stages E or above are predicted to occur at stages higher than CVMI Stage 4 [Table 11]. In contrast to the study by Sun-Mi Cho et al.<sup>[28]</sup> where it was shown that in females, the samples in Demirjian stages E or above are predicted to occur at the higher stages of CVMI Stage 5. Thus it can be concluded that in females DI Stage E and in males DI Stage F correlate that the peak of the pubertal growth spurt has been passed.

The mean ages at different stages of DI individually indicate that lower third molar development is complete earlier in males than in females, but it is statistically insignificant

except for Stage D, which signifies the peak of the pubertal growth spurt in males. This finding is consistent with the results of Bolanos *et al.*,<sup>[31]</sup> which showed for males and females similar age distribution, mean age, and developmental stages, with negligible differences in the mean degree of formation of the four molars. However, findings by Mincer *et al.*,<sup>[36]</sup> Solari *et al.*,<sup>[37]</sup> Sisman *et al.*,<sup>[38]</sup> and Golovcencu *et al.*<sup>[39]</sup> showed that lower third molar development is complete earlier in males than in females.

The revealed correlation between lower third molar development and skeletal maturity in this study will allow clinicians to use the mandibular third molar as an adjunctive tool to assess adolescent growth, in combination with cervical vertebrae evaluations. Individual variations should be taken into consideration when using the developmental stage of the third molar in growth evaluations, as third molars are known for their many variations, based on previous studies. This cross-sectional study has limitations in terms of the evaluation of results because the subjects in this study were in the pubertal growth period and mainly concentrated in DI stages C, D, and E. Increasing the number of subjects in each stage would further increase the accuracy of results obtained. Further longitudinal study with a larger sample size is recommended for establishing specific guidelines to use the DI of the mandibular third molar for growth assessment.

## Conclusion

- Both males and females show statistically significant positive correlation between the development of the third molar (DI) and CVMI
- DI stage B signifies the prepeak of pubertal growth spurt in both males and females
- In males, DI stages C and D represent the peak of the pubertal growth spurt
- In females, stages B and C correlate that the peak of the pubertal growth spurt has not been passed
- DI Stage E in females and DI Stage F in males correlate that the peak of the pubertal growth spurt has been passed
- Both sexes present similar developmental pace of the third molar, except for DI Stage D in males that signifies the peak of puberty.

Dental maturity evaluation using the mandibular third molar can be used as an adjunctive tool for adolescent growth assessment in clinical orthodontics.

## Financial support and sponsorship

Nil.

## Conflicts of interest

There are no conflicts of interest.

## References

1. Różyło-Kalinowska I, Kolasa--Rączka A, Kalinowski P. Relationship between dental age according to Demirjian and cervical vertebrae maturity in Polish children. *Eur J Orthod* 2011;33:75-83.
2. Greulich WW, Pyle SI. *Radiographic Atlas of Skeletal Development of the Hand and Wrist*. 2<sup>nd</sup> ed. Stanford: Stanford University Press; 1959.
3. Banerjee KK, Agarwal BB. Estimation of age from epiphyseal union at the wrist and ankle joints in the capital city of India. *Forensic Sci Int* 1998;98:31-9.
4. Kreitner KF, Schweden FJ, Riepert T, Nafe B, Thelen M. Bone age determination based on the study of the medial extremity of the clavicle. *Eur Radiol* 1998;8:1116-22.
5. Kunos CA, Simpson SW, Russell KF, Hershkovitz I. First rib metamorphosis: Its possible utility for human age-at-death estimation. *Am J Phys Anthropol* 1999;110:303-23.
6. Webb PA, Suchey JM. Epiphyseal union of the anterior iliac crest and medial clavicle in a modern multiracial sample of Americans males and females. *Am J Phys Anthropol* 1985;68:457-66.
7. Coben SE. The speno-occipital synchondrosis: The missing link between the profession's concept of craniofacial growth and orthodontic treatment. *Am J Orthod Dentofacial Orthop* 1998;114:709-14.
8. Meneses M, Laude M, Casero LG. Age of closure of the speno-occipital junction of the clivus, Determination by MRI. *Bull Assoc Anat (Nancy)* 1994;78:27-9.
9. Sahni D, Jit I, Neelam S, Suri S. Time of fusion of the basisphenoid with the basilar part of the occipital bone in northwest Indian subjects. *Forensic Sci Int* 1998;98:41-5.
10. Chaillet N, Willems G, Demirjian A. Dental maturity in Belgian children using Demirjian's method and polynomial functions: New standard curves for forensic and clinical use. *J Forensic Odontostomatol* 2004;22:18-27.
11. Krailassiri S, Anuwongnukroh N, Dechkunakorn S. Relationships between dental calcification stages and skeletal maturity indicators in Thai Individuals. *Angle Orthod* 2002;72:156-66.
12. Hassel B, Farman AG. Skeletal maturation evaluation using cervical vertebrae. *Am J Orthod Dentofacial Orthop* 1995;107:58-66.
13. García-Fernandes P, Torre H, Flores L, Rea J. The cervical vertebrae as maturational indicators. *J Clin Orthod* 1998;32:221-5.
14. Baccetti T, Franchi L, McNamara JA Jr. An improved version of the cervical vertebral maturation (CVM) method for the assessment of mandibular growth. *Angle Orthod* 2002;72:316-23.
15. Mito T, Sato K, Mitani H. Cervical vertebral bone age in girls. *Am J Orthod Dentofacial Orthop* 2002;122:380-5.
16. Flores-Mir C, Burgess CA, Champney M, Jensen RJ, Pitcher MR, Major PW. Correlation of skeletal maturation stages determined by cervical vertebrae and hand-wrist evaluations. *Angle Orthod* 2006;76:1-5.
17. Soegiharto BM, Moles DR, Cunningham SJ. Discriminatory ability of the skeletal maturation index and the cervical vertebrae maturation index in detecting peak pubertal growth in Indonesian and white subjects with receiver operating characteristics analysis. *Am J Orthod Dentofacial Orthop* 2008;134:227-37.
18. San Román P, Palma JC, Oteo MD, Nevado E. Skeletal maturation determined by skeletal vertebrae development. *Eur J Orthod* 2002;24:303-11.
19. Gandini P, Mancini M, Andreani F. A comparison of hand-wrist bone and cervical vertebral analyses in measuring skeletal maturation. *Angle Orthod* 2006;76:984-9.
20. Alkhal HA, Wong RW, Rabie AB. Correlation between

- chronological age, cervical vertebral maturation and Fishman's skeletal maturity indicators in southern Chinese. *Angle Orthod* 2008;78:591-6.
21. Santiago RC, da Miranda Costa LF, Vitral RW, Fraga MR, Bolognese AM, Maia LC. Cervical vertebral maturation as a biologic indicator of skeletal maturity. *Angle Orthod* 2012;82:11123-31.
  22. Lamparski D. *Skeletal Age Assessment Utilizing Cervical Vertebrae*. Pittsburgh: University of Pittsburgh; 1972.
  23. Rasool G, Bashir U, Kundi IU. Comparative evaluation between cervical vertebrae and hand-wrist maturation for assessment of skeletal maturity in orthodontic patients. *Pak Oral Dental J* 2010;30:85-95.
  24. Kamal M, Ragini, Goyal S. Comparative evaluation of hand wrist radiographs with cervical vertebrae for skeletal maturation in 10-12 years old children. *J Indian Soc Pedod Prev Dent* 2006;24:124-35.
  25. Nolla CM. The development of the permanent teeth. *J Dent Child* 1960;27:254-63.
  26. Demirjian A, Goldstein H, Tanner JM. A new system of dental age assessment. *Hum Biol* 1973;45:211-27.
  27. Engström C, Engström H, Sagne S. Lower third molar development in relation to skeletal maturity and chronological age. *Angle Orthod* 1983;53:97-106.
  28. Cho SM, Hwang CJ. Skeletal maturation evaluation using mandibular third molar development in adolescents. *Korean J Orthod* 2009;39:120-9.
  29. Chertkow S. Tooth mineralization as an indication of the pubertal growth spurt. *Am J Orthod* 1980;77:79-91.
  30. Kumar S, Singla A, Sharma R, Viridi M, Anupam A, Mittal B. Skeletal maturation evaluation using mandibular second molar calcification stages. *Angle Orthod* 2012;82:501-6.
  31. Bolanos MV, Moussa H, Manrique MC, Bolaños MJ. Radiographic evaluation of third molar development in Spanish children and young people. *Forensic Sci Int* 2003;133:212-9.
  32. Uysal T, Sari Z, Ramoglu SI, Basciftci FA. Relationships between dental and skeletal maturity in Turkish subjects. *Angle Orthod* 2004;74:657-64.
  33. Fishman LS. Radiographic evaluation of skeletal maturation. A clinically oriented method based on hand-wrist films. *Angle Orthod* 1982;52:88-112.
  34. Hagg U, Taranger J. Maturation indicators and the pubertal growth spurt. *Am J Orthod* 1982;82:299-309.
  35. Björk A, Helm S. Prediction of the age of maximum pubertal growth in body height. *Angle Orthod* 1967;37:134-43.
  36. Mincer HH, Harris EF, Berryman HE. The A.B.F.O. study of third molar development and its use as an estimator of chronological age. *J Forensic Sci* 1993;38:379-90.
  37. Solari AC, Abramovitch K. The accuracy and precision of third molar development as an indicator of chronological age in Hispanics. *J Forensic Sci* 2002;47:531-5.
  38. Sisman Y, Uysal T, Yagmur F, Ramoglu SI. Third-molar development in relation to chronologic age in Turkish children and young adults. *Angle Orthod* 2007;77:1041-6.
  39. Golovcencu L, Scripcaru C, Zegan G. Third molar development in relation to chronological age in Romanian children and young adults. *Rom J Leg Med* 2009;17:277-82.