

## Introduction

The safety and efficacy of carotid artery stenting (CAS) with the use of emboli protection devices (EPDs) have been demonstrated in the treatment of atherosclerotic carotid artery disease (CAD) (1). CAS has even recently become more popular than carotid endarterectomy (CEA) in the treatment of CAD thanks to newly developed techniques, including open or closed cell stents and protection devices, as well as special wires and catheters (1-3). Cerebral EPDs reduce the incidence of peri-procedural embolic events in patients undergoing CAS (4). Several EPDs have been designed and marketed so far. Distal emboli protection (filter) devices (d-EPD) and proximal emboli protection devices (p-EPD) are the two most frequently used EPDs systems (5). The Mo.Ma device (Medtronic Inc., Santa Rosa, CA, USA), which was approved by the Food and Drug Administration in 2009, is a p-EPD commonly used in high-risk patients for the protection from cerebrovascular embolic events (6). Although the Mo.Ma device was substantially successful, it may lead to some complications, including arterial vasospasm and arterial dissection during the inflation of the proximal and distal balloon (6). Here we present a serious common carotid artery dissection as a result of using the Mo.Ma device during CAS.

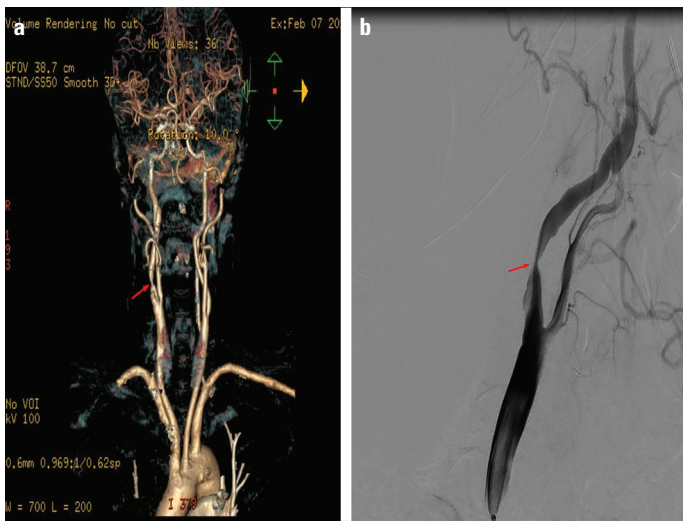
## Case Report

A 60-year-old man with a history of CAD, hypertension, and smoking, and a transient ischemic attack with left hemiparesis 2 weeks before was referred to our clinic for CAS. His blood pressure was 120/70 mmHg, and the pulse rate was 85 bpm. A neurological examination did not show any significant findings, except a murmur on the right carotid artery. Other systemic examinations were also normal. The electrocardiogram showed a normal sinus rhythm. Computed tomography (CT) demonstrated a 95% stenosis in the right internal carotid artery (RICA) (Fig. 1a). After an informed consent form was obtained, the patient was transferred to the angiography unit for CAS. Diagnostic angiography showed a severe stenosis in RICA, which was defined as 95% stenosis according to the North American Symptomatic Carotid Endarterectomy Trial classification (Fig. 1b). The rest of extracranial cerebral arteries were normal. In addition, there was no baseline carotid dissection in axial CT imaging (Fig. 2).

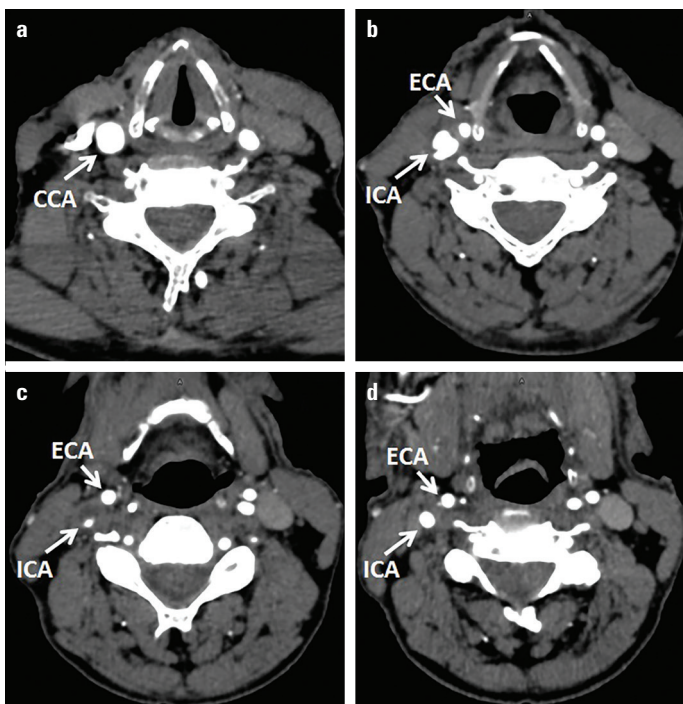
CAS was planned for the patient in index procedure. After 5000 units of heparin was given intravenously, the right common carotid artery was cannulated with a 5F Simmons catheter via the transfemoral approach. The external carotid artery (ECA) was wired with a 0.035" hydrophilic wire, and the 5F Simmons catheter was advanced in there. The hydrophilic wire was exchanged with super stiff wire. After the Mo.Ma device was prepared, it was positioned in the right ECA and CCA behind the lesion, aiming to close all side branches in ECA. After the ECA

## Unusual complication of carotid artery stenting as the result of a proximal emboli protection device (the Mo.Ma): Iatrogenic common carotid artery dissection

**Fatih Güngören\***, **Fezullah Beşli\***, **Zülkif Tanrıverdi\***,  
**Özcan Kocatürk\*\***, **Mustafa Beğenç Taşcanov\***  
Departments of \*Cardiology, and \*\*Neurology, Faculty of Medicine,  
Harran University; Şanlıurfa-Turkey



**Figure 1.** (a) 95% stenosis in the right internal carotid artery in computed tomography and (b) diagnostic angiography

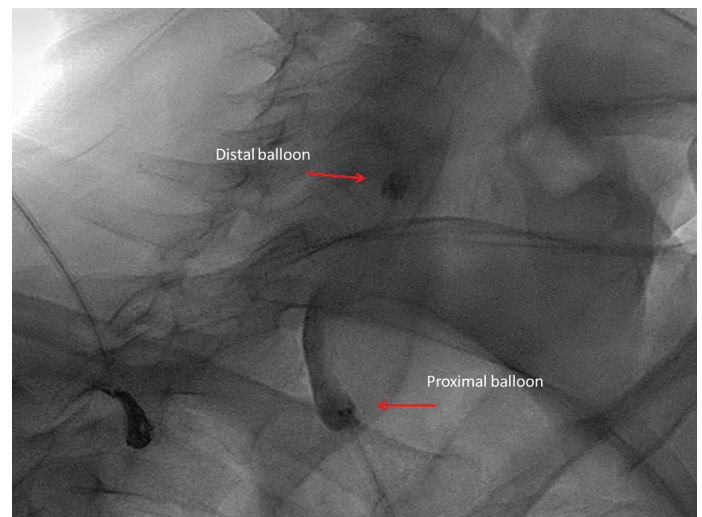


**Figure 2.** Pre-procedural axial computed tomography imaging. There was no baseline carotid dissection in axial CT images

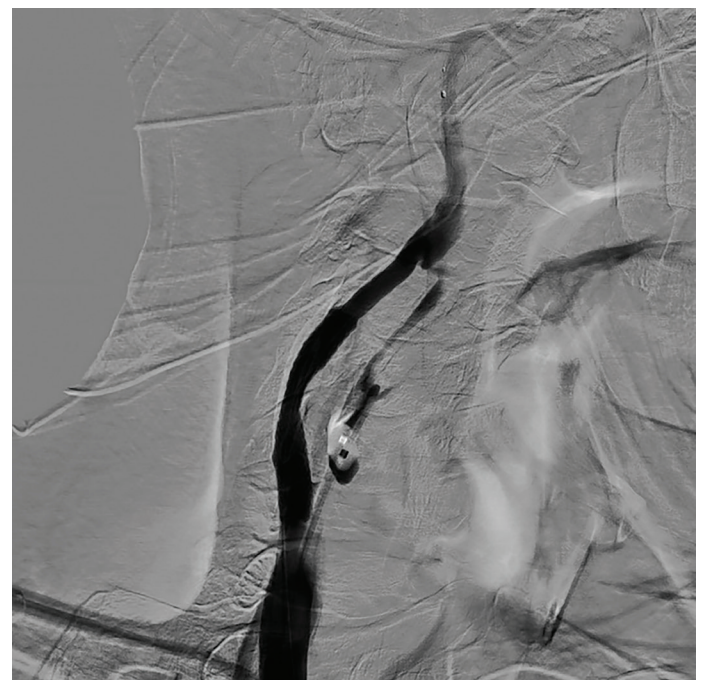
occlusion was verified by a low-dose contrast injection, the CCA balloon was inflated (Fig. 3). Inflating of the balloon was stopped when the shape of balloon turned to the cylindrical form from spheric form. It was also confirmed with low-dose contrast injection that the balloons in CCA blocked the flow in antegrade and retrograde. However, the patient could not tolerate it due to hemodynamic instability, where the carotid pressure decreased to 10–15 mm Hg. Because the patient was unable to tolerate it, the CCA balloon was deflated immediately. Then, the use of a distal protection device was decided. A 0.014" guide wire was advanced through the lesion and positioned in the distal ICA, and

5.0 spider FX (Medtronic, Minneapolis, MN, USA) was deployed as over the wire. A 8×40 mm Cordis Precise Nitinol Stent (Cordis) was implanted to the lesion after a 5×30 mm balloon pre-dilatation. There was an adequate flow in ICA, and the residual lesion was less than 30%, so post-dilatation was not performed (Fig. 4). After the procedure, the patient's clinical status and neurologic examination were normal. He was transferred to the coronary care unit. He was discharged on the 2nd day. Aspirin 100 mg/day plus clopidogrel 75 mg/day had been started for 1 week before stenting and planned to continue 1 month after the procedure.

The patient was admitted with localized and slight neck pain 2 weeks after CAS. Carotid doppler ultrasonography indicated the dissection extended from the mid-CCA to the beginning of

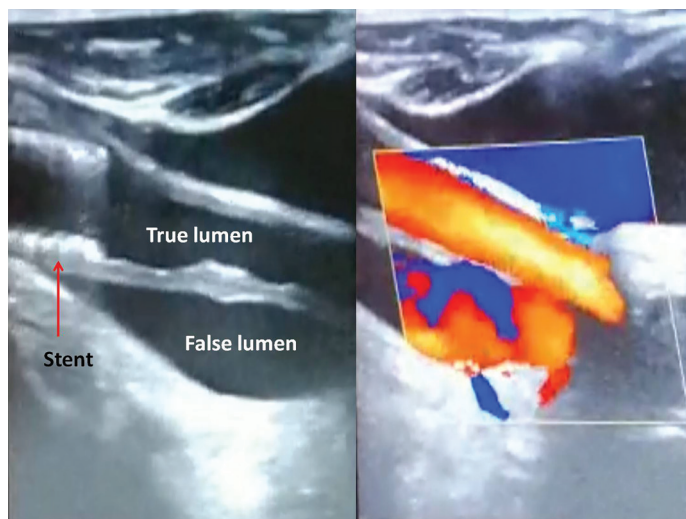


**Figure 3.** Position of the MO.Ma device




**Figure 4.** Final result after carotid stenting





**Figure 5.** Carotid artery dissection in Doppler ultrasonography



**Figure 6.** The carotid artery dissection in computed tomography

the CCA-RICA stent (Fig. 5). The CT finding was consistent with carotid doppler ultrasonography (Fig. 6). After the evaluation of cardiology and neurology, anticoagulant therapy (warfarin) was given to the patient in addition to dual antiplatelet therapy for 1 month. The patient presented as asymptomatic and without any new complication at the 3-month follow-up.

## Discussion

CAS is a relatively newly developed CAD treatment option. However, when compared to CEA, it is associated with more frequent periprocedural complications, including 1) cerebral embolization due to catheters manipulation in arcus aorta and cannulation of CCA, lesion wiring, delivery of devices, balloon inflation, stent deployment, and EPD-placed removal, 2) carotid artery dissection associated with catheter or devices, 3) access site complications, and 4) acute stent occlusion.

Cerebral protection was first described by Theron et al. (7) in 1987. EPDs have emerged especially to reduce the embolic complications during the periprocedural period of CAS. There are currently two EPD systems: d-EPDs and p-EPDs. Although d-EPDs are more commonly used in clinical practice, current data support that p-EPDs more efficiently reduce the embolic risk than d-EPDs. Therefore, p-EPDs are more favorable in high-risk plaques (recently symptomatic and vulnerable plaque such as ulcerated, heterogeneous, high-lipid burden and the presence of intraplaque hemorrhage or intraluminal thrombus) (8, 9). The most commonly used pEPD is the Mo.Ma device in clinical practice. The Mo.Ma device system saves the cerebrum from embolic debris by two atraumatic balloons. One of these blocks the antegrade blood flow from the CCA, and the other blocks the retrograde blood flow from the ECA. Nonetheless, the Mo.Ma device itself may also lead to some complications such as vasospasm, dissection, embolization, etc. (1, 9).

Carotid artery dissection is an uncommon event, and it can occur either spontaneously or iatrogenic. Also, carotid artery dissection may be one of the most serious potential complications of the Mo.Ma device. The mechanisms underlying the iatrogenic carotid artery dissection can be endothelial damage due to barotraumas caused by an over-inflation of the Mo.Ma device proximal balloon. A tear in the intima of the arterial wall after endothelial damage may lead to blood accumulation in the subintimal space, resulting in the formation of the false lumen. This false lumen can compress and limit true lumen flow. It is difficult to establish the real incidence of dissection, because the majority of cases can be asymptomatic or have minor symptoms that are overlooked by the patients and/or physicians. Therefore, the dissection may not be diagnosed, or the diagnosis can be delayed.

Iatrogenic carotid artery dissections take place more frequently during interventional procedures than during diagnostic angiography due to increased catheter exchanges, the use of a sophisticated guide wire, and EPDs (10). In the discussed case, we think that the Mo.Ma device proximal balloon caused the CCA dissection as a result of over-inflation. Over-inflation and uncontrolled inflation, or not changing the shape of the balloon during inflation, leads to an increased risk of dissection, particularly in the case of balloon inflation without real-time fluoroscopic imaging.

Although an optimal treatment approach of carotid artery dissection has not been clearly established in the literature, medical therapy is more acceptable than interventional treatment. However, carotid artery stenting can be feasible in the case of poor intracranial circulation, a degree of luminal stenosis of over 70%, and failure of medical therapy (11). There are also limited data regarding the comparative efficacy of warfarin and antiplatelet therapy. Moreover, an optimal duration of antiplatelet therapy or warfarin is controversial (12). The decision-making process may rely on individual clinical factors, response to treatment, and repeat vascular imaging. In our case, there was the necessity to continue the dual antiplatelet therapy due to stent deployment.

Therefore, warfarin was applied without discontinuing the dual antiplatelet therapy for 1 month.

## Conclusion

Because carotid artery dissection generally has a nonspecific presentation, patients were closely evaluated after CAS, and even mild symptoms should be taken into consideration. Although the Mo.Ma device balloons have an atraumatic design, the balloon inflation can result in carotid artery dissection depending on high pressure and inflation that lasts for a long time. Thus, the application of the Mo.MA device balloons should be more gentle. Anticoagulant therapy can be convenient without stenting in the case of iatrogenic carotid artery dissection.

**Informed consent:** An informed consent was obtained from the patient.

## References

- Jansen O, Fiehler J, Hartmann M, Brückmann H. Protection or non-protection in carotid stent angioplasty: the influence of interventional techniques on outcome data from the SPACE Trial. *Stroke* 2009; 40: 841-6.
- [No authors listed]. Endovascular versus surgical treatment in patients with carotid stenosis in the Carotid and Vertebral Artery Transluminal Angioplasty Study (CAVATAS): a randomised trial. *Lancet* 2001; 357: 1729-37.
- Brooks WH, McClure RR, Jones MR, Coleman TC, Breathitt L. Carotid angioplasty and stenting versus carotid endarterectomy: randomized trial in a community hospital. *J Am Coll Cardiol* 2001; 38: 1589-95.
- Knappich C, Kuehnl A, Tsantilas P, Schmid S, Breikreuz T, Kallmayer M, et al. The use of embolic protection devices is associated with a lower stroke and death rate after carotid stenting. *JACC Cardiovasc Interv* 2017; 26: 1257-65.
- Giri J, Kennedy KF, Weinberg I, Hawkins BM, Press MC, Drachman D, et al. Comparative effectiveness of commonly used devices for carotid artery stenting: an NCDR Analysis (National Cardiovascular Data Registry). *JACC Cardiovasc Interv* 2014; 7: 171-7.
- Atkins MD, Bush RL. Embolic protection devices for carotid artery stenting: have they made a significant difference in outcomes? *Semin Vasc Surg* 2007; 20: 244-51.
- Théron J, Raymond J, Casasco A, Courtheoux F. Percutaneous angioplasty of atherosclerotic and postsurgical stenosis of carotid arteries. *AJNR Am J Neuroradiol* 1987; 8: 495-500.
- Kassavin DS, Clair DG. An update on the role of proximal occlusion devices in carotid artery stenting. *J Vasc Surg* 2017; 65: 271-5.
- Giordan E, Lanzino G. Carotid Angioplasty and Stenting and Embolic Protection. *Curr Cardiol Rep* 2017; 19: 120.
- Cloft HJ, Jensen ME, Kallmes DF, Dion JE. Arterial dissections complicating cerebral angiography and cerebrovascular interventions. *AJNR Am J Neuroradiol* 2000; 21: 541-5.
- Paramasivam S, Leesch W, Fifi J, Ortiz R, Niimi Y, Berenstein A. Iatrogenic dissection during neurointerventional procedures: a retrospective analysis. *J Neurointerv Surg* 2012; 4: 331-5.
- Wein T, Lindsay MP, Côté R, Foley N, Berlingieri J, Bhogal S, et al; Heart and Stroke Foundation Canadian Stroke Best Practice Committees. Canadian stroke best practice recommendations: Secondary prevention of stroke, sixth edition practice guidelines, update 2017. *Int J Stroke* 2018; 13: 420-43.

**Address for Correspondence:** Dr. Fatih Güngören,  
Harran Üniversitesi Tıp Fakültesi,  
Kardiyoloji Anabilim Dalı,  
Şanlıurfa-Türkiye  
Phone: +90 535 795 45 80  
E-mail: fatihgungorendr@gmail.com  
©Copyright 2019 by Turkish Society of Cardiology - Available online  
at [www.anatoljcardiol.com](http://www.anatoljcardiol.com)  
DOI:10.14744/AnatolJCardiol.2019.33238

