

# COVID-19 Autopsies: A Case Series from Poland

Ewa Chmielik<sup>a</sup> Joanna Jazowiecka-Rakus<sup>b</sup> Grzegorz Dyduch<sup>c</sup>  
Anna Nasierowska-Guttmejer<sup>d,e</sup> Lukasz Michalowski<sup>d,f</sup> Aleksander Sochanik<sup>b</sup>  
Magdalena Ulatowska-Bialas<sup>c</sup>

<sup>a</sup>Tumor Pathology Department, Maria Skłodowska-Curie National Research Institute of Oncology Gliwice Branch, Gliwice, Poland; <sup>b</sup>Center for Translational Research and Molecular Biology of Cancer, Maria Skłodowska-Curie National Research Institute of Oncology Gliwice Branch, Gliwice, Poland; <sup>c</sup>Chair of Pathomorphology, Jagiellonian University Medical College, Krakow, Poland; <sup>d</sup>Pathomorphology Department, Central Clinical Hospital of the MSWiA in Warsaw, Warsaw, Poland; <sup>e</sup>Faculty of Medicine, Lazarski University in Warsaw, Warsaw, Poland; <sup>f</sup>Department of Pathology, Medical University of Warsaw, Warsaw, Poland

## Keywords

COVID-19 · Autopsy · Pulmonary embolism · Diffuse alveolar damage

## Abstract

This paper presents autopsy findings of 3 COVID-19 patients randomly selected for post-mortem from two tertiary referral Polish hospitals. Analysis of macroscopic, histopathological findings with clinical features was performed. All 3 deceased patients were Caucasian males (average age 61 years, range from 56 to 68 years). Using real-time polymerase chain reaction assay, the patients were confirmed (antemortem) to have severe acute respiratory syndrome coronavirus 2 (SARS-CoV-2) infection. Two patients were obese, and 1 patient had type 2 diabetes mellitus. The medical history of 1 patient included hemorrhagic pancreatitis, gangrenous cholecystitis, *Acinetobacter baumannii* sepsis, and cholecystectomy. Pulmonary embolism was diagnosed in 2 patients. At autopsy, in 1 case, the lungs showed bilateral interstitial pneumonia with diffuse alveolar damage (DAD), while in another case, interstitial pulmonary lymphoid infiltrates and

enlarged atypical pneumocytes were present but without DAD. Microthrombi in lung vessels and capillaries were observed in 2 cases. This study revealed thrombotic complications of COVID-19 and interstitial pneumonia with DAD presence as the main autopsy findings in patients with SARS-CoV-2 infection that was confirmed antemortem with molecular tests. Autopsy studies using tissue sections handled in accordance with SARS-CoV-2 biosafety guidelines are urgently needed, especially in the case of subjects who were below the age of 60.

© 2020 S. Karger AG, Basel

## Introduction

The severe acute respiratory syndrome coronavirus 2 (SARS-CoV-2) is a single-stranded RNA virus belonging to the coronavirus family. It was identified as the causative factor for the ongoing coronavirus disease 2019 (COVID-19), a pandemic involving human-to-human transmission and causing substantial mortality, particularly among the elderly and those with comorbid condi-

tions. COVID-19 has impacted many areas of human activity and has led to a crisis in medical management worldwide. SARS-CoV-2 mediates its pathogenic effects through binding with angiotensin-converting enzyme 2 (ACE2), a receptor found on the cell membrane of many types of cells [1].

The virus was first (?) identified in patients treated for pneumonia in a Wuhan hospital in China. Since the average rate of nucleotide substitutions per site per year for coronaviruses is ca.  $10^{-4}$ , the 99.9% identity of sequences in viral isolates from initial Wuhan patients suggests that SARS-CoV-2 emerged from one source within a very short time. The virus might have been initially hosted by bats sold at the seafood market in Wuhan and people processing bat carcasses and guano during manufacture of traditional Chinese medical products were likely responsible for bat-to-human transmission [2]. However, testimonials from athletes who have revealed that they fell ill during the Military World Games in October 2019 in Wuhan, as well as fragmentary evidence from various Chinese and other sources suggest alternative scenarios of actual SARS-CoV-2 spread timeframe. Researchers from Harvard have suggested that COVID-19 might have been present in China before it was first acknowledged on December 31, 2019 [3]. Re-testing of isolates from pneumonia patients treated in Avicenna and Jean Verdier Hospital in Paris proved the presence of SARS-CoV-2 in a sample collected in December 2019, nearly a month before first acknowledged COVID-19 cases in France [4, 5]. Also, various alternative scenarios concerning the origin of COVID-19 have been put forward including the intriguing Mojiang Miners Passage hypothesis [6].

COVID-19 genome sequences obtained from samples of bronchoalveolar lavage fluid and cultured isolates taken from individuals linked to Huanan seafood market in Wuhan allowed to track the evolutionary history of the virus and make inferences about its likely origin. SARS-CoV-2 was found to be related (with 88% identity) to two bat-derived coronaviruses (bat-SL-CoVZC45 and bat-SL-CoVZXC21) connected with SARS-like syndrome, but genetically divergent from SARS-CoV responsible for SARS-2002 epidemic (about 79%) and from MERS-CoV responsible for MERS-2012 epidemic (about 50%) [6].

Even though advanced and sensitive diagnostic tests have now become available, whole body autopsies remain the key for understanding the biological characteristics of SARS-CoV-2 infection and pathogenesis of COVID-19, as well as for planning therapeutic strategies. Literature reports based on autopsy material are so far scarce. This

might be partially attributable to COVID-19-related autopsy guidelines which vary from country to country.

As of early September 2020, Poland registered ca. 70,000 COVID-19 cases, 2,000 fatalities, and more than 54,000 recoveries. Over 2.8 million samples were tested for COVID-19 coronavirus, of which ca. 70,000 samples were positive [7, 8]. Although the pandemic put a strain on the medical system, the number of ICU beds has been oscillating around 500 per 100,000 people. A June report of the Polish Economic Institute indicated that COVID-19 most likely did not lead to an increased number of deaths in Poland, and thus underestimated mortality during the coronavirus era should not be high [9]. Since differences in demographic and epidemiological risks require varied policy reactions, the European Commission redirected EUR 618 million in EU Cohesion Policy funding to address the effects of the coronavirus crisis in the Polish economy and health system [10].

Although in Poland postmortem examinations of COVID-19 victims have not been restricted, the total number of autopsies performed on such subjects or on subjects suspected of COVID-19-related death has been low due to concerns about safeguarding health of employees in hospital pathology departments.

## Materials and Methods

The postmortem examinations were performed in two tertiary referral Polish hospitals. The clinical and autopsy data were collected and reanalyzed. Biopsy material taken during autopsy was fixed in 10% buffered formalin and embedded in paraffin. Sections (4  $\mu$ m) were cut, mounted on slides, and stained with hematoxylin and eosin. Samples isolated from the lungs were additionally examined by immunohistochemistry for leukocyte common antigen, CD20, CD3, CD4, CD8, and cytokeratin (CKAE1/3).

## Results

### Case 1

A 63-year-old man, suspected of coronavirus SARS-CoV-2 infection and with several comorbidities was transferred from Rheumatology Department, where he had been treated with steroids, to the intensive care unit. At the time of admission, the patient showed severe respiratory insufficiency and signs of heart insufficiency. The reason to start oxygen therapy was presence of fever (38 °C) and lowered oxygen saturation. This step led to a short-term improvement, but later the patient again developed fever and, additionally, dyspnea. Under these cir-



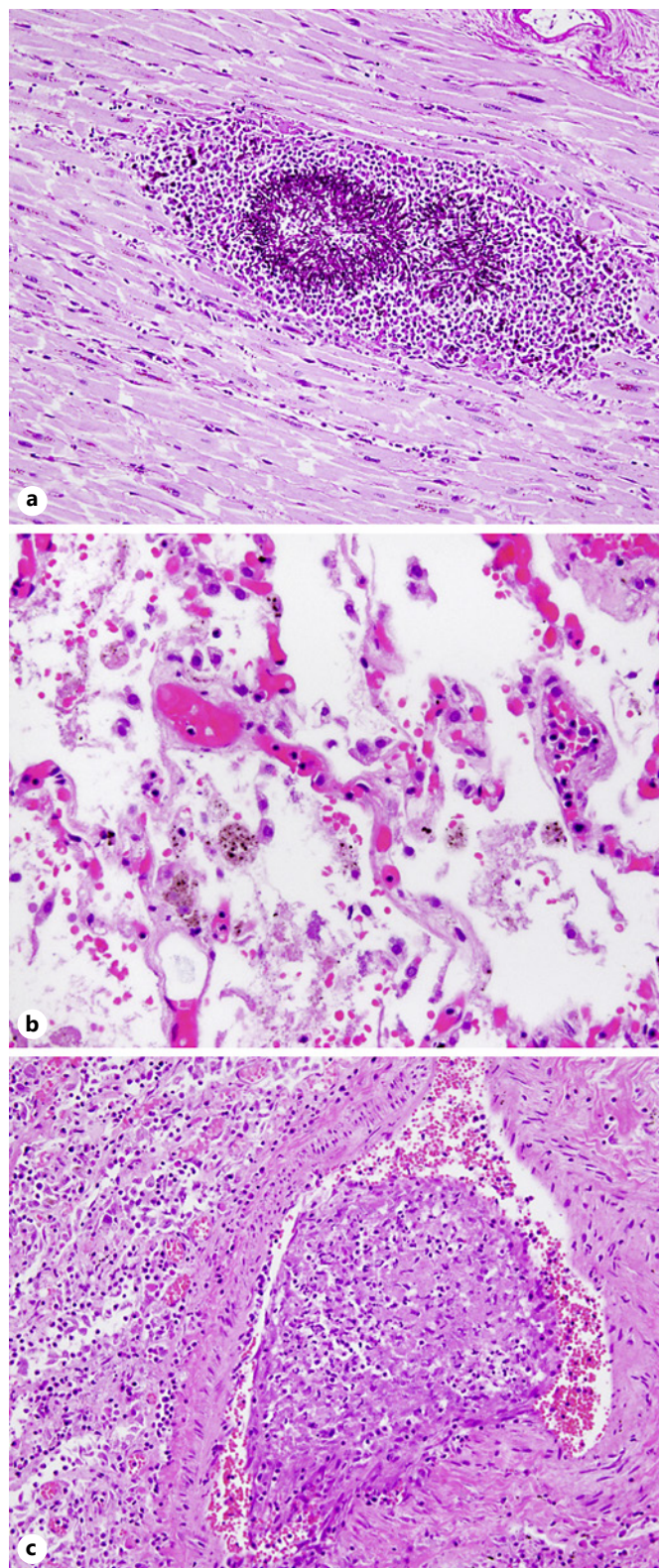
cumstances, nasopharyngeal swab was taken which confirmed COVID-19 presence. Lopinavir and ritonavir drugs were introduced. Three days after admission, *Candida albicans* was detected in the patient's blood. Despite intensive therapy, the subject died among symptoms of multiorgan failure 5 days after admission to the intensive care unit.

Previous medical history showed hemorrhagic pancreatitis and gangrenous cholecystitis with sepsis (*Acinetobacter baumannii*) and secondary panniculitis and polyarthrititis. Cholecystectomy was performed. According to his medical history, the patient was addicted to alcohol (alcohol use disorder) and heavy smoking. The autopsy was performed, and biopsy samples were taken from all major organs: lungs, heart, liver, pancreas, kidneys, and brain stem. Mycotic microabscesses in the right lung, both kidneys, and myocardium (Fig. 1a) were detected. Features of massive confluent purulent bronchopneumonia were found in the right lung. Samples from the left lung showed focal desquamation of pneumocytes and microthrombi in the intra-alveolar capillaries, without hyaline membrane formation (Fig. 1b). Partly organized thrombi were observed also in larger pulmonary vessels (Fig. 1c).

#### Case 2

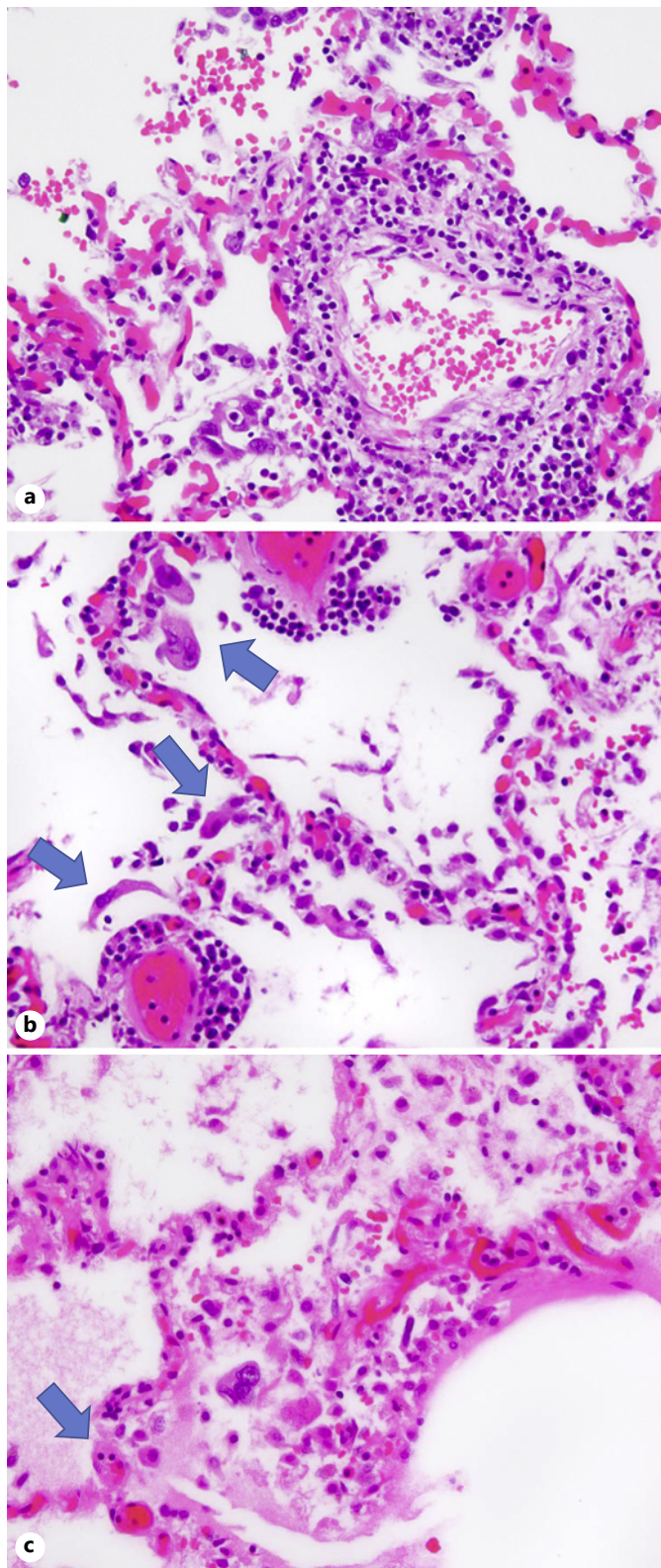
A 56-year-old man diagnosed with coronavirus SARS-CoV-2 infection was admitted to hospital on March 28, 2020, with severe clinical symptoms typical in the course of COVID-19: high fever (38.5 °C), shortness of breath, cough, weakness, and olfactory and taste changes. Ten days earlier, the patient had returned to Poland from Great Britain, and after 3 days he started to experience the first symptoms of the infection. SARS-CoV-2 presence was confirmed by reverse real-time polymerase chain reaction assay.

The patient was obese, without concomitant chronic disorders. On admission, blood saturation was 97%. Three days later, blood saturation dropped to 91%, and the patient received oxygen through nasal cannula (2 L/min). Chest X-ray on admission revealed multiple, patchy shadows and densities in the middle and lower lobe of the right lung. The second chest X-ray was done 3 days later and the findings were similar. The patient received broad-



**Fig. 1.** Case 1. Microscopic myocardium and lung findings. **a** Mycotic microabscesses in myocardium. H&E staining.  $\times 200$ . **b** Microthrombi in the intra-alveolar capillaries. H&E staining.  $\times 400$ . **c** Partly organized thrombi in larger pulmonary vessels. H&E staining.  $\times 200$ .





spectrum antibiotic therapy, hydroxychloroquine, low-flow passive oxygen therapy, and antithrombotic prophylaxis. On April 2, 2020, the patient developed sudden cardiac arrest and was resuscitated for 60 min. Despite adrenalin use, no response was observed, and the patient was declared dead.

Tissue samples were taken from all major organs: lungs, heart, liver, pancreas, kidneys, and brain stem. On gross examination, the most spectacular finding was a saddle embolus in the pulmonary trunk and both pulmonary arteries, 15 cm in length. There were no signs of hyaline membrane formation and no evidence of diffuse alveolar damage (DAD), but the interstitial mononuclear inflammatory infiltrates, mostly lymphocytes were present in the lung tissue samples (Fig. 2a). Groups of enlarged, atypical pneumocytes with large nuclei (but without obvious intranuclear inclusions) were present in intra-alveolar spaces (Fig. 2b), and small microthrombi could be seen in intra-alveolar septa (Fig. 2c). The liver specimens showed unspecific signs of hyperemia, small groups of mononuclear inflammatory infiltrates mostly in lobular location, and microvesicular steatosis in single hepatocytes. In the heart tissue, small, scattered foci of myocardial fibrosis were noted in the latero-posterior wall of the left ventricle and in the septum.

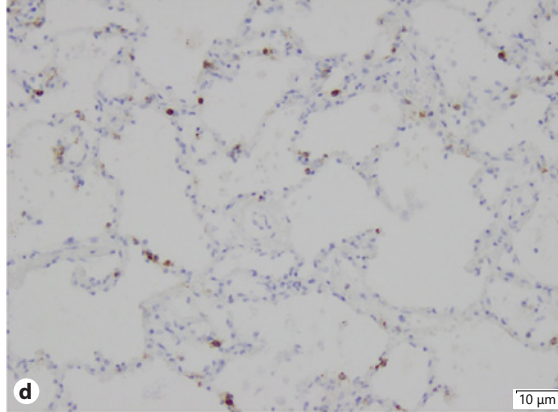
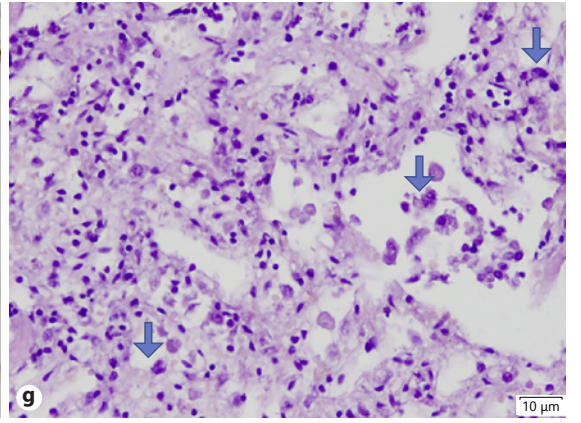
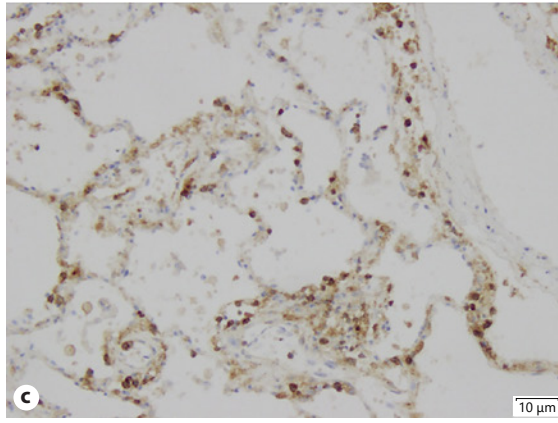
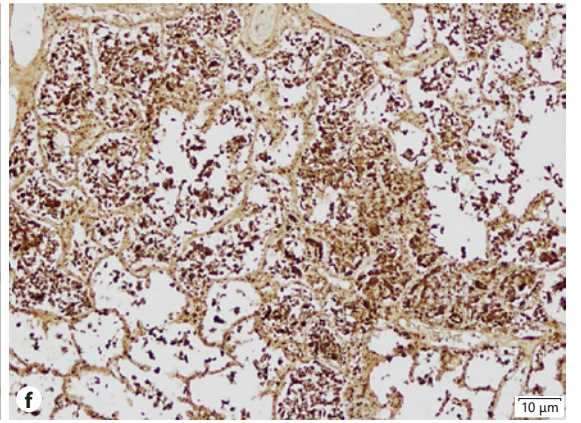
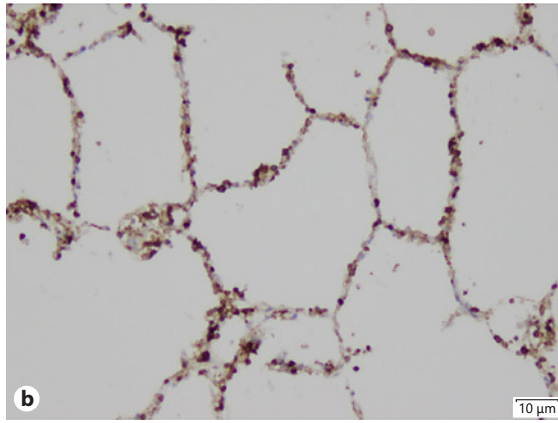
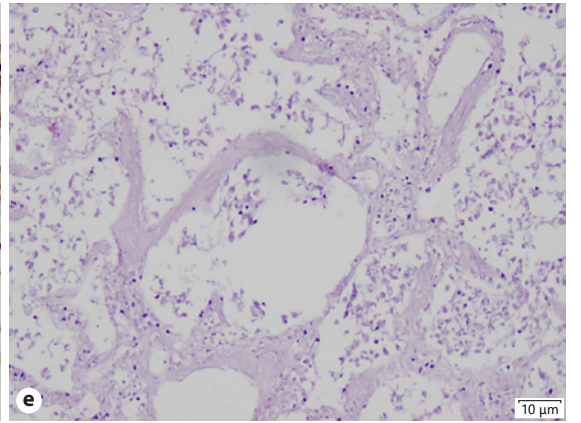
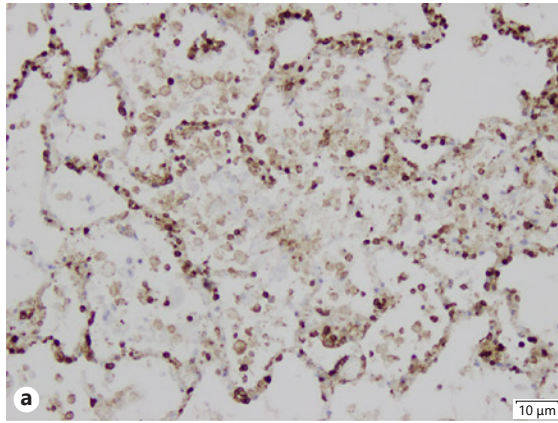
### Case 3

This 59-year-old paramedic was hospitalized and tested for SARS-CoV-2 presence, 4 days after onset of typical COVID infection symptoms (fever, cough, and fatigue). Presence of SARS-CoV-2 was confirmed in the collected nasopharyngeal swabs. Despite aggressive treatment including Arechin and Kaletra (lopinavir and ritonavir), the patient's condition rapidly deteriorated within 10 days. The patient died following unsuccessful cardiopulmonary resuscitation.

Postmortem examination revealed virus-caused severe lesions in the respiratory system as well as the pulmonary trunk. Trachea with a smooth gray-pink mucosa revealed a small amount of mucus. Lung surface was smooth with mild features of pleurisy. Front area was gray-pink while back one was dark-cherry in color. The cohesion of the lungs was increased. On the cutting surface numerous sharply delimited areas of red color and

**Fig. 2.** Case 2. Microscopic lung findings. **a** Interstitial mononuclear inflammatory infiltrates. H&E staining.  $\times 400$ . **b** Enlarged, atypical pneumocytes with large nuclei in intra-alveolar spaces (arrows). H&E staining.  $\times 400$ . **c** Microthrombi in intra-alveolar septa. H&E staining.  $\times 400$ .





**Table 1.** Patients' clinical characteristics

	Case 1	Case 2	Case 3
Age, years	68	56	59
Sex	Male	Male	Male
RT-qPCR COVID assay and organ	Confirmed Nasopharyngeal swab	Confirmed Nasopharyngeal swab	Confirmed Nasopharyngeal swab
Time between first symptoms and test	13 days	13 days	4 days
Time between test and death	4 days	28 days	10 days
Obesity	Yes, slight (BMI = 26.12)	Yes (BMI = 34.6)	Yes
Preexisting medical history	Alcohol use disorder Hemorrhagic pancreatitis Gangrenous cholecystitis with sepsis ( <i>Acinobacter baumani</i> ) with secondary panniculitis and polyarteritis cholecystectomy	Previous history lower limb thrombophlebitis	Type 2 diabetes mellitus
Oxygen nasal canula or face mask	Yes	Yes	Yes
Intubation	Yes	Yes	Yes
Chest X-ray	Diffuse densities in the lower lobes of both lungs	Multiple shadows and densi- ties in the right lung	Bilateral ground glass opacities
Blood group	ORh-	ND	BRh+
Immunosuppression	Steroids	No	No
COVID treatment	Kaletra (lopinavir+ritonavir)	Arechin	Arechin, Kaletra (lopinavir+ ritonavir)
ND, no data.			

1–4 cm in diameter exceeded below the pleura. Macroscopically, the changes corresponded to red infarcts. After compression, blood and small amount of foamy fluid came out of the lungs. The bronchial mucosa was hyperemic and covered with a small amount of mucus. Thromboembolism filled the pulmonary trunk; lobular and segmental arteries were detected. The kidneys on the cutting surface were dark cherry in color. The lesions visible during macroscopic analysis were limited to the lungs. No evidence of deep venous thrombosis in the lower limbs, preexisting heart disease, coronary artery sclerosis, ischemic cord diseases, or ischemic enteritis were found. There was no evidence of cancer.

Tissue samples examined during autopsy were taken from the lungs, heart, liver, and kidneys. Microscopic findings mainly concerned the lungs. The histopathological examination showed bilateral interstitial pneumonia with infiltration of lymphocytes, alveolar destruction,

and DAD. CD4 lymphocytes in the alveolar septa as well as lumen around the vessels were found (Fig. 3a–d). Granulocytic infiltration was not observed. Microscopic examination confirmed thromboembolism in numerous vessels and extensive areas of red infarction. The microscopic lung findings were heterogeneous. Edema, hyaline membranes (Fig. 3e), exfoliated and hyperplastic pneumocytes (Fig. 3f and g, respectively) as well as macrophages in the alveolar lumen could be seen next to the areas of interstitial inflammation. Single hypertrophied cardiomyocytes and small areas of fibrosis were found in the heart. No cardiac lymphocytic infiltration was observed. Necrotic lesions in the kidneys and hepatic steatosis of 10% was found.

The patients' clinical characteristics are summarized in Table 1. Macroscopic and microscopic findings in the respiratory tract are summarized in Table 2.

**Table 2.** Autopsy findings in the respiratory tract

	Case 1	Case 2	Case 3
Age, sex	68 years, M	56 years, M	59 years, M
Bronchial tree	Hyperemic mucosa, multiple ecchymoses	Normal mucosa without significant changes	Hyperemic mucosa, small amount of mucus
Lung parenchyma grossly	Firm	Soft	Firm, numerous red infarcts (1–4 cm)
Pulmonary arteries grossly	No changes	Pulmonary embolism	Pulmonary embolism
Pleura grossly	Smooth, no adhesions	Smooth, no adhesions	Smooth, no adhesions
Lung parenchyma microscopically	Right lung: purulent bronchopneumonia Left lung: pneumocytes desquamation focally	No signs of hyaline membrane No evidence of DAD Enlarged atypical pneumocytes with large nuclei in intra-alveolar spaces	Bilateral interstitial pneumonia DAD: hyaline membranes, exfoliated hyperplastic pneumocytes and macrophages in the alveolar lumens
Lung vessels, capillaries microscopically	Microthrombi	Small microthrombi in the intra-alveolar septa	Thromboembolism

M, male; DAD, diffuse alveolar damage.

## Discussion/Conclusion

The traditional autopsy remains “the gold standard” for identifying the cause of death [11]. We present here the results of postmortem examinations performed in 3 COVID-19-positive Caucasian male patients (average age 61 years). All autopsies were done by applying the traditional technique. Two autopsies included skull, thoracic, and abdominal cavity examination, and one autopsy covered both cavities but no skull.

Our postmortem observations are similar to those reported previously. No higher incidence of blood group A was observed. Male predominance was seen as in previously published reports [10–14].

Severe COVID-19 cases involve hemostatic abnormalities that mimic disseminated intravascular coagulopathy associated with sepsis, with the major difference being increased risk of thrombosis rather than bleeding. SARS-CoV-2 infection is associated with platelet hyperreactivity which may contribute to COVID-19 pathophysiology. Increased platelet activation and aggregation could partially be attributed to enhanced MAPK pathway activation and thromboxane generation. Furthermore, platelets from COVID-19 patients showed increased spreading on both fibrinogen and collagen [15].

Thrombotic complications in COVID-19 patients are common and contribute to organ failure and mortality. Roughly a quarter of patients develop pulmonary thromboembolism with infarcts and/or hemorrhage [15].

We observed pulmonary embolism in 2 examined subjects, while 1 had previous history of lower limb thrombophlebitis. Pulmonary embolism was detected in 19% of cases reported by Menter et al. [13] and 22% cases reviewed by Buja et al. [14]. Pulmonary embolism as the direct cause of death was listed in one-third out of 12 autopsies reported by Wichmann et al. [10]. These authors noted high incidence of this pathological finding with underlying deep venous thrombosis. Moreover, all cases in the Wichmann series revealed pulmonary microthrombosis [10].

In our study, hemorrhagic infarct was detected in 1 of 2 cases involving pulmonary embolism. Wichmann et al. [10] noted hemorrhagic infarct in half of the analyzed cases.

In the case series reported by Lax, pulmonary artery thrombosis was seen in all 11 patients, while hemorrhagic infarct in 9 of them. The thrombotic material was present in the branches of the pulmonary arteries with extent ranging from focal to extensive [12]. These authors did not discern the group with pulmonary embolism only. Fibrin-rich thrombi in capillaries and small blood vessels were noted in 26% of cases studied by Buja et al. [14]. Involvement of thrombotic material in pulmonary artery of patients with severe COVID-19 and diagnosed by CT angiography was reported by Grillet et al. [15].

Venous thromboembolism was detected in 11% of Italian clinical patients from the series of Lodigiani et al. [16], and pulmonary embolism confirmed by CT angiography was found in 2.5% of patients from this group. Mul-



ticenter prospective cohort study data from intensive care units in France show that the incidence of pulmonary embolism has been much higher in COVID-19 acute respiratory distress syndrome (ARDS) patients, as compared to non-COVID-19 patients (11.7 vs. 2.1%) [17].

Pulmonary thrombosis may be a consequence of inflammatory processes within the lung and pulmonary endothelial dysfunction or damage [18]. The mechanisms of pulmonary thrombosis and pulmonary embolism are probably different. Such observation might change the clinical approach to administration of anticoagulants [19]. Close correlation of clinical, radiological, and pathological data from prospective studies might help resolve this problem.

Altered platelet gene expression and functional responses were found in patients infected with SARS-CoV-2 [18]. RNA sequencing demonstrated distinct changes in the gene expression profile of circulating platelets from COVID-19 patients. Analysis revealed differential gene expression changes in pathways associated with protein ubiquitination, antigen presentation, and mitochondrial dysfunction. The mRNA or ACE2 receptor protein for SARS-CoV-2 binding was not detected in platelets. Surprisingly, mRNA for the SARSCoV-2 N1 gene was detected in platelets from 2 out of 25 COVID-19 patients, suggesting that platelets may take up SARS-CoV-2 mRNA independently of ACE2. Resting platelets from COVID-19 patients showed increased P-selectin expression both basally and upon activation. Circulating platelet aggregates (with neutrophils, monocytes, and T-cells) were all significantly elevated in COVID-19 patients [18].

Further laboratory and imaging studies are needed to better understand the thrombotic complications of COVID-19 as well as the conditions required for strict thrombosis prophylaxis and to improve early anticoagulant therapy for suspected pulmonary arterial thrombosis or thromboembolism.

COVID-19 affects predominantly the lungs, causing DAD and leading to acute respiratory insufficiency. The term DAD, first proposed by Katzenstein, refers to diffuse impairment with endothelial and alveolar lining cell injury comprising the distal pulmonary acinus [20]. DAD is considered a pathological correlate of ARDS. However, the clinical and autopsy data suggest that only one half of patients with ARDS have DAD [21]. DAD was detected in 1 case in our series (case 3). The microscopic changes seen in the lung specimens from subject 1 suggested only focal DAD presence. Under such circumstances, we did not call it DAD in order to remain in full agreement with

the definition. It might be pointed out that our microscopic findings showed differences when compared to pathological features in early phase COVID-19 pneumonia as observed by Tian et al. [22]. DAD is a key pathological feature among 76% cases studied by Menter et al. [13]. According to very detailed supplementary materials provided with their findings, 3 cases were classified as early exudative phase of DAD, while 8 cases presented both the exudative and proliferative phase of alveolar damage. Eight out of 12 patients from the Wichmann cohort study were characterized by DAD as well [10]. Hyaline membranes as a sign of accomplished alveolar damage were found in all cases, while proliferation of pneumocytes and fibroblasts was seen in almost all cases studied by Lax et al. [12]. Lymphocytic interstitial pneumonitis accompanied by DAD was reported in the majority of subjects examined in the study by Buja et al. [14]. One of our subjects (case 3) also presented DAD with lymphocytic interstitial pulmonary infiltrates composed mainly of T-cell (CD4) lymphocytes.

Histology of the lungs without DAD presented extensive granulocytic infiltration resembling bacterial bronchopneumonia [10]. Superimposed bacterial bronchopneumonia could be identified together with SARS-CoV-2-associated respiratory failure as the cause of death in 8 out of 21 cases from Switzerland [13]. Similar complication was observed in 1 subject from our series (case 1) in whom early alveolar damage was detected microscopically in the left lung but purulent bronchopneumonia in the right lung.

Comparative analysis of DAD due to SARS-CoV-2 infection and DAD due to other causes performed by Kopopka et al. [20] showed that they were histologically indistinguishable. Diabetes was present in all subjects from their inpatient cohort. All but 1 subject with diabetes mellitus from the cohort of Menter et al. [13] presented DAD, and half of the group had an early exudative phase, while the other half showed both exudative and concomitant proliferative type. Supported by clinical data from Wuhan, China, Guo et al. [23] have claimed that diabetes should be considered a risk factor for rapid progression and bad prognosis. Pathology data from our autopsy series support this conclusion. SARS-CoV-2 infection dysregulates glucose metabolism and affects the severity of pneumonia [23]. Inflammation processes and presence of hypoxia activate the exogenous coagulation pathway, leading to a hypercoagulable state or even disseminated intravascular coagulation [23].

To summarize: our observations remain in agreement with the previously published COVID-19 larger autopsy



series. We are aware of the limitation underlying general inferences from the 3-case series reported here. Nonetheless, these autopsies contribute to conclusions concerning COVID-19 subjects with molecularly confirmed presence of SARS-CoV-2. Another acknowledged limitation of the presented short series has been the lack of confirmed virus presence in the respiratory tract and other autopsied organs. This was likely due to the shortage of molecular tests at the time of performing the procedure. Concomitant with the technical developments in virus detection in paraffin block sections of tissues sampled during autopsy, it is possible now to confirm the virus presence, as described by Best Rocha et al. [24].

Thanks to autopsy studies, we learn more and more about COVID-19, its mechanisms, and the threat it poses, especially for diabetes 2 patients. As the pandemic continues, further autopsy studies using tissue sections obtained using proper biosafety procedures are badly needed, especially in cases of subjects who were below the age of 60.

## References

- Verdecchia P, Cavallini C, Spanevello A, Angeli F. The pivotal link between ACE2 deficiency and SARS-CoV-2 infection. *Eur J Intern Med*. 2020 Jun;76:14–20.
- Sun P, Lu X, Xu C, Sun W, Pan B. Understanding of COVID-19 based on current evidence. *J Med Virol*. 2020 Jun;92(6):548–51.
- Nsoesie EA, Rader B, Yiyao LB, Goodwin L, Brownstein JS. Analysis of hospital traffic and search engine data in Wuhan China indicates early disease activity in the Fall of 2019. <http://nrs.harvard.edu/urn-3:HUL.InstRepos:42669767>.
- Reuters World News, May 4, 2020.
- Lescure FX, Bouadma L, Nguyen D, Parisey M, Wicky PH, Behillil S, et al. Clinical and virological data of the first cases of COVID-19 in Europe: a case series. *Lancet Infect Dis*. 2020 Jun;20(6):697–706.
- Lu R, Zhao X, Li J, Niu P, Yang B, Wu H, et al. Genomic characterisation and epidemiology of 2019 novel coronavirus: implications for virus origins and receptor binding. *Lancet*. 2020 Feb;395(10224):565–74.
- <https://www.statista.com/statistics/1102229/poland-coronavirus-diagnostics/>
- <https://healthcaremarketexperts.com/en/news/mortality-in-poland-covid-19-did-not-affect-growth/>
- <https://www.thefirstnews.com/tag/European%20Commission>
- Wichmann D, Sperhake JP, Lütgehetmann M, Steurer S, Edler C, Heinemann A, et al. Autopsy Findings and Venous Thromboembolism in Patients with COVID-19: A Prospective Cohort Study. *Ann Intern Med*. 2020 Aug;173(4):268–77.
- Barton LM, Duval EJ, Stroberg E, Ghosh S, Mukhopadhyay S. COVID-19 Autopsies, Oklahoma, USA. *Am J Clin Pathol*. 2020 May;153(6):725–33.
- Lax SF, Skok K, Zechner P, Kessler HH, Kaufmann N, Koelblinger C, et al. Pulmonary Arterial Thrombosis in COVID-19 With Fatal Outcome : Results From a Prospective, Single-Center, Clinicopathologic Case Series. *Ann Intern Med*. 2020 Sep;173(5):350–61.
- Menter T, Haslbauer JD, Nienhold R, Savic S, Hopfer H, Deigendesch N, et al. Postmortem examination of COVID-19 patients reveals diffuse alveolar damage with severe capillary congestion and variegated findings in lungs and other organs suggesting vascular dysfunction [published online ahead of print, 2020 May 4]. *Histopathology*. 2020 May;77(2):198–209.
- Buja LM, Wolf DA, Zhao B, Akkanti B, McDonald M, Lelenwa L, et al. The emerging spectrum of cardiopulmonary pathology of the coronavirus disease 2019 (COVID-19): report of 3 autopsies from Houston, Texas, and review of autopsy findings from other United States cities. *Cardiovasc Pathol*. 2020 Sep - Oct;48:107233.
- Grillet F, Behr J, Calame P, Aubry S, Delabrousse E. Acute Pulmonary Embolism Associated with COVID-19 Pneumonia Detected with Pulmonary CT Angiography. *Radiology*. 2020 Sep;296(3):E186–8.
- Lodigiani C, Iapichino G, Carenzo L, Cecconi M, Ferrazzi P, Sebastian T, et al. Humanitas COVID-19 Task Force. Venous and arterial thromboembolic complications in COVID-19 patients admitted to an academic hospital in Milan, Italy. *Thromb Res*. 2020 Jul;191:9–14.
- Helms J, Tacquard C, Severac F, Leonard-Lorant I, Ohana M, Delabranche X, et al.; CRICS TRIGGERSEP Group (Clinical Research in Intensive Care and Sepsis Trial Group for Global Evaluation and Research in Sepsis). High risk of thrombosis in patients with severe SARS-CoV-2 infection: a multicenter prospective cohort study. *Intensive Care Med*. 2020 Jun;46(6):1089–98.

## Statement of Ethics

This study report was conducted ethically in accordance with the World Medical Association Declaration of Helsinki. Ethics approval and informed consent were not required, according to the local Ethics Committee regulations.

## Conflict of Interest Statement

The authors have no conflicts of interest to declare.

## Funding Sources

The authors have not declared a specific grant for this research.

## Author Contributions

Study design by E.C. and A.N.-G. Manuscript written by E.C., J.J.-R., G.D., A.N.-G., L.M., A.S. and M.U.-B. Autopsies performed by G.D., L.M., and M.U.-B. Histopathology by G.D., A.N.-G., L.M. and M.U.-B.

All authors read and approved the manuscript.

- 18 Manne BK, Denorme F, Middleton EA, et al. Platelet Gene Expression and Function in COVID-19 Patients. *Blood*. 2020 Sep 10; 136(11):1317-1329.
- 19 Gabrielli M, Lamendola P, Esperide A, Valletta F, Franceschi F. COVID-19 and thrombotic complications: pulmonary thrombosis rather than embolism? [Letter]. *Thromb Res*. 2020 Sep;193:98.
- 20 Konopka KE, Nguyen T, Jentzen JM, Rayes O, Schmidt CJ, Wilson AM, et al. Diffuse alveolar damage (DAD) resulting from coronavirus disease 2019 Infection is Morphologically Indistinguishable from Other Causes of DAD. *Histopathology*. 2020 Oct;77(4):570-8.
- 21 Cardinal-Fernández P, Lorente JA, Ballén-Barragán A, Matute-Bello G. Acute Respiratory Distress Syndrome and Diffuse Alveolar Damage. New Insights on a Complex Relationship. *Ann Am Thorac Soc*. 2017 Jun; 14(6):844-50.
- 22 Tian S, Hu W, Niu L, Liu H, Xu H, Xiao SY. Pulmonary Pathology of Early-Phase 2019 Novel Coronavirus (COVID-19) Pneumonia in Two Patients With Lung Cancer. *J Thorac Oncol*. 2020 May;15(5):700-4.
- 23 Guo W, Li M, Dong Y, Zhou H, Zhang Z, Tian C, et al. Diabetes is a risk factor for the progression and prognosis of COVID-19. *Diabetes Metab Res Rev*. 2020 Mar;36(7):e3319.
- 24 Best Rocha A, Stroberg E, Barton LM, Duval EJ, Mukhopadhyay S, Yarid N, et al. Detection of SARS-CoV-2 in formalin-fixed paraffin-embedded tissue sections using commercially available reagents. *Lab Invest*. 2020 Nov; 100(11):1485-9.