



Pancreatitis associated with calciphylaxis successfully treated with sodium thiosulfate

Aoibheann Flynn, MD, Aine de Bhailis, MD, Ann-Marie Tobin, PhD,
George Mellotte, MD, FRCPI, and Maureen Connolly, MD
Dublin, Ireland

Key words: calciphylaxis; pancreatitis; sodium thiosulfate.

INTRODUCTION

Although pancreatitis is not uncommon, the underlying cause is usually identified from clinical history, physical examination, laboratory investigations, and radiologic imaging. Causes include alcohol, gallstones, medications, hypertriglyceridemia, and postendoscopic retrograde cholangiopancreatography.

We report the case of a 54-year-old man with a history of renal failure who developed severe recurrent pancreatitis while on hemodialysis. No underlying cause for his pancreatitis could be identified, despite multiple investigations. He was later diagnosed with cutaneous calciphylaxis, and when this was successfully treated with sodium thiosulfate, his pancreatitis completely settled.

Calciphylaxis is an ischemic vasculopathy, which can affect patients with end-stage renal disease. The skin findings are retiform purpura, stellate ulceration, and gangrene predominantly located on the lower legs. Calciphylaxis can affect internal organs; however, to the best of our knowledge, this is the first case report of calciphylaxis-associated pancreatitis.

REPORT

A 54-year-old man developed recurrent episodes of severe abdominal pain associated with a raised amylase level and deranged liver function. Computed tomography scan of the abdomen and magnetic resonance cholangiopancreatography confirmed pancreatitis. On imaging, there was evidence of pancreatic duct dilatation, but no renal calculi were visible (**Fig 1**). He was given the diagnosis of recurrent pancreatitis and treated

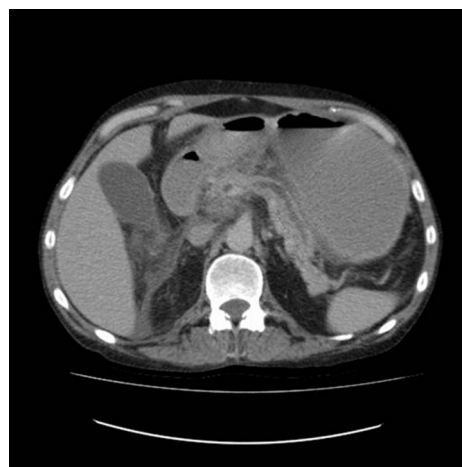

Fig 1. Computed tomography of pancreas showing severe pancreatitis.

conservatively. Over the following 12 months, he had numerous episodes of severe pancreatitis requiring recurrent admissions to the hospital, including a prolonged stay in intensive care. Despite multiple investigations and imaging for his pancreatitis, no underlying case could be identified.

His medical history included a renal transplant secondary to glomerulonephritis 20 years previously, adrenal insufficiency, dysplastic marrow, hypertension, gout, and previous venous thromboembolism requiring warfarin therapy. His renal transplant had failed 1 year previously, and he was on regular hemodialysis.

During 1 of his hospital admissions, it was noted he had developed painful bilateral ulcerations on his lower legs, and the dermatology team were

From the Adelaide and Meath Hospital, Tallaght, Dublin.

Funding sources: None.

Conflicts of interest: None declared.

Correspondence to: Aoibheann Flynn, MD, Department of Dermatology, Adelaide and Meath Hospital, Tallaght, Dublin 24, Ireland. E-mail: flynnam@tcd.ie.

JAAD Case Reports 2018;4:159-61.

2352-5126

© 2017 by the American Academy of Dermatology, Inc. Published by Elsevier, Inc. This is an open access article under the CC BY-NC-ND license (<http://creativecommons.org/licenses/by-nc-nd/4.0/>).

<http://dx.doi.org/10.1016/j.jidcr.2017.07.030>

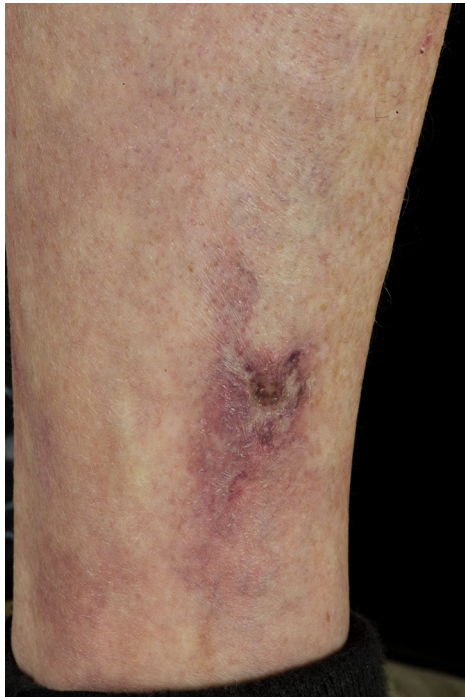

Fig 2. Retiform purpura with ulcer on lower leg.

consulted. Clinical examination revealed retiform purpura with ulceration on both legs and lower abdomen (Fig 2). The differential diagnosis was a medium-vessel vasculitis or calciphylaxis.

Initial histopathology from a punch biopsy revealed nonspecific findings. Because of the high index of suspicion, biopsies were taken from the patient on 2 additional occasions. His third biopsy revealed multiple small vessels with mural calcification and some fibromuscular proliferation. The subcutaneous fat showed foci of fat necrosis with minor inflammatory reaction and small vessel calcification (Fig 3, A and B). These findings were consistent with calciphylaxis.

In light of the diagnosis of calciphylaxis, treatment with warfarin was discontinued and treatment with sodium thiosulfate was commenced at a dosage of 15 g 3 times per week. His skin improved within weeks with complete healing of his ulcers, and his purpura resolved. His abdominal pain also settled over the same period, coupled with an improvement of his biochemical markers, including serum amylase. Given his pancreatitis settled with IV sodium thiosulfate, we believe he had calciphylaxis-induced pancreatitis.

Several months later, when his sodium thiosulfate dosage was reduced to 15 g twice weekly, his symptoms relapsed, with a recurrence of pancreatitis and skin disease with the development of cutaneous purpura and skin ulceration. His dosage of sodium

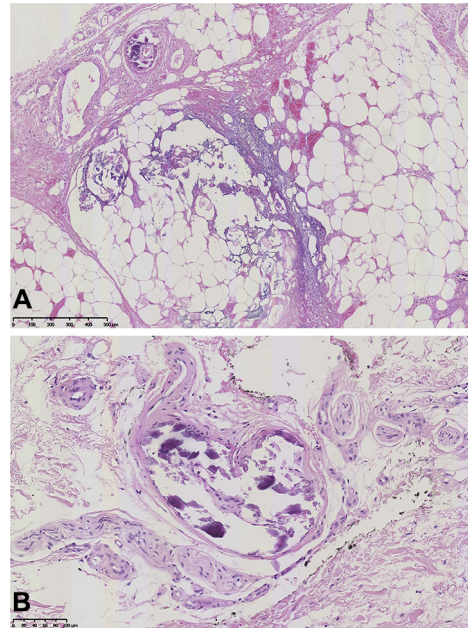


Fig 3. **A,** Histopathology demonstrating a focus of fat necrosis within the subcutaneous fat layer with a minor surrounding inflammatory reaction. **B,** Extensive mural calcification of blood vessel with no evidence of vasculitis.

thiosulfate was increased back to 15 g 3 times per week and his symptoms resolved again over several weeks. He has remained in clinical remission on this maintenance dose.

DISCUSSION

Calciphylaxis, otherwise known as calcific uremic arteriolopathy, is a rare and life threatening ischemic vasculopathy, which causes ischemia and subcutaneous necrosis. Patients with end-stage renal disease are at risk. Other risk factors include high phosphate levels, hypercoagulable states, diabetes, and medications, such as warfarin, calcium-based binders, and vitamin D analogues.^{1,2} Our patient was on warfarin and receiving regular hemodialysis. Once calciphylaxis was confirmed on histology, his warfarin was discontinued.

Systemic calciphylaxis can be difficult to diagnose in the absence of skin involvement. Even on skin histology, the findings can be difficult to identify, and therefore, one must have a high index of suspicion. Given that calcium deposition primarily occurs within the vessel walls of the deep subcutaneous fat, a deep incisional biopsy might be necessary to yield a diagnosis,³ as in our patient's case.

Treatment of calciphylaxis can be challenging. Triggers, such as supplemental calcium, vitamin D, and offending medications should be withdrawn. Cinacalcet can be used for hyperparathyroidism, as

well as bisphosphonates for the reduction of calcium. A parathyroidectomy should be considered in patients with hyperparathyroidism unresponsive to cinacalcet.⁴

Sodium thiosulfate is a potent antioxidant, which increases the solubility of calcium deposits. It can be used in both uremic and nonuremic calciphylaxis. It is commonly used to treat calciphylaxis and is generally well tolerated.^{1-3,5}

The clinical picture in our patient's case was one of chronic relapsing pancreatitis without a definitive cause until the patient developed cutaneous calciphylaxis and responded to treatment with sodium thiosulfate. The subsequent improvement of his condition led us to believe that calciphylaxis was causing the episodes of recurrent pancreatitis. Although calciphylaxis is known to affect internal organs,⁶⁻⁸ this is the first reported case of calciphylaxis-induced pancreatitis. Research in 1970 demonstrated calciphylactic pancreatitis developing in rats with hyperparathyroidism⁹; however, as far as we are aware, there are no previous reports in humans.

REFERENCES

1. Wilmer WA, Magro CM. Calciphylaxis: emerging concepts in prevention, diagnosis, and treatment. *Semin Dial.* 2002;15(3):172-186.
2. Nigwekar SU, Kroshinsky O, Nazarian RM, et al. Calciphylaxis: riskfactors, diagnosis, and treatment. *Am J Kidney Dis.* 2015;66(1):133-146.
3. Ng AT, Peng DH. Calciphylaxis. *Dermatol Ther.* 2011;24(2):256-262.
4. Angelis M, Wong LL, Myers SA, et al. Calciphylaxis in patients on hemodialysis: a prevalence study. *Surgery.* 1997;122(6):1083-1089.
5. Cicone JS, Petronis JB, Embert OD, et al. Successful treatment of calciphylaxis with intravenous sodium thiosulfate. *Am J Kidney Dis.* 2004;43(6):1104-1108.
6. Suryadevara M, Schurman SJ, Landas SK, et al. Systemic calciphylaxis. *Pediatr Blood Cancer.* 2008;51:548-550.
7. Oh DH, Eulau D, Tokugawa DA, McGuire JS, Kohler S. Five cases of calciphylaxis and a review of the literature. *J Am Acad Dermatol.* 1999;40(6):979-987.
8. Li YJ, Tian YC, Chen YC, et al. Fulminant pulmonary calciphylaxis and metastatic calcification causing acute respiratory failure in a uremic patient. *Am J Kidney Dis.* 2006;47(4):47-53.
9. Schmidt H, Creutzfeldt W. Calciphylactic pancreatitis and pancreatitis in hyperparathyroidism. *Clin Orthop Relat Res.* 1970;69:135-145.