CASE REPORT – OPEN ACCESS

International Journal of Surgery Case Reports 76 (2020) 480–483

Contents lists available at ScienceDirect

International Journal of Surgery Case Reports

journal homepage: www.casereports.com

A rare case of gastric perforation by a 5-year-old Intra-gastric Balloon in situ: Case report and review of literature

Vijay Chander Vinod*, Muhammad Umar Younis, Humera Mubarik, Homero Rivas

Mediclinic City Hospital, Dubai Healthcare City, Dubai, United Arab Emirates

ARTICLE INFO

Article history:
Received 11 September 2020
Received in revised form 6 October 2020
Accepted 6 October 2020
Available online 12 October 2020

Keywords:
Case report
Intragastric balloon
Gastric perforation
Bariatric surgery
Acute abdomen

ABSTRACT

INTRODUCTION: Insertion of an Intra gastric Balloon (IGB) has widely been used as a minimally invasive procedure for the treatment of obesity. Gastric balloons are usually inserted for a period of six months only. They have a high safety profile and one of their rare, reported, serious complications include gastric or esophageal perforation, which are usually early and require immediate operative management.
PRESENTATION OF CASE: We report a 26-year-old lady who presented to the ED with signs and symptoms of acute abdomen and five-year history of endoscopic placement of Intra-gastric Balloon. Emergent endoscopic removal of the balloon revealed a large pressure ulcer at gastric incisura with central necrosis. Laparoscopy confirmed gastric perforation along lesser curvature with extensive soilage of peritoneal cavity. Extensive irrigation and drainage and Graham omental patch repair were carried out laparoscopically, and the perforation sealed satisfactorily. She recovered well from surgery and within days she was tolerating a diet. Broad spectrum IV antibiotics were given for 10 days.
DISCUSSION: Gastric perforation is a rare complication reported in 0.1% of patients undergoing IGB insertion. It can ensue as early as days after placement or late at weeks to months. In our review of literature, we found the maximum time frame in which a patient presented with an IGB induced gastric perforation was at 22 months. This makes our case unique as the patient was able to tolerate it for 5 years (60 months) before presenting to the emergency with this sinister complication.
CONCLUSION: Very late Gastric perforations in patients with IGB placement are rare. An upper gastrointestinal endoscopy should be arranged as soon as possible to remove the balloon and assess the stomach visualize the perforation followed by a laparoscopic approach to repair the defect if expertise is available.

1. Introduction

Obesity is a major health concern and different conventional, minimally invasive and surgical procedures are performed for its treatment.

Intra-gastric Balloon Insertion (IGB) has widely been used as a minimally invasive procedure for the treatment of overweight or obese individuals. It is considered a preferred method by many due to its safety, tolerability and relatively low cost [1], bridging the gap between the conventional methods and bariatric surgery [2,3].

The recommended indications of Intra-gastric Balloon insertion are [4]

- BMI <35 with comorbidities and resistance to conservative treatment
- BMI >35 with resistance to conservative treatment and refusal or present contraindication to surgical treatment
- BMI >50 super-obese individuals with extremely high operative risk as preparation of further surgery
- Reduction of anesthetic risk

Gastric balloons are inserted usually for a period of six months only [5] and are then retrieved endoscopically. Balloon insertion should be considered carefully in patients with large hiatus hernia, inflammatory bowel disease, and increased risk of upper GI bleed, drug/alcohol abuse and uncontrolled psychiatric disease [5].

Different types of gastric Balloons currently available in the market are [6]:

* Corresponding author.
E-mail addresses: vijay.chander@mediclinic.ae (V.C. Vinod), muhammad.umar@mediclinic.ae (M.U. Younis), humera.mubarik@mediclinic.ae (H. Mubarik), homero.rivas@mediclinic.ae (H. Rivas).

https://doi.org/10.1016/j.ijscr.2020.10.028

Gastric Balloon Brand	Material/Volume	Mode of insertion	Duration
Orbera® (Apollo Endosurgery, Inc)	Elastic silicon balloon, containing 400–500 mL of saline	most commonly used, inserted endoscopically	6 months
ReShape™ (Reshape Medical, Inc) duo	Elastic silicon, dual balloon, containing 900 mL (450 × 2 mL) saline	inserted endoscopically	to be retrieved 6 months after placement
Spatz™ adjustable balloon system (Spatz FGIA, Inc)	Elastic silicon balloon, containing 400–600 mL of saline	inserted endoscopically	allowed to be implanted for 6–12 months
Elipse™ (Allurion, Inc)	550 mL of fluid	Swallowed and naturally expelled	4 months
Obalon® (Obalan Therapeutics, Inc)	Air supplied balloon	Fluoroscopy guided, swallowed as a capsule	6 months
Heliosphere® bag (Helioscopie Medical Implants)	Polyurethane and silicon filled with air	Inserted endoscopically	6 months

Although the insertion procedure is easy and well tolerated by most of the patients, a few complications such as gastric ulcer, gastric erosion, esophagitis and GERD and spontaneous deflation of balloon can occur [7]. One of the reported serious complications of IGB is perforation (Gastric/Esophageal) which requires operative management. However, perforation usually occurs at the time of insertion or removal of the gastric balloon. We report an unusual case of gastric perforation caused by Intra-gastric Balloon 5 years after its insertion. This work has been reported in line with the SCARE 2018 criteria [8].

2. Case presentation

A 26-year-old female was referred to our Emergency Department (ED) with an acute onset of severe epigastric pain which woke her from sleep. The pain started in the epigastrium and gradually progressed to the whole abdomen and was associated with nausea but no vomiting. She also complained of several episodes of loose stools on the day of admission. Initially, she did not share with us her previous balloon placement, however after imaging and after prompting her for any previous gastric procedures, she confirmed that she had an Intra gastric balloon (IGB) placed endoscopically 5 years back and described a weight loss of 12 kg. She tolerated the balloon reasonably well; however, she did have some vague abdominal symptoms and postural pain when sleeping on her abdomen. When quizzed about the enormous delay in removal of the IGB, she reiterated that she was lost in follow up as her doctor who placed the balloon stop his practice, and while she knew about the need for removal, she did not proceed with it due to personal reasons and was tolerating it well. She did not have any obesity related comorbidities other than back pain, and was not on any chronic medication. She was a smoker and she denied any alcohol consumption. She did describe taking Celecoxib and Diclofenac for the preceding 3 weeks for back pain without any Proton Pump Inhibitor with it.

On presentation, the patient had an acute abdomen. Abdominal examination revealed generalized tenderness, with significant tenderness over the epigastrium and right upper quadrant. Patient was guarding on palpation and bowel sounds were sluggish. Vital signs showed a blood pressure of 122/74 mm Hg with a heart rate of 104/minute, regular and no fever. She had a weight of 62 kg with a BMI of 24.219. Rest of the systemic examination was unremarkable.

Initial laboratory investigations revealed a White Blood Cell (WBC) count of 28.8 K/ul (4.00–11.00) and Neutrophils 91%. Hemoglobin was 10.9 g/dl (11.5–16.0). C - reactive protein (CRP) was 426.5 mg/l (0.00–5.00) and Serum Lactate was 2.8 mmol/L (0.5–2.2). Serum beta human chorionic gonadotropin (BHCG) was negative. Chest X-Ray did not reveal any free air under diaphragm. A Computed Tomography (CT) Scan of Abdomen and Pelvis was done, which revealed moderate degree of free fluid in the abdomen and pelvis. Also seen were tiny pockets of sub capsular air below the liver and an impression of perforated and sealed bowel was entertained. Her Intra-gastric Balloon was easily identified in the mid and distal stomach, and in close contact to a very thickened gastric wall along the lesser curvature. Appendix could not be clearly visualized. In view of the above findings an urgent bariatric surgical opinion was sought.

Patient was admitted and started on broad spectrum antibiotics, intravenous fluids and kept nil per oral. She was seen by Gastroenterologist and an urgent Upper Gastrointestinal (GI) Endoscopy was performed which revealed the intact gastric balloon. The balloon was then deflated and removed without problems (Image 1).

On further visualization, we identified at the incisura, a large gastric pressure ulcer with an area of central necrosis (Image 2).

Patient was then taken for a diagnostic laparoscopy which revealed peritonitis with extensive fibrinous exudates on the stomach wall, for which extensive irrigation and drainage was done. Methylene blue was instilled through the nasogastric tube and the perforation was confirmed at the anterior stomach wall along the lesser curvature of stomach. Graham omental patch repair was carried out using viable omentum and absorbable sutures and the perforation was sealed satisfactorily. Drains were left in the sub hepatic, left hypochondrial quadrants and a nasogastric tube was kept as well. Patient recovered well from the procedure and gradually tolerated oral intake. Follow-up CT done days later did not show any intra-abdominal. She was kept on intravenous antibiotics for the completion of 2 weeks, and she was discharged in a stable condition from the hospital. She remained well on follow up at 3 weeks and 6 weeks after surgery. Eight weeks after surgery, she had a follow-up endoscopy and by then, her stomach had healed completely and there was no evidence of persistent ulcer. During the first 3 months after surgery she continued taking PPIs and she finally quit smoking.

We report a 26-year-old lady who presented to the ED with gastric perforation caused by a long standing Intra Gastric Balloon of 5 years duration.

3. Discussion

Intragastric balloon (IGB) placement has been endorsed as a minimally invasive procedure in the armamentarium of a bariatric endoscopist, including gastroenterologists and surgeons, and has generally been accepted as safe and efficient [1] in the care of obese patients. It has been extensively used around the world for at least 20 years [3], due to its ease of insertion and its simplicity and reversibility. Not only it has been used in obese and overweight patients, but also it has been used in patients with prohibitive risk for surgery or refusing to do so. Its modus operandi includes induction of early satiety due to reduction of effective gastric volume and delaying gastric emptying [3]. Studies have reported an average loss of excess body weight of between 32.1% and 55.6% at 6 months after placement [3,10,11]. The balloon is usually deployed endoscopically, but it can be self-administered like the Elipse balloon which is swallowed and is usually recommended to be left in place in the stomach for a maximum of 6 months while the patient is receiving proton pump inhibitors and takes part in a supervised weight loss program [5,9]. Despite the benefits and availability of evolving products in the market, various complications related to

Image 1. Intra-gastric Balloon deflated and removed from the stomach.

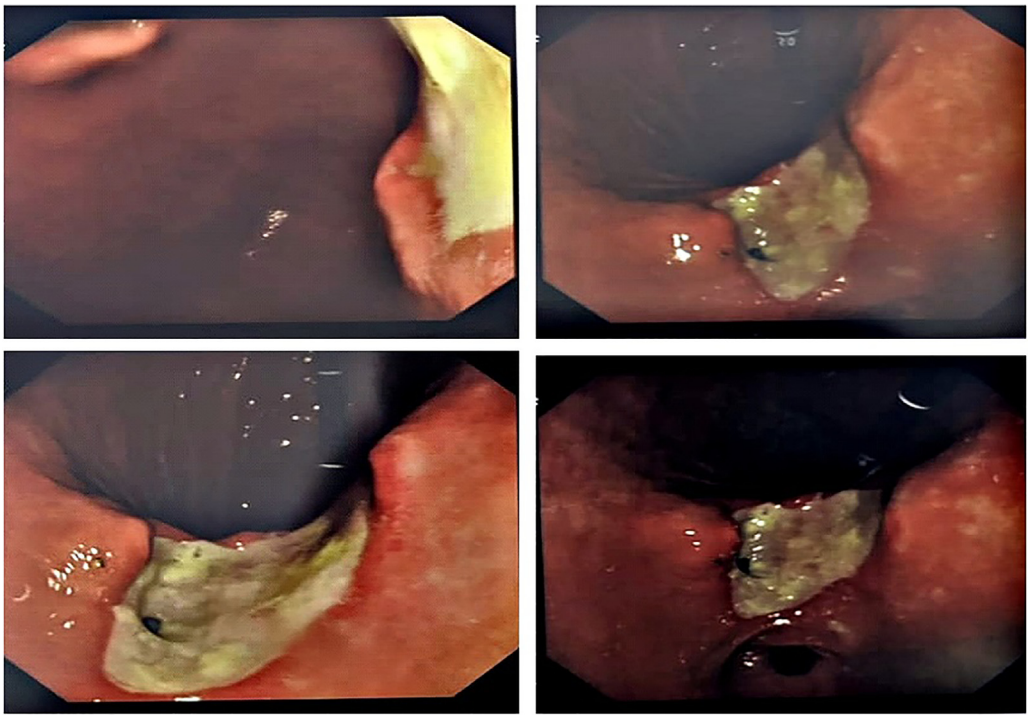

Image 2. Endoscopy showing large gastric pressure ulcer with an area of central necrosis.

the procedure have also been described in literature which include gastrointestinal ulceration, gastric perforation, esophageal perforation, distal migration, gastric bleeding and intestinal obstruction [12,13].

Gastric perforation is a rare complication reported in 0.1% of patients undergoing IGB insertion [13]. It can ensue as early as days after placement or late at weeks to months [14]. In our review of literature, we found the maximum time frame in which a patient presented with an IGB induced gastric perforation was at 22 months [15]. This makes our case unique as she was able to tolerate it for 5 years (60 months) before presenting to the emergency with this sinister complication. The underlying mechanisms are poorly described, and different theories have proposed pressure necrosis leading to ischemic ulcer and perforation [16] along with noncompliance of PPI post insertion and excessive intake of Non Steroidal Anti Inflammatory Drugs [14] smoking, etc. The location of the

perforation is usually described to be on the anterior wall of the stomach as was seen in our case as well [17] and may be due to the selective impaction of the balloon above the incisura inducing pressure necrosis [18].

A low threshold of diagnosis should be entertained in patients with a history of IGB insertion and presentation with sudden upper abdominal pain. A contrast enhanced CT scan should be ordered despite normal laboratory values and x ray findings to exclude the possibility of a perforation. These perforations have been customarily dealt with an open laparotomy approach in most cases to ensure removal of the balloon and closure of the perforation. However, the presence of an expert endoscopist in the team can be extremely helpful and a minimally invasive combined endoscopic-laparoscopic procedure can be capably carried out to treat such a patient. Our case illustrates the advantage of such an approach and emphasizes the need for early diagnosis and optimal collaboration between multidisciplinary team members in dealing with bariatric related complications.

4. Conclusion

Extremely late Gastric perforations in patients with IGB placement may occur and a low threshold for diagnosis should be maintained in such patients. An upper gastrointestinal endoscopy should be arranged as soon as possible with an attempt to remove the balloon and visualize the perforation followed by a laparoscopic approach to repair the defect if expertise is available.

Declaration of Competing Interest

No conflicts of interest.

Funding

No funding.

Ethical approval

Exemption for Ethical approval given from the Mediclinic Research & Ethic Committee, as it was only a case report.

Consent

Written informed consent was obtained from the patient for publication of this case report and accompanying images. A copy of the written consent is available for review by the Editor-in-Chief of this journal on request.

Author contribution

Dr. Vijay Chander Vinod – Original draft writing and editing.
Dr. Muhammad Umar Younis – Draft writing, editing, images editing, literature review.
Dr Humera Mubarik – Draft writing.
Dr. Homero Rivas – Bariatric Surgeon who performed the surgical procedure. Reviewing & editing the draft.

Registration of research studies

Not applicable.

Guarantor

Dr Vijay Vinod.
Dr Muhammad Umar.
Dr Humera Mubarik.
Dr Homero Rivas.

Provenance and peer review

Not commissioned, externally peer-reviewed.

References

[1] George Stavrou, Georgia Tsaousi, Katerina Kotzampassi, Life-threatening visceral complications after Intragastric balloon insertion: is the device, the patient or the doctor to blame? Endosc. Int. Open 7 (February (2)) (2019) E122–E129.
[2] F. Puglisi, N. Antonucci, P. Capuano, L. Zavoianni, P. Lobascio, G. Martines, G. Lograno, V. Memeo, Intragastric balloon and binge eating, Obes. Surg. 17 (April (4)) (2007) 504–509, http://dx.doi.org/10.1007/s11695-007-9088-0, PMID: 17608263.
[3] P. Laing, T. Pham, L.J. Taylor, et al., Filling the void: a review of Intragastric balloons for obesity, Dig. Dis. Sci. 62 (2017) 1399–1408.
[4] Marko Nikolic, Marko Boban, Neven Ljubičić, Vladimir Supanc, Gorana Mirosević, Borka Pezo-Nikolić, Vanja Zjacić-Rotkvić, Petar Gaćina, Milan Mirković, Miroslav Bekavac-Beslin, Position of Intragastric balloons in global initiative for obesity treatment, Coll. Antropol. 35 (2011) 1353–1362.
[5] K. Kotzampassi, V. Grosomanidis, P. Papakostas, et al., 500 Intragastric balloons: what happens 5 years thereafter? Obes. Surg. 22 (2012) 896–903.
[6] S.H. Kim, H.J. Chun, H.S. Choi, E.S. Kim, B. Keum, Y.T. Jeen, Current status of Intragastric balloon for obesity treatment, World J. Gastroenterol. 22 (24) (2016) 5495–5504, http://dx.doi.org/10.3748/wjg.v22.i24.5495.
[7] H. Coskun, S. Bozkurt, A case of asymptomatic fungal and bacterial colonization of an Intragastric balloon, World J. Gastroenterol. 15 (45) (2009) 5751–5753.
[8] R.A. Agha, M.R. Borrelli, R. Farwana, K. Koshy, A. Fowler, D.P. Orgill, For the SCARE Group, The SCARE 2018 statement: updating consensus Surgical CAse REport (SCARE) guidelines, Int. J. Surg. 60 (2018) 132–136.
[9] A. Genco, T. Bruni, S.B. Doldi, et al., Bio enterics Intragastric balloon: the Italian experience with 2,515 patients, Obes. Surg. 15 (2005) 1161–1164.
[10] K. Kotzampassi, A.D. Shrewsbury, P. Papakostas, et al., Looking into the profile of those who succeed in losing weight with an Intragastric balloon, J. Laparoendosc. Adv. Surg. Tech. A 24 (2014) 295–301.
[11] B.K. Abu Dayyeh, N. Kumar, S.A. Edmundowicz, et al., ASGE Bariatric Endoscopy Task Force and ASGE Technology Committee. ASGE Bariatric Endoscopy Task Force systematic review and meta-analysis assessing the ASGE PIVI thresholds for adopting endoscopic bariatric therapies, Gastrointest. Endosc. Clin. N. Am. 82 (2015) 425–438.
[12] G. Lopez-Nava, R. Asokkumar, I. Bautista, et al., Spontaneous hyperinflation of Intragastric balloon: what caused it? Endoscopy 52 (5) (2020) 411–412.
[13] B.M. Abou Hussein, A.A. Khammas, A.M. Al Ani, et al., Gastric perforation following Intragastric balloon insertion: combined endoscopic and laparoscopic approach for management: case series and review of literature, Obes. Surg. 26 (5) (2016) 1127–1132.
[14] A.A. Rahman, K. Loi, Gastric perforation as a complication of Intragastric balloon, Surg. Obes. Relat. Dis. 14 (5) (2018) 719–722.
[15] R. Baigel, F. Rashid, D. Shrestha, D. Ravichandran, Peritonitis following a bariatric procedure in a young woman, BMJ Case Rep. (February) (2011), http://dx.doi.org/10.1136/bcr.12.2010.3602.
[16] D. Dayan, B. Sagie, S. Fishman, Late Intragastric balloon induced gastric perforation, Obes. Surg. 26 (5) (2016) 1138–1140.
[17] S.A. Barrichello Junior, I.B. Ribeiro, R.J. Fittipaldi-Fernandez, et al., Exclusively endoscopic approach to treating gastric perforation caused by an Intragastric balloon: case series and literature review, Endosc. Int. Open 6 (2018) E1322–E1329.
[18] R. Caruso, E. Vicente, Y. Quijano, et al., A combined laparoscopic and endoscopic approach for an early gastric perforation secondary to Intragastric balloon: endoscopic and surgical skills with literature review [published online ahead of print, 2020 May 26], Obes. Surg. (2020), http://dx.doi.org/10.1007/s11695-020-04727-6.