

SHORT REPORT

Endovascular Stent Grafting of a Deep Femoral Artery Pseudoaneurysm

P.E. Ocke Reis ^{a,c,*}, L. Roever ^b, I.F. Ocke Reis ^c, F. de Azambuja Fontes ^c, M. Rotolo Nascimento ^c, L. Nunes dos Santos ^c, P. de Almeida Sandri ^c

^a Department of Specialized and General Surgery, Fluminense Federal University, Rio de Janeiro, Brazil

^b Department of Clinical Research, Federal University of Uberlandia, Brazil

^c Vascular Clinic Ocke Reis, Rio de Janeiro, Brazil

Introduction: Pseudoaneurysms (PSAs) are uncommon, but can occur as a complication of orthopedic procedures, usually associated with femur surgery. This report describes successful management of a PSA of the deep femoral artery (DFA) with an endovascular stent graft.

Report: This case reports an injury that presented as a false aneurysm secondary to a fractured neck of femur, which was initially confused with hematoma. Imaging confirmed the diagnosis of PSA, and the decision was taken to implant an endovascular stent graft.

Discussion: The endovascular stent graft was implanted based on radiological, anatomical, and clinical parameters. This case supports the feasibility, safety, and efficacy of stenting for PSA of the DFA.

© 2016 The Author(s). Published by Elsevier Ltd on behalf of European Society for Vascular Surgery. This is an open access article under the CC BY-NC-ND license (<http://creativecommons.org/licenses/by-nc-nd/4.0/>).

Article history: Received 17 May 2016, Revised 26 July 2016, Accepted 29 July 2016,

Keywords: Pseudoaneurysm, Covered stent aneurysm, Deep femoral artery, Endovascular repair

INTRODUCTION

Fractured femur neck is a common presentation and arterial injury is a rare but recognized complication of proximal femur fractures.^{1–4} Most injuries are sub-clinical and radiological imaging is used to confirm the suspicion using duplex ultrasonography, computed tomography angiography (CTA), or angiography during the procedure. Depending on the anatomical characteristics and hemodynamic status of the patient, either an open or endovascular approach should be performed.^{1–10} This case reports a femoral fracture with delayed presentation of a deep femoral artery pseudoaneurysm (DFA-PSA) that was, at first confused with hematoma and initially presented with bleeding after orthopedic surgery. It was managed successfully with an endovascular stent graft after diagnosis.^{3,4,10}

REPORT

A 66 year old man presented with a fracture of the left femoral neck after falling. There was bruising in the left

hip and thigh after the orthopedic surgery. Four months later, the patient was admitted to a general hospital for treatment of the hematoma, which was drained by the orthopedic team. Post-operatively, the patient developed bleeding and falling hematocrit. Image evaluation with arterial color Doppler and CTA confirmed the diagnosis of PSA. Doppler showed turbulent flow within the saccular structure with a wide communication with the DFA. CTA confirmed the presence of a 6.37 cm × 6.12 cm PSA in the DFA (Fig. 1). From a right common femoral artery puncture, a 6 Fr percutaneous Sheath Introducer was introduced, the left PFA was catheterized, and selective arteriography revealed an iatrogenic PSA (Fig. 2), which was successfully treated by stent graft repair. Two covered endovascular stent grafts (ADVANTA STENT Graft- 5 × 22 mm and 6 × 22 mm) were deployed into the feeding vessel with complete exclusion of the PSA (Fig. 3). PFA patency with no recurrence was confirmed at post-operative follow up by Duplex scan and CT (Figs. 4–6).

* Corresponding author. Department of Specialized and General Surgery, Fluminense Federal University, Rio de Janeiro, Brazil.

E-mail address: vascular@pauloocke.com.br (P.E. Ocke Reis).

2405-6553/© 2016 The Author(s). Published by Elsevier Ltd on behalf of European Society for Vascular Surgery. This is an open access article under the CC BY-NC-ND license (<http://creativecommons.org/licenses/by-nc-nd/4.0/>).

<http://dx.doi.org/10.1016/j.ejvssr.2016.07.004>

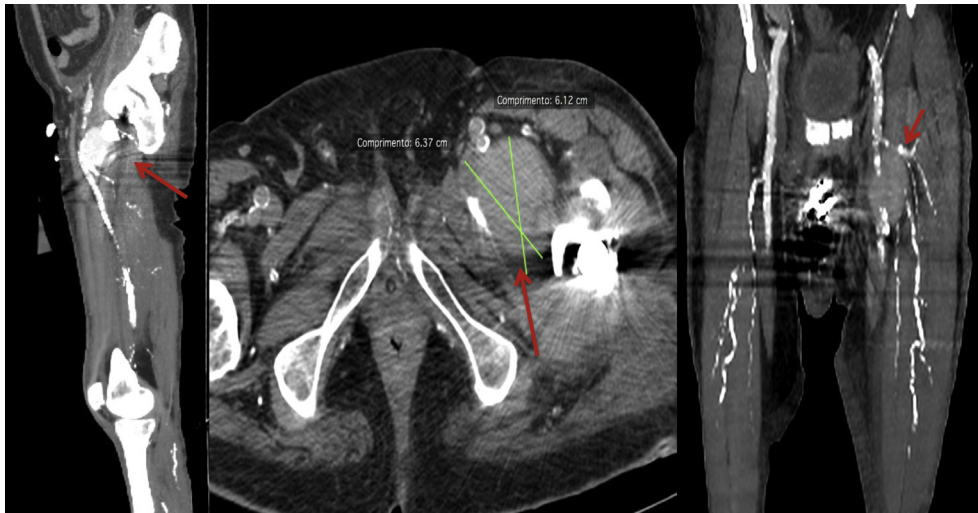

Figure 1. From left to right, the red arrows show contrast CTscan with PSA. CTA confirmed the presence of a 6.37 cm × 6.12 cm PSA in the DFA.

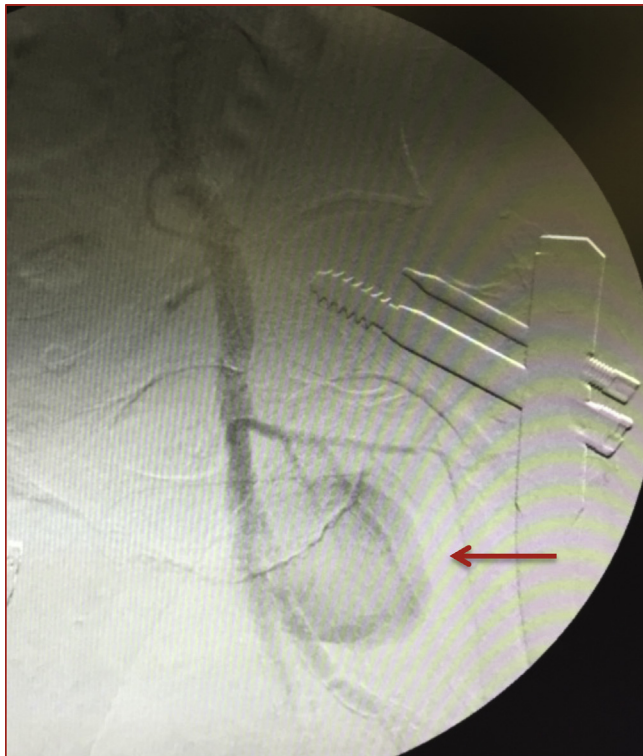


Figure 2. Angiography and filling of the superficial and DFA and the associated PSA (red arrow).

DISCUSSION

Injury to the DFA accounts for approximately 2% of peripheral arterial wounds.^{5,6} Undiagnosed complications include PSA and arteriovenous fistula.⁶ In cases of DFA in association with proximal femur fractures in orthopedic procedures, the possibility of PSA should be considered; however, no update based on trustworthy data has been published about this possibility. Only a few cases have been reported in the literature, analyzing a total of 131 cases of

arterial PSAs and concluding that arteriography is the investigation of choice to confirm the diagnosis, while good options for treatment are embolization for small branch PSAs or stent grafts for PSAs originating from arterial trunks (as in the present case).⁷ Alternatively, surgical ligation or repair of PSAs is still an option.^{6,7} This is the treatment of choice in the presence of rupture, limb ischemia, or distal embolization.³ There are several other reports of DFA-PSAs being treated with various embolization techniques.^{6,8} Waldher et al. showed advances in endovascular procedures with embolic materials that made PSA treatment safe and efficient.⁸ Others agree that endovascular stent graft placement is safe,^{3,4,9,10} and this was therefore chosen as the most appropriate treatment option for the present case.

Endovascular grafting may be of particular value in patients with significant comorbid conditions such as older age, diabetic complications, cardiac or pulmonary dysfunction, and patients who are not considered good candidates for open surgery. Many physicians prefer the less invasive endovascular intervention in such cases.^{3,4,9,10}

In the present case, a covered stent was used to prevent flow into the pseudoaneurysm while maintaining vessel patency and DFA flow to the lower extremity. Two covered stents were necessary for the patient, showing trunk patency and complete exclusion of the PSA (Figs. 3 and 6) as in the literature.^{3,4,9,10}

Another study published a series of six femoral PSAs with endografts in high risk patients after previous vascular surgery treated with stent graft implantation.¹⁰ That study concluded that femoral PSAs can be excluded successfully and that vessel occlusion is not expected.¹⁰ The present authors prefer an endovascular approach as endograft use has been well established based on anatomical and clinical parameters. Others have highlighted the decision to use covered stents suggested by the type of lesion and a large tear in the arterial wall.³

The literature confirms the observations in this report in relation to the use of the stent graft; however, each case

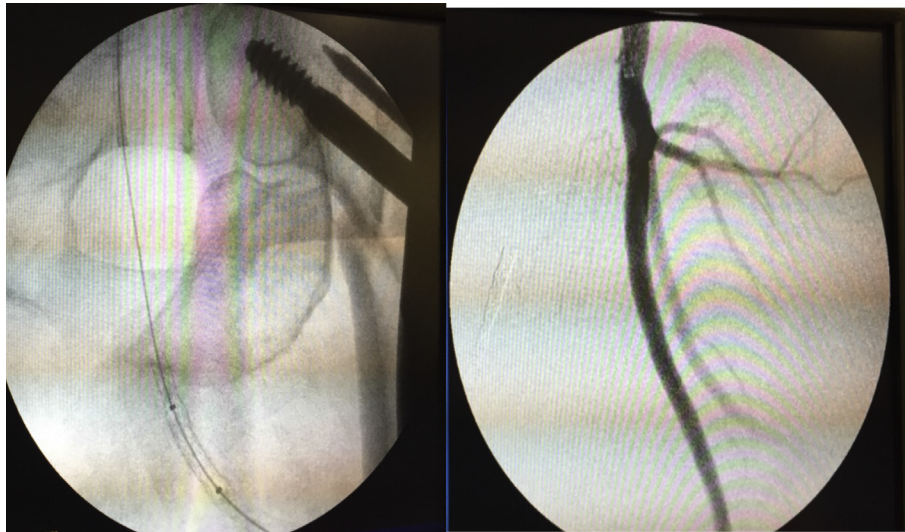


Figure 3. From left to right, the stent graft position and angiography showing the final result after stenting deployment.

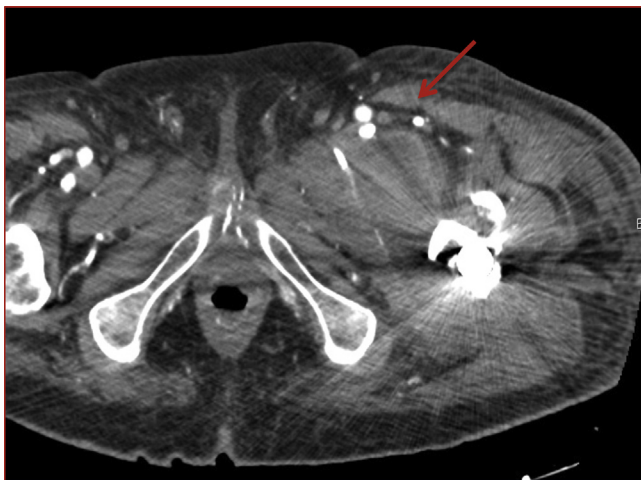

Figure 4. Contrast CT scan with no PSA after treatment (red arrow).

must be evaluated individually in the event of a rupture and decision making must be quicker so as not to endanger the patient's life. Conventional open procedures may yet provide a suitable and necessary option for treatment.

Pitfalls and limitations

A surveillance program with appropriate management of possible in-stent intimal hyperplasia may improve the long-term patency.

Conclusion

This case highlights the need for increased awareness of the possibility of PSA of the DFA in association with proximal femur fractures. Early outcome data from patients who underwent DFA revascularization with covered stents indicate that the procedure is safe with low complication rates.

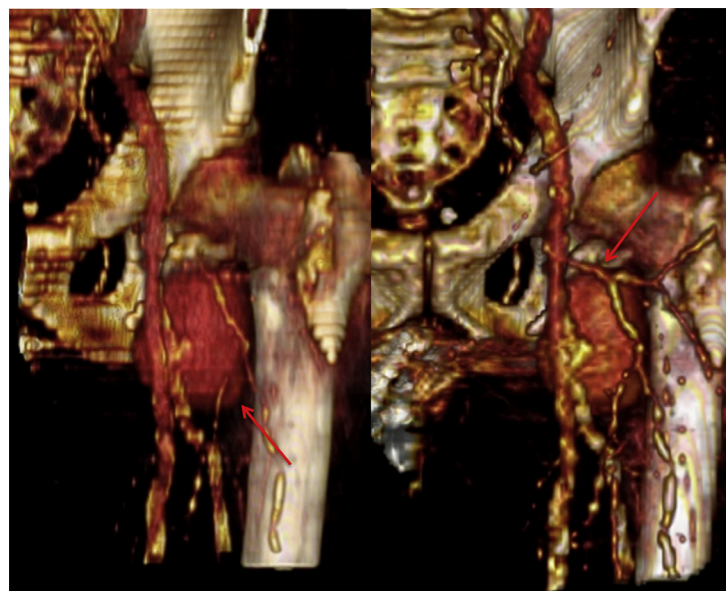


Figure 5. 3D angiogram reconstruction showing PSA with lateral and anterior view (red arrow) from left to right, respectively.

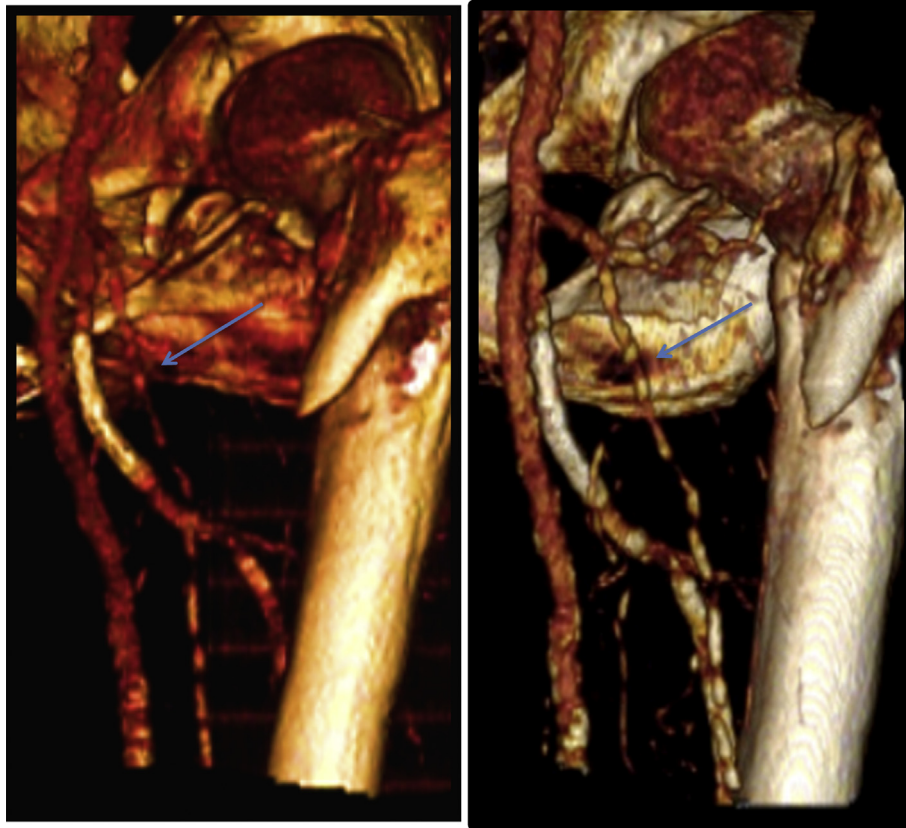


Figure 6. DFA with covered stents (blue arrow) best seen on 3D images.

FUNDING

None.

CONFLICT OF INTEREST

None.

REFERENCES

- Murphy PG, Geoghegan JG, Austin O, More-O'Ferrall R, Quinlan WR, Keaveny TV. Pseudoaneurysm of the profunda femoris artery due to intertrochanteric fracture of the hip. *Arch Orthop Trauma Surg* 1999;**119**:117–8.
- Hanna GB, Holdsworth RJ, McCollum PT. Profunda femoris artery pseudoaneurysm following orthopaedic procedures. *Injury* 1994;**25**:477–9.
- Dorrucci V, Spinamano L, Petralia G, Griselli F, Cibi N, Adornetto R. Endovascular repair of a large deep femoral artery branch pseudoaneurysm following a femur fracture: a case report. *EJVES* 2008;**15**:21–3.
- Saha S, Trompetas V, Al-Robaie B, Anderson H. Endovascular stent graft management of a ruptured profunda femoris artery aneurysm. *EJVES* 2010;**19**:e38–40.
- Synder III WH, Thal ER, Perry MO. Vascular injuries of the extremity. In: Rutherford RB, editor. *Vascular surgery*. Philadelphia: Saunders; 1989. p. 613–37.
- Naouli H, Jiber H, Bouarhroum A. False aneurysm of perforating branch of the deep femoral artery—report of two cases. *Int J Surg Case Rep* 2015;**14**:36–9.
- Raherinantenaina F, Rajaonahary TMA, Rakoto Ratsimba HN. Update on diagnostic and therapeutic features of peripheral artery pseudoaneurysms following orthopedic and traumatic surgery. *Rev Vasc Med* 2015;**3**:16–21.
- Waldher RC, Kickuth R, Ludwig K, Do DD, Triller J. Superselective embolization of deep femoral artery branch pseudoaneurysm with a coaxial microcatheter system. *Vasa* 2006;**35**:45–9.
- Thalhammer C, Kirchherr AS, Uhlich F, Waigand J, Gross CM. Postcatheterization pseudoaneurysms and arteriovenous fistulas: repair with percutaneous implantation of endovascular covered stents. *Radiology* 2000;**214**:127–31.
- Derom A, Nout E. Treatment of femoral pseudoaneurysms with endograft in high risk patients. *EJVES* 2005;**30**:644–7.