

ORIGINAL PAPER

Comparative examination of pinniped craniofacial musculature and its role in aquatic feeding

Sarah S. Kienle¹  | Roxanne D. Cuthbertson² | Joy S. Reidenberg³ 

¹Department of Biology, Baylor University, Waco, Texas, USA

²Department of Biology and Marine Biology, University of North Carolina Wilmington, Wilmington, North Carolina, USA

³Icahn School of Medicine at Mount Sinai, Center for Anatomy and Functional Morphology, New York, New York, USA

Correspondence

Sarah S. Kienle, Department of Biology, Baylor University, One Bear Place #97388, Waco, TX 76798, USA.
Email: sarah_kienle@baylor.edu

Funding information

American Museum of Natural History; National Oceanic and Atmospheric Administration; University of California Santa Cruz

Abstract

Secondarily aquatic tetrapods have many unique morphologic adaptations for life underwater compared with their terrestrial counterparts. A key innovation during the land-to-water transition was feeding. Pinnipeds, a clade of air-breathing marine carnivorans that include seals, sea lions, and walruses, have evolved multiple strategies for aquatic feeding (e.g., biting, suction feeding). Numerous studies have examined the pinniped skull and dental specializations for underwater feeding. However, data on the pinniped craniofacial musculoskeletal system and its role in aquatic feeding are rare. Therefore, the objectives of this study were to conduct a comparative analysis of pinniped craniofacial musculature and examine the function of the craniofacial musculature in facilitating different aquatic feeding strategies. We performed anatomic dissections of 35 specimens across six pinniped species. We describe 32 pinniped craniofacial muscles—including facial expression, mastication, tongue, hyoid, and soft palate muscles. Pinnipeds broadly conform to mammalian patterns of craniofacial muscle morphology. Pinnipeds also exhibit unique musculoskeletal morphologies—in muscle position, attachments, and size—that likely represent adaptations for different aquatic feeding strategies. Suction feeding specialists (bearded and northern elephant seals) have a significantly larger masseter than biters. Further, northern elephant seals have large and unique tongue and hyoid muscle morphologies compared with other pinniped species. These morphologic changes likely help generate and withstand suction pressures necessary for drawing water and prey into the mouth. In contrast, biting taxa (California sea lions, harbor, ringed, and Weddell seals) do not exhibit consistent craniofacial musculoskeletal adaptations that differentiate them from suction feeders. Generally, we discover that all pinnipeds have well-developed and robust craniofacial musculature. Pinniped head musculature plays an important role in facilitating different aquatic feeding strategies. Together with behavioral and kinematic studies, our data suggest that pinnipeds' robust facial morphology allows animals to switch feeding strategies depending on the environmental context—a critical skill in a heterogeneous and rapidly changing underwater habitat.

KEYWORDS

adaptation, biting, foraging, marine mammals, morphology, suction

This is an open access article under the terms of the Creative Commons Attribution-NonCommercial License, which permits use, distribution and reproduction in any medium, provided the original work is properly cited and is not used for commercial purposes.

© 2021 The Authors. *Journal of Anatomy* published by John Wiley & Sons Ltd on behalf of Anatomical Society

1 | INTRODUCTION

Diverse tetrapod lineages have reinvaded the aquatic environment, including birds, mammals, and reptiles (Schwenk, 2000; Taylor, 1987; Werth, 2000). Secondarily aquatic tetrapods underwent substantial modifications to their behavior, ecology, morphology, and physiology during these independent transitions from terrestrial to aquatic ecosystems (Ashley-Ross et al., 2013; Blob et al., 2014; Zimmer, 1999). Tetrapod adaptations for aquatic life include the development of streamlined bodies, increased oxygen storage capabilities, and modifications of multiple sensory systems (Kelley & Motani, 2015; Kelley & Pyenson, 2015; Thewissen & Nummela, 2008).

Pinnipeds (seals, sea lions, and walruses) are a recently derived group of marine mammals that evolved from terrestrial carnivorans and reentered the marine environment ~30 million years ago (Berta et al., 2018). Unlike most marine mammals (e.g., cetaceans, sirenians), pinnipeds retain an amphibious lifestyle, spending most of their time at sea feeding but returning to land annually to breed and molt (Fish, 2000; Liwanag et al., 2012; Werth, 2000). The pinniped skull exhibits many adaptations for aquatic life compared with their terrestrial ancestors, including larger orbits (and therefore larger eyes) for better visual acuity at depth and increased surface area of the nasal turbinates associated with heat and water conservation (as opposed to olfaction; Debey & Pyenson, 2013; Schusterman et al., 2000; Van Valkenburgh et al., 2011).

Pinnipeds (along with all secondarily aquatic tetrapods) had to overcome a major obstacle in the land-to-water transition: capturing and consuming prey underwater (Kienle et al., 2017; Taylor, 1987; Werth, 2000). Prey capture underwater fundamentally differs from prey capture in air, as water is more viscous and denser than air. Pinnipeds have converged on three underwater feeding strategies: biting, filter feeding, and suction feeding (Hocking et al., 2017; Kienle et al., 2017; Taylor, 1987; Werth, 2000). Each of these feeding strategies is associated with specific skull and dental adaptations, feeding behaviors, and kinematics (Adam & Berta, 2002; Churchill & Clementz, 2015; Hocking et al., 2013, 2015, 2016; Jones & Goswami, 2010; Jones et al., 2013; Kienle & Berta, 2016, 2018; Kienle et al., 2018, 2019, 2020; Marshall et al., 2008, 2014).

Although many studies have examined the pinniped skull and dental morphology, little is known about pinniped craniofacial musculature and the role it plays in facilitating different aquatic feeding strategies. Studies of pinniped head musculature are limited to the following: 1. Descriptions of the craniofacial and tongue musculature of the California sea lion (*Zalophus californianus*; Howell, 1929; Mori, 1958), the harbor seal (*Phoca vitulina*; Howell, 1929), the Weddell seal (*Leptonychotes weddellii*; Pierard, 1971) and the walrus (*Odobenus rosmarus*; Gordon, 1984; Kastelein et al., 1991); 2. Broad descriptions of craniofacial muscle groups in the southern sea lion (*Otaria byronia*; Murie, 1872) and the Ross seal (*Ommatophoca rossi*; King, 1969); and 3. Descriptions of the tongue of South American fur seals (*Arctocephalus australis*) and sea lions (*Otaria flavescens*; Erdoğan et al., 2015) and the eye musculature of the Baikal seal (*Pusa*

sibirica; Endo et al., 1998). With the singular exception of Erdoğan et al. (2015), previous studies focused only on a single species, which was often represented by a single individual.

The craniofacial musculoskeletal system is an integral part of the mammalian feeding apparatus (Hiimae, 1967; Hiimae & Crompton, 1985; Kienle et al., 2015; Konow et al., 2010; Naples, 1999). The paucity of pinniped musculoskeletal studies hinders our ability to understand biologic integration between anatomy and feeding behavior; further, this limits our ability to test hypotheses about the functional adaptations of pinnipeds in response to an aquatic environment. Therefore, the first objective of this study was to conduct a detailed comparative analysis of pinniped craniofacial musculature. We dissected and compared the craniofacial muscles of multiple individuals across six pinniped species, including representatives of the two largest pinniped clades: phocids (true seals) and otariids (sea lions, fur seals). The second objective was to examine the relationship between the pinniped craniofacial musculoskeletal system and aquatic feeding strategies. We compared the craniofacial musculature between pinniped species with skull morphologies adapted for biting versus those adapted for suction feeding. Filter feeders were not available for comparison. We hypothesized that pinnipeds with skull adaptations for a particular feeding strategy—biting or suction—would have corresponding craniofacial musculature adaptations. Specifically, we predicted that species with skull adaptations for biting would have more robust and better-developed muscles of mastication associated with producing strong bite forces. In contrast, we predicted that suction feeding specialists would have a more robust tongue and hyoid musculature for generating the pressure differential to draw water and prey into the mouth. Together, the results of this study provide the first broad-scale comparative data on pinniped craniofacial musculature. We demonstrate the importance of the land-to-water transition in driving morphologic adaptations and highlight the role of diverse musculoskeletal adaptations for different aquatic feeding strategies.

2 | METHODS

We conducted detailed dissections of the craniofacial musculoskeletal anatomy of six pinniped species across 35 individuals: bearded seals (*Erignathus barbatus*, $n = 6$), California sea lions ($n = 5$), harbor seals ($n = 6$), northern elephant seals (*Mirounga angustirostris*, $n = 11$), ringed seals (*Pusa hispida*, $n = 6$), and Weddell seals ($n = 1$; Table S1, Figure 1). Specimens were obtained from the Alaska Department of Fish and Game, the Marine Mammal Center, Moss Landing Marine Lab, Ohio University, the Pacific Marine Mammal Center, SeaWorld San Diego, the University of Alaska, and the University of California Santa Cruz (UCSC). Specimens were obtained through NMFS permits #358-1787, #15324, #18786-04; MMHSRP #18786-04, and NMFS Southwest Region letters of authorization to A. Berta (San Diego State University) and S. Kienle (UCSC). All specimens were opportunistically collected and included different age classes and sexes. Specimens in this study consisted of either the whole head

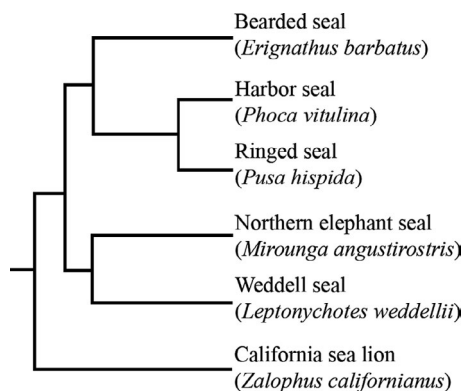


FIGURE 1 Phylogenetic relationships of the six pinniped species in this study modified from Fulton and Strobeck (2010), Amson and de Muinoz (2014), and Paterson et al. (2020)

including the hyoid apparatus in situ, the whole head with the hyoid apparatus ex situ, or the whole head without an associated hyoid apparatus.

All specimens showed little to no tissue decomposition and were frozen shortly after death to prevent further tissue degradation. Prior to dissection, each specimen was thawed for 1–2 days. We then took scaled photographs, measured, and described the external morphology of each specimen. Skull length and width measurements were collected in situ. Skull area (or lateral projected area) was measured in two dimensions from scaled photographs in ImageJ v. 32 (Schneider et al., 2012).

A dorso-caudal to dorso-rostral midline incision was made on each specimen to reveal the internal anatomic relationships. Skin, blubber, and superficial fascia were carefully peeled away to expose the underlying craniofacial muscles. The general morphology and the muscular and ligamentous connections between bony and cartilaginous elements were examined. The muscle origin, insertion, and fiber direction were documented and described for each individual muscle that could be identified. We infer the muscle action by assuming shortening along the axis of the muscle fiber as they contract along the path of the whole muscle between the origin and insertion. Muscle terminology follows Evans and de Lahunta (2013), except where noted. We documented the three-dimensional (3D) arrangement between muscles and bony elements and reported inter- and intraspecific variation when observed.

In situ measurements—maximum length (straight rostral-caudal distance from rostral tip of the skull to the caudal edge of occipital condyles), width (straight mediolateral distance from lateral edges of the zygomatic arch), and depth (straight dorsoventral distance from sagittal crest to auditory bullae)—were measured for each muscle when possible. We used scaled photographs to take ex situ measurements of the maximum length and width of each muscle in two dimensions in ImageJ. Muscle area was calculated from tracing the perimeter of the muscle in scaled photographs. We then calculated the muscle-to-skull area ratio (MSR) for each muscle, which was obtained by dividing each muscle area by the skull area to standardize

for head size. We calculated the mean MSR for each craniofacial muscle group within each species (e.g., facial expression, mastication, tongue, hyoid, soft palate) for interspecific comparisons.

We ran linear models to compare the relationship between relative muscle size (MSR), species, and feeding strategy and determined significance using ANOVAs (car package; Bates et al., 2014; Fox & Weisberg, 2011). We examined the relationship between muscle size and species with species as the predictor variable and between muscle size and feeding strategy with feeding strategy as the predictor variable. We used least-square means to perform Tukey posthoc pairwise contrasts between each significant predictor variable (lsmeans package; Lenth, 2016). Residual plots for each model were examined for deviations from normality and homoscedasticity. When heteroscedasticity was observed, data were log-transformed.

Additionally, we examined variability in MSR for each muscle and species by quantifying the coefficient of variation (CV, standard deviation [SD]/mean) for each muscle. The CV measures variation in a trait. A low CV (values close to 0) indicates stereotypy, whereas a high CV (values close to 1) indicates high variability (Gerhardt, 1991; Wainwright et al., 2008). All statistical analyses were conducted in R v. 3.5.3 (R Core Team, 2019). Data and codes are available online (Kienle, 2021).

3 | RESULTS

We identify 34 craniofacial muscles that are associated with facial expression ($n = 13$), mastication ($n = 5$), the tongue ($n = 4$), hyoid ($n = 9$), and soft palate ($n = 3$) across the six pinniped species in this study. We describe the general muscle morphology, including the position, origin, insertion, and fiber direction, for each craniofacial muscle below. Intra- and interspecific variation in muscle morphology is noted afterward for each muscle when applicable.

3.1 | Facial expression muscles

3.1.1 | Platysma

The platysma is a thin superficial muscle immediately underneath the skin and blubber layers (Figure 2). It extends along the lateral sides of the head. The platysma travels from its origin caudal to neck (which was not included in any specimens in this study) to its insertion into connective tissue at the lateral corners of the mouth, which is immediately caudal to the orbicularis oris. The platysma is located on either side of the skull, and the two portions of the muscle do not connect along the entire length of the cranium. The platysma muscle fibers run caudo-rostrally. The platysma narrows as it travels rostrally toward its insertion in the mouth. The platysma is bordered rostrally by the orbicularis oris, ventrally by the sphincter colli profundus, and is superficial to the masseter. The action of the platysma is to draw the lips caudally.

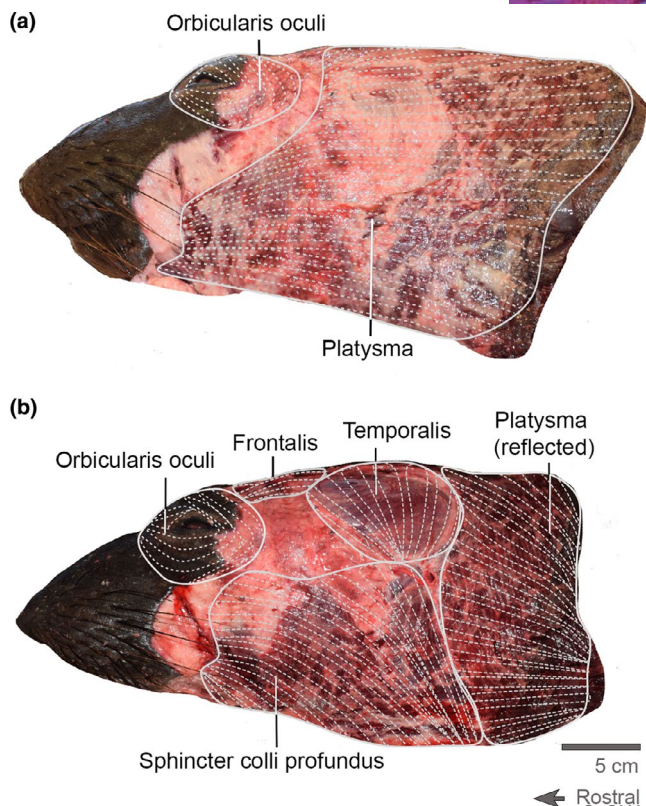


FIGURE 2 Superficial pinniped facial expression muscles shown in lateral view on a northern elephant seal. (a) Outer-most layer of craniofacial muscles after the skin and blubber layers are removed. (b) Deeper layer of craniofacial muscles, with the platysma reflected caudally

California sea lions have the largest platysma, and ringed seals have the smallest after correcting for skull size (Table S2). The platysma merges with the sphincter colli profundus to form a single sheet of muscle in bearded seals and California sea lions. The two muscles are differentiated by a marked change in fiber direction along the ventral edge of the mandible. The platysma fibers travel rostro-caudally and the sphincter colli profundus fibers travel dorso-ventrally. The platysma in California sea lions and northern elephant seals has attachments to the ventral side of the mandible and to the lateral and ventral edges of the zygomatic arch. This differs from other pinniped species where the platysma does not directly attach to bone. Additionally, the platysma in both California sea lions and northern elephant seals has a small slip of muscle that extends dorsally and attaches to the caudal and dorsal edge of the squamosal bone. The platysma in California sea lions also extends around the ventral edge of the mandible, wraps ventrally and medially around the digastric, and attaches to the medial edge of the mandible.

3.1.2 | Sphincter colli profundus

The sphincter colli profundus is a thin sheet of muscle on the ventral portion of the skull (Figure 2b). It originates caudal to the hyoid and throat musculature (which was not preserved in any specimens in

this study) and inserts onto the ventral edge of the mandibular symphysis. The muscle fibers run mediolaterally and meet at the midline on the ventral side of the skull. The sphincter colli profundus is superficial to the mylohyoid and bordered dorsally by the platysma along the lateral edge of the mandible. The sphincter colli profundus has fibrous attachments to the platysma but is differentiated by a marked change in fiber direction. The sphincter colli profundus supports the tongue and hyoid musculature of the lower jaw and acts as a sling that tightens when contracted.

Northern elephant seals have the largest sphincter colli profundus, and Weddell seals have the smallest after correcting for skull size (Table S2). The sphincter colli profundus forms a single muscle layer with the platysma in bearded seals and California sea lions. The sphincter colli profundus in northern elephant seals extends dorsally along the lateral sides of the skull to attach to the zygomatic arch, deep to the attachment of the platysma. The Weddell seals' sphincter colli profundus inserts into the corners of the mouth caudal to the orbicularis oris.

3.1.3 | Frontalis

The frontalis is a superficial triangular muscle that covers the dorsal and medial portion of the cranium (Figures 2, 3c and 4d). It originates on the frontal bone at the junction of the maxilla. The muscle is composed of two portions that meet and insert along the sagittal crest on the dorsal midline of the skull. The muscle fibers run rostro-caudally. A small slip of the frontalis travels caudally to border the occipitalis. A second small slip of the frontalis attaches rostrally into the corner of the eyelid. The frontalis is superficial to the temporalis and immediately dorso-caudal to the orbits. The muscle is bordered rostrally by the levator nasolabialis and the orbicularis oculi. The frontalis helps pull the ear canal and cartilage rostrally.

Few specimens had an intact frontalis muscle; of these, northern elephant seals have the largest frontalis, and ringed seals have the smallest after correcting for skull size (Table S2). A portion of the frontalis originates on the orbital ligament in Weddell seals. The frontalis in ringed seals travels rostrally until the junction of the maxilla and nasal bone. The frontalis in California sea lions has two distinct bodies: one portion originates immediately dorsal to the eye and runs rostro-caudally; the second portion originates on the lateral side of the skull and travels medially to the sagittal crest.

3.1.4 | Occipitalis

The occipitalis is a thin superficial muscle on the dorsal and caudal portion of the cranium. This muscle was only identifiable in northern elephant seals. Many of the other specimens had the dorso-caudal portion of the cranium removed (to access and sample the brain tissue during necropsies) prior to their inclusion in this study. The occipitalis of northern elephant seals attaches to the occipital and parietal bones. The muscle fibers run rostro-caudally. The occipitalis

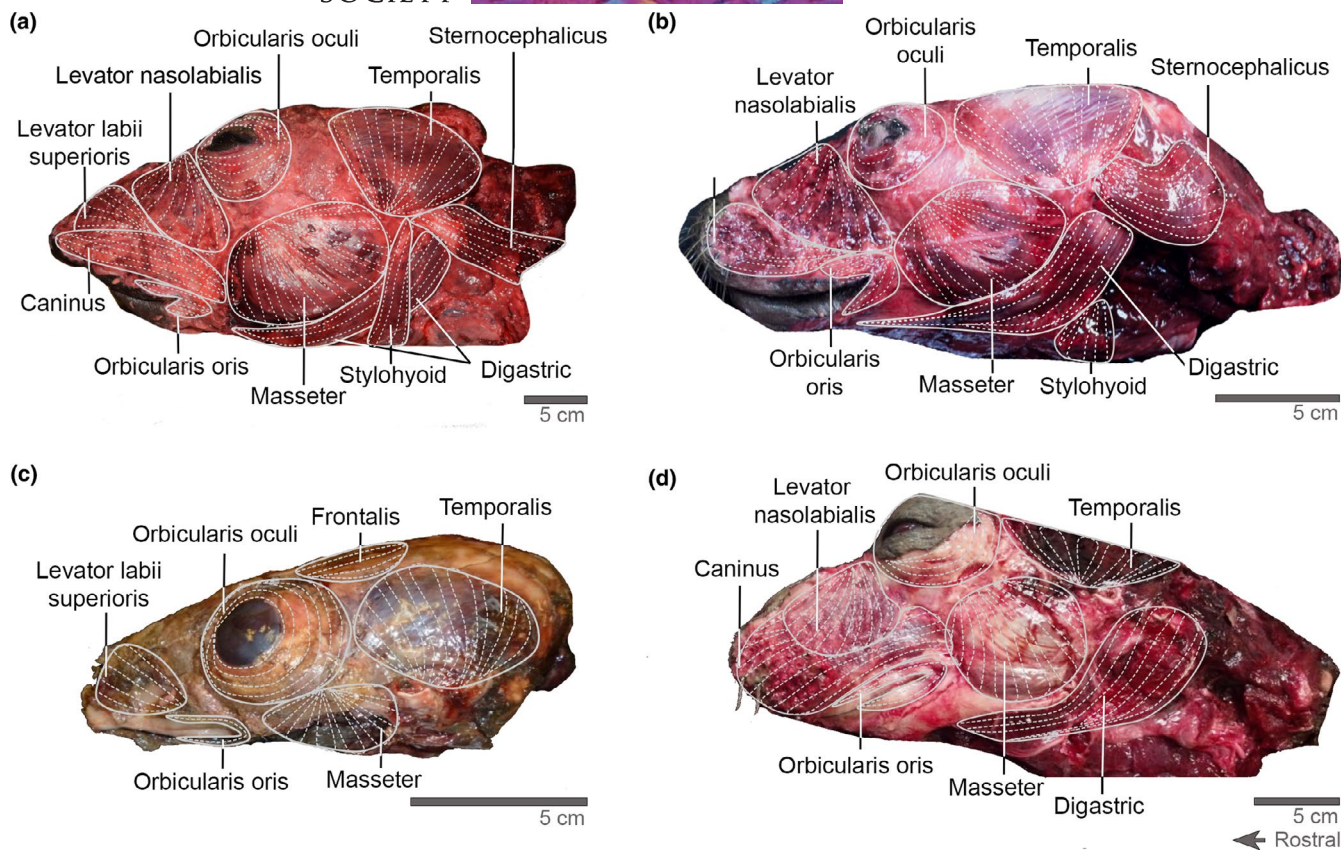


FIGURE 3 Pinniped facial expression and mastication muscles shown in lateral view on a (a) northern elephant seal, (b) harbor seal, (c) ringed seal, and (d) bearded seal. Note the position of the stylohyoid superficial to the digastric in northern elephant seals and ventral to the digastric in harbor seals

has multiple attachments to cervical muscles at the caudal edge of the skull. The occipitalis is deep to the platysma, caudal to the orbicularis oculi and frontalis, and bordered laterally by the temporalis. The occipitalis tenses the nasofrontal fascia and pulls it caudally.

3.1.5 | Orbicularis oculi

The orbicularis oculi is a superficial circular muscle surrounding the eyes and is located directly underneath the skin and blubber (Figures 2, 3 and 4d). The muscle fibers follow the curvature of the eye in a circular orientation. The muscle fibers are widest dorsoventrally and narrower mediolaterally at the corners of the eye. The orbicularis oculi is bordered dorsally and rostrally by the levator nasolabialis. It is bordered dorsally and caudally by the frontalis. The orbicularis oculi is firmly attached to the skin of the eyelid and is responsible for closing the eyelid.

Ringed seals have the largest orbicularis oculi, and harbor seals have the smallest after correcting for skull size (Table S2). The orbicularis oculi is thinner in ringed seals than other species. The orbicularis oculi is wide and prominent in California sea lions and Weddell seals. Some supraorbital vibrissae are embedded in the orbicularis oculi, dorsal to the orbits, in Weddell seals.

3.1.6 | Levator nasolabialis

The levator nasolabialis is a large muscle covering the dorsal and lateral sides of the rostrum (Figures 3 and 4). It originates broadly along the dorsal midline of the skull, rostral to the orbits on the nasal bone. The levator nasolabialis inserts along the dorsal edge of the caninus. The left and right pairs meet at their origin along the dorsal midline. The muscle fibers run dorsoventrally and are slightly rostrally directed. The levator nasolabialis is superficial and caudal to the levator labii superioris. The levator nasolabialis is bordered caudally by the orbicularis oculi and frontalis and bordered ventrally by the caninus. The action of the levator nasolabialis is to pull the upper lip caudally and dorsally, possibly elevating the upper lip to reveal the canine teeth. The levator nasolabialis may potentially exert some control over the movement of the mystacial vibrissae.

Bearded seals have the largest levator nasolabialis and ringed seals have the smallest after correcting for skull size (Table S2). The nerves that run from the infraorbital foramen are deeply embedded in both the caninus and levator nasolabialis in bearded seals. The levator nasolabialis in bearded seals also originates dorsal to the eye. It then travels rostrally and ventrally to curve around the rostral edge of the orbit.

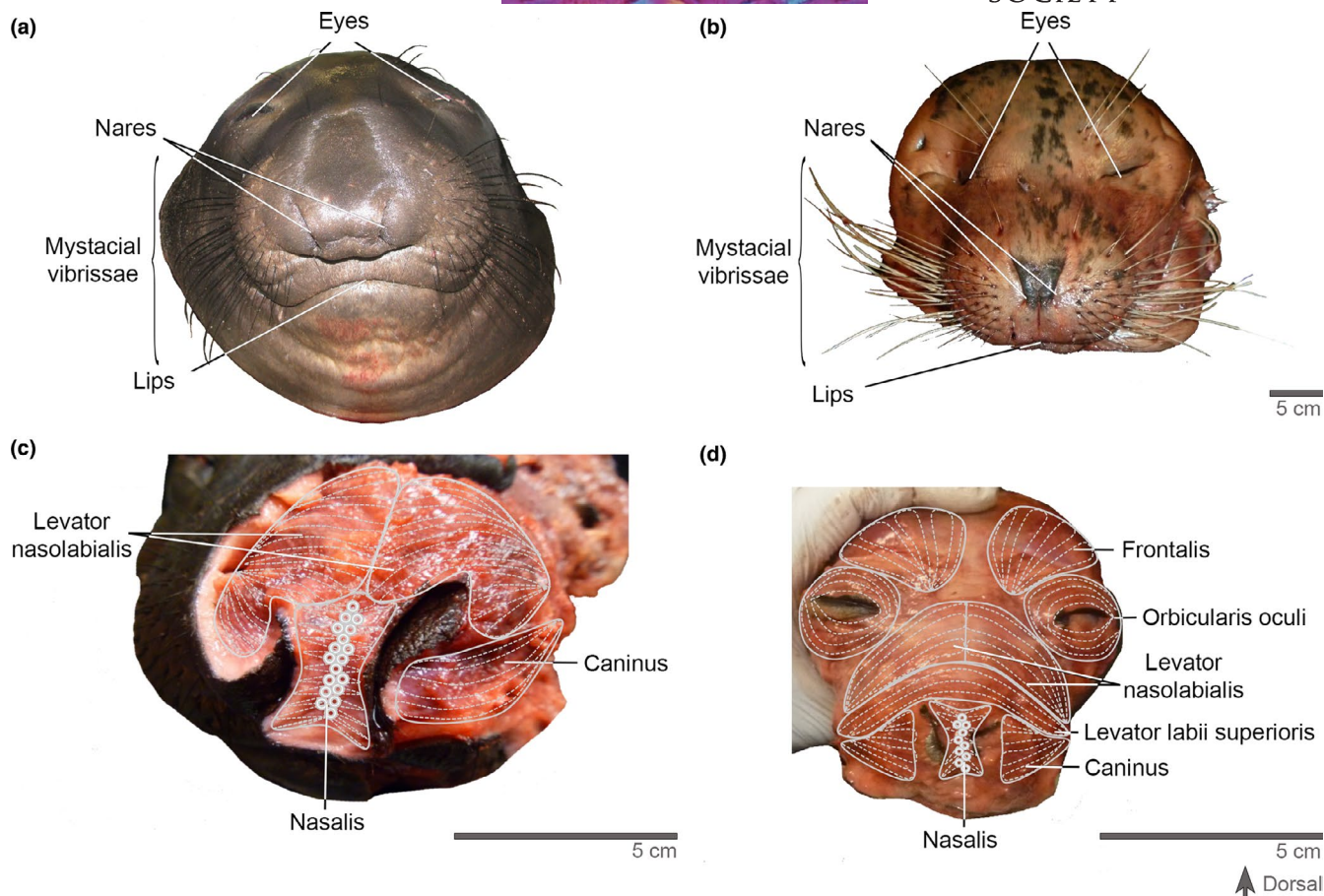


FIGURE 4 Pinniped nasal musculature in rostral view shown on a northern elephant seal (a, c) and harbor seal (b, d). (a, b) External nasal and rostral morphology. Note the skin fold underneath the nostrils in the northern elephant seal and the lack of a skin fold in the harbor seal; (c, d) Nasal and facial expression musculature of a northern elephant and harbor seal. Small circles indicate muscle fibers traveling rostro-caudally. Italics indicate hyoid bones and nonmuscular anatomic features

3.1.7 | Levator labii superioris

The levator labii superioris is a deep facial muscle that runs along the lateral sides of the upper rostrum to the nasal ala on the outer portion of the nostril (Figures 3 and 4d). It originates on the maxillary bone rostral to the infraorbital foramen, and the origin blends with fibers of the levator nasolabialis. The levator labii superioris inserts into the soft tissue of the rostrum near and on the edges of the nostrils. The muscle directly covers the maxillary, premaxillary, and nasal bones and comprises the lateral portion of the soft tissue of the rostrum. The levator labii superioris extends rostrally past the premaxillary and nasal bones into the soft tissue of the rostrum, surrounding the lateral edges of the nostrils. The muscle fibers arc dorsally from the corner of the mouth to run caudo-rostrally. The muscle is bordered ventrally by the caninus, and some fibers of the two muscles blend together. The levator labii superioris is deep to and bordered dorsally and caudally by the levator nasolabialis. The levator labii superioris is distinguished from the levator nasolabialis by a marked change in the fiber direction. The levator labii superioris is responsible for moving the soft tissue of the rostrum, possibly elevating the upper lip to reveal the canine teeth, and opening the nostrils.

Bearded seals have the largest levator labii superioris and harbor seals have the smallest after correcting for skull size (Table S2). The levator labii superioris in northern elephant seals has two insertions: one attaches to the dorsal portion of the nostril and the other attaches to the lateral side of the nostril.

3.1.8 | Caninus

The caninus (also known as the levator anguli oris) is a thick muscle that travels rostrally along the maxilla toward the front of the rostrum (Figures 3 and 4). It originates on the rostral edge of the jugal and maxillary bone, caudal to the infraorbital foramen. The caninus is deep to the levator nasolabialis at its origin. The muscle inserts into the connective tissue at the front of the rostrum, ventral to the nostrils. The muscle fibers run caudo-rostrally. The caninus is bordered caudally by the masseter, ventrally by the orbicularis oris, and dorsally by the levator nasolabialis and levator labii superioris. Some muscle fibers of the levator nasolabialis and levator labii superioris blend with the caninus. The caninus runs parallel to the orbicularis oris, but the two muscles are separated by a distinct layer

of connective tissue. The mystacial vibrissae are deeply embedded in the caninus. The caninus parallels the branches of the trigeminal nerve's second division that emerges from the infraorbital foramen, just dorsal to the origin of the caninus. These nerve branches are deeply embedded in the caninus as the muscle travels rostrally but do not appear to innervate the muscle. The caninus is responsible for moving the mystacial vibrissae and for drawing the soft tissue of the rostrum caudally.

California sea lions have the largest caninus and northern elephant seals have the smallest after correcting for skull size (Table S2). The mystacial vibrissae are deeply embedded in the caninus and levator nasolabialis in bearded seals. Also, the caninus in bearded seals extends downward toward the corner of the mouth and partially covers the orbicularis oris. In contrast, the mystacial vibrissae are not as deeply embedded in the caninus and are easy to remove during dissections in ringed and harbor seals. Fibers of the levator nasolabialis and levator labii superioris blend with the caninus in northern elephant and Weddell seals. The caninus in harbor seals does not extend underneath the nostrils but rather ends in the connective tissue caudal to the nostrils.

There is significantly more soft tissue between the ventral edge of the nostrils and the upper lip of northern elephant seals compared with other species, and this results in a distinct fold (Figure 4). Also, the caninus in northern elephant seals travels farther rostrally compared to other species and makes up the lower portion of the fold. Further, the caninus is bordered dorsally by the levator labii superioris, comprising the upper portion of the fold. Additionally, the northern elephant seal caninus has only one origin but two bellies. The inferior belly ends in the mystacial vibrissae and the second belly continues rostrally and curves dorsally to meet the inferior lateral portion of the nasal opening. Finally, the rostral edge of the caninus of northern elephant seals inserts into the inferior and lateral aspect of the nasal ala. It therefore appears to open the soft tissue nostril, along with the levator labii superioris. The caninus is also responsible for the movement of the inferior portion of the nostril in northern elephant seals.

3.1.9 | Orbicularis oris

The orbicularis oris is a thin circular muscle that lies under the lips (Figure 3). The muscle runs along both the upper and lower jaws, following the curvature of the mouth in a "C" shape. The orbicularis oris is most distinct at the corner of the mouth. The muscle extends along the length of the lower jaw toward the mentalis on the lower jaw. The muscle fibers radiate outward rostrally and ventrally from the corner of the mouth. The orbicularis oris is less distinct on the upper jaw; it runs rostro-caudally and is bordered dorsally by the levator nasolabialis and caninus but is separated by a layer of connective tissue. The muscle fibers of the orbicularis oris and caninus often blend together as the orbicularis oris travels rostrally, especially as the orbicularis oris intersects with the mystacial vibrissae. The orbicularis oris is bordered caudally by the insertions

of the platysma and sphincter colli profundus at the corner of the mouth. The orbicularis oris is responsible for closing the lips when the mouth is closed.

Bearded seals have the largest orbicularis oris and Weddell seals have the smallest after correcting for skull size (Table S2). The muscle fibers of the orbicularis oris and mentalis blend together rostrally on the lower jaw in bearded seals. The orbicularis oris is most distinct and well-defined in bearded seals, California sea lions, and Weddell seals.

3.1.10 | Buccinator

The buccinator is a small, thin muscle that runs along the upper and lower jaws under the lips, deep to the orbicularis oris. It originates from connective tissue attached to the maxilla by the ventral edge of the levator nasolabialis. The muscle fibers of the buccinator insert into the caninus on the upper jaw, and the fibers of the two muscles blend together. The buccinator travels along the lateral edge of the mandible on the lower jaw, and the muscle fibers insert into connective tissue caudal to the mentalis. The muscle fibers run rostro-caudally and follow the curvature of the mouth, similar to the orbicularis oris. The buccinator is bordered caudally by the masseter. The buccinator is bordered dorsally by the caninus, but separated by a layer of connective tissue that is similar to the orbicularis oris. The buccinator is difficult to differentiate from the orbicularis oris, especially at the corners of the mouth. The buccinator helps draw back the angle of the mouth and flatten the cheek.

Northern elephant seals have the largest buccinator, and bearded seals have the smallest after correcting for skull size (Table S2). The buccinator is only located on the lower jaw in ringed seals. The buccinator in California sea lions travels rostrally on the upper jaw, a few vibrissae are embedded in the rostral portion, and it terminates ventrally at the nostrils. The buccinator also attaches to the suture between the maxilla and jugal bones, caudal to the infraorbital foramen in California sea lions. The buccinator fibers in northern elephant seals fan out on the upper and lower jaws and become indistinct toward their insertion. The buccinator of northern elephant seals is deep to the caninus and inserts inside the lateral portion of the cheek, manipulating no more than 1/3 of the total length of the caudal portion of the upper lip.

3.1.11 | Mentalis

The mentalis is a small, thin muscle located on the rostral tip of the lower jaw (Figure 5). It originates on the caudal edge of the mandibular symphysis and inserts into the lower lip where it blends with fibers of the orbicularis oris. The muscle fibers radiate like a fan dorsoventrally from beneath the lower canine and extend rostrally toward the incisors. The mentalis stiffens the lower lip. In most species, the mentalis is extremely difficult to locate and distinguished

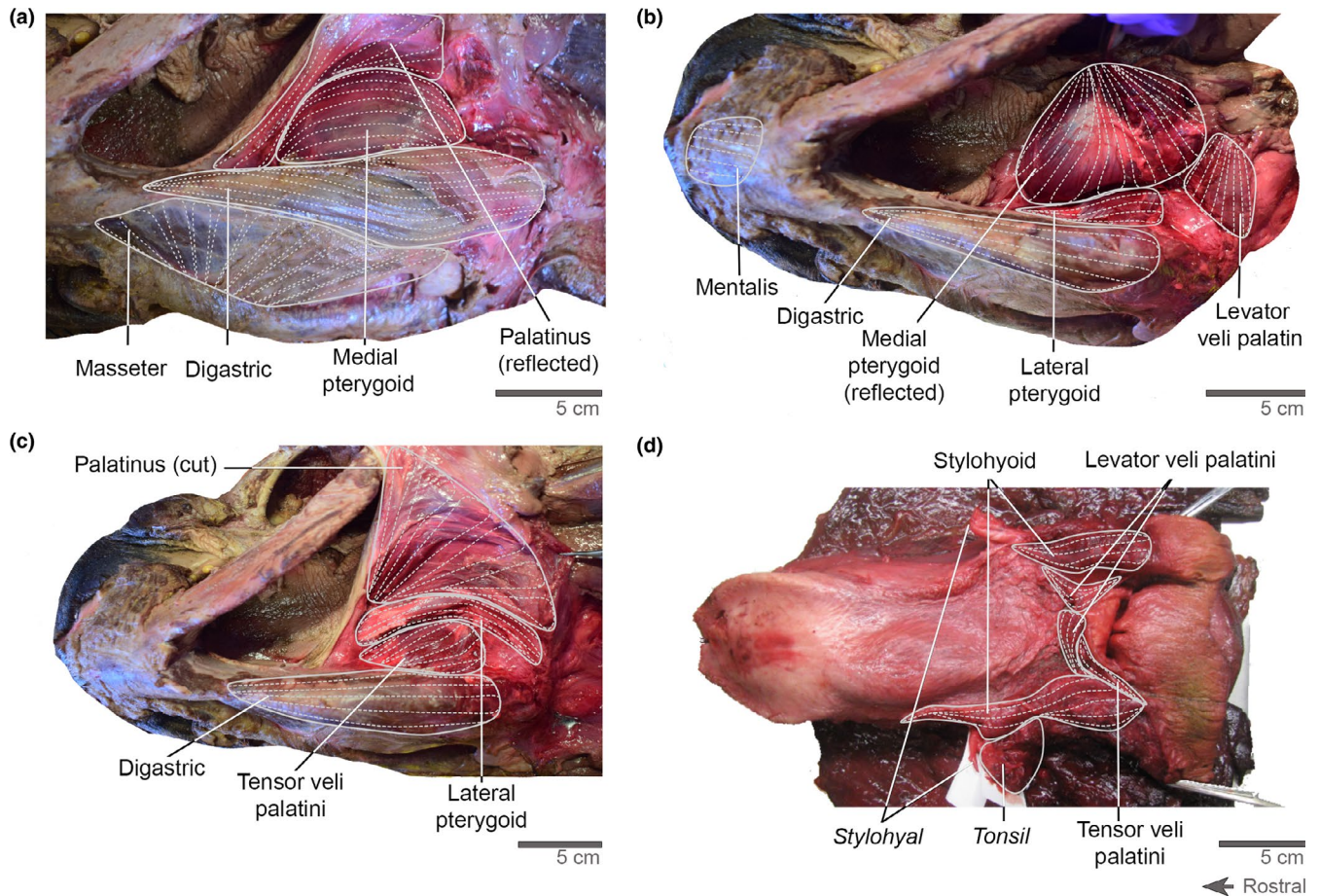


FIGURE 5 Pinniped soft palate and mastication muscles shown on a northern elephant seal in (a–c) ventral view, and (d) dorsal view with the tongue and larynx detached from the skull. Italics indicate hyoid bones

by only a few muscle fibers. The mentalis is not present in ringed seals. The mentalis is most distinct in Weddell seals but difficult to separate from the orbicularis oris at the caudal edges.

3.1.12 | Zygomaticus

The zygomaticus is a thin muscle. It extends from its origin on the rostral portion of the jugal and squamosal bones to its insertion where it blends with the muscle fibers of the levator nasolabialis. The muscle fibers travel rostrally and ventrally. The zygomaticus is deep to the platysma and bordered dorsally by the orbicularis oculi. The zygomaticus aids in drawing the upper lip caudally and dorsally. This muscle was only identified in northern elephant seals and California sea lions (Table S2).

3.1.13 | Nasalis

The nasalis (nomenclature following Diogo et al., 2009) is a thin unpaired superficial muscle that runs between the left and right nostrils at the tip of the rostrum (Figure 4). The muscle fibers run dorsoventrally and mediolaterally between the two nostrils and extend along

the entire dorsoventral length of the nostrils. The nasalis is likely responsible for opening the nostrils.

Weddell seals' nasalis does not extend ventral to the nostrils; rather, underneath the nostrils there is a layer of connective tissue and blubber above the lips. The nasalis is large and well-defined in northern elephant seals. The muscle fibers of the nasalis of northern elephant seals extend from the dorsal-most edge of the nostrils ventrally to the upper lip (Figure 4c). The fibers of the northern elephant seal nasalis blend with fibers of the levator labii superioris. The continuation of the nasalis ventral to the nostrils in northern elephant seals may help indent the fold of skin directly underneath the nostrils.

3.2 | Mastication muscles

3.2.1 | Temporalis

The temporalis is a large, thick muscle covering the entire dorsal surface of the parietal bone on both the dorsal and lateral sides of the skull (Figures 2 and 3). It has a broad origin along the rostral edge of the parietal bone and inserts on the lateral and medial sides of the coronoid process. The muscle is covered by a thick layer of superficial fascia. The left and right muscle pairs are separated by

connective tissue at the dorsal midline of the cranium. The muscle fibers run dorsoventrally and are rostrally directed. The temporalis travels ventrally underneath the zygomatic arch. The lateral portion of the temporalis and its insertion on the lateral portion of the coronoid process are deep to the masseter. The ventral edge of the muscle is deep to the auditory canal. The temporalis is bordered rostrally by the orbicularis oculi and bordered on the medial insertion by the medial pterygoid. The temporalis is responsible for elevating the mandible to close the jaw.

Weddell seals have the largest temporalis, and bearded seals have the smallest after correcting for skull size (Table S2). Weddell seals' temporalis extends rostrally to partially originate on the ligament that forms the caudal edge of the orbit, and the muscle extends caudally to attach to the dorsal portion of the mastoid process. This resulted in Weddell seals' temporalis having a much larger attachment on the cranium, leading to a much larger overall surface area compared with the other species. The rostral-most portion of the temporalis is deep to the occipitalis in bearded seals. The temporalis travels rostrally to attach to the frontal bone in California sea lions and northern elephant seals. Also in northern elephant seals, the temporalis has two heads at the insertion that merge dorsally; one head is attached to the medial side of the coronoid process, and the other head is attached to the lateral surface of the coronoid process. The temporalis in harbor seals does not cover the entire surface of the parietal bone.

3.2.2 | Masseter

The masseter is a large, thick muscle that is deep to the platysma and sphincter colli profundus. It is separated from other muscles by a thick layer of superficial fascia (Figures 3, 5a, 6 and 8). The masseter originates on the ventral border of the jugal and squamosal bones starting at the rostral-most point of the jugal. The muscle has a broad insertion along the lateral side of the mandible where it attaches directly to the lateral surface of the coronoid process. A portion of the masseter also curves around the caudal and ventral edge of the lower jaw to insert on the medial side of the mandible. The muscle fibers fan out from the origin dorsoventrally and are caudally directed. The hypoglossal nerve is superficial to the masseter and runs caudo-rostrally along the masseter. The masseter is bordered rostrally by the orbicularis oris and ventrally by the digastric. The insertion of the masseter on the medial side of the mandible is bordered by the medial pterygoid. The masseter is used to raise the mandible to close the mouth and exert strong bite forces.

Northern elephant seals have the largest masseter, and harbor seals have the smallest after correcting for skull size (Table S2). California sea lions, harbor seals, northern elephant seals, and ringed seals exhibit intraspecific variation of the masseter. The masseter presents individual variation in each species: some individuals of each species have a masseter comprised of one belly, whereas in other individuals, the masseter is divided into a superficial belly

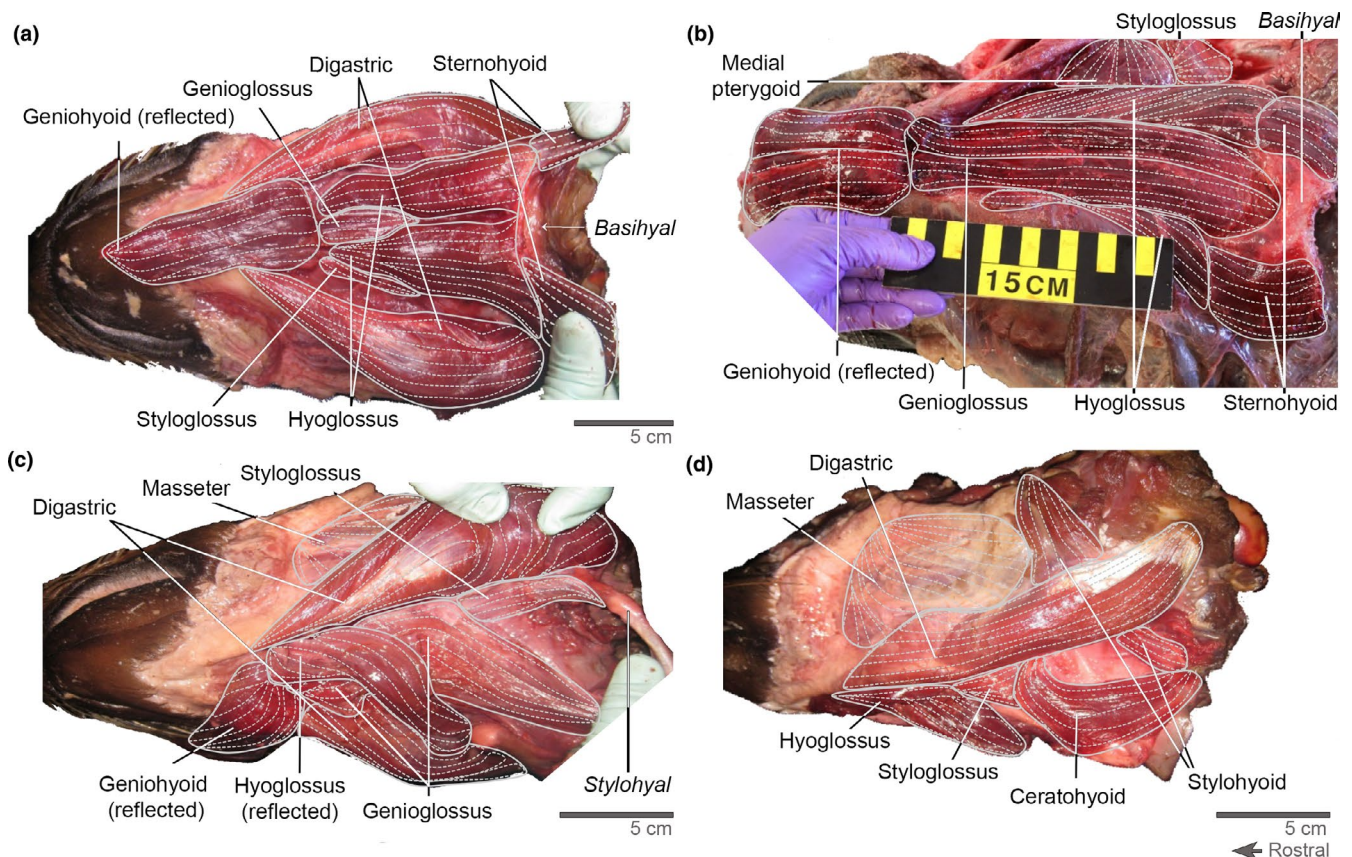


FIGURE 6 Pinniped tongue, mastication, and hyoid muscles in ventral view shown on a California sea lion (a, c–d) and northern elephant seal (b). (a, b) Superficial view of the tongue muscles and (c–d) deep view of the tongue and hyoid muscles. Italics indicate hyoid bones

and a deep belly. In individuals with two bellies, the superficial belly is larger and originates along the jugal and squamosal. The muscle fibers of the superficial belly travel dorsoventrally and are caudally directed. The superficial belly inserts on the lateral side of the mandible, where it is bordered by the insertion of the digastric. The deep belly has a similar origin that is difficult to separate from the superficial belly. The muscle fibers of the deep belly fan out toward its insertion along the lateral edge of the angular process of the mandible.

3.2.3 | Lateral pterygoid

The lateral pterygoid is a small, round muscle (Figure 5). It originates on the rostral edge of the auditory bulla, deep to the digastric. It inserts onto the medial surface of the mandible, rostral to the condyles. The muscle fibers run mediolaterally and are slightly rostrally directed. It is located immediately lateral to the medial pterygoid. The lateral pterygoid is bordered dorsally by the temporalis on the medial side of the coronoid process. The lateral pterygoid mainly assists in elevating the mandible. It may also cause minor side-to-side shifts when contracted singularly or mandible retraction when contracted as a pair. This muscle was only identified in northern elephant seals (Table S2).

3.2.4 | Medial pterygoid

The medial pterygoid is a large bulbous muscle that travels along the lateral sides of the pterygoid hamuli and the medial side of the mandible (Figures 5 and 6b). It originates on the rostral edge of the auditory bulla by a strong tendinous attachment. It also arises on the lateral edge of the palate along the caudal edge of the jugal and maxilla. The medial pterygoid inserts along the medial edge of the mandible below the coronoid process. The medial pterygoid fits into the groove between the mandible and the auditory bulla by the temporomandibular joint. The muscle fibers run rostro-caudally along the pterygoid hamulus and curve ventrally to attach to the mandible. The medial pterygoid runs along the pterygoid hamulus but does not have any attachments to it. The muscle is widest along with its origin and narrows toward the insertion. The medial pterygoid is deep to the digastric and masseter and passes deep to the soft palate along the lateral edges along with the pterygoid plate. The origin of the medial pterygoid is rostral and slightly medial to the origin of the lateral pterygoid. The medial pterygoid is bordered dorsally by the insertion of the temporalis, medially by the levator veli palatini, laterally by the insertion of the mylohyoid and masseter, and caudally by the stylohyoid. The medial pterygoid primarily assists in raising the mandible along with the lateral pterygoid, possibly adding power to the bite. Additionally, it may be responsible for mild side-to-side shifts when contracting individually or protraction when contracting as a pair.

The medial pterygoid is similar in size across the four species in which it was identified (California sea lions, harbor, northern

elephant, and Weddell seals; Table S2). Muscle fibers of the medial pterygoid in northern elephant seals blend with fibers of the masseter around the ventral edge of the mandible, perhaps adding strength to the masseter's bite force. The medial pterygoid in ringed seals partially inserts into the tongue muscles.

3.2.5 | Digastric

The digastric is a large and thick two-bellied muscle (Figures 3 and 5-7). It has a broad origin on the ventral edge of the paraoccipital process lateral to the occipital condyles and caudal to the auditory bulla. The digastric inserts along the ventral edge of the mandible caudal to the mandibular symphysis. The digastric insertion is bordered and partially covered by the insertion of the mylohyoid. The digastric is wrapped in the superficial fascia, and the muscle fibers run caudo-rostrally. The digastric is widest at its origin and narrows as it travels rostrally toward the insertion. The two bellies of the

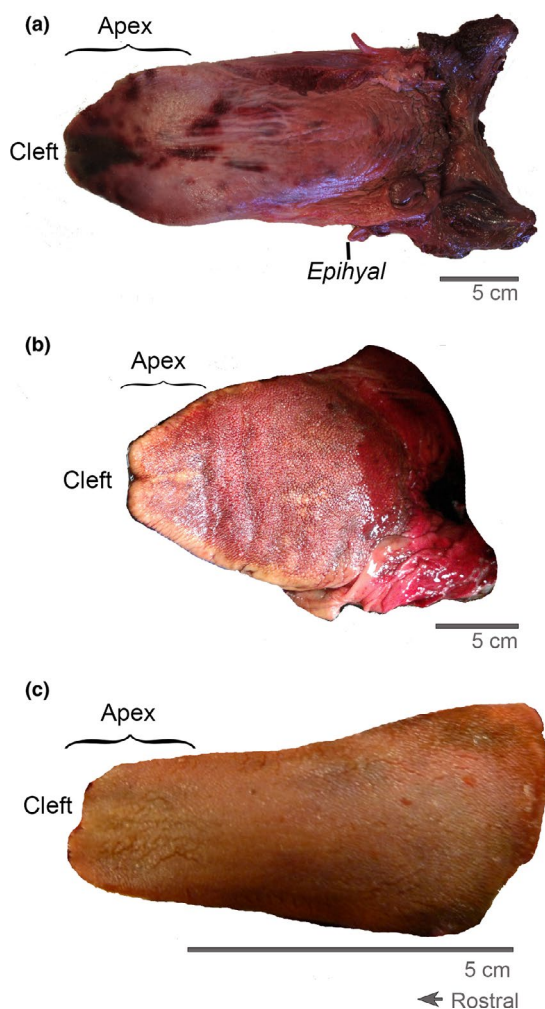


FIGURE 7 External pinniped tongue morphology shown in dorsal view of (a) northern elephant seal, (b) bearded seal, and (c) California sea lion. Italics indicate hyoid bones

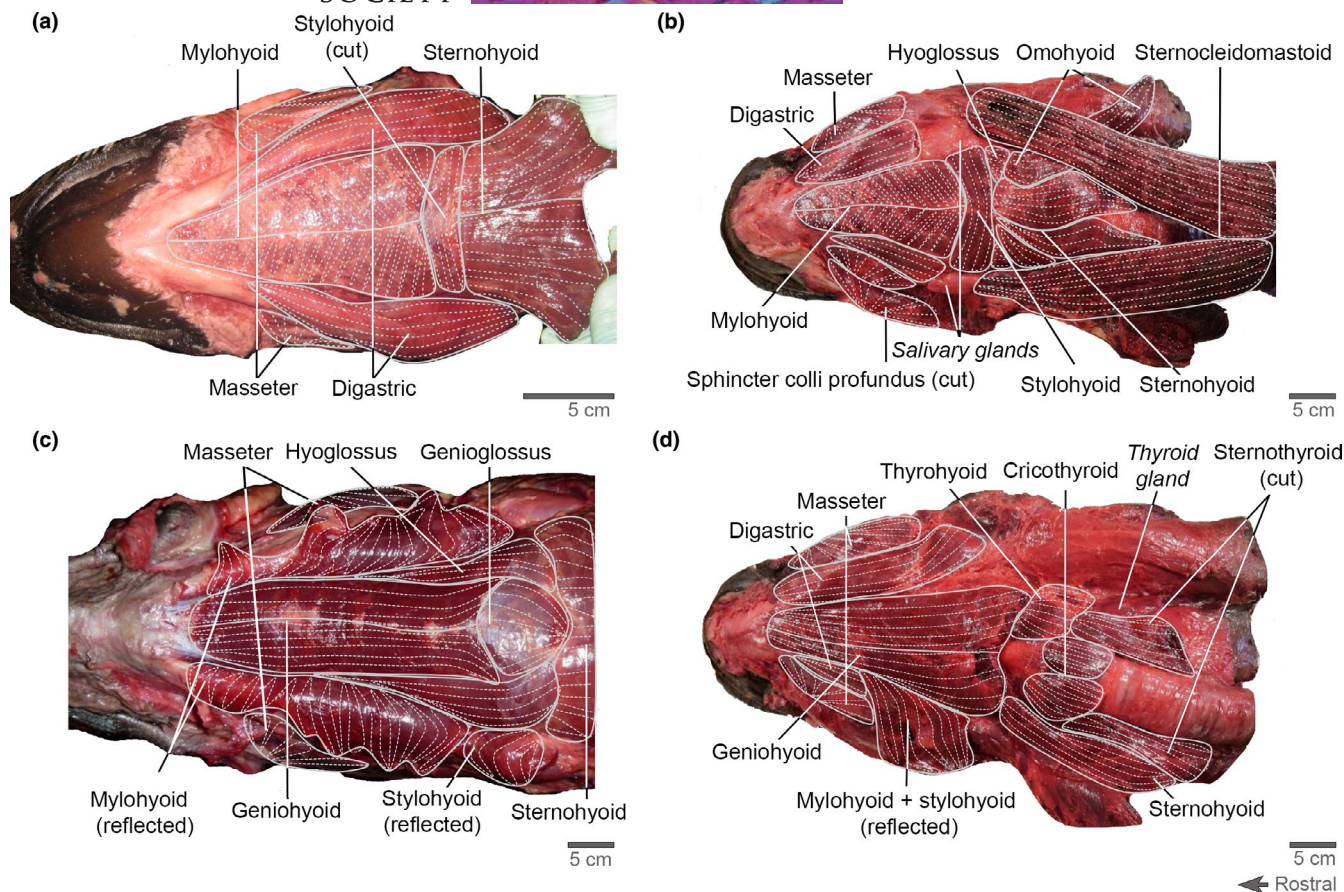


FIGURE 8 Pinniped hyoid muscles in ventral view shown on a (a, c) California sea lion, and (b, d) northern elephant seal. Italics indicate hyoid bones and nonmuscular anatomic features

digastric are delineated by a tendinous attachment between them. The first belly begins at the rostral and ventral edge of the mandible and travels caudally. The second belly attaches directly to the first belly caudal to the mandible and fibers are directed dorsoventrally. The muscle covers the auditory bulla, is deep to the stylohyoid, and is bordered dorsally by the masseter. The digastric opens the mouth by depressing the mandible.

California sea lions have the largest digastric, and harbor seals have the smallest after correcting for skull size (Table S2). The digastric of one northern elephant seal specimen originates on the lateral edge of the mastoid process. A small slip of the digastric in one California sea lion specimen extends along the lateral edge of the mandible underneath the masseter.

3.3 | Tongue muscles

3.3.1 | Styloglossus

The styloglossus is a thin muscle that makes up the lateral portion of the tongue and connects it to the cranium (Figure 6). The styloglossus of most pinnipeds originates on the rostral, lateral, and ventral edges of the auditory bulla. The styloglossus inserts into the lateral

sides of the tongue. The muscle fibers run caudo-rostrally. The styloglossus runs along the lateral edge of the stylohyal. The muscle is deep to the digastric on the auditory bulla. The muscle is bordered medially by the hyoglossus and geniohyoid, and it is dorsal to the mylohyoid. The styloglossus draws the tongue caudally and may create traction for the tongue when feeding.

Ringed seals have the largest styloglossus, and bearded and harbor seals have the smallest after correcting for skull size (Table S2). The caudal-most fibers of the styloglossus in Weddell seals become indistinct and are difficult to differentiate from other muscles. The styloglossus originates on both the auditory bulla as well as on the caudal and medial edges of the stylohyal in harbor seals and California sea lions. The styloglossus of one California sea lion has three distinct heads at its origin that attach to the medial and lateral edges of the stylohyal and by connective tissue to the auditory bulla.

3.3.2 | Hyoglossus

The hyoglossus is a large thick muscle that makes up the lateral and ventral portions of the tongue (Figures 4c,d, 6 and 8). It originates on the ventral and lateral edges of the basihyal and inserts into the

lateral and ventral body of the tongue. The muscle fibers run caudo-rostrally. The pairs of the hyoglossus do not intersect at the midline but rather lie side-by-side (parallel) on either side of the midsagittal line, separated by fibers of the genioglossus. The hyoglossus travels together with the genioglossus to the tip of the tongue. The hyoglossus is located dorsally to the mylohyoid and sphincter colli profundus. The hyoglossus is bordered laterally by the styloglossus and medially by the genioglossus. It is bordered caudally by the thyrohyoid. The hyoglossus is responsible for retracting and depressing the tongue.

California sea lions have the largest hyoglossus and harbor seals have the smallest after correcting for skull size (Table S2). The hyoglossus fibers in bearded seals originate adjacent to the thyrohyoid, with the two muscles running in opposite directions. The origin of the hyoglossus in harbor and northern elephant seals is on the ventral edges of the thyrohyal, caudal to the basihyal, and superficial to the ceratohyal. Additionally, in both northern elephant and harbor seals, the hyoglossus is comprised of two bellies: one belly arises from the stylohyal near the tip of the tympanohyal, and the other belly arises from the caudal edge of the basihyal. These two bellies blend together rostrally to form one band of muscle. The hyoglossus in California sea lions originates on the lateral and rostral edges of the basihyal and ceratohyal.

3.3.3 | Genioglossus

The genioglossus is a large muscle that comprises the medial portion of the tongue (Figures 6 and 8). It originates along the caudal edge of the mandibular symphysis. The genioglossus inserts into the main body of the tongue, traveling to the rostral tip of the tongue. The genioglossus also inserts onto the rostral edge of the basihyal and has fibrous attachments to the rostral edges of the ceratohyal and epihyal. The muscle fibers travel dorsally from their origin on the mandibular symphysis. The left and right muscles meet along the midline and travel as a single sheet into the main body of the tongue. At this point, the muscle fibers run rostro-caudally from the tip of the tongue to the hyoid apparatus. The genioglossus is bordered laterally by the hyoglossus and styloglossus. It is dorsal to the geniohyoid, and the two muscles are separated by superficial fascia. The genioglossus is responsible for depressing the tongue. The rostral fibers curl the apex of the tongue ventrally. The caudal fibers pull the hyoid apparatus rostro-ventrally.

The genioglossus is largest in northern elephant seals have the largest genioglossus and bearded seals have the smallest after correcting for skull size (Table S2). The fibers of the genioglossus are difficult to separate and distinguish from the geniohyoid in Weddell seals. Some species showed intraspecific variation at the insertion of the genioglossus on the hyoid apparatus. For example, genioglossus fibers were inserted directly on the basihyal in some California sea lions and northern elephant seals, but in other individuals of the same species, there was no fibrous attachment to the basihyal.

3.3.4 | Tongue (Lingua propria)

The pinniped tongue is bifurcated at its apex but has no longitudinal sulcus running along the dorsal midline to delineate the left and right sides (Figures 5d and 7). The styloglossus makes up the lateral body of the tongue. The hyoglossus makes up most of the lateral and ventral portions of the tongue. The genioglossus comprises the majority of the dorsal and medial portions. Both the genioglossus and hyoglossus extend rostrally to the tip of the tongue. Additionally, intrinsic tongue muscles run rostro-caudally immediately underneath the epithelium, extending from the caudal base of the tongue rostrally. The intrinsic tongue muscles comprise the majority of the rostral body of the tongue. The intrinsic muscle fibers travel rostro-caudally, mediolaterally, and dorso-ventrally. The tongue is extremely muscular and contains no adipose tissue. The tip of the tongue is freely mobile and has a cleft separating the two bifurcated lobes. The extrinsic tongue muscles (e.g., styloglossus, hyoglossus, genioglossus) produce gross movements of tongue position. The intrinsic tongue muscles produce complex tongue shapes.

Northern elephant seals have the largest tongues, and California sea lions have the smallest after correcting for skull size (Table S2). The genioglossus and hyoglossus in northern elephant seals travel rostrally to the tip of the tongue; they interdigitate with the intrinsic tongue muscles in the rostral $\frac{1}{4}$ of the tongue.

There are interspecific differences in the gross morphology of the pinniped tongue. Bearded seals have a yellow-brown tongue. California sea lions and Weddell seals have a reddish-pink tongue. Harbor seals have a pink tongue. Northern elephant seals have a light pink tongue with some dark red spots on the rostral half. The dorsal surface of the northern elephant seal tongue is mostly smooth, with some rigidity along the rostral edges (Figure 7a). Bearded seals, California sea lions, harbor seals, and ringed seals have small lingual papillae on the rostral and lateral surfaces of the tongue and extend caudally along the surface of the tongue. Bearded seals have a course dorsal surface of the tongue that is covered in tiny bulges that may be taste buds. Although there is no evidence of taste buds in Weddell seals, there are numerous blood vessels on the dorsal surface of the tongue. Northern elephant and Weddell seals have a deep tongue cleft and large frenulum. In contrast, California sea lions have a short frenulum.

3.4 | Hyoid muscles

The pinniped hyoid apparatus is comprised of nine bony elements: the unpaired basihyal and the paired thyrohyals, ceratohyals, epihyals, and stylohyals. Eight distinct muscles attach to these bones. The pinniped hyoid apparatus also includes the paired tympanohyal cartilage that attaches the stylohyals to the lateral edge of the auditory bulla.

3.4.1 | Mylohyoid

The mylohyoid is a thin, flat muscle running latero-medially between the ventral edges of the mandible (Figure 8). It originates along the

entire ventral and medial length of the mandible, and the muscle inserts into its pair along the ventral midline. The muscle fibers run mediolaterally and together with its pair forms a sling for the floor of the mouth. The left and right muscles give the appearance of a weak chevron with mild flexion of the fiber direction where the two muscles meet at the midline. The entire muscle is wrapped in the superficial fascia. The muscle is bordered on the lateral edges by the digastric, is deep to the sphincter colli profundus, and superficial to the geniohyoid. The primary function of the mylohyoid is to raise the floor of the mouth (including the tongue). It can also pull the hyoid apparatus rostro-dorsally.

California sea lions have the largest mylohyoid and Weddell seals have the smallest after correcting for skull size (Table S2). The mylohyoid of northern elephant seals is partially covered on its caudal edge by the stylohyoid, and it attaches directly to the digastric, rather than the mandible. The mylohyoid in harbor seals has attachments to the caudal edge of the mandibular symphysis and partially inserts on the ventral edge of the basihyal. Similarly, the mylohyoid inserts on the basihyal in ringed seals and California sea lions.

3.4.2 | Sternohyoid

The sternohyoid is a robust muscle that is found ventral to the thyroid cartilage of the larynx (Figures 6 and 8). It travels rostrally from its origin in the ventral thoracic region (which was not included in any specimens in this study). The sternohyoid inserts along the caudal edge of the basihyal and extends laterally onto a connective tissue aponeurosis that attaches along the caudal edge of the thyrohyal. The fibers run caudo-rostrally. The pairs of the muscle lie parallel and adjacent to each other with no perceptible gap in the midline as they approach their insertion on the basihyal. The sternohyoid is bordered rostrally by the hyoglossus and geniohyoid, and it is ventral to the thyrohyoid, sternothyroid, and ceratohyoid. The sternohyoid pulls the basihyal caudally and ventrally, thereby causing retraction and depression of the tongue and larynx that are also attached to the hyoid apparatus.

Northern elephant seals have the largest sternohyoid, and bearded seals have the smallest after correcting for skull size (Table S2). The sternohyoid in bearded seals and California sea lions are a thin sheet of muscle. The sternohyoid in harbor seals inserts more rostrally on the basihyal closer to the origin of the hyoglossus, with some fibers also attaching to the caudal edge of the epihyal.

The sternohyoid of northern elephant seals has a unique morphology compared with the other species. Specifically, their sternohyoid is long and thick, with the muscle fibers blending with the geniohyoid ventral to the basihyal to form a single sheet of muscle. The sternohyoid also has two heads: one is a small, medial bundle, and the other is a wide, lateral bundle. Both heads of the muscle blend rostrally with the geniohyoid. The geniohyoid and sternohyoid are attached to each other by connective tissue that attaches to the basihyal, potentially acting as one strap of muscle. There are also some connective tissue attachments to the ventral surface of the

trachea. Additionally, northern elephant seals show some intraspecific variation for these attachments, with the pairs of the sternohyoid meeting at the midline in some specimens and fusing together at the midline in one individual.

3.4.3 | Geniohyoid

The geniohyoid is a long, flat muscle that runs from the hyoid apparatus to the mandibular symphysis (Figures 6 and 8). It originates on the caudal and ventral edge of the mandibular symphysis and inserts along the rostral and ventral edges of the basihyal. The pairs of the muscle run in parallel and are connected at the midline raphe. The geniohyoid is ventral to the genioglossus, ventral and medial to hyoglossus, and dorsal to the mylohyoid. The geniohyoid is bordered caudally by the omohyoid and sternohyoid. The muscle fibers run rostro-caudally, and some fibers blend with the genioglossus along the border of the two muscles. The geniohyoid draws the hyoid apparatus rostrally during swallowing and therefore also elevates the attached larynx. The geniohyoid can also protrude the attached tongue.

Northern elephant seals have the largest geniohyoid and bearded seals have the smallest after correcting for skull size (Table S2). The origin of the geniohyoid in bearded seals continues onto the rostral edge of the epihyal. The fibers of the geniohyoid in Weddell seals blend with those of the mylohyoid but are differentiated by a change in the fiber direction. The insertion of the geniohyoid in northern elephant seals is on both the thyrohyal and basihyal, dorsal to the stylohyoid. Also, there are some geniohyoid muscle fibers that merge with those of the sternohyoid, caudal to the basihyal, in northern elephant seals. The muscle fibers of both the geniohyoid and sternohyoid muscle fibers run rostro-caudally but a thin layer of connective tissue separates the two.

3.4.4 | Stylohyoid

The stylohyoid is a rectangular strap-shaped muscle (Figures 3, 5d, 6d and 8). It originates on the cranium in the same plane as the external auditory meatus. The exact origin varies by species (see below). The stylohyoid inserts into its pair from the opposite side along the midsagittal line, and some muscle fibers blend with those of the caudal edge of the mylohyoid. The stylohyoid runs dorsoventrally as it travels from its origin on the cranium to the insertion into its pair. It curves around the lateral sides of the mandible, and the fibers then run latero-medially. The muscle fibers are parallel to those of the mylohyoid at its insertion. The stylohyoid lies caudal to the mylohyoid in the same plane. The muscle is widest at the origin and narrows toward its insertion. The stylohyoid is superficial to the digastric and covers part of the digastric as the muscle travels from its origin to insertion. The stylohyoid is bordered rostrally by the masseter. The muscle is bordered at the origin by the external auditory canal. The function of the stylohyoid is potentially to extend the

width (mediolaterally) of the back of the throat and/or elevate the hyoid apparatus dorsally.

Bearded and northern elephant seals have the largest stylohyoid and northern elephant seals and California sea lions, harbor, and ringed seals have the smallest after correcting for skull size (Table S2). The bearded seals' stylohyoid originates from connective tissue attached between the masseter and digastric and does not arise directly from the skull. The stylohyoid in California sea lions, harbor seals, and Weddell seals originates dorsal to the external auditory meatus; it is bordered by the external auditory canal and lateral to the auditory bulla. The ringed seals' stylohyoid originated on the lateral side of the mastoid process, caudal to the auditory bulla.

The stylohyoid is extremely distinct in northern elephant seals. It is a thick band of muscle superficial and ventral to the mylohyoid. It originates at the junction of the mastoid process and end of the squamosal on the latero-caudal edge. The two pairs of the stylohyoid meet and attach to each other at the ventral midline. At the insertion, the fibers form a chevron shape, similar in shape to the mylohyoid, at their insertion into each other. There is some attachment to the mylohyoid and to the ventral edge of the basihyal. The stylohyoid is tapered toward the ends and wider in the middle. The stylohyoid is deep to the sphincter colli profundus and is superficial to all other hyoid muscles.

3.4.5 | Omohyoid

The omohyoid (with terminology following Diogo et al., 2012, 2016; Saban, 1968) is a thick hyoid muscle that runs from the basihyal caudally toward the lateral neck (Figure 8b). The caudal portion was severed in all specimens but likely originates on the scapula. The rostral portion of the omohyoid inserts on the lateral and caudal edges of the basihyal via a connective tissue aponeurosis. The omohyoid shares a common aponeurosis on the basihyal with the geniohyoid, the lateral portion of the sternohyoid, and the thyrohyoid. The fibers of the rostral portion of the omohyoid run rostro-caudally but after they pass under the sternocleidomastoid, the fibers are directed laterally at a 45° angle from the midline. The omohyoid is bordered medially by the sternohyoid. The function of the omohyoid is to depress the hyoid bone and attached larynx caudally. This action can also retract the tongue. The omohyoid was only observed in California sea lions and northern elephant seals.

3.4.6 | Thyrohyoid

The thyrohyoid is a triangular muscle that runs from the thyroid cartilage of the larynx to the hyoid apparatus (Figure 8d). It originates on ventro-lateral aspect of the thyroid cartilage. The muscle inserts on the lateral, caudal, and ventral edge of the basihyal, on the ventral edge of the ceratohyal, and on the ventral-most projection of the thyrohyal. The thyrohyoid is narrow at its origin and widens as it travels to the insertion. The thyrohyoid is deep to the sternohyoid

and omohyoid, and bordered rostrally by the hyoglossus and geniohyoid. The muscle fibers run caudo-rostrally. The thyrohyoid is responsible for retracting the hyoid apparatus caudally and elevating it dorsally.

Ringed seals have the largest thyrohyoid and harbor and northern elephant seals have the smallest after correcting for skull size (Table S2). The thyrohyoid in northern elephant seals is an extremely thick muscle. The thyrohyoid in harbor seals blends with fibers of the sternothyroid.

3.4.7 | Sternothyroid

The sternothyroid is a rectangular hyoid muscle (Figure 8d). It originates from the sternum (not present in our specimens) and inserts on the ventro-caudal aspect of the thyroid cartilage. The muscle fibers travel rostro-caudally. The sternothyroid is responsible for pulling the larynx caudally.

The sternothyroid was only identified in bearded and northern elephant seals and showed interspecific differences. The bearded seal sternothyroid is dorsal to the sternohyoid and lateral to the thyroid cartilage. The sternothyroid of northern elephant seals is intimately connected with the sternohyoid. These two muscles are found in the same plane but differentiated by their separate layers of fascia, with the sternothyroid positioned medial to the sternohyoid. The sternohyoid and sternothyroid of northern elephant seals are merged caudally approaching the sternum. The sternothyroid of northern elephant seals inserts into fibers of the cricothyroid, overlapping with the rostral attachment of the thyrohyoid.

3.4.8 | Ceratohyoid

The ceratohyoid is a triangular muscle connecting the ceratohyal, thyrohyal, and epihyal elements of the hyoid apparatus (Figure 6d). It originates along the lateral edge of the thyrohyal and inserts onto the lateral edge of the ceratohyal and along the caudal border of the epihyal. The ceratohyoid is deep to the styloglossus. The muscle fibers run caudo-rostrally and are ventrally directed. The ceratohyoid decreases the space between the ceratohyal, thyrohyal, and epihyal. Contraction appears to bring the basihyal and thyrohyal caudo-dorsally, thereby elevating the attached larynx closer to the soft palate. The ceratohyoid was not observed in ringed and Weddell seals. This muscle is largest in California sea lions and smallest in bearded seals (Table S2).

3.5 | Soft palate muscles

3.5.1 | Tensor veli palatine

The tensor veli palatini is a thin soft palate muscle (Figure 5). It originates on the rostral and ventral edges of the auditory bulla and

inserts into the lateral edges of the soft palate, into the palatinus, and onto the lateral edges of the nasopharynx. The tensor veli palatini is narrowest at the origin and widens toward the insertion. The muscle fibers run rostro-caudally. The tensor veli palatini runs along the medial edges of the pterygoid hamuli. It is deep to the stylohyoid and digastric, bordered caudally by the rectus capitis, and bordered medially by the levator veli palatini. Some fibers of the tensor veli palatini blend with the levator veli palatini at the origin, but the two muscles are distinct along their lengths and have separate insertions. The tensor veli palatini is responsible for stretching the palate between the pterygoid hamuli and appears to pull the soft palate caudally and laterally.

3.5.2 | Levator veli palatine

The levator veli palatini is another thin soft palate muscle (Figure 5). It originates from connective tissue on the rostral edge of the auditory bulla, medial to the origin of the tensor veli palatini. The levator veli palatini inserts into the soft palate along the length of the pterygoid hamulus on the palatine and terminates at the suture of the maxilla and palatine. The muscle fibers run rostro-caudally. The levator veli palatini is bordered laterally by the tensor veli palatini and medial pterygoid. The levator veli palatini pulls the soft palate dorsally. In Weddell seals the levator veli palatini is especially thin. In contrast, in northern elephant seals the levator veli palatini is extremely large and has a broader origin on the auditory bulla compared with the other species in the study.

3.5.3 | Palatinus

The palatinus is a thin, flat muscle (Figure 5a). It originates on the palatine bone, travels rostrally toward the postcanine teeth, and inserts into the soft palate. The muscle fibers run rostro-caudally. The action of the palatinus is to stretch the palate. The palatinus was only observed in northern elephant seals and harbor seals.

3.6 | Craniofacial muscle morphologic patterns

We quantified the mean MSR (muscle/skull area ratio) for each species and for each muscle (Table 1). Northern elephant seals have the largest facial expression and hyoid muscles. Weddell seals have the largest mastication muscles. California sea lions, northern elephant seals, and ringed seals have the largest tongue muscles. In contrast, harbor seals consistently have the smallest craniofacial musculature. Across all pinniped species, two facial expressions (sphincter colli profundus, platysma), one mastication (temporalis), and three hyoid (sternohyoid, omohyoid, and mylohyoid) muscles have the greatest mean MSR. In comparison, three mastications (levator veli palatini, medial and lateral pterygoid), one hyoid (ceratothyroid), and one facial expression (frontalis) muscles have the smallest MSR across species.

We quantified variability in MSR by averaging the CV (SD/mean) for each species for each muscle (Table 2). Overall, the mastication muscles are the most stereotyped (CV = 0.40), whereas the hyoid muscles are the most variable (CV = 0.64). Among species, bearded seals have the highest variability across all craniofacial muscles (mean CV = 0.64), whereas ringed seals exhibit the most stereotyped craniofacial muscles (mean CV = 0.20). Further, suction feeders consistently have higher variability in MSR (CV = 0.59) compared with biters (CV = 0.37).

Our linear mixed effect models find interspecific differences in MSR for the masseter and styloglossus (Table 1). Although not significant, we find that ringed seals have a larger styloglossus (mean MSR = 0.08) compared with the other species (mean MSR range: 0.01–0.02, $F_5 = 8.4$, $p = 0.06$). Additionally, northern elephant seals have a larger masseter (mean \pm SD; MSR = 0.11 ± 0.06) compared with harbor seals that approach significance (mean MSR = 0.04 ± 0.01 ; $F_4 = 2.90$; $p = 0.06$). Among the two feeding strategies, suction feeding species (e.g., bearded and northern elephant seals) have a significantly larger masseter than biting species (e.g., California sea lions, harbor, ringed, Weddell seals; mean MSR = 0.04; $F_1 = 4.98$, $p = 0.04$).

4 | DISCUSSION

Pinnipeds in this study represent species with diverse feeding strategies and evolutionary histories, making this the most comprehensive and comparative analysis of pinniped craniofacial musculature to date. Pinnipeds conform to many of the craniofacial muscle morphology patterns described for other mammals (Burrows, 2008; Diogo et al., 2009, 2012, 2016; Evans & de Lahunta, 2013; Huber, 1931; Kastelein et al., 1991; Noden & Francis-West, 2006). Pinnipeds also show unique musculoskeletal differences from terrestrial mammals (Thewissen, 2009) that likely represent adaptations for their aquatic existence, including benthic foraging, underwater jaw abduction/adduction, and suction generation. There is broad conformity in the craniofacial muscle morphology across pinnipeds, but species also show some interspecific and intraspecific variation in muscle structure and function that is likely related to specific-specific ecologic and physiologic selective pressures.

We identify 32 unique pinniped craniofacial muscles that include facial expression, mastication, tongue, hyoid, and soft palate muscles (Table 3). Ringed and bearded seals have the fewest (24), whereas northern elephant seals have the most (32). Among mammals with comparable data, primates have the greatest number (40) of craniofacial muscles, whereas monotremes had the fewest (e.g., 24; Diogo et al., 2009). In fact, pinnipeds have the fewest facial expression muscles compared with other placental mammals for which comparable data exist (e.g., canids, felids, primates, rodents, sirenians; Diogo et al., 2008, 2009, 2012; Evans & de Lahunta, 2013); this pattern is primarily driven by a reduction in the number of facial expression muscles in pinnipeds. Although apes (gorillas, chimpanzees, and humans) have 21 facial expression muscles,

TABLE 1 Comparison of mean muscle to skull area ratios (MSRs) for each craniofacial muscles for the six pinniped species in the study

Group	Muscle	Bearded seals	California sea lions	Harbor seals	Northern elephant seals	Ringed seals	Weddell seals
		Suction	Biting	Biting	Suction	Biting	Biting
Facial expression	Buccinator	0.01 (1)	—	0.02 ± 0.00 (3)	0.08 ± 0.09 (2)	—	—
	Caninus	0.03 ± 0.03 (4)	0.04 (1)	0.02 ± 0.01 (4)	0.04 ± 0.03 (5)	0.02 ± 0.01 (2)	0.03 (1)
	Frontalis	—	0.02 (1)	—	0.04 (1)	0.01 (1)	—
	Levator labii superioris	0.05 ± 0.01 (2)	0.03 (1)	0.02 ± 0.01 (2)	0.03 ± 0.01 (4)	—	—
	Levator nasolabialis	0.06 ± 0.04 (4)	0.04 (1)	0.03 ± 0.01 (3)	0.04 ± 0.01 (5)	0.03 ± 0.00 (2)	—
	Orbicularis oculi	0.06 ± 0.06 (2)	0.01 ± 0.01 (2)	0.03 ± 0.00 (2)	0.04 ± 0.01 (2)	0.09 ± 0.01 (3)	0.05 (1)
	Orbicularis oris	0.14 ± 0.15 (4)	0.05 ± 0.02 (3)	0.04 ± 0.03 (3)	0.04 ± 0.03 (5)	0.02 (1)	0.01 (1)
	Platysma	0.15 ± 0.10 (2)	0.19 ± 0.09 (2)	—	0.16 ± 0.12 (6)	0.02 (1)	—
	Spinctor colli profundus	—	0.06 (1)	0.04 (1)	0.31 ± 0.24 (4)	—	0.02 (1)
	Zygomaticus	—	0.02 (1)	—	0.05 (1)	—	—
Mastication	Digastric	0.08 ± 0.05 (3)	0.12 ± 0.07 (4)	0.07 ± 0.02 (3)	0.08 ± 0.02 (6)	0.09 ± 0.04 (4)	0.11 (1)
	Masseter	0.05 ± 0.02 (3) ^a	0.06 ± 0.03 (4) ^b	0.04 ± 0.01 (5) ^{A,b}	0.11 ± 0.06 (6) ^{B,a}	0.05 ± 0.02 (3) ^b	—
	Lateral pterygoid	—	—	—	0.01 (1)	—	—
	Medial pterygoid	—	0.01 (1)	0.02 ± 0.00 (2)	0.02 ± 0.01 (5)	—	0.01 (1)
	Temporalis	0.08 (1)	0.15 (1)	0.09 ± 0.05 (3)	0.19 ± 0.07 (2)	0.11 ± 0.00 (2)	0.24 (1)
Tongue	Genioglossus	0.02 ± 0.01 (3)	0.05 ± 0.03 (3)	0.03 ± 0.00 (3)	0.06 ± 0.03 (3)	0.05 (1)	0.03 (1)
	Hyoglossus	0.03 ± 0.02 (3)	0.08 ± 0.03 (3)	0.02 ± 0.01 (3)	0.05 ± 0.04 (3)	0.03 (1)	0.07 (1)
	Styloglossus	0.01 (1) ^B	0.02 ± 0.01 (3) ^B	0.01 (1) ^B	0.03 ± 0.01 (2)	0.08 (1) ^A	0.03 (1)
Hyoid	Ceratohyoid	0.01 (1)	0.03 ± 0.00 (2)	0.02 (1)	0.02 ± 0.01 (2)	—	—
	Geniohyoid	0.03 ± 0.01 (3)	0.08 ± 0.04 (3)	0.04 ± 0.03 (4)	0.13 ± 0.13 (5)	0.08 (1)	—
	Mylohyoid	0.08 (1)	0.16 ± 0.20 (2)	0.06 (1)	0.11 ± 0.06 (5)	—	0.03 (1)
	Omohyoid	—	—	—	0.12 (1)	—	—
	Sternohyoid	0.03 (1)	0.11 ± 0.02 (2)	—	0.17 ± 0.12 (2)	—	—
	Stylohyoid	0.04 ± 0.03 (2)	0.02 ± 0.01 (2)	0.02 (1)	0.04 ± 0.02 (4)	0.02 (1)	—
	Thyrohyoid	0.03 ± 0.02 (2)	0.03 (1)	0.02 (1)	0.02 (1)	0.04 (1)	—

(Continues)

TABLE 1 (Continued)

Group	Muscle	Bearded seals	California sea lions	Harbor seals	Northern elephant seals	Ringed seals	Weddell seals
		Suction	Biting	Biting	Suction	Biting	Biting
Soft palate	Levator veli palatini	–	–	–	–	>0.01 (1)	–
	Tensor veli palatini	–	–	–	–	0.03 (1)	–

Values are reported as mean \pm SD and the number of individuals are included in parentheses (*n*).

Feeding strategies are based off of Kienle and Berta (2016).

Uppercase letters show significant differences between species from post-hoc pairwise contrasts ($p \leq 0.05$).

Lowercase letters show significant differences between biting and suction feeding taxa ($p \leq 0.05$).

TABLE 2 Comparison of the coefficient of variation (CV) of mean muscle to skull area ratios (MSRs) for each craniofacial muscles for each pinniped species in the study

Muscle group	Muscle	Bearded seals	California sea lions	Harbor seals	Northern elephant seals	Ringed seals	Weddell seals
Facial expression	Buccinator	–	–	0.19	1.17	–	–
	Caninus	1.07	–	0.38	0.66	0.27	–
	Frontalis	–	–	–	–	–	–
	Levator labii superioris	0.27	–	0.28	0.28	–	–
	Levator nasolabialis	0.72	–	0.37	0.23	0.1	–
	Orbicularis oculi	0.95	0.1	0.01	0.29	0.12	–
	Orbicularis oris	1.14	0.38	0.76	0.68	–	–
	Platysma	0.7	0.47	0.74	–	–	–
	Spinctor colli profundus	–	–	–	0.76	–	–
	Zygomaticus	–	–	–	–	–	–
	Mean	0.81	0.32	0.39	0.58	0.16	–
Mastication	Digastric	0.63	0.58	0.33	0.28	0.42	–
	Masseter	0.32	0.45	0.31	0.53	0.48	–
	Lateral pterygoid	–	–	–	–	–	–
	Medial pterygoid	–	–	0.13	0.31	–	–
	Temporalis	–	–	0.55	0.35	0.00	–
	Mean	0.48	0.52	0.33	0.37	0.30	–
Tongue	Genioglossus	0.49	0.74	0.08	0.49	–	–
	Hyoglossus	0.49	0.42	0.58	0.74	–	–
	Styloglossus	–	0.41	–	0.51	–	–
	Mean	0.49	0.52	0.33	0.58	–	–
Hyoid	Ceratohyoid	–	0.01	–	0.44	–	–
	Geniohyoid	0.59	0.46	0.72	1	–	–
	Mylohyoid	–	1.22	–	0.59	–	–
	Omohyoid	–	–	–	–	–	–
	Sternohyoid	–	0.2	–	0.72	–	–
	Stylohyoid	0.86	0.5	–	0.42	–	–
	Thyrohyoid	0.79	–	–	–	–	–
	Mean	0.75	0.48	0.72	0.63	–	–
	Overall mean	0.64	0.42	0.36	0.52	0.20	–

TABLE 3 Comparison of muscle counts by muscle group between different mammalian taxa for which comparable data are available

Scientific name	Species name	Facial expression	Mast.	Tongue	Hyoid	Soft palate	Sum	References
<i>Pusa hispida</i>	Ringed seal	≥10	≥3	3	≥5	≥2	≥23	This study
<i>Erignathus barbatus</i>	Bearded seal	10	≥3	3	7	?	≥23	This study
<i>Ornithorhynchus anatinus</i>	Platypus	8	5	2	8	1	24	Diogo (2009)
<i>Leptonychotes weddellii</i>	Weddell seal	11	4	3	5	≥1	≥24	This study
<i>Phoca vitulina</i>	Harbor seal	10	≥4	3	≥6	2	≥25	This study
<i>Zalophus californianus</i>	California sea lion	12	4	3	≥7	?	≥26	This study
<i>Trichechus inunguis</i>	Amazonian manatee	≥13	5	3	≥5	1	≥27	Domning (1978)
<i>Mirounga angustirostris</i>	Northern elephant seal	13	5	3	8	3	32	This study
<i>Cynocephalus volans</i>	Philippine flying lemur	16	5	4	6	1	32	Diogo (2009)
<i>Rattus norvegicus</i>	Norwegian rat	16	5	3	8	1	33	Diogo (2009)
<i>Aotus</i> sp.	Night monkey	17	5	3	7	2	34	Diogo and Wood (2011)
<i>Canis familiaris</i>	Dog	17	5	3	8	2	35	Evans and de Lahunta (2013)
<i>Panthera tigris</i>	Tiger	18	5	3	8	2	36	Diogo et al. (2012)
<i>Tupaia</i> sp.	Tree shrew	18	5	3	9	2	37	Diogo (2009)
<i>Lepilemur ruficaudatus</i>	Red-tailed sportive lemur	18	5	3	9	2	37	Diogo et al. (2009); Diogo and Wood (2011)
<i>Tarsius</i> sp.	Tarsier	18	5	3	8	3	37	Diogo and Wood (2011)
<i>Pongo pygmaeus</i>	Bornean orangutan	20	5	≥3	7	3	≥38	Diogo et al. (2009); Diogo and Wood (2011)
<i>Leptailurus serval</i>	Serval	20	5	3	8	2	38	Diogo et al. (2012)
<i>Hylobates lar</i>	Lar gibbon	20	5	4	7	3	39	Diogo et al. (2009); Diogo and Wood (2011)
<i>Macaca mulatta</i>	Rhesus macaque	20	5	4	8	3	40	Diogo et al. (2009); Diogo and Wood (2011)
<i>Gorilla gorilla</i>	Gorilla	21	5	4	7	3	40	Diogo et al. (2009); Diogo and Wood (2011)
<i>Pan troglodytes</i>	Chimpanzee	21	5	4	7	3	40	Diogo et al. (2009); Diogo and Wood (2011)
<i>Homo sapien</i>	Human	21	5	4	7	3	40	Diogo (2009)

pinnipeds only have ~10–13, likely as a result of adaptations for underwater life.

4.1 | Interspecific comparisons

4.1.1 | Facial expression muscles

The facial expression muscles form the outermost muscle layer surrounding the head. This muscle group is composed of the superficial craniofacial muscles (platysma and sphincter colli profundus), lip and nose muscles (orbicularis oris, zygomaticus, levator labii superioris,

caninus, buccinator, mentalis, and levator nasolabialis), and eye and ear muscles (orbicularis oculi, occipitalis, and frontalis). These muscles control fine-scale movements of the lips, vibrissae (mystacial and supraorbital), eyes, and ears. These sensory structures and their associated musculature are important for a variety of functions, including auditory, tactile, and visual (Hanke et al., 2009; Insley et al., 2003; Reichmuth et al., 2013; Schusterman et al., 2000).

Pinnipeds have reduced or lost some facial expression muscles that are found in other mammals (Diogo et al., 2008, 2009, 2012). For example, the pinniped mentalis is reduced or absent among species in this study. When present, the pinniped mentalis is only represented by a few fibers that blend with those of the orbicularis oris.

Additionally, the mentalis of phocids and otariids differs from that of odobenids (walruses), another closely related pinniped lineage. Walruses have an extremely well-developed mentalis that allows the lower lip to move in several directions, thereby playing a role in food manipulation and processing (Kastelein et al., 1991). A similar well-developed, prominent, fat-filled mentalis has been documented in some other mammals, including canids, felids, and primates; in these species, the mentalis moves the soft tissue and fat pad of the chin, which raises the central portion of the lip (Diogo et al., 2012; Evans & de Lahunta, 2013; Zide & McCarthy, 1989). Phocids and otariids also have a reduced or absent zygomaticus, and a similar pattern has been documented in odobenids (Kastelein et al., 1991). The zygomaticus structure and function vary among mammals, ranging from completely absent/reduced (e.g., pinnipeds, monotremes) to a distinct two-bellied muscle (e.g., felids, primates; Diogo et al., 2009, 2012; Diogo & Wood, 2011, 2012). In species with a robust zygomaticus, the muscle moves the mouth and/or ear cartilage and helps correct skin position during contractions of deeper facial expression muscles (Diogo & Wood, 2011; Diogo et al., 2012; Evans & de Lahunta, 2013). Few studies have examined the role of facial expression muscles in mammals (Miller, 1975; Waller & Micheletta, 2013), particularly in pinnipeds. The reduction and/or loss of facial expression muscles in pinnipeds suggests a lack of selective pressure to maintain their functionality.

Here, bearded seals, northern elephant seals, and California sea lions have the most robust and well-developed facial expression muscles. Bearded and northern elephant seals are ancestral phocid lineages that are categorized as specialized suction feeders based on skull and dental morphology (Berta et al., 2018; Churchill & Clementz, 2015; Kienle & Berta, 2016). Both species are also named for their unique facial features, from the bearded seals' expansive mystacial vibrissae (Dehn et al., 2007; Ling, 1977) to the male northern elephant seals' elongated, fleshy proboscis (Sanvito et al., 2007; Townsend, 1912). California sea lions are otariids with a skull morphology associated with biting (Adam & Berta, 2002; Churchill & Clementz, 2015). In comparison, more recently derived phocids (harbor, ringed, and Weddell seals) have the smallest and least developed facial expression musculature.

Bearded seals have robust musculature associated with the mouth and mystacial vibrissae (e.g., levator labii superioris, levator nasolabialis, orbicularis oris, caninus). The bearded seals' orbicularis oris is larger than that of other species in this study. The mystacial vibrissae are deeply embedded in the surrounding caninus and levator nasolabialis muscles. Facial nerves travel through both the caninus and levator nasolabialis to innervate the muscles of the bearded seal's large vibrissal bed. The increased size of the bearded seal's facial expression muscles supports and controls fine-scale movements of the mystacial vibrissae, as well as helps form the mouth into a small, circular opening when suction feeding (Marshall et al., 2006, 2008; Kienle et al., 2018). Bearded seals have the largest vibrissal follicle-sinus complex among all phocids and are second only to the walrus among all 33 extant pinnipeds (Marshall et al., 2006). The mammalian vibrissal follicle-sinus complex is composed

of specialized sensory structures that respond to vibrotactile cues in the environment that are transmitted to the brain (Halata, 1975; Marshall et al., 2006), presumably by afferent fibers of the trigeminal nerve's maxillary division. The vibrissal follicle-sinus complex in both bearded seals and walruses is hypothesized to be associated with their use of benthic suction feeding (Kastelein & van Gaalen, 1988; Marshall et al., 2006). Specifically, the well-developed vibrissal follicle-sinus complex may allow individuals to detect and discriminate between prey located on or near the seafloor.

Northern elephant seals have robust craniofacial musculature associated with the nose, mystacial vibrissae, and superficial muscles (i.e., nasalis, buccinator, platysma, sphincter colli profundus, and caninus). The northern elephant seal's large rostrum is composed of several muscles, specifically the nasalis, levator labii superioris, and caninus. All northern elephant seals, regardless of age or sex, have fleshier and larger nasal regions than other pinnipeds. Adult male northern elephant seals are characterized by the long proboscis that inspired the species' name (Sanvito et al., 2007; Townsend, 1912). Unfortunately, no adult male specimens were available for dissection, and, to our knowledge, no published description of their nasal musculature exists. Here, we find that all northern elephant seals in this study, from juvenile males to adult females, have long muscular noses. We hypothesize that the nasal musculature of adult males will cluster similar to its conspecifics in muscle morphology based on the stereotyped nasal musculature in other northern elephant seal age classes and sexes. The function of the northern elephant seals' iconic nose is still debated. It has been postulated that the nose plays a role in identifying age and breeding status, in male visual displays, and in aiding male vocalizations (Galimberti et al., 2019; Sandegren, 1976; Sanvito et al., 2007), but this requires further investigation. Similar to bearded seals and walruses, northern elephant seals are hypothesized to be suction feeders (Antonelis et al., 1987; Kienle & Berta, 2016; Naito et al., 2013); therefore, the increased size of the facial expression muscles may aid in suction feeding.

4.1.2 | Mastication muscles

The mastication muscles are named for their role in breaking down food for swallowing and digestion (Evans & de Lahunta, 2013; Hiimeae, 1967; Ito & Endo, 2016). However, pinnipeds do not masticate, and this is also true for most marine mammals. Most prey is swallowed whole with little to no processing (Kienle et al., 2017; Taylor, 1987; Werth, 2000). Despite the lack of mastication, the mastication muscles in pinnipeds play an important role in prey capture and consumption. Further, the mastication muscles aid in communication, social/aggressive interactions, and vocal signaling (Adam & Berta, 2002; Jones, et al., 2013; Kiliaridis, 1995). The mastication muscles sometimes refer only to the jaw adduction (closing) muscles—the masseter, temporalis, medial pterygoid, and lateral pterygoid. Here, we include the jaw abduction (opening) muscle, the digastric, as a mastication muscle following Evans and de Lahunta (2013) and consistent with descriptions of the walrus mastication

muscles (Kastelein et al., 1991). The digastric in some animals is sometimes classified as a mandibular muscle or hyoid muscle (Diogo et al., 2008, 2009, 2012). However, the pinniped digastric primarily functions to depress the mandible and does not have any attachments to the hyoid apparatus. In general, carnivorans—including pinnipeds—have large, powerful digastric muscles compared with other mammals. In particular, aquatic carnivorans (e.g., pinnipeds, mustelids—otters, weasels, badgers) have an enlarged digastric, which is potentially an adaptation for rapid jaw opening underwater (Scapino, 1976).

California sea lions and Weddell seals have the largest mastication muscles, and this is primarily due to their large, thick temporalis (Weddell seals) and digastric (California sea lions). The mastication muscles generate the forces needed to capture, subdue, and process prey (Hartstone-Rose, et al., 2012; Kienle et al., 2017; Law et al., 2016). Both California sea lions and Weddell seals rely on a biting feeding strategy during prey capture (Calhaem & Christoffel, 1969; Ponganis & Stockard, 2007; Roffe & Mate, 1984), and their large temporalis may be related to the need for rapid and strong jaw closure when targeting medium to large prey. Comparatively, large mastication muscles have been documented in mustelids, which also use a biting strategy (Ito & Endo, 2016; Scapino, 1976). Northern elephant seals, a suction feeder, and ringed seals, a biter, have the next largest mastication muscles after California sea lions and Weddell seals. Harbor seals, a biting taxon, have the smallest mastication muscles.

The mastication muscles are proportionally larger and better-developed in pinnipeds compared with the other craniofacial muscle groups. Pinniped mastication muscles are also broadly consistent in relative size and shape across taxa. Opening the jaw underwater is hindered by the increased viscosity of water, and aquatic carnivorans need more power during jaw opening compared with their terrestrial counterparts (Scapino, 1976). The suction feeding strategy also relies on rapid jaw opening to draw water and prey into the mouth (Kienle et al., 2018, 2019). The development of a well-developed mastication muscles—including the adaptation of a powerful digastric for jaw opening—therefore likely represents an adaptation in pinnipeds for feeding underwater. Furthermore, jaw closing is important for both trapping whole prey inside the oral cavity and generating appropriate bite forces when feeding. The mastication muscles, therefore, facilitate all aquatic pinniped feeding strategies, reinforcing our finding that this muscle group is well developed, robust, and stereotyped across pinnipeds. Further, mastication muscles are also used for purposes outside of feeding—such as vocal communication and intrasexual competition, and likely have additional selective pressures acting on these muscle forms and functions.

4.1.3 | Tongue muscles

The tongue muscles include the styloglossus, hyoglossus, genioglossus, and the intrinsic muscles of the body of the tongue (lingua propria). Together, the tongue muscles control the position,

orientation, and movement of the tongue. The tongue has multiple essential functions: it aids in mastication, food gathering, prey processing, transport, swallowing, and is the primary taste organ in the gustatory system (Doran & Baggett, 1971; Iwasaki, 2002; Sokoloff & Burkholder, 2012). The tongue of some marine mammals (e.g., baleen whales) is also a site of countercurrent heat exchange and prevents excess heat loss during mouth opening (Ekdale & Kienle, 2015; Heyning & Mead, 1997).

Pinnipeds retain most of the common mammalian tongue musculature (Gordon, 1984; Kastelein et al., 1991; Reidenberg, 2018). However, pinnipeds lack the palatoglossus. Other mammals lack the palatoglossus too, including some canids (Evans & de Lahunta, 2013) and felids (e.g., servals, tigers; Diogo et al., 2012). Mammalian tongues exhibit structural variation that reflects adaptations for different specialized functions (Doran & Baggett, 1971). The basic terrestrial mammal tongue is adapted for food manipulation, as many species rely on inertial food transport (Hiimeae & Crompton, 1985; Iwasaki, 2002; Werth, 2007). In contrast, aquatic mammals rely on hydrodynamic and hydraulic forces for prey capture and consumption. Aquatic mammals are often unable to pin down prey and cannot use inertial feeding effectively underwater (Taylor, 1987; Werth, 2007). As a result, many aquatic mammals, like pinnipeds, grab prey with their teeth (biting) or use the tongue (and hyoid) to draw prey into the mouth (suction). The tongue is then used to manipulate prey and move prey to the back of the throat so that it can be swallow prey whole with little to no processing. The tongue of many aquatic mammals has therefore been modified and plays a critical role in generating suction pressures for prey transport and intraoral prey transport (Iwasaki, 2002; Werth, 2000, 2004, 2007).

The pinniped tongue is extremely muscular, wide, thick, and freely mobile. This morphology differs from the narrow, thin tongues found in many terrestrial carnivorans (e.g., Liem, 1990; Sonntag, 1923). The increase in size and mobility of the pinniped tongue is likely associated with increased complexity and functionality (Doran & Baggett, 1971; Livingston, 1956). The comparably robust and muscular tongues in the pinnipeds in this study highlight the importance of this muscle group. Although studies are scarce, it appears that marine mammal tongues represent a continuum, where the tongues of more recently derived taxa (e.g., sea otters, *Enhydra lutris*) are most similar to those of terrestrial mammals (Emura et al., 2017; Shimoda et al., 1996), whereas fully aquatic mammals (i.e., cetaceans, sirenians) have tongues representing a more derived condition (Kastelein & Dubbeldam, 1990; Werth, 2000; Yoshimura et al., 2002, 2007).

As amphibious mammals, pinnipeds appear to represent an intermediate step in tongue morphology between fully terrestrial and fully aquatic mammals (Erdoğan et al., 2015; Yoshimura et al., 2002, 2007). The pinniped tongue is a specialized part of the feeding apparatus. For example, the tongues of South American fur seals and sea lions have well-developed papillary structures on the lingual surface that are used for manipulating and directing food to the upper digestive tract (Erdoğan et al., 2015). In walruses, the tongue generates negative pressure in the buccal cavity that is used to draw

in water and prey during suction feeding (Gordon, 1984; Kastelein et al., 1991). Additionally, since pinnipeds primarily consume whole prey without mastication, the tongue also functions to move prey from the front to the back of the mouth prior to swallowing. Because the tongue is important for generating suction pressures in walrus (Gordon, 1984; Kastelein et al., 1994), we had predicted that the suction feeding species in our study would have larger tongue musculature compared with biting species. However, this prediction only holds true for northern elephant seals. California sea lions, ringed and Weddell seals, the species with the next largest tongue muscles, are all biters. Data from captive feeding studies have shown that most pinnipeds are capable of generating suction during ingestion (prey capture, prey manipulation, and/or external prey processing) and intraoral transport, regardless of their skeletal adaptations for a particular feeding strategy (Hocking et al., 2013, 2015; Kienle et al., 2017, 2018, 2019; Marshall et al., 2008, 2014). Pinnipeds also use suction as both a distinct feeding strategy (here, suction feeding) or in combination with other feeding strategies (biting, filter feeding; Hocking et al., 2017; Kienle et al., 2017). Therefore, robust and muscular tongues across diverse pinniped taxa may reflect the ability of pinnipeds to generate suction underwater—regardless of their primary feeding strategy. Furthermore, the pinniped tongue may also play an important role in intraoral processing, regardless of the initial mode of prey capture (suction or biting).

Northern elephant seals have the largest and most unique tongue musculature. This pattern is primarily driven by the size of the genioglossus and lingua propria, which are responsible for moving, extending, and depressing the tongue and providing fine motor control of the apex of the tongue (Evans & de Lahunta, 2013).

4.1.4 | Hyoid muscles

The pinniped hyoid apparatus comprises nine bony elements (the unpaired basihyal and the paired thyrohyals, ceratohyals, epihyals, and stylohyals) and the associated musculature (i.e., sternohyoid, thyrohyoid, mylohyoid, ceratohyoid, geniohyoid, stylohyoid, omohyoid, and sternothyroid). The mammalian hyoid apparatus is involved in numerous functions, including supporting and suspending the tongue, swallowing, and moving the larynx. It is also the attachment site for major muscle groups involved in breathing, feeding, and sound production (Evans & de Lahunta, 2013; Reidenberg & Laitman, 1994; Takada et al., 2009).

Hyoid apparatus morphology substantially varies among mammals (Evans & de Lahunta, 2013; King, 1983; Naito, 1974; Peters & Hast, 1994; Reidenberg & Laitman, 1994; Takada et al., 2009; Weissenrubler et al., 2002). Few studies have described the bony and cartilaginous elements of the pinniped hyoid apparatus (King, 1969, 1983; Naito, 1974). Here, we find that pinnipeds retain the same bony and cartilaginous elements typically described for Carnivora (Evans & de Lahunta, 2013). Also, the musculoskeletal morphology of the pinniped hyoid in this study broadly matches that previously described for harbor seals (Naito, 1974) and spotted

seals (*Phoca largha*; King, 1983). Previous research on three of the four species of lobodontines (Antarctic phocids; Ross, crabeater, and leopard seals) documented that these species lacked paired stylohyals and that the proximal ends of the epihyals were unossified and attached directly on the auditory bulla (King, 1969, 1983). Although we were able to include Weddell seals, which is the only lobodontine not included in those previous studies, its hyoid apparatus was removed prior to this study so we cannot compare the number of bony and cartilaginous elements.

The pinniped hyoid apparatus is a robust and well-developed mobile structure with numerous elements working together to control movements of the oral, pharyngeal, and laryngeal regions. The muscles of the pinniped hyoid apparatus are largely conserved across pinnipeds, with the exception of northern elephant seals. The hyoid apparatus is thought to play a key role in creating the pressure differential used to generate suction (Gordon, 1984; Kastelein et al., 1991; Marshall et al., 2008, 2014; Reidenberg, 2018). Movements of the pinniped hyoid apparatus may also play a role in shaping the resonant spaces that affect sound production (King, 1970; Reidenberg, 2017; Reidenberg & Laitman, 2010).

We had predicted that the suction feeding pinnipeds would have larger hyoid musculature compared with the biting species. However, this pattern is only true for northern elephant seals, similar to our findings for the tongue musculature. The large hyoid musculature of the northern elephant seals is driven by the larger sizes of the geniohyoid, omohyoid, sternohyoid, and stylohyoid compared with other species. Northern elephant seals also have a unique sternohyoid. Their sternohyoid has two heads, attaches into the geniohyoid rather than into the basihyal, and is closely connected to the fibers of the sternothyroid. The typical mammalian sternohyoid depresses the basihyal, elongates the pharyngeal space, and is activated during food capture, processing, and swallowing (Evans & de Lahunta, 2013; Konow et al., 2010). However, in northern elephant seals, the unique sternohyoid suggests a function in depressing the floor of the mouth. Northern elephant seals also have a distinctive stylohyoid. The stylohyoid is superficial to the mylohyoid. It has a belly that tapers toward the origin and insertion, rather than maintaining a rectangular shape throughout its length. Their stylohyoid originates on the junction of the mastoid and squamosal processes, caudal to its origin in other pinnipeds. Finally, the two muscle pairs meet and insert into each other at the ventral midline to form a chevron shape. The typical mammalian stylohyoid is responsible for extending the width of the back of the throat, thereby playing an important role in food processing and swallowing (Evans & de Lahunta, 2013; Herring, 1993; Kastelein et al., 1991). The stylohyoid of northern elephant seals, however, appears to elevate the oral floor cavity.

The northern elephant seal sternohyoid and stylohyoid suggests a different or modified functional role of the hyoid apparatus from other mammals. Modified hyoid muscles have also been documented in anteaters and are attributed to their elongated necks (Naples, 1999). The function of this unique anatomic position of these hyoid muscles in northern elephant seals is currently unclear. It may be that these modified muscle arrangements provide increased support

for the floor of the mouth (stylohyoid) and in depressing the hyoid apparatus to create a larger intraoral cavity when suction feeding (sternohyoid). These actions could generate negative pressure in the oropharyngeal space to enable suction feeding without withdrawing the tongue as a piston, as other pinnipeds or cetaceans do (Gordon, 1984; Kastelein et al., 1994). There may be some advantage to not use the tongue as a piston during suction feeding that may explain the unique muscular anatomy of northern elephant seals. The stylohyoid is superficial to the mylohyoid and interdigitates in the midline in a V-shape with its pair. Perhaps this anatomy allows the northern elephant seal tongue to perform other functions. Northern elephant seals, for example, heavily rely on vocal communication for many aspects of their life history, including dominance interactions, parental care, and reproduction (Casey et al., 2020; Southall et al., 2019). Their unique hyoid morphology may help shape the oral cavity to produce their unique vocalizations. Male northern elephant seals produce loud, stereotyped vocalizations that are used to establish dominance hierarchies in male–male interactions (Casey et al., 2020). The ability to depress the floor of the mouth through the modified sternohyoid and stylohyoid may increase the volume of the oral cavity, helping to project sound.

4.1.5 | Soft palate muscles

The muscles of the soft palate are closely associated with the muscles of the pharynx and include the tensor veli palatini, levator veli palatini, and palatinus. Together, these soft palate muscles form the roof of the mouth and are responsible for moving and stretching the palate (Evans & de Lahunta, 2013; Kastelein et al., 1991). The soft palate is distinguished from the hard palate by the absence of bony elements. In the specimens in this study, these muscles are difficult to find, separate, and describe based on their proximity to the throat, tissue degradation, and small size. This differs from the well-developed palatal musculature described for other mammals (Crompton, 1989) as well as for walruses and Ross seals (Kastelein et al., 1991; King, 1969). Therefore, we suggest that future studies of the hyoid apparatus concentrate on examining and further comparing the functional morphology of these muscles.

4.2 | Craniofacial muscles and feeding strategies

We find support for our hypothesis that pinnipeds with skull and dental morphologic adaptations for specific feeding strategies (biting or suction feeding) exhibit corresponding craniofacial musculature specializations. This pattern was most apparent for the suction feeding specialists in this study, bearded and northern elephant seals. Both species are classified as suction feeders based on skull and dental morphology, behavioral feeding trials, and kinematic performance data (Adam & Berta, 2002; Churchill & Clementz, 2015; Kienle & Berta, 2016; Kienle et al., 2018; Marshall et al., 2008; Naito et al., 2013). Bearded and northern elephant seals also share

a similar skull and dental morphology with the best-known pinniped suction feeder: the walrus. All three species have wide skulls and palates that increase the volume of the oral cavity (Kienle & Berta, 2016). These three species also have reduced postcanine dentition, with rounded postcanine teeth that barely erupt from the gum line. Reduced or absent teeth are associated with other suction feeding mammals (Churchill & Clementz, 2015; Johnston & Berta, 2011; Wainwright, et al., 2015; Werth, 2006). The teeth are not used for catching or holding onto prey and are therefore likely vestigial in suction feeding marine mammal taxa.

We predicted that pinnipeds with morphologic adaptations for suction feeding would have more robust tongue and hyoid musculature. Here, we demonstrate that both suction feeding species, bearded and northern elephant seals, have more masseters than biting species; further, one suction feeding species (northern elephant seals) has the largest facial expression and hyoid muscles. When pinnipeds use suction feeding, the lateral facial expression muscles (e.g., caninus, buccinator, orbicularis oris) visibly tighten. This may help shape the oral cavity into a rounded cylinder to aid in drawing in water and prey (Kienle et al., 2018, 2019). The lateral craniofacial muscles, particularly the caninus, are also responsible for controlling fine-scale motions of the mystacial vibrissae. The mystacial vibrissae are an important structure for detecting and capturing prey (Kastelein et al., 1991; Marshall et al., 2006). Although the mechanics of pinniped suction feeding are not well known, models and functional studies suggest that the pressure differential during suction used to draw water and prey into the mouth is generated by coordinated movements of the tongue and hyoid (Gordon, 1984; Kastelein et al., 1994; Marshall et al., 2008, 2014). Specifically, the retraction and depression of the tongue are thought to act as a piston, resulting in low pressure inside the oral cavity (Gordon, 1984; Kastelein et al., 1994). This prediction is supported by controlled feeding trials that have observed the pinniped hyoid depressing during suction feeding events (Kienle et al., 2018, 2019). Both suction feeding specialist species exhibit more variability in muscle size (MSR; Table 2) than biting species. This finding is consistent with behavioral and kinematic studies of pinniped suction feeding (Kienle et al., 2018, 2019), suggesting that suction feeding is a variable and flexible pinniped feeding strategy. Together, these results suggest that the suction feeding pinnipeds invest more heavily in the development and growth of their facial expression, tongue, and hyoid muscles compared with biting species, as these muscle groups are most likely responsible for detecting prey as well as generating and maintaining suction pressures when feeding.

Most pinnipeds (including four of the six species in this study) are classified as biters (Adam & Berta, 2002; Churchill & Clementz, 2015; Jones, et al., 2013; Kienle & Berta, 2016, 2018). Biting is a ubiquitous marine mammal feeding strategy (Hocking et al., 2017; Kienle et al., 2017, 2020; Werth, 2000) as well as the ancestral strategy of pinnipeds (Berta et al., 2018). We hypothesized that pinnipeds with skull adaptations for biting (e.g., California sea lions, harbor, ringed, eddell seals) would have larger mastication muscles than species with skull adaptations for suction feeding; only California sea

lions and Weddell seals fit this prediction. California sea lions and Weddell seals have been classified as biters based on skull and dental morphology, diet studies, and opportunistic observations of wild animals feeding (Ainley & Siniff, 2009; Burns et al., 1998; Churchill & Clementz, 2015; Kienle & Berta, 2016; Lake et al., 2003; Ponganis & Stockard, 2007; Roffe & Mate, 1984). Here, we document that Weddell seals have the largest temporalis, while California sea lions have the largest digastric. We predict that these large jaw abduction and adduction muscles allow California sea lions and Weddell seals to capture and consume large prey that require a lot of handling and processing using the jaws and teeth (Ainley & Siniff, 2009; Everitt et al., 1981; Lowry & Carretta, 1999; Ponganis & Stockard, 2007). Although not included in this study, we also predict that the mastication muscles of leopard seals (*Hydrurga leptonyx*) are extremely large and powerful, as this species exhibits morphologic adaptations for biting (specifically grip and tear feeding; Adam & Berta, 2002; Kienle & Berta, 2016; Kienle et al., 2017; King, 1983) and is a quintessential biter when consuming large endothermic prey (e.g., penguins, other pinnipeds; Penney & Lowry, 1967).

Contrary to our initial hypothesis, approximately half of the biting species in this study (i.e., harbor seals and ringed seals) do not show specific musculoskeletal adaptations for biting or suction feeding. This finding supports results from controlled feeding trials with captive pinnipeds (Hocking et al., 2013; Kienle et al., 2018, 2019, 2020; Marshall et al., 2008, 2014). In fact, most pinnipeds use both biting and suction feeding, regardless of morphological adaptations for particular feeding strategies (Berta, et al., 2018; Heithaus & Dill, 2009; Kienle et al., 2018, 2019, 2020; Marshall & Goldbogen, 2015). Further, several pinniped species without morphologic adaptations for suction have been shown to be extremely capable suction feeders (Hocking et al. 2013, 2014, 2016; Kienle et al., 2018, 2019; Marshall et al., 2014, 2015), overturning a previous hypothesis that suction feeding requires a specialized skull morphology (Adam & Berta, 2002; Kienle & Berta, 2016; Kienle et al., 2018; Werth, 2000). Similarly, we find that although suction feeding and some biting taxa have some unique musculoskeletal adaptations, pinnipeds in this study have robust, stereotyped, and well-developed facial expression, mastication, tongue, and hyoid musculature—all of which are important for both biting and suction feeding. Although filter feeding pinnipeds (e.g., crabeater seals, *Lobodon carcinophaga*; leopard seals, *Hydrurga leptonyx*) were not available for this study, we predict that filter feeding specialists have robust, well-developed facial muscles, as seen in biting and suction feeding pinnipeds. Further, feeding trials with captive leopard seals show that filter feeding heavily relies on the generation of suction, suggesting possible convergence between suction and filter feeding in musculoskeletal morphology.

Most pinnipeds are opportunistic predators, with individuals alternating between different feeding strategies depending on the feeding context (e.g., position in the water column, prey type, prey size; Bowen et al., 2002; Breed et al., 2009; Hocking et al., 2015, 2016; Kienle et al., 2019, 2020). The behavioral flexibility afforded to animals by their ability to switch between strategies is likely invaluable for these marine predators foraging in temporally and spatially

dynamic marine ecosystems (Beever et al., 2017). Therefore, we suggest that most pinnipeds retain the ability to use multiple underwater feeding strategies by investing in craniofacial musculature that is associated with multiple feeding strategies. We also predict that musculoskeletal specializations for particular feeding strategies likely confer some distinct benefits when capturing and consuming prey. For example, we hypothesize that specialized suction feeders generate more powerful suction pressures as a result of their musculoskeletal morphologic specializations for suction feeding compared with non-specialists. Alternatively, pinnipeds with biting adaptations are likely able to generate stronger bite forces than suction feeding specialists. Specialization may provide individuals with access to additional and novel prey resources compared with generalists. However, there are also likely functional and performance trade-offs between specialist and generalist feeding morphologies, which remain to be tested.

Moving forward, we anticipate that the inclusion of additional species, as well as increased sampling of different age classes, sexes, and populations, will better clarify and elucidate the patterns we describe here. It will be particularly interesting for future studies to examine the musculoskeletal adaptations of filter feeding pinnipeds, which were not included in this study. Additionally, it is important to remember that the craniofacial musculoskeletal system is involved in regulating multiple sensory systems and behaviors besides feeding, including inter- and intraspecific communication, intrasexual aggression, vision, respiration, and hearing. Therefore, although the focus of this study has been on identifying musculoskeletal adaptations associated with aquatic feeding, craniofacial muscles play multiple functional roles that vary in importance based on the life history of different species. We look forward to future studies teasing apart the function of different craniofacial muscles associated with sensory systems and biologic functions other than feeding.

5 | CONCLUSIONS

Pinnipeds largely conform to mammalian patterns of craniofacial musculoskeletal morphology, but there are some distinct differences that are attributable to their secondary adaptation to an aquatic lifestyle compared with their terrestrial counterparts. Interspecific musculoskeletal differences among pinniped taxa were observed that are associated with different aquatic feeding strategies, specifically biting or suction feeding. Overall, pinnipeds have well-developed facial expression, mastication, tongue, and hyoid musculature necessary for both suction feeding and biting, allowing most species to operate as generalist foragers and switch between biting and suction feeding when foraging in dynamic marine habitats. This study provides the first comparison of craniofacial musculoskeletal elements in pinnipeds and highlights the remarkable adaptations of these marine predators for life underwater.

ACKNOWLEDGEMENTS

We thank W. Ary, C. Casey, R. Dunkin, A. Favilla, S. Quellen Field, J. Fredianai, R. Furbish, C. Goetsch, R. Holser, L. Huckstadt, J. Kendall-Bar,

S.C. Kienle, J. Martin, E. McHuron, J. Osborne, M. Smallcomb, A. Valenzuela-Toro, M. Yamato, S. Young, and N. Zellmer for their invaluable assistance with this project. We acknowledge the California Department of Fish and Wildlife and the San Diego State University Museum of Biodiversity, especially M. Van Patten, for the use of their necropsy facilities. We thank the NOAA National Marine Mammal Stranding Network for facilitating our access to samples. We are extremely grateful to L. Quakenbush at the Alaska Department of Fish and Game, The Marine Mammal Center, Moss Landing Marine Lab, the Witmer Lab at Ohio University, the Pacific Marine Mammal Center, SeaWorld San Diego, J. Burns, and M. Shero at the University of Alaska Anchorage, the University of California, Santa Cruz, and the West Coast Marine Mammal Stranding Network for providing specimens. Ringed and bearded seals for this study were provided by Alaska Native subsistence hunters through Alaska Department of Fish and Game's (ADFG) ice seal monitoring program with funding from NMFS. Funding for this project was provided by an NOAA Dr. Nancy Foster Scholarship and an American Museum of Natural History Lerner Grey Grant for Marine Research awarded to S.S.K., a Community College Research Internship for Scientific Engagement (CC-RISE) awarded to R.C. We also thank A. Kirkpatrick for their design of the graphical abstract.

AUTHOR CONTRIBUTIONS

S. S. K. conceived the study, with input from J. R. All co-authors collected the data. S. S. K. and R. D. C. analyzed the data. S. S. K. wrote the manuscript with R. D. C. and J. R. providing input and editing assistance. R. D. C. created the figures.

DATA AVAILABILITY STATEMENT

The data that support the findings of this study are openly available in Dryad at <http://doi.org/10.5061/dryad.47d7wm3d3>.

ORCID

Sarah S. Kienle  <https://orcid.org/0000-0002-8565-2870>

Joy S. Reidenberg  <https://orcid.org/0000-0002-4180-7156>

REFERENCES

- Adam, P.J. & Berta, A. (2002) Evolution of prey capture strategies and diet in the Pinnipedimorpha (Mammalia, Carnivora). *Oryctos*, 4, 83–107.
- Amson, E. & de Muizon, C. (2014) A new durophagous phocid (Mammalia: Carnivora) from the late Neogene of Peru and considerations on monachine seals phylogeny. *Journal of Systematic Palaeontology*, 12, 523–548.
- Antonelis, G.A. Jr, Lowry, M.S., DeMaster, D.P. & Fiscus, C.H. (1987) Assessing northern elephant seal feeding habits by stomach lavage. *Marine Mammal Science*, 3, 308–322.
- Ashley-Ross, M.A., Hsieh, S.T., Gibb, A.C. & Blob, R.W. (2013) Vertebrate land invasions—past, present, and future: an introduction to the symposium. *Integrative and Comparative Biology*, 53, 192–196.
- Bates, D., Mächler, M., Bolker, B. & Walker, S. (2014) Fitting linear mixed-effects models using lme4. *arXiv preprint arXiv:1406.5823*.
- Beever, E.A., Hall, L.E., Varner, J., Loosen, A.E., Dunham, J.B., Gahl, M.K. et al. (2017) Behavioral flexibility as a mechanism for coping with climate change. *Frontiers in Ecology and the Environment*, 15, 299–308.
- Berta, A., Churchill, M. & Boessenecker, R.W. (2018) The origin and evolutionary biology of pinnipeds: seals, sea lions, and walrus. *Annual Review of Earth and Planetary Sciences*, 46, 203–228.
- Blob, R.W., Espinoza, N.R., Butcher, M.T., Lee, A.H., D'Amico, A.R., Baig, F. et al. (2014) Diversity of limb-bone safety factors for locomotion in terrestrial vertebrates: evolution and mixed chains. *Integrative and Comparative Biology*, 54, 1058–1071.
- Bowen, W.D., Tully, D., Boness, D.J., Bulheier, B.M. & Marshall, G.J. (2002) Prey-dependent foraging tactics and prey profitability in a marine mammal. *Marine Ecology Progress Series*, 244, 235–245.
- Breed, G.A., Jonsen, I.D., Myers, R.A., Bowen, W.D. & Leonard, M.L. (2009) Sex-specific, seasonal foraging tactics of adult grey seals (*Halichoerus grypus*) revealed by state-space analysis. *Ecology*, 90, 3209–3221.
- Burns, J.M., Trumble, S.J., Castellini, M.A. & Testa, J.W. (1998) The diet of Weddell seals in McMurdo Sound, Antarctica as determined from scat collections and stable isotope analysis. *Polar Biology*, 19, 272–282.
- Burrows, A.M. (2008) The facial expression musculature in primates and its evolutionary significance. *BioEssays*, 30, 212–225.
- Calhaem, I. & Christoffel, D.A. (1969) Some observations of the feeding habits of a Weddell seal, and measurements of its prey, *Dissostichus mawsoni*, at McMurdo Sound, Antarctica. *New Zealand Journal of Marine and Freshwater Research*, 3, 181–190.
- Casey, C., Charrier, I., Mathevon, N., Nasr, C., Forman, P. & Reichmuth, C. (2020) The genesis of giants: behavioural ontogeny of male northern elephant seals. *Animal Behavior*, 166, 247–259.
- Churchill, M. & Clementz, M.T. (2015) Functional implications of variation in tooth spacing and crown size in Pinnipedimorpha (Mammalia: Carnivora). *Anatomical Record*, 298, 878–902.
- Crompton, A.W. (1989). The evolution of mammalian mastication. In: Wake, D.B. & Roth, G. (Eds.) *Complex organismal functions: integration and evolution in vertebrates*. Chichester: John Wiley and Sons, pp. 23–40.
- Debey, L.B. & Pyenson, N.D. (2013) Osteological correlates and phylogenetic analysis of deep diving in living and extinct pinnipeds: what good are big eyes? *Marine Mammal Science*, 29, 48–83.
- Dehn, L.A., Sheffield, G.G., Follmann, E.H., Duffy, L.K., Thomas, D.L. & O'Hara, T.M. (2007) Feeding ecology of phocid seals and some walrus in the Alaskan and Canadian Arctic as determined by stomach contents and stable isotope analysis. *Polar Biology*, 30, 167–181.
- Diogo, R. (2009) The head and neck muscles of the Philippine colugo (Dermoptera: *Cynocephalus volans*), with a comparison to tree-shrews, primates, and other mammals. *Journal of Morphology*, 270(1), 14–51.
- Diogo, R., Abdala, V., Lonergan, N. & Wood, B.A. (2008) From fish to modern humans—comparative anatomy, homologies and evolution of the head and neck musculature. *Journal of Anatomy*, 213, 391–424.
- Diogo, R., Bello-Hellegouarch, G., Kohlsdorf, T., Esteve-Altava, B. & Molnar, J.L. (2016) Comparative myology and evolution of marsupials and other vertebrates, with notes on complexity, Bauplan, and “scala naturae”. *Anatomical Record*, 299, 1224–1255.
- Diogo, R., Pastor, F., De Paz, F., Potau, J.M., Bello-Hellegouarch, G., Ferrero, E.M. et al. (2012) The head and neck muscles of the serval and tiger: homologies, evolution, and proposal of a mammalian and a veterinary muscle ontology. *Anatomical Record*, 295, 2157–2178.
- Diogo, R. & Wood, B. (2011) Soft-tissue anatomy of the primates: phylogenetic analyses based on the muscles of the head, neck, pectoral region and upper limb, with notes on the evolution of these muscles. *Journal of Anatomy*, 219(3), 273–359.
- Diogo, R. & Wood, B.A. (2012) *Comparative anatomy and phylogeny of primate muscles and human evolution*. New York, NY: CRC Press.
- Diogo, R., Wood, B.A., Aziz, M.A. & Burrows, A. (2009) On the origin, homologies and evolution of primate facial muscles, with a particular

- focus on hominoids and a suggested unifying nomenclature for the facial muscles of the Mammalia. *Journal of Anatomy*, 215, 300–319.
- Domning, D.P. (1978) The myology of the Amazonian manatee, *Trichechus inunguis* (Natterer) (Mammalia: Sirenia). *Acta Amazonica*, 8, 5–81.
- Doran, G.A. & Baggett, H. (1971) A structural and functional classification of mammalian tongues. *Journal of Mammalogy*, 52, 427–429.
- Ekdale, E.G. & Kienle, S.S. (2015) Passive restriction of blood flow and counter-current heat exchange via lingual retia in the tongue of a neonatal gray whale *Eschrichtius robustus* (Cetacea, Mysticeti). *The Anatomical Record*, 298(4), 675–679.
- Emura, S., Sugiyama, K. & Kusuda, S. (2017) Morphology of the lingual papillae of the polar bear (*Ursus maritimus*). *Okajimas Folia Anatomica Japonica*, 94, 55–59.
- Endo, H., Sasaki, H., Hayashi, Y., Petrov, E.A., Amano, M. & Miyazaki, N. (1998) Macroscopic observations of the facial muscles in the Baikal seal (*Phoca sibirica*). *Marine Mammal Science*, 14(4), 778–788.
- Erdoğan, S., Villar Arias, S. & Pérez, W. (2015) Morphology of the lingual surface of South American fur seal (*Arctocephalus australis*) and sea lion (*Otaria flavescens*). *Microscopy Research and Technique*, 78, 140–147.
- Evans, H.E. & De Lahunta, A. (2013) *Miller's anatomy of the dog*. St. Louis, MO: Elsevier Health Sciences.
- Everitt, R.D., Gearin, P.J., Skidmore, J.S. & DeLong, R.L. (1981) Prey items of harbor seals and California sea lions in Puget Sound, Washington. *The Murrelet*, 62, 83–86.
- Fish, F.E. (2000) Biomechanics and energetics in aquatic and semiaquatic mammals: platypus to whale. *Physiological and Biochemical Zoology*, 73, 683–698.
- Fox, J. & Weisberg, S. (2011) *An R companion to applied regression*, 2nd edition. Thousand Oaks, CA: Sage.
- Fulton, T.L. & Strobeck, C. (2010) Multiple markers and multiple individuals refine true seal phylogeny and bring molecules and morphology back in line. *Proceedings of the Royal Society B*, 277, 1065–1070.
- Galimberti, F., Sanvito, S., Vinesi, M.C. & Cardini, A. (2019) “Nosemetrics” of wild southern elephant seal (*Mirounga leonina*) males using image analysis and geometric morphometrics. *Journal of Zoological Systematics and Evolutionary Research*, 57, 710–720.
- Gerhardt, H.C. (1991) Female mate choice in treefrogs: static and dynamic acoustic criteria. *Animal Behavior*, 42, 615–635.
- Gordon, K.R. (1984) Models of tongue movement in the walrus (*Odobenus rosmarus*). *Journal of Morphology*, 182, 179–196.
- Halata, Z. (1975) The mechanoreceptors of the mammalian skin ultrastructure and morphological classification. In: Brodal, A., Hild, W., van Limborgh, J., Ortmann, R., Schiebler, T.H., Töndury, G. & Wolff, E. (Eds.) *Advances in anatomy, embryology and cell biology* 50–5. New York: Springer-Verlag, pp. 5–75.
- Hanke, F.D., Hanke, W., Scholtyssek, C. & Dehnhardt, G. (2009) Basic mechanisms in pinniped vision. *Experimental Brain Research*, 199, 299.
- Hartstone-Rose, A., Perry, J.M. & Morrow, C.J. (2012) Bite force estimation and the fiber architecture of felid masticatory muscles. *Anatomical Record*, 295, 1336–1351.
- Heithaus, M.R. & Dill, L.M. (2009) Feeding strategies and tactics. In: Perrin, W., Wursig, B. & Thewissen, J. (Eds.) *Encyclopedia of marine mammals*. San Diego, CA: Academic Press, pp. 414–423.
- Herring, S. (1993) Functional morphology of mammalian mastication. *American Zoologist*, 33, 289–299.
- Heyning, J.E. & Mead, J.G. (1997) Thermoregulation in the mouths of feeding gray whales. *Science*, 278(5340), 1138–1140.
- Hiimeae, K.M. (1967) Masticatory function in the mammals. *Journal of Dental Research*, 46, 883–893.
- Hiimeae, K.M. & Crompton, A.W. (1985) Mastication, food transport and swallowing. In: Hildebrand, M., Bramble, D.M., Liem, K.F. & Wake, D.B. (Eds.) *Functional vertebrate morphology*. Cambridge, MA: Harvard University Press, pp. 262–290.
- Hocking, D.P., Evans, A.R. & Fitzgerald, E.M. (2013) Leopard seals (*Hydrurga leptonyx*) use suction and filter feeding when hunting small prey underwater. *Polar Biology*, 36, 211–222.
- Hocking, D.P., Fitzgerald, E.M.G., Salverson, M. & Evans, A.R. (2015) Prey capture and processing behaviors vary with prey size and shape in Australian and subantarctic fur seals. *Marine Mammal Science*, 32, 568–587.
- Hocking, D.P., Ladds, M.A., Slip, D.J., Fitzgerald, E.M.G. & Evans, A.R. (2016) Chew, shake, and tear: prey processing in Australian sea lions (*Neophoca cinerea*). *Marine Mammal Science*, 33, 541–557.
- Hocking, D.P., Marx, F.G., Park, T., Fitzgerald, E.M. & Evans, A.R. (2017) A behavioural framework for the evolution of feeding in predatory aquatic mammals. *Proceedings of the Royal Society B: Biological Sciences*, 284(1850), 20162750.
- Hocking, D.P., Salverson, M., Fitzgerald, E.M. & Evans, A.R. (2014) Australian fur seals (*Arctocephalus pusillus doriferus*) use raptorial biting and suction feeding when targeting prey in different foraging scenarios. *PLoS One*, 9(11), e112521.
- Howell, A.B. (1929) Contribution to the comparative anatomy of the eared and earless seals (genera *Zalophus* and *Phoca*). *Proceedings of the United States National Museum*, 73, 1–142.
- Huber, E. (1931) *Evolution of facial musculature and facial expression*, 98, 1024.
- Insley, S., Phillips, A.V. & Charrier, I. (2003) A review of social recognition in pinnipeds. *Aquatic Mammals*, 29, 181–201.
- Ito, K. & Endo, H. (2016) Comparative study of physiological cross-sectional area of masticatory muscles among species of carnivora. *Mammal Study*, 41, 181–190.
- Iwasaki, S.I. (2002) Evolution of the structure and function of the vertebrate tongue. *Journal of Anatomy*, 201, 1–13.
- Johnston, C. & Berta, A. (2011) Comparative anatomy and evolutionary history of suction feeding in cetaceans. *Marine Mammal Science*, 27, 493–513.
- Jones, K.E. & Goswami, A. (2010) Morphometric analysis of cranial morphology in pinnipeds (Mammalia, Carnivora): convergence, ecology, ontogeny, and dimorphism. In: Goswami, A. & Friscia, A. (Eds.) *Carnivoran evolution: new views on phylogeny, form and function*. Cambridge: Cambridge University Press.
- Jones, K.E., Ruff, C.B. & Goswami, A. (2013) Morphology and biomechanics of the pinniped jaw: mandibular evolution without mastication. *Anatomical Record*, 296, 1049–1063.
- Kastelein, R.A. & Dubbeldam, J.L. (1990) Marginal papillae on the tongue of the harbour porpoise (*Phocoena phocoena*), bottlenose dolphin (*Tursiops truncatus*) and Commerson's dolphin (*Cephalorhynchus commersonii*). *Aquatic Mammals*, 15, 158–170.
- Kastelein, R., Gerrits, N., Dubbeldam, J. & Kastelein, R. (1991) The anatomy of the walrus head (*Odobenus rosmarus*). Part 2: description of the muscles and of their role in feeding and haul-out behaviour. *Aquatic Mammals*, 17, 156–180.
- Kastelein, R.A., Muller, M. & Terlouw, A. (1994) Oral suction of a Pacific walrus (*Odobenus rosmarus divergens*) in air and under water. *Zeitschrift Fur Säugetierkunde*, 59, 105–115.
- Kastelein, R.A. & Van Gaalen, M.A. (1988) The sensitivity of the vibrissae of a Pacific walrus (*Odobenus rosmarus divergens*) Part 1. *Aquatic Mammals*, 14, 123–133.
- Kelley, N.P. & Motani, R. (2015) Trophic convergence drives morphological convergence in marine tetrapods. *Biology Letters*, 11, 20140709.
- Kelley, N.P. & Pyenson, N.D. (2015) Evolutionary innovation and ecology in marine tetrapods from the Triassic to the Anthropocene. *Science*, 348, aaa3716.
- Kienle, S. (2021) Comparative examination of pinniped craniofacial musculature and its role in aquatic feeding. *Dryad, Dataset*. <https://doi.org/10.5061/dryad.47d7wm3d3>
- Kienle, S.S. & Berta, A. (2016) The better to eat you with: the comparative feeding morphology of phocid seals (Pinnipedia, Phocidae). *Journal of Anatomy*, 228, 396–413.
- Kienle, S.S. & Berta, A. (2018) The evolution of feeding strategies in phocid seals (Pinnipedia, Phocidae). *Journal of Vertebrate Paleontology*, 38, e1559172.

- Kienle, S.S., Cacanindin, A., Kendall, T., Richter, B., Ribeiro-French, C., Castle, L. et al. (2019) Hawaiian monk seals exhibit behavioral flexibility when targeting prey of different size and shape. *Journal of Experimental Biology*, 222, jeb194985.
- Kienle, S.S., Ekdale, E.G., Reidenberg, J.S. & Deméré, T.A. (2015) Tongue and hyoid musculature and functional morphology of a neonate gray whale (Cetacea, Mysticeti, *Eschrichtius robustus*). *Anatomical Record*, 298, 660–674.
- Kienle, S.S., Hermann-Sorensen, H., Costa, D.P., Reichmuth, C. & Mehta, R.S. (2018) Comparative feeding strategies and kinematics in phocid seals: suction without specialized skull morphology. *Journal of Experimental Biology*, 221, jeb179424.
- Kienle, S.S., Law, C.J., Costa, D.P., Berta, A. & Mehta, R.S. (2017) Revisiting the behavioural framework of feeding in predatory aquatic mammals. *Proceedings of the Royal Society B*, 284, 20171035.
- Kienle, S.S., Powers, J., Kendall, T., Richter, B., Castle, L., Lentés, G. et al. (2020) Context matters: Hawaiian monk seals switch between feeding strategies depending on ecological context. *Integrative and Comparative Biology*, 60, 425–439.
- Kiliaridis, S. (1995) Masticatory muscle influence on craniofacial growth. *Acta Odontologica Scandinavica*, 53, 196–202.
- King, J.E. (1969) *Some aspects of the anatomy of the Ross seal, Ommatophoca rossi* (Pinnipedia: Phocidae). Cambridge: British Antarctic Survey.
- King, J.E. (1970) *Some aspects of the anatomy of the Ross seal, Ommatophoca rossi* (Pinnipedia: Phocidae). Cambridge: British Antarctic Survey.
- King, J.E. (1983) *Seals of the world*. London: University of Queensland Press.
- Konow, N., Thexton, A., Crompton, A.W. & German, R.Z. (2010) Regional differences in length change and electromyographic heterogeneity in sternohyoid muscle during infant mammalian swallowing. *Journal of Applied Physiology*, 109, 439–448.
- Lake, S., Burton, H. & van den Hoff, J. (2003) Regional, temporal and fine-scale spatial variation in Weddell seal diet at four coastal locations in east Antarctica. *Marine Ecology Progress Series*, 254, 293–305.
- Law, C.J., Young, C. & Mehta, R.S. (2016) Ontogenetic scaling of theoretical bite force in southern sea otters (*Enhydra lutris nereis*). *Physiological and Biochemical Zoology*, 89(5), 347–363.
- Lenth, R.V. (2016) Least-squares means: the R package lsmeans. *Journal of Statistical Software*, 69, 1–33.
- Liem, K.F. (1990) Aquatic versus terrestrial feeding modes: possible impacts on the trophic ecology of vertebrates. *American Zoologist*, 30, 209–221.
- Ling, J.K. (1977) Vibrissae of marine mammals. In: Harrison, R.J. (Ed.) *Functional anatomy of marine mammals*. London: Academic Press.
- Livingston, R.M. (1956) Some observations on the natural history of the tongue. *Annals of the Royal College of Surgeons of England*, 19, 185–200.
- Liwanag, H.E., Berta, A., Costa, D.P., Budge, S.M. & Williams, T.M. (2012) Morphologic and thermal properties of mammalian insulation: the evolutionary transition to blubber in pinnipeds. *Biological Journal of the Linnean Society*, 107, 774–787.
- Lowry, M.S. & Carretta, J.V. (1999) Market squid (*Loligo opalescens*) in the diet of California sea lions (*Zalophus californianus*) in southern California (1981–1995). *California Cooperative Oceanic Fisheries Investigations Report*, 40, 196–207.
- Marshall, C.D., Amin, H., Kovacs, K.M. & Lydersen, C. (2006) Microstructure and innervation of the mystacial vibrissal follicle-sinus complex in bearded seals, *Erignathus barbatus* (Pinnipedia: Phocidae). *The Anatomical Record*, 288, 13–25.
- Marshall, C.D. & Goldbogen, J.A. (2015) Feeding mechanisms. In: Castellini, M.A. & Mellish, J.-A. (Eds.) *Marine mammal physiology: requisites for ocean living*. New York, NY: CRC Press.
- Marshall, C.D., Kovacs, K.M. & Lydersen, C. (2008) Feeding kinematics, suction and hydraulic jetting capabilities in bearded seals (*Erignathus barbatus*). *Journal of Experimental Biology*, 211, 699–708.
- Marshall, C.D., Rosen, D.A. & Trites, A.W. (2015) Feeding kinematics and performance of basal otariid pinnipeds, Steller sea lions and northern fur seals: implications for the evolution of mammalian feeding. *Journal of Experimental Biology*, 218(20), 3229–3240.
- Marshall, C.D., Wieskotten, S., Hanke, W., Hanke, F.D., Marsh, A., Kot, B. et al. (2014) Feeding kinematics, suction, and hydraulic jetting performance of harbor seals (*Phoca vitulina*). *PLoS One*, 9, e86710.
- Miller, E.H. (1975) A comparative study of facial expressions of two species of pinnipeds. *Behaviour*, 53, 268–284.
- Mori, M. (1958) The skeleton and musculature of *Zalophus*. *Okajimas Folia Anatomica Japonica*, 31, 203–284.
- Murie, J. (1872) XVI. Researches upon the anatomy of the pinnipedia. Part II. Descriptive anatomy of the sea-lion (*Otaria jubata*). *The Transactions of the Zoological Society of London*, 7, 527–596.
- Naito, Y. (1974) The hyoid bones of two kinds of harbour seals in the adjacent waters of Hokkaido. *Scientific Reports of the Whales Research Institute*, 26, 313–320.
- Naito, Y., Costa, D.P., Adachi, T., Robinson, P.W., Fowler, M. & Takahashi, A. (2013) Unravelling the mysteries of a mesopelagic diet: a large apex predator specializes on small prey. *Functional Ecology*, 27(3), 710–717.
- Naples, V.L. (1999) Morphology, evolution and function of feeding in the giant anteater (*Myrmecophaga tridactyla*). *Journal of Zoology*, 249, 19–41.
- Noden, D.M. & Francis-West, P. (2006) The differentiation and morphogenesis of craniofacial muscles. *Developmental Dynamics*, 235, 1194–1218.
- Paterson, R.S., Rybczynski, N., Kohno, N. & Maddin, H.C. (2020) A total evidence phylogenetic analysis of pinniped phylogeny and the possibility of parallel evolution within a monophyletic framework. *Frontiers in Ecology and Evolution*, 7, 457.
- Penney, R.L. & Lowry, G. (1967) Leopard seal predation of adelic penguins. *Ecology*, 48, 878–882.
- Peters, G. & Hast, M.H. (1994) Hyoid structure, laryngeal anatomy, and vocalization in felids (Mammalia: Carnivora: Felidae). *Zeitschrift Fur Saugetierkunde*, 59(2), 87–104.
- Piérard, J. (1971) Osteology and myology of the Weddell seal *Leptonychotes weddelli* (Lesson, 1826). *Antarct Pinnipedia*, 18, 53–108.
- Ponganis, P.J. & Stockard, T.K. (2007) Short Note: the Antarctic toothfish: how common a prey for Weddell seals? *Antarctic Science*, 19, 441–442.
- R Core Team. (2019) *R: a language and environment for statistical computing*. Vienna: R Foundation for Statistical Computing, <https://www.R-project.org/> [Accessed 17th August 2021].
- Reichmuth, C., Holt, M.M., Mulsow, J., Sills, J.M. & Southall, B.L. (2013) Comparative assessment of amphibious hearing in pinnipeds. *Journal of Comparative Physiology A*, 199, 491–507.
- Reidenberg, J.S. (2017) Terrestrial, semiaquatic, and fully aquatic mammal sound production mechanisms. *Acoust Today*, 13, 35–43.
- Reidenberg, J.S. (2018) Musculature. In: Bernd Wursig, J.G.M. & Thewissen, K.K. (Eds.) *Encyclopedia of marine mammals*. Cambridge, MA: Academic Press.
- Reidenberg, J.S. & Laitman, J.T. (1994) Anatomy of the hyoid apparatus in Odontoceti (toothed whales): specializations of their skeleton and musculature compared with those of terrestrial mammals. *Anatomical Record*, 240, 598–624.
- Reidenberg, J.S. & Laitman, J.T. (2010) Generation of sound in marine mammals. *Handbook of Behavioral Neuroscience*, 19, 451–465.
- Roffe, T.J. & Mate, B.R. (1984) Abundances and feeding habits of pinnipeds in the Rogue River, Oregon. *The Journal of Wildlife Management*, 48, 1262–1274.
- Saban, R. (1968) Musculature de la tête. In: Grassé, P.P. (Ed.) *Traité de zoologie XVI: 3. Mammifères*. Paris: Masson et Cie.
- Sandegren, F.E. (1976) Agonistic behavior in the male northern elephant seal. *Behaviour*, 57, 136–157.

- Sanvito, S., Galimberti, F. & Miller, E.H. (2007) Having a big nose: structure, ontogeny, and function of the elephant seal proboscis. *Canadian Journal of Zoology*, 85, 207–220.
- Scapino, R.P. (1976) Function of the digastric muscle in carnivores. *Journal of Morphology*, 150, 843–859.
- Schneider, C.A., Rasband, W.S. & Eliceiri, K.W. (2012) NIH Image to ImageJ: 25 years of image analysis. *Nature Methods*, 9, 671–675.
- Schusterman, R.J., Kastak, D., Levenson, D.H., Reichmuth, C.J. & Southall, B.L. (2000) Why pinnipeds don't echolocate. *Journal of the Acoustical Society of America*, 107, 2256–2264.
- Schwenk, K. (2000) *Feeding: form, function and evolution in tetrapod vertebrates*. San Diego, CA: Academic Press.
- Shimoda, T., Nakanishi, E., Yoshino, S. & Kobayashi, S. (1996) Light and scanning electron microscopic study on the lingual papillae in the newborn sea otter *Enhydra lutris*. *Okajimas Folia Anatomica Japonica*, 73, 65–74.
- Sokoloff, A. & Burkholder, T. (2012) Tongue structure and function. In: McLoon, L.K. & Andrade, F. (Eds.) *Craniofacial muscles*. New York: Springer.
- Sonntag, C.F. (1923) The comparative anatomy of the tongues of the mammalia—VIII. Carnivora. *Proceedings of the Zoological Society of London*, 93, 129–153.
- Southall, B.L., Casey, C., Holt, M., Insley, S. & Reichmuth, C. (2019) High-amplitude vocalizations of male northern elephant seals and associated ambient noise on a breeding rookery. *Journal of the Acoustical Society of America*, 146, 4514–4524.
- Takada, Y., Izumi, M. & Gotoh, K. (2009) Comparative anatomy of the hyoid apparatus of carnivores. *Mammal Study*, 34(4), 213–218.
- Taylor, M.A. (1987) How tetrapods feed in water: a functional analysis by paradigm. *Zoological Journal of the Linnean Society*, 91, 171–195.
- Thewissen, J.G.M. (2009) Musculature. In: Perrin, W.F., Würsig, B. & Thewissen, J.G.M. (Eds.) *Encyclopedia of marine mammals*. San Diego, CA: Academic Press.
- Thewissen, J.G. & Nummela, S. (2008) *Sensory evolution on the threshold: adaptations in secondarily aquatic vertebrates*. Los Angeles, CA: Univ of California Press.
- Townsend, C.H. (1912) *The northern elephant seal* (No. 2). New York, NY: The Society of the Zoological Park.
- Van Valkenburgh, B., Curtis, A., Samuels, J.X., Bird, D., Fulkerson, B., Meachen-Samuels, J. et al. (2011) Aquatic adaptations in the nose of carnivores: evidence from the turbinates. *Journal of Anatomy*, 218, 298–310.
- Wainwright, P.C., McGee, M.D., Longo, S.J. & Patricia Hernandez, L. (2015) Origins, innovations, and diversification of suction feeding in vertebrates. *Integrative and Comparative Biology*, 55, 134–145.
- Wainwright, P.C., Mehta, R.S. & Higham, T.E. (2008) Stereotypy, flexibility and coordination: key concepts in behavioral functional morphology. *Journal of Experimental Biology*, 211, 3523–3528.
- Waller, B.M. & Micheletta, J. (2013) Facial expression in nonhuman animals. *Emotion Review*, 5(1), 54–59.
- Weissengruber, G.E., Forstenpointner, G., Peters, G., Kübber-Heiss, A. & Fitch, W.T. (2002) Hyoid apparatus and pharynx in the lion (*Panthera leo*), jaguar (*Panthera onca*), tiger (*Panthera tigris*), cheetah (*Acinonyx jubatus*) and domestic cat (*Felis silvestris* f. *catus*). *Journal of Anatomy*, 201(3), 195–209.
- Werth, A.J. (2000) Feeding in marine mammals. In: Schwenk, K. (Ed.) *Feeding: form, function and evolution in tetrapod vertebrates*. San Diego, CA: Academic Press.
- Werth, A.J. (2004) Functional morphology of the sperm whale (*Physeter macrocephalus*) tongue, with reference to suction feeding. *Aquatic Mammals*, 30, 405–418.
- Werth, A.J. (2006) Mandibular and dental variation and the evolution of suction feeding in Odontoceti. *Journal of Mammalogy*, 87, 579–588.
- Werth, A.J. (2007) Adaptations of the cetacean hyolingual apparatus for aquatic feeding and thermoregulation. *The Anatomical Record*, 290, 546–568.
- Yoshimura, K., Shindo, J., Miyawaki, Y., Kobayashi, K. & Kageyama, I. (2007) Scanning electron microscopic study on the tongue and lingual papillae of the adult spotted seal, *Phoca largha*. *Okajimas Folia Anatomica Japonica*, 84, 83–98.
- Yoshimura, K., Shindoh, J. & Kobayashi, K. (2002) Scanning electron microscopy study of the tongue and lingual papillae of the California sea lion (*Zalophus californianus californianus*). *The Anatomical Record*, 267, 146–153.
- Zide, B.M. & McCarthy, J. (1989) The mentalis muscle: an essential component of chin and lower lip position. *Plastic and Reconstructive Surgery*, 83, 413–420.
- Zimmer, C. (1999) *At the water's edge: fish with fingers, whales with legs, and how life came ashore but then went back to sea*. New York: Touchstone.

SUPPORTING INFORMATION

Additional supporting information may be found in the online version of the article at the publisher's website.

How to cite this article: Kienle, S.S., Cuthbertson, R.D. & Reidenberg, J.S. (2022) Comparative examination of pinniped craniofacial musculature and its role in aquatic feeding. *Journal of Anatomy*, 240, 226–252. <https://doi.org/10.1111/joa.13557>