

Case Report

Closed reduction of a posterior sternoclavicular joint dislocation: A case report

Tadashi Iwai^{a,b,*}, Kazushige Tanaka^a, Mamoru Okubo^a

^a Department of Orthopedic Surgery, Kishima Hon-in Hospital, 3-33, Gakuonji, Yao-shi, Osaka 581-0853, Japan

^b Department of Orthopedic Surgery, Osaka City University Graduate School of Medicine, 1-4-3 Asahi-Machi, Abeno-Ku, Osaka 545-8585, Japan

ARTICLE INFO

Keywords:

Posterior sternoclavicular joint dislocation

Judo

Closed reduction

ABSTRACT

Sternoclavicular joint dislocation (SCJD) is a rare injury; there are only two reported cases of SCJD that have occurred during judo practice. We present a case of an 18-year-old male athlete who fell while practicing judo and experienced upper left chest pain. He was diagnosed with posterior SCJD at another institute before being transferred to our hospital. Closed reduction was initially not possible using traditional methods. Reduction was eventually accomplished by clamping the proximal end of the clavicle using bone forceps and rotating it while pulling it upward. Many authors have reported that closed reduction is difficult if not performed within 48 h after SCJD injury. However, we were able to achieve closed reduction approximately 72 h after injury. We found that reduction might be easily accomplished by pulling the proximal end of the clavicle up and rotating it when other closed reduction methods are unsuccessful.

Introduction

Sternoclavicular joint dislocation (SCJD) is very rare, representing less than 1% of all dislocations and 3% of shoulder dislocations [1]. SCJD may be anterior or posterior, with the latter representing only 5% of cases [2]. Posterior SCJD is potentially fatal and is a true emergency due to the vital structures that lie posterior to the medial clavicle.

There are only two reported cases of SCJD occurring in judo [3,4], and only one was a case of posterior SCJD [4].

We herein report a case of posterior SCJD that occurred during judo practice.

Case history

The patient was an 18-year-old male with no past medical history who had been thrown by his opponent during judo practice. He presented at another hospital with good general health status and consciousness. However, the left shoulder had decreased range of motion. Radiographs and CT revealed posterior SCJD (Fig. 1).

The patient presented at the orthopaedic department of our hospital for a second opinion. On physical examination, there was marked tenderness localised over the left SCJ, as well as an obvious deformity with less prominence of the joint on the left compared with the right. The patient was neurovascularly intact. Radiographs demonstrated SCJ asymmetry between left and right sides. The patient was scheduled for urgent closed reduction within 24 h.

Closed reduction of the left posterior SCJD was performed under fluoroscopic guidance approximately 72 h after the initial injury.

* Department of Orthopedic Surgery, Osaka City University Graduate School of Medicine, 1-4-3 Asahi-Machi, Abeno-Ku, Osaka 545-8585, Japan.
E-mail address: qq329xpd@opal.ocn.ne.jp (T. Iwai).

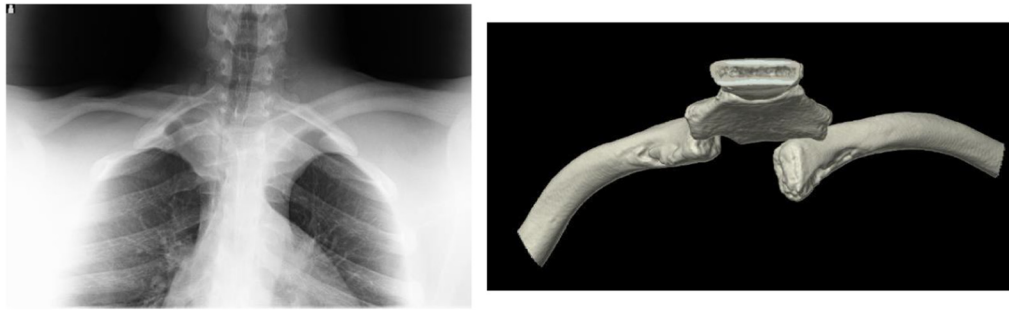


Fig. 1. Pre-reduction X-ray and CT scan.

The patient was placed in a supine position with a towel bolster between his scapulae, and gentle traction was applied to the left arm while it was extended and in 90° abduction [5]. A percutaneously placed towel clip was used to hold the proximal end of the clavicle and pull it upwards [5]; we also retracted the left shoulder with caudal traction on the adducted arm [6]. At first, reduction was not achieved. However, reduction was eventually accomplished by clamping the proximal end of the clavicle using bone forceps and pulling it upwards with rotation (Fig. 2). The sternum and the distal end of the clavicle were used as anatomical landmarks. Reduction resulted in stability of the SCJ. CT demonstrated that the SCJ was correctly positioned (Fig. 3). Vital signs, including blood pressure fluctuation, were measured for 24 h post-reduction. There were no complications after the reduction.

The patient was placed in a figure-of-eight clavicle brace and left shoulder sling and admitted for monitoring of potential damage to the surrounding vital structures. The patient remained in the brace for 8 weeks and the sling for 3 weeks following reduction. Chest CT was performed to verify not only the position of the clavicle but also the neurovascular bundle of the upper chest area. Two weeks after reduction, the patient was allowed to internally and externally rotate the adducted arm. Activity was limited until 3 weeks after reduction, when the sling was discontinued. The patient returned to sports 3 months post-injury without difficulty. Fourteen months after reduction, radiography and 3D CT showed complete reduction of the SCJ without any instability or shoulder disability.

Discussion

Posterior SCJD occurs secondary to an indirect force to the posterolateral shoulder, forcing the lateral clavicle anteriorly and levering the medial clavicle posteriorly. Such an indirect force can be caused during contact sports such as football, wrestling, and judo [7]. Less commonly, posterior SCJD can occur when a posterior force is transmitted directly to the surface of the medial clavicle, which typically occurs during athletic events or motor vehicle accidents [8,9]. The mechanism in the present case was likely to be indirect force. However, there are only two previously reported cases of posterior SCJD occurring in judo (Table 1). Although posterior SCJD may be very rare in judo, it should be suspected after trauma during highly competitive sports.

In cases of recent and isolated posterior SCJD, attempting closed reduction under general anaesthesia within 48 h maximises the chance of success [7]. The reduction technique comprises placing the patient in supine position with a sandbag between the shoulder

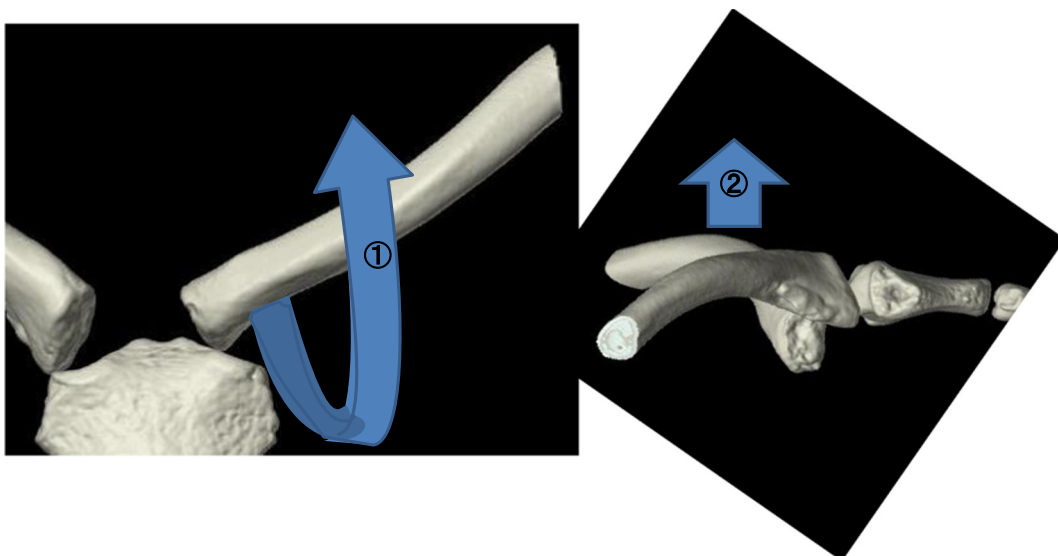


Fig. 2. Our technique for the reduction of a posterior sternoclavicular joint dislocation.

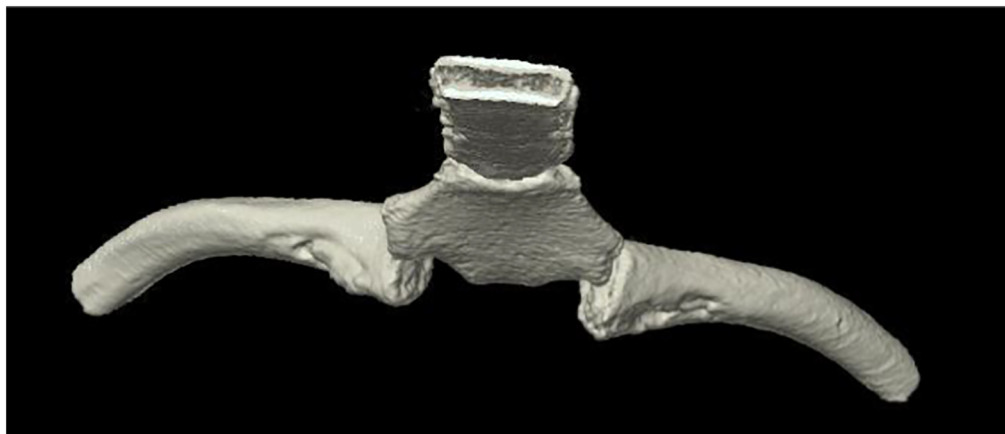


Fig. 3. Post-reduction CT scan.

Table 1

Previous paper concerning SCJD in judo.

Author	Year	Age/sex	SCID	Treatment	Ref
Castropil W et al.	2008	16M	Anterior	Surgery after conservative treatment	[3]
Galanis N et al.	2014	12M	Posterior	Closed reduction (Rockwood's method, 90-degree abduction and traction)	[4]
Our case		18M	Posterior	Closed reduction (Modified Rockwood's method using bone forceps)	

blades. Traction is applied to the adducted arm, while pressure is applied on the shoulder toward the back. If external manoeuvres fail, use of a percutaneous towel clip or small sharp bone-holding forceps can help with reduction [5]. The presence of a thoracic surgeon is recommended for possible vascular complications. Recent posterior SCJD with closed reduction failure or the existence of chest complications requires surgical treatment, while avoiding the use of Kirschner pins/wires that can migrate and cause serious complications due to the proximity of the mediastinum. Post-reduction, restraint is provided by a figure-of-eight bandage for 4–6 weeks [1].

In the present case, closed reduction was achieved under general anaesthesia. However, there was no consultation with a thoracic surgeon. Generally, if there are no thoracic surgeons available, it is better to transfer the patient to a facility where thoracic or vascular surgeons can assist. Nevertheless, the patient and his parents chose to undergo treatment in our facility and gave informed consent before the reduction. Although surgery is indicated in cases of posterior SCJD with closed reduction failure or complications, we reattempted closed reduction after the initial reduction failure. We chose closed reduction instead of surgical treatment for three reasons: many previous reports have mentioned the justification of closed reduction [7,10], the patient's parents chose closed reduction after being informed of the choices, and there were no associated emergency symptoms.

There are some reported techniques for closed reduction of posterior SCJD. Rockwood suggested a closed reduction technique using a towel clip placed percutaneously to grasp the medial clavicle and pull it anteriorly, also indicating that the abduction traction technique is useful [5]. In the abduction traction technique, the shoulder is abducted to 90° and traction is applied; an extension force is then applied to the shoulder, resulting in anterior translation of the medial clavicle back into the joint [2]. Buckerfield et al. described a technique involving shoulder retraction with caudal traction on the adducted arm [6], which achieves reduction in some cases where other methods of closed reduction have failed. Therefore, closed reduction in the present case was performed using both Rockwood's and Buckerfield's methods. Reduction was initially not achieved but was eventually accomplished by clamping the proximal end of the clavicle with bone forceps and pulling it up with rotation. We could not find any previous reports about the addition of rotation to Rockwood's method. We believe that reduction might be more easily accomplished by using this modified Rockwood's technique with a towel clip.

Patient declaration statement

The authors certify that they have obtained all appropriate patient consent forms. In the form the patient has given his consent for his images and other clinical information to be reported in the journal. The patient understands that their names and initials will not be published and due efforts will be made to conceal their identity, but anonymity cannot be guaranteed. This case report was approved by the Institutional Review Board of Kishima Hon-in Hospital. Written informed consent was obtained from the patient.

Financial statement

The authors declare no financial statement.

Sources of support

The authors declare no sources of support.

Conflict of interest

The authors declare no potential conflict of interests.

References

- [1] G. Ngom, A.S. Mohamed, M.O. El Housseine, O. Ndour, Traumatic posterior sternoclavicular joint dislocation in a child: a case report, *Pan Afr. Med. J.* 19 (2014) 386.
- [2] C.A. Rockwood, D.P. Green, R.W. Bucholz, *Rockwood and Green's Fractures in Adults*, Lippincott Williams & Wilkins, Philadelphia, 2006.
- [3] W. Castropil, L.B. Ramadan, A.C. Bitar, B. Schor, C. de Oliveira D'Elia, Sternoclavicular dislocation reconstruction with semitendinosus tendon autograft: a case report, *Knee Surg. Sports Traumatol. Arthrosc.* 16 (2008) 865–868.
- [4] N. Galanis, P. Anastasiadis, F. Grigoropoulou, J. Kirkos, G. Kapetanos, Judo-related traumatic posterior sternoclavicular joint dislocation in a child, *Clin. J. Sport Med.* 24 (2014) 271–273.
- [5] C.A. Rockwood, Dislocations of the sternoclavicular joint, in: E. Evans (Ed.), *American Academy of Orthopaedic Surgeons Instructional Course Lectures: Volume XXIV*, CV Mosby, St. Louis, 1975, pp. 144–159.
- [6] C.T. Buckerfield, M.E. Castle, Acute traumatic retrosternal dislocation of the clavicle, *J. Bone Joint Surg. Am.* 66 (1984) 379–385.
- [7] F. Tepolt, P.M. Carry, P.C. Heyn, N.H. Miller, Posterior sternoclavicular joint injuries in the adolescent population; a meta-analysis, *Am. J. Sports Med.* 42 (2014) 2517–2524.
- [8] E.R. Glass, J.D. Thompson, P.A. Cole, T.M. Gause 2nd, G.T. Altman, Treatment of sternoclavicular joint dislocations: a systematic review of 251 dislocations in 24 case series, *J. Trauma* 70 (2011) 1294–1298.
- [9] D. Thut, D. Hergan, A. Dukas, M. Day, O.H. Sherman, Sternoclavicular joint reconstruction: a systematic review, *Bull. NYU Hosp. Jt. Dis.* 69 (2011) 128–135.
- [10] J.A. Sykes, C. Ezetendu, A. Sivitz, J. Lee Jr., H. Desai, K. Norton, et al., Posterior dislocation of sternoclavicular joint encroaching on ipsilateral vessels in 2 pediatric patients, *Pediatr. Emerg. Care* 27 (2011) 327–330.