

Can rivaroxaban be a drug of choice for treating heparin-induced thrombocytopenia in a patient with pulmonary thromboembolism? 🎬

Marija Vavlukis, Irina Kotlar, Hajber Taravari, Lidija Poposka, Sasko Kedev
 University Clinic of Cardiology, Medical Faculty, University Ss' Cyril and Methodius; Skopje-Republic of Macedonia

Introduction

Heparin-induced thrombocytopenia (HIT) is an adverse effect of heparin therapy (1). There are two types of HIT: non-immunomedi-ated (HIT-I) and immunomedi-ated (HIT-II) disorders. HIT-II is characterized by the formation of IgG antibodies against the heparin-PLT factor 4 complex (PF4) (1, 2). Bounded with heparin, this factor creates a neoantigen and stimulates the production of antibodies (2). Activated PLTs, along with the heparin/PF4 antibody complex attached to their surface, undergo aggregation and premature removal from the circulation, leading to thrombocytopenia and additionally to a procoagulant state with high potential for thrombus formation and thromboembolic events (3). The incidence of HIT-II is 0.1%–1% in low-molecular-weight heparins (LMWH) and 3%–5% in un-fractionated heparin (UHF)-

treated patients (3). In HIT-II, the PLT count drop can be seen 3–4 days after exposure in patients with pre-existing heparin-PF4 antibodies from a previous exposure to heparin, whereas in those exposed for the first time, the PLT count drops 5–10 days after heparin administration (3). It has been confirmed that new oral anticoagulants (NOACs) offer advantages regarding this side effect (4), and this case report aims to share our first positive experience in relation to the previously mentioned .

Case Report

A 35-year-old patient presented with shortness of breath and tachycardia that had worsened in the last 4 days following phlegmon treatment on the left leg. Besides immobility, obesity was a significant risk factor (body mass index, 32.4 kg/m²). ECG revealed sinus tachycardia, right axis deviation, and an S₁Q₃T₃ pattern typical of pulmonary thromboembolism (PTE) (Fig. 1).

He was hospitalized and suspicion of PTE was confirmed using D-dimer test (8700 ng/mL), color Doppler ultrasound (non-obstructive thrombus in the left femoral superficial vein), echo-cardiography [large thrombus in the right atrium (RA), dilated right ventricle (RV) with reduced systolic function, McConnell's sign, tricuspid regurgitation, and dilated truncus pulmonary (TP)], and computed tomography (CT) [RV/LV ratio, >1; thrombi in RA; saddle thrombus in TP; and subocclusive thrombi in the main pulmonary arteries] (Fig. 2). Anticoagulant therapy with

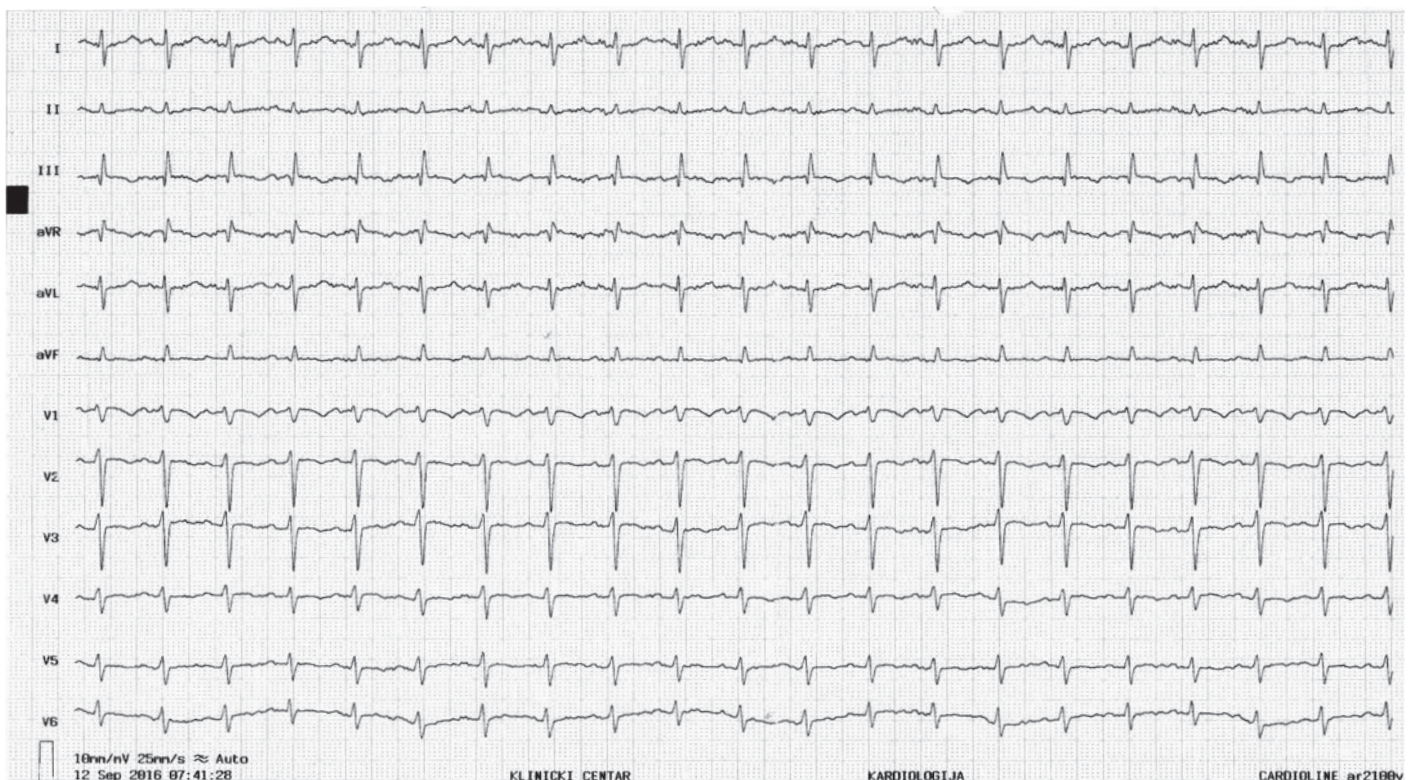


Figure 1. ECG at patient admission

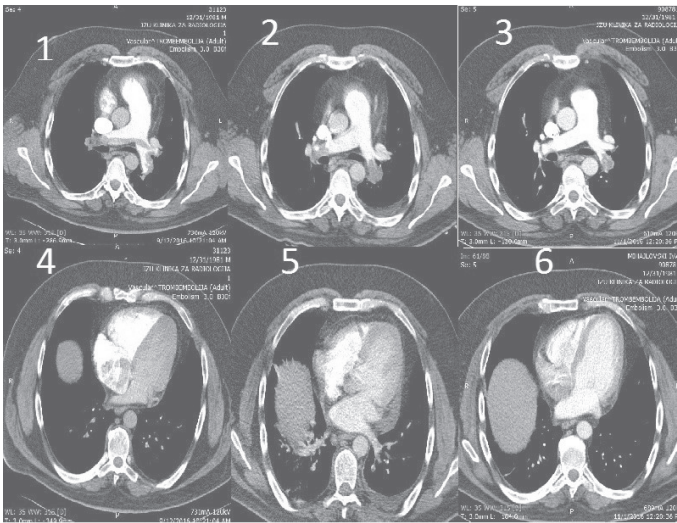


Figure 2. CT scan - angio images at the time of diagnosis, and during the treatment with rivaroxaban

1-3: truncus pulmonalis, arteriae pulmonales and their principal branches at the time of diagnosis (1); after 10 days (2) and after 1 month (3) treatment with rivaroxaban; RA thrombus, dilated RV (RV/LV ratio >1) (4); RV re-shaped after 10 days and 1 month treatment with rivaroxaban

UFH was initiated. During the follow-up hemograms and hemostasis, although the therapeutic UFH effect was confirmed by prothrombin and activated partial thromboplastin times, which were within the therapeutic range, a significant drop in the PLT count was observed [(initial 278×10^9 L to 11×10^9 L) on day five. Suspicion of HIT was confirmed with increased heparin-PF4 antibodies [positive ELISA test (reactivity, >40% and heparin inhibition, >50%)]. A very low PLT count, accompanied with epistaxis and hemoptysis, was an indication for PLT concentrate transfusion. UFH was replaced with LMWH. After an initial rise of the PLT count (109×10^9 L), a significant drop [$>50\%$ (52×10^9 L)] was again observed after 5 days. At that point rivaroxaban was initiated (15 mg twice daily). Rivaroxaban led to a progressive rise in the PLT count (262×10^9 L), which remained stable, simultaneously with a significant thrombotic material resolution, leading to normalization of RV function seen at 2-weeks' echocardiography control and on CT scans performed after 10 days and 1 month (RV/LV ratio, <1; lysis of the thrombi in RA; saddle thrombus; and the one in the left PA) (Fig. 2, Video 1).

Discussion

This case draws attention to the importance of close follow-up of patients receiving heparin therapy in order to recognize the early signs of HIT. Diagnosis is typically made on clinical grounds, with laboratory tests playing a supportive role (significant PLT drop, $\geq 50\%$ of the baseline value or $< 150 \times 10^9$ /L) (2). Four T's have been recommended for clinical use: thrombocytopenia, timing of PLT count drop, thrombosis and other sequelae, and other non-evident causes of thrombocytopenia (5, 6). Treatment should be initiated as soon as HIT diagnosis is suspected. Exposure to all forms of heparin should be discontinued, and according to the

current guidelines, alternative anticoagulants such as the direct thrombin inhibitors (DTIs) lepirudin, bivalirudin, argatroban, fondaparinux, and danaparoid should be initiated (6). DTIs do not react with HIT antibodies but are associated with a higher bleeding risk and are available only in parenteral forms, making them unsuitable for outpatient treatment. Vitamin K antagonists do not interact with HIT antibodies but can cause venous limb gangrene and skin necrosis during the hypercoagulable stage of HIT and are difficult to maintain within their therapeutic range (4). Rivaroxaban, as all NOACs, might be a potential candidate for HIT treatment because of the direct antithrombin/anti FXa activity as opposed to heparins, a feature that makes NOACs particularly suitable in patients with HIT (7, 8). A study by Walenga confirms that rivaroxaban does not cause PLT activation or aggregation with any of the HIT antibodies (7).

Conclusion

Rivaroxaban appears to be effective in the treatment of HIT patients. This conclusion applies to all NOACs, although specific guidelines on their use in HIT treatment—an underdiagnosed complication of heparin treatment—are still unavailable.

Video 1. 1 and 2 saddle thrombus in TP, 3 - RA thrombus; 4, 5 and 6 lysis of the saddle thrombus, and RA thrombus after 10 days therapy; 7–10 lysis and decreased subocclusive thrombi in principal branches of PA and re-shaped RV after 1 month therapy.

References

- Cohen RA, Castellano M, Garcias CA. Heparin induced thrombocytopenia: case presentation and review. *J Clin Med Res* 2012; 4: 68-72.
- Rauova L, Poncz M, McKenzie SE, Reilly MP, Arepally G, Weisel JW, et al. Ultralarge complexes of PF4 and heparin are central to the pathogenesis of heparin-induced thrombocytopenia. *Blood* 2005; 105: 131-8.
- Franchini M. Heparin-induced thrombocytopenia: an update. *Thromb J* 2005; 3: 14.
- Walenga JM, Prechel M, Jeske WP, Hoppensteadt D, Maddineni J, Iqbal O, et al. Rivaroxaban – an oral, direct Factor Xa inhibitor – has potential for the management of patients with heparin-induced thrombocytopenia. *Br J Haematol* 2008; 143: 92-9.
- Lo GK, Juhl D, Warkentin TE, Sigouin CS, Eichler P, Greinacher A. Evaluation of pretest clinical score (4 T's) for the diagnosis of heparin-induced thrombocytopenia in two clinical settings. *J Thromb Haemost* 2006; 4: 759-65.
- Linkins LA, Dans AL, Moores LK, Bona R, Davidson BL, Schulman S, et al. American College of Chest Physicians. Treatment and prevention of heparin-induced thrombocytopenia: antithrombotic therapy and prevention of thrombosis, 9th ed: American College of Chest Physicians evidence-based clinical practice guidelines. *Chest* 2012; 2 Suppl: e495S-530S.
- Depasse F, Busson J, Mnich J, Le Flem L, Gerotziafas GT, Samama MM. Effect of BAY 59-7939—a novel, oral, direct Factor Xa inhibitor—on clot-bound Factor Xa activity in vitro. *J Thromb Haemost* 2005; 3: P1104. 29.

8. Linkins LA, Warkentin TE, Pai M, Shivakumar S, Manji RA, Wells PS. Rivaroxaban for treatment of suspected or confirmed heparin-induced thrombocytopenia study. *J Thromb Haemost* 2016; 14: 1206-10.

Address for Correspondence: Prof. Marija Vavlukis, MD, PhD, FESC

University Clinic of Cardiology, Medical Faculty,
University Ss Cyril and Methodius,
St. Mother Theresa nr 17, 1000,
Skopje-Republic of Macedonia



Phone: +38972231131 Fax: +38923113116 E-mail: marija.vavlukis@gmail.com

©Copyright 2016 by Turkish Society of Cardiology - Available online

at www.anatoljcardiol.com

DOI:10.14744/AnatolJCardiol.2017.7805
