

Compound heterozygous mutations in *WFS1* cause atypical Wolfram syndrome

Yun-Di Pan, Jun-Ling Fu, Xin-Hua Xiao

Department of Endocrinology, NHC Key Laboratory of Endocrinology, Peking Union Medical College Hospital, Chinese Academy of Medical Sciences and Peking Union Medical College, Beijing 100730, China.

To the Editor: Wolfram syndrome (WS, MIM 222300) is a rare autosomal recessive disorder caused by mutations in *WFS1* or *CISD2* (*WFS2*). Its prevalence is estimated to be one in 160,000 to 770,000.^[1] Patients usually present with insulin-dependent diabetes mellitus (DM) at around 6 years old and then with optic atrophy (OA) at around 11 years old. Other symptoms, such as diabetes insipidus, sensorineural deafness, urinary tract abnormalities, and neuropsychiatric disorders, occur at older ages and affect a fraction of individuals. The expected age at death is approximately 30 to 40 years, mostly caused by respiratory failure. WS is inherited in an autosomal recessive manner, while some pathogenic mutations in the *WFS1* gene are dominant, are associated with hearing impairment, OA, DM, and psychiatric problems, and cause Wolfram-like syndrome.^[2] In the present report, we describe a case of *WFS1*-related spectrum disorder onset with non-insulin-dependent DM and OA in a Chinese patient. This patient had compound heterozygous mutations in the *WFS1* gene, and a novel nonsense mutation, c.2217C>A, was found.

A 19-year-old man was referred to our department with a 5-month history of DM and a 7-year history of progressive visual loss. Five months earlier, the patient presented to the local hospital with polydipsia, polyphagia, and polyuria and weight decreasing from 58 (1 year earlier) to 52 kg. His height was 173 cm. Fasting serum glucose was 14.4 mmol/L, and anti-glutamic acid decarboxylase, anti-islet cell antibodies, and anti-insulin autoantibodies were negative. He was diagnosed with type 2 DM and was treated with intensive insulin therapy (multiple daily insulin injections) for 1 month. Then, his therapy gradually changed to acarbose and 2 U recombinant insulin glargine at bedtime. Those symptoms resolved once the therapy was initiated. He came to our department for counseling on future management. W-

e conducted a 2 h oral glucose tolerance test with a standard meal. His serum glucose, insulin, and C-peptide were 5.2 mmol/L, 2.95 μ IU/mL (normal range: 5.2–17.2 μ IU/mL), and 0.57 ng/mL (normal range: 0.8–4.2 ng/mL) at 0 h and were 3.2 mmol/L, 13.77 μ IU/mL, and 2.68 ng/mL at 2 h, respectively. Hemoglobin A1c (HbA1c) was 5.7% and C-reactive protein was 0.19 mg/L. Urine albumin was negative. The patient has no siblings. His parents are non-consanguineous and have no signs or symptoms. His grandmother on his father's side was diagnosed with type 2 DM at 62 years of age.

The patient was young and not obese. Suspecting that he had genetic diabetes such as maturity-onset diabetes of the young or recessive genetic syndromes, we performed whole-exome sequencing and patient consent forms were obtained. No diabetes-associated genetic defects were detected except for compound heterozygous mutations in the *WFS1* gene. Sanger sequencing confirmed that the patient inherited a missense variant, c.1673G>A, from his father and a nonsense variant, c.2217C>A, from his mother [Figure 1]. Both parents carry one mutated allele and do not have hearing impairment, OA, or DM. Given the genetic testing results, we suggested that the patient receive optic nerve and hearing tests. His visual acuity was normal before 11 years of age and gradually decreased to 20/40 and 20/50 in each eye. Brain magnetic resonance imaging showed bilateral optic nerve atrophy. Audiometry demonstrated normal hearing. No signs of urological abnormalities or psychiatric disorders were observed. DM, OA and gene mutations confirmed the diagnosis of *WFS1*-related spectrum disorder.

WS is a rare, neurodegenerative, progressive, autosomal recessive disease, and the diagnosis requires the coincidence of insulin-dependent DM and bilateral OA before the second decade.^[1] Though the patient presented here

Access this article online

Quick Response Code:



Website:
www.cmj.org

DOI:
10.1097/CM9.0000000000000464

Correspondence to: Dr. Xin-Hua Xiao, Department of Endocrinology, NHC Key Laboratory of Endocrinology, Peking Union Medical College Hospital, Chinese Academy of Medical Sciences and Peking Union Medical College, Beijing 100730, China
E-Mail: xiaoxh2014@vip.163.com

Copyright © 2019 The Chinese Medical Association, produced by Wolters Kluwer, Inc. under the CC-BY-NC-ND license. This is an open access article distributed under the terms of the Creative Commons Attribution-Non Commercial-No Derivatives License 4.0 (CCBY-NC-ND), where it is permissible to download and share the work provided it is properly cited. The work cannot be changed in any way or used commercially without permission from the journal.

Chinese Medical Journal 2019;132(20)

Received: 22-05-2019 Edited by: Li-Shao Guo

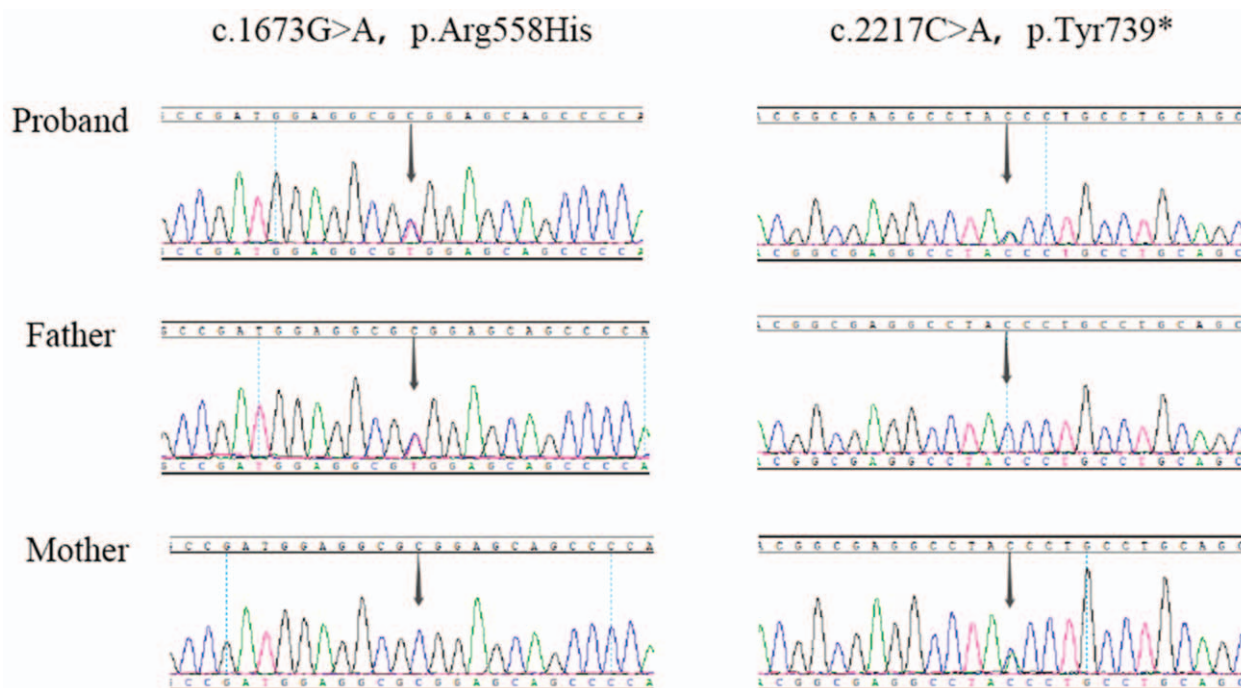


Figure 1: Sequencing of exon 8 of *WFS1* (NM_006005.3). The patient inherited a missense variant c.1673G>A (p. Arg558His) from his father and a nonsense variant c.2217C>A (p. Tyr739*) from his mother.

was confirmed to have bilateral OA, his non-insulin-dependent DM is atypical for WS. The application of next-generation sequencing technology allowed rapid diagnosis and appropriate evaluations.

Genetic analyses have identified more than 300 pathogenic variants in *WFS1*, and the severity of the disease varies with the mutation type. Efforts have been put into establishing genotype-phenotype correlation for better diagnosis and management.^[3] Our patient's c.1673G>A mutation causes a substitution of arginine at residue 558 for histidine, and the c.2217C>A mutation generates p.Y739X, which has never been reported. A brother and sister with the same p.R558C mutation in compound heterozygosity with a p.E864X nonsense mutation were reported to have DM and OA in their teens without any signs of other problems.^[4] According to the genetic test results, our patient is likely to have a mild form of WS.

What is special about this patient is that his DM was diagnosed at an early stage and he had not progressed to insulin-dependent DM with good control of serum glucose. Certain dominant *WFS1* mutations have been discovered to cause type 2 DM due to relative insulin insufficiency, but recessive mutations are almost always considered to cause insulin-dependent DM.^[2,5] The patient's parents do not have DM, visual loss, or hearing problems. He maintained glucose control with diet and exercise and without medication for the next 3 months, and his HbA1c was 6.4% at the last follow-up. The prognosis of this patient remains to be further studied. This case can broaden our knowledge about *WFS1* gene function in DM and its genotype-phenotype correlation.

Declaration of patient consent

The author certifies that they have obtained all appropriate patient consent forms. In the form, the patient has given his consent for his images and other clinical information to be reported in the journal. The patient understands that his name and initials will not be published and due efforts will be made to conceal their identity, but anonymity cannot be guaranteed.

Conflicts of interest

None.

References

1. Urano F. Wolfram syndrome: diagnosis, management, and treatment. *Curr Diab Rep* 2016;16:6. doi: 10.1007/s11892-015-0702-6.
2. Tranebjaerg L, Barrett T, Rendtorff ND. *WFS1-Related Disorders*. 2009 Feb 24 [Updated 2013 Dec 19]. In: Gene Reviews (R). Seattle (WA): University of Washington, Seattle; 1993–2019. Available from: <https://www.ncbi.nlm.nih.gov/books/NBK4144/>. [Last accessed on 2019 May 20].
3. de Heredia ML, Clères R, Nunes V. Genotypic classification of patients with Wolfram syndrome: insights into the natural history of the disease and correlation with phenotype. *Genet Med* 2013;15:497–506. doi: 10.1038/gim.2012.180.
4. Smith CJ, Crock PA, King BR, Meldrum CJ, Scott RJ. Phenotype-genotype correlations in a series of Wolfram syndrome families. *Diabetes Care* 2004;27:2003–2009. doi: 10.2337/diacare.27.8.2003.
5. Bonnycastle LL, Chines PS, Hara T, Huyghe JR, Swift AJ, Heikinheimo P, et al. Autosomal dominant diabetes arising from a Wolfram syndrome 1 mutation. *Diabetes* 2013;62:3943–3950. doi: 10.2337/db13-0571.

How to cite this article: Pan YD, Fu JL, Xiao XH. Compound heterozygous mutations in *WFS1* cause atypical Wolfram syndrome. *Chin Med J* 2019;132:2508–2509. doi: 10.1097/CM9.0000000000000464