



Image-Guided Percutaneous Management of Skull and Spine Giant Cell Tumors: Case Report of 2 Challenging Cases Successfully Treated with Doxycycline Sclerotherapy

Megan N. Wong¹, Kathleen Nicol², James W. Murakami¹

Key words

- Doxycycline
- Giant cell tumor
- Sclerotherapy

Abbreviations and Acronyms

ABC: Aneurysmal bone cyst
CT: Computed tomography
GCT: Giant cell tumor
IR: Interventional radiology
MRI: Magnetic resonance imaging

From the Departments of ¹Radiology and ²Pathology, Nationwide Children's Hospital, Columbus, Ohio, USA

To whom correspondence should be addressed:

James W. Murakami, M.D.

[E-mail: James.Murakami@nationwidechildrens.org]

Citation: *World Neurosurg.* X (2020) 5:100061.

<https://doi.org/10.1016/j.wnsx.2019.100061>

Journal homepage: www.journals.elsevier.com/world-neurosurgery-x

Available online: www.sciencedirect.com

2590-1397/© 2019 The Author(s). Published by Elsevier Inc.

This is an open access article under the CC BY-NC-ND license (<http://creativecommons.org/licenses/by-nc-nd/4.0/>).

INTRODUCTION

A giant cell tumor (GCT) of bone is an osteolytic lesion made up of mononuclear stromal cells and multinucleated giant cells that typically affect younger adults. GCTs constitute 5% of all primary bone tumors. Approximately 85% of GCTs occur in the metaphyseal region of long bones, especially in the distal femur, proximal tibia, and distal radius.^{1,2} GCTs present in the axial skeleton, such as the skull and spine, in approximately 10% of cases. Whereas most GCTs are locally aggressive, a few show pulmonary metastases, and even fewer show malignant transformation.²

Various treatments have been developed to address the challenge posed by the propensity for GCTs to recur.² The applicability and effectiveness of each option is often limited by the location of the tumor, given that the goal of complete resection needs to be balanced with minimizing damage to adjacent

■ **BACKGROUND:** A giant cell tumor (GCT) of bone is a benign, locally aggressive tumor that is often challenging to treat. When complete resection is not possible, curettage with or without adjuvants is the most common treatment. The high frequency of local recurrence and risk of injury to adjacent structures can limit this surgical approach, especially with skull and spine lesions.

■ **CASE DESCRIPTION:** We report 2 cases of axial skeleton GCTs, 1 in the skull of a 58-year-old woman in whom operative management failed, who experienced local recurrence, and 1 in the cervical spine of an 8-year-old girl that grew extracompartmentally to surround her brachial plexus. Both patients were referred to us because of the surgically challenging nature of their tumors. After completion of the same percutaneous doxycycline sclerotherapy protocol previously described for aneurysmal bone cysts (ABCs), both patients were considered cured and were able to return to normal activities without loss of pretreatment function. After 4 and 10 years of follow-up, respectively, there has been no tumor recurrence in either patient.

■ **CONCLUSIONS:** We successfully treated 2 patients with very challenging axial skeleton GCTs using a percutaneous doxycycline sclerotherapy protocol previously shown to have success with ABCs. We believe that this minimally invasive procedure should be considered a potential alternative treatment for GCTs, especially axial skeleton lesions, which may not be easily approached with standard surgical techniques.

structures and maintaining function. Although adjuvants have been used to enhance existing surgical treatments, en bloc resection remains the best surgical option for complete cure.^{3,4} Skull and spine GCTs highlight these treatment selection dilemmas because they are commonly very difficult or impossible to completely resect without morbidity.⁵ Denosumab was approved by the U.S. Food and Drug Administration for use in the treatment of these surgically challenging GCTs in 2013.⁶ Since that time it has been tried as a salvage treatment or a neoadjuvant preoperative measure, but recent reviews indicate that it usually results in only partial response and can in fact increase the risk of postoperative recurrence after later curettage.⁷⁻⁹

A recent report by Shiels and Mayer-son¹⁰ introduced doxycycline sclerotherapy as an alternative to surgical

resection in definitive curative treatment of ABCs, which are histopathologically very similar to GCTs. Both of these tumors comprise locally destructive osteoclast-like giant cells coupled with unique mononuclear stromal cells that are osteoblast-like in GCTs and fibroblast-like in ABCs.^{11,12} Doxycycline is a locally toxic agent when used as a sclerosant but also promotes osteoblast function and inhibits angiogenesis and osteoclast function, all aiding in the healing of bone lesions.^{10,13,14} We posited that doxycycline sclerotherapy would be analogously definitively effective in treating GCTs, and we now report the treatment of 2 challenging neurosurgical cases using this technique. We wish to report the definitive success of doxycycline sclerotherapy in treating these 2 GCTs, 1 in the skull and 1 in the cervical spine, with 4 and 10 years, respectively, of disease-free follow-up.

CASE DESCRIPTIONS

Patient 1

A 58-year-old woman was referred to our institution in May 2014 for percutaneous treatment of a recurrent right sphenoid wing lytic bone tumor (Figure 1). In January 2011, 3 years before coming to us, she had undergone partial tumor resection at another major medical center. The presumptive clinical, radiologic, and pathologic diagnosis was GCT versus solid ABC. Postoperatively the residual tumor gradually increased in size, and the patient experienced progressive debilitating daily pain.

Because she was deemed ineligible for more surgery, she was referred to the interventional radiology (IR) service for percutaneous doxycycline injections, which is our routine management of pediatric ABCs. During her first treatment, in August 2014, multiple core biopsy specimens were obtained, and they were interpreted as GCT (Figure 2).

The lesion was accessed under computed tomography (CT) guidance with 2 14G Bonopty bone biopsy needles (AprioMed, Uppsala, Sweden). One of the access points was through the roof of the

temporomandibular joint, and the second was through a tumor-related dehiscence in the temporal bone (Figure 3A). After the core biopsy specimens were obtained, doxycycline was injected under CT guidance. Using the technique previously described by Shiels and Mayerson,¹⁰ doxycycline was mixed with 25% human serum albumin (Grifols Therapeutics, Clayton, North Carolina, USA) and then agitated with an equal volume of air to generate a stable foam with a final doxycycline concentration of 10 mg/mL. The doxycycline foam is extremely easy to visualize by CT because its density is air, so no additional radiographic contrast material is needed (Figure 3B). Care was taken to use a double-needle injection technique to allow pressure to release out the second needle during injection of the first, rather than build within the tumor and extravasate to surrounding tissue.¹⁵ To prevent back bleeding after needle removal, Surgifoam pledgets (Ethicon, Somerville, New Jersey, USA) were pushed through the needles as they were withdrawn. The procedure was performed on an outpatient basis, and the patient had no significant pain postoperatively.

CT-guided percutaneous needle access and doxycycline injection were performed 2 additional times by a similar technique, in October 2014 and May 2015, without complication. During that time, her pain resolved, and her CT scans showed progressive ossification of the lesion. No other interventions or medications were used. Routine yearly imaging has been performed, and her most recent scan, in May 2019, 4 years after the last procedure, showed no recurrence (Figure 4). At that last follow-up visit, she remained symptom free.

Patient 2

An 8-year-old girl was brought to our institution in April 2008 with a 6-month history of progressive neck pain and right arm weakness and numbness. Magnetic resonance imaging (MRI) and CT showed an 8-cm-diameter mixed cystic and solid C7 mass causing vertebra plana and collapse of the right C7 articular pillar. The tumor replaced the right pedicle, lamina, and spinous process at C7, with extraosseous extension into the soft tissues around the right brachial plexus and into the superior sulcus of the right hemithorax (Figure 5). She was referred to

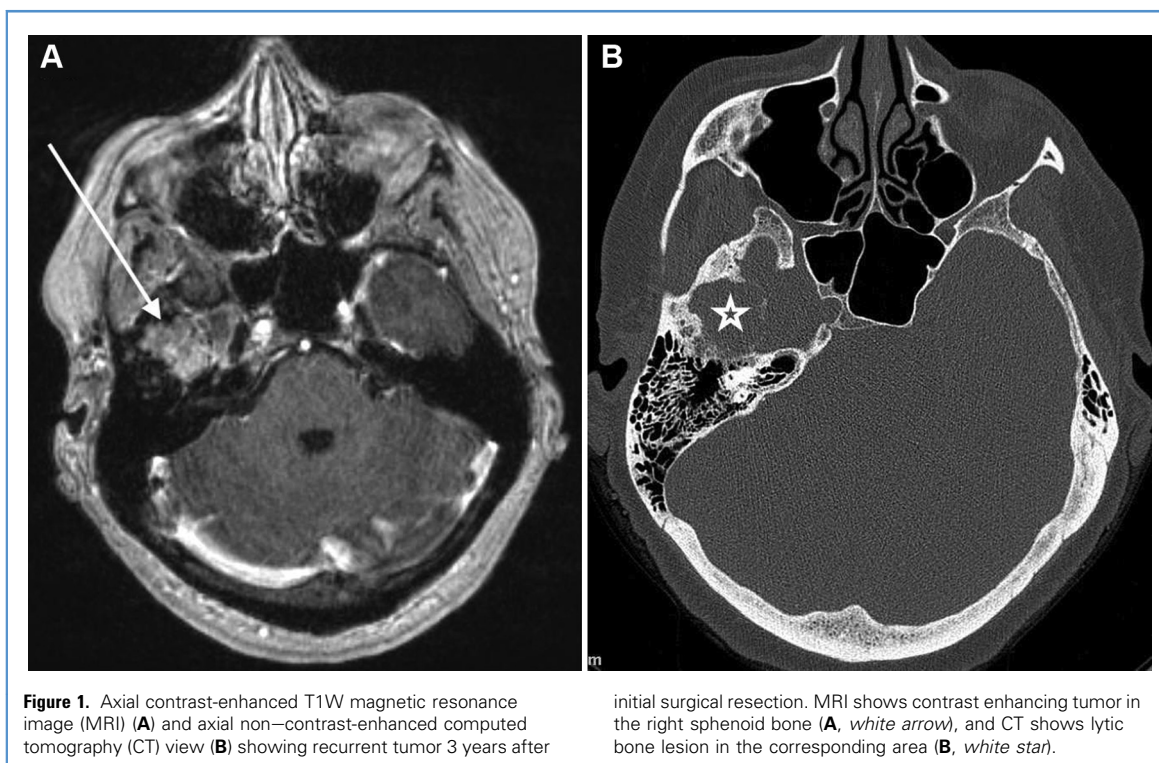


Figure 1. Axial contrast-enhanced T1W magnetic resonance image (MRI) (A) and axial non-contrast-enhanced computed tomography (CT) view (B) showing recurrent tumor 3 years after

initial surgical resection. MRI shows contrast enhancing tumor in the right sphenoid bone (A, white arrow), and CT shows lytic bone lesion in the corresponding area (B, white star).

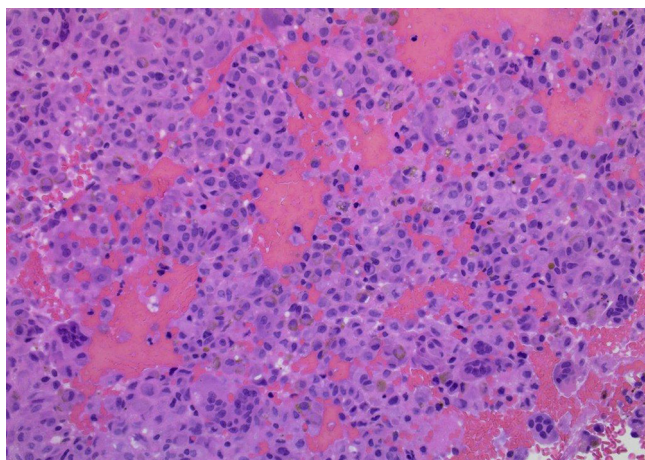


Figure 2. Histologic view showing several multinucleated osteoclast-like giant cells within a stroma composed of sheets of mononuclear cells and scattered pigmented macrophages (hematoxylin and eosin, $\times 40$).

IR for percutaneous sclerotherapy because her case was deemed surgically challenging, with a significant risk of permanent loss of arm function.

Analysis of a percutaneous biopsy specimen taken during the first ultrasound and fluoroscopic-guided treatment in May 2008 identified the mass as a GCT with some areas of associated ABC (Figure 6A). A total of 10 percutaneous treatments were performed over the next 16 months, with

the early procedures done under ultrasound and fluoroscopic guidance, and the later procedures done under CT guidance (Figure 6B). In all treatments, independent of the modality used for image guidance, doxycycline foam was injected throughout the tumor without complication. During the course of treatment, the tumor melted away, and most of the pain and the brachial plexopathy resolved, allowing her to

return to normal activities. She has been monitored by the IR and neurosurgery services with yearly imaging and clinical follow-up for over 10 years, primarily because of persistent reports of occasional neck pain and arm paresthesia. Her last follow-up MRI, in January 2019, showed no evidence of residual or recurrent tumor and solid osseous fusion of the right C6/C7 and C7/T1 facets across the collapsed C7 articular pillar (Figure 7). Her neurosurgeons have found no compelling reasons for any operative intervention.

DISCUSSION

GCTs are benign, locally aggressive tumors with a great propensity for post-operative local recurrence. They consist of mononuclear stromal cells, multinucleated giant cells, and hemosiderin-laden macrophages.^{1,2} Diagnosis of a GCT relies on both histopathologic and radiologic evidence. Location of the lesion and age of the patient help to narrow the differential diagnosis. Other bone lesions, like ABCs, have similar histopathologic characteristics with osteolytic components that can make definitive diagnosis of a GCT more challenging.¹⁶

Different treatment options for GCTs exist, but these tumors remain difficult to

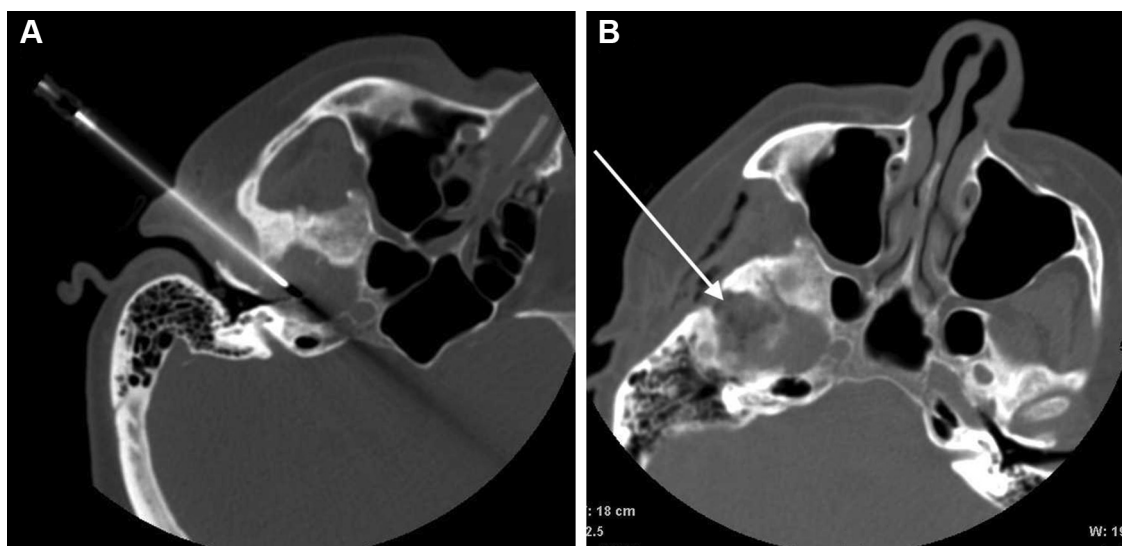


Figure 3. Percutaneous computed tomography (CT)-guided needle biopsy and doxycycline foam sclerotherapy. Biopsy performed with 14G guiding needle placed through the roof of the tempomandibular joint (A). Injected doxycycline foam has air

density (black on CT), making it very easy to see percolating throughout the lesion (B, white arrow). Some of the injected foam has leaked out into the overlying temporalis muscle with no clinical consequence (B).

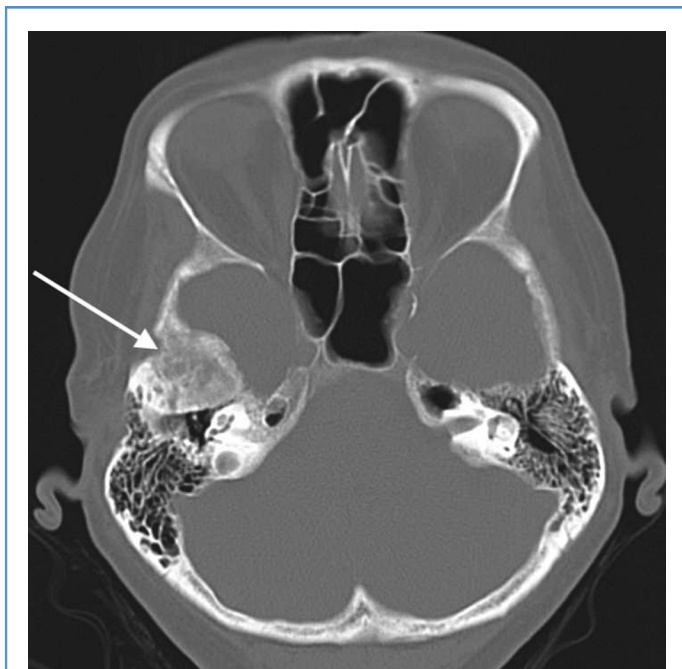

Figure 4. Four years after the last of 3 treatments, noncontrast computed tomography (CT) view showing complete osseous fill-in of the lytic lesion (white arrow).

definitively cure. Surgical intervention is currently the best option.^{3,4} Complete resection has the lowest recurrence rate

(0% to 12%) but is often not possible without causing loss of function, especially in tumors of the axial

skeleton.^{3,17} Curettage is the most common surgical approach when complete resection is not possible, but its high recurrence rate (12% to 34%) diminishes its complete success as a curative treatment.^{4,17} Embolization, radiotherapy, and denosumab are used as adjuvants to bolster the effectiveness of curettage. However, some studies have shown that these adjuvants, although they possibly facilitate more effective or safe surgery, have limited influence on decreasing the recurrence rate.^{9,18} Recent studies report that neoadjuvant treatment with denosumab actually increases the risk of recurrence after surgery, making its use for this indication problematic.^{8,9}

Whereas GCTs typically occur in the metaepiphyseal region of long bones in adults aged 30 to 50 years, ABCs commonly manifest in the juxtaphyseal region of bones in children.^{1,2,10} Despite the differing clinical presentations, GCTs and ABCs demonstrate similar pathogenesis and histologic characteristics, manifesting similar radiologic appearances.^{2,12} One main difference between these lesions lies in the identity of their mononuclear stromal cells, with GCT stromal cells resembling osteoblasts and ABC stromal cells

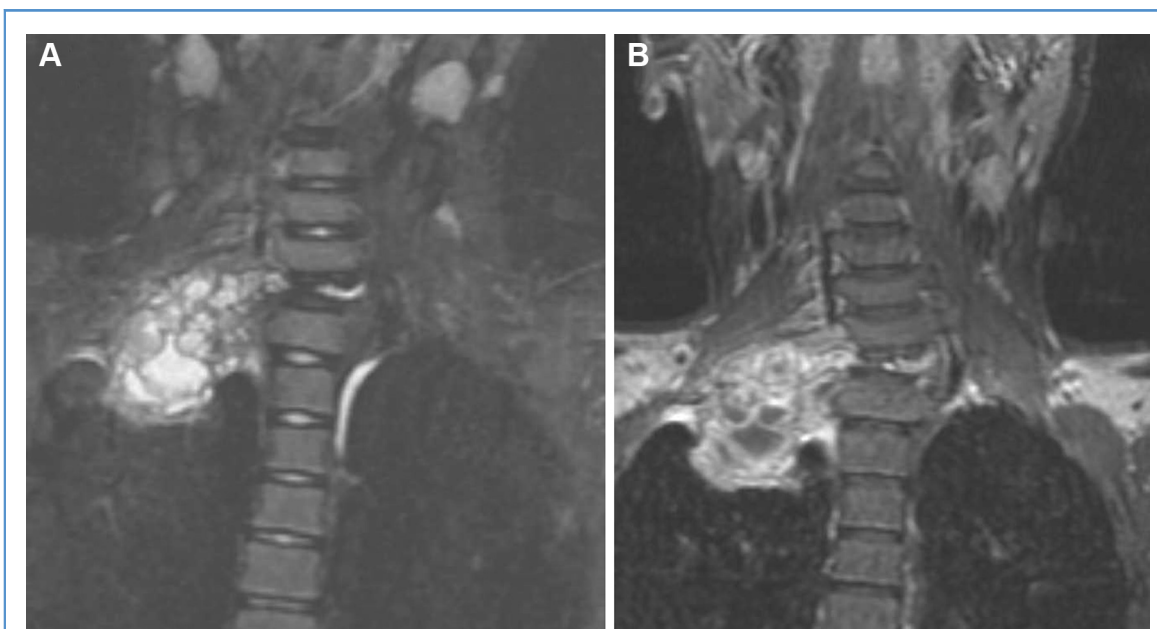


Figure 5. Pretreatment coronal short-TI inversion recovery magnetic resonance image (MRI) (A) and contrast-enhanced coronal T1W MRI (B) showing large predominantly solid mass

with scattered small internal cysts arising from the collapsed C7 vertebral body and right pedicle and growing extracompartmentally to surround the right brachial plexus.

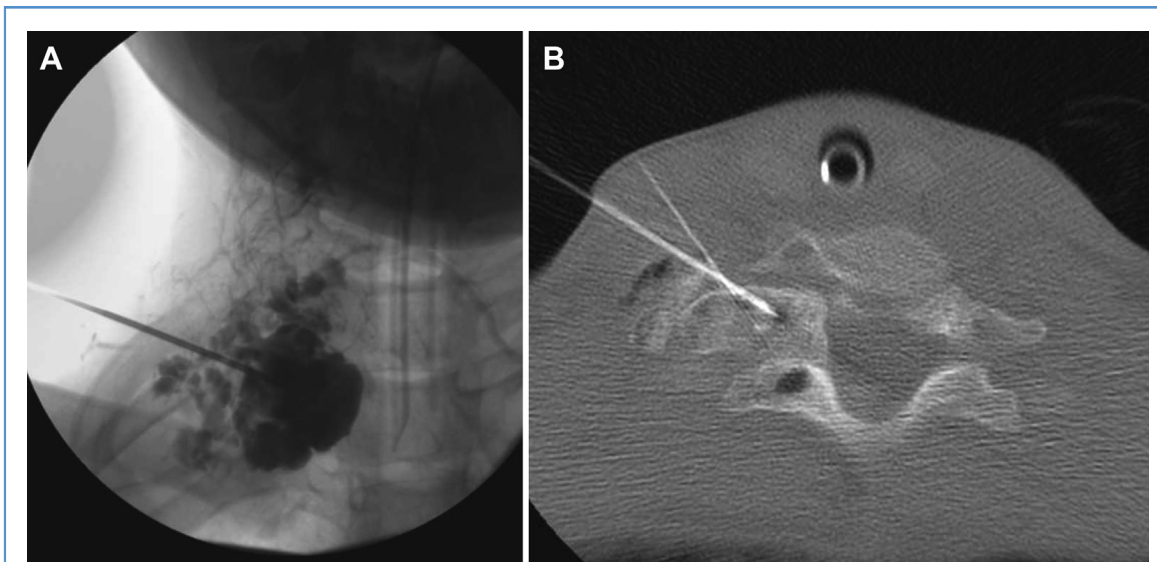


Figure 6. Percutaneous sclerotherapy performed initially with fluoroscopic (A) and ultrasound guidance and later with computed tomography (CT) guidance (B). During initial treatment (A), a biopsy was performed, and sclerotherapy was performed with doxycycline foam after initial contrast injections to

demarcate the cystic areas and ultrasound to see the solid areas of the tumor. During the final treatment (B), doxycycline foam was injected into the remaining osseous remnants of the tumor with the air density of the foam making it easily visible by CT.

resembling fibroblasts.¹² However, factors essential to osteoclastogenesis, such as vascular endothelial growth factor and

receptor-activator of nuclear κ B ligand, are found in both types of stromal cells, where they retain comparable osteoclast-

stimulating functions.^{12,19} The analogous functions of the stromal cells in ABCs and GCTs suggest that the osteolytic behavior of both tumors may be regulated by similar cellular mechanisms.¹²

Shiels and Mayerson¹⁰ and Shiels et al.²⁰ successfully treated ABCs using percutaneous doxycycline sclerotherapy with a low recurrence rate (6%). Clinical cure was achieved in their patients with long-term follow-up and without the need of surgical resection or orthopedic fixation. The shared osteoclast-stimulating factors in ABC and GCT stromal cells suggests that doxycycline sclerotherapy, which successfully treated ABCs, could similarly be applied to definitively treat GCTs.¹⁹⁻²² We have demonstrated in these 2 axial skeleton GCT cases that definitive treatment is indeed possible with disease-free, long-term follow-up.

Clinically and radiologically, our 2 patients with GCT showed healing similar to that previously reported for patients with ABC.^{10,20} Long-term follow-up imaging showed continued ossification of our 2 lesions, with no residual areas of cystic or active disease observed. Patient 1 was successfully treated for a surgically inaccessible skull GCT, and patient 2 was cured of a cervical spine GCT without

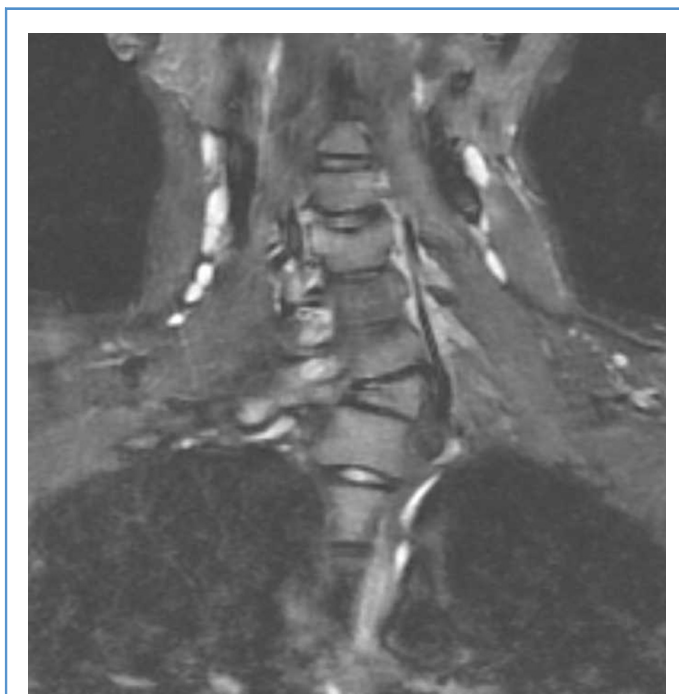

Figure 7. Coronal short-T1 inversion recovery magnetic resonance image (MRI) 10 years after the last treatment showing no residual tumor, cystic or solid. The right facets at C6/C7 and C7/T1 have fused.

need for resection or spine fusion. More importantly, both patients maintained their preoperative functionality after treatment.

This report describes the success of doxycycline sclerotherapy in the treatment of 2 different axial skeleton GCTs. Although a larger study with more patients is required to confirm our findings and to elucidate any limitations of this treatment, we wish to present this percutaneous technique as a new option for treating GCTs. We particularly recommend consideration of this minimally invasive treatment for patients with GCTs for whom standard surgical approaches may be overly risky or nearly impossible.

DECLARATION OF COMPETING INTEREST

The authors declare that the article content was composed in the absence of any commercial or financial relationships that could be construed as a potential conflict of interest.

ACKNOWLEDGMENT

Dr. W. E. Shiels, II, served as the primary investigator for most of the life of this research study. He was integral to developing the experimental design and acquiring data. Unfortunately, he passed away before the writing of the manuscript for this article.

REFERENCES

- Chakarun CJ, Forrester DM, Gottsegen CJ, Patel DB, White EA, Matcuk GR Jr. Giant cell tumor of bone: review, mimics, and new developments in treatment. *Radiographics*. 2013;33:197-211.
- van der Heijden L, Dijkstra S, van de Sande MA, et al. The clinical approach toward giant cell tumor of bone. *Oncologist*. 2014;19:550-561.
- Errani C, Ruggieri P, Asenzio MA, et al. Giant cell tumor of the extremity: a review of 349 cases from a single institution. *Cancer Treat Rev*. 2010;36:1-7.
- Klenke FM, Wenger DE, Inwards CY, Rose PS, Sim FH. Recurrent giant cell tumor of long bones: analysis of surgical management. *Clin Orthop Relat Res*. 2011;469:1181-1187.
- Yu X, Xu M, Xu S, Fu Z. Long-term outcome of giant cell tumor of bone involving sacroiliac joint treated with selective arterial embolization and curettage: a case report and literature review. *World J Surg Oncol*. 2013;11:72.
- Singh AS, Chawla NS, Chawla SP. Giant-cell tumor of bone: treatment options and the role of denosumab. *Biologics*. 2015;9:69-74.
- Charest-Morin R, Boriani S, Fisher CG, et al. Benign tumors of the spine: has new chemotherapy and interventional radiology changed the treatment paradigm? *Spine*. 2016;41:S178-S185.
- Chinder PS, Hindiskere S, Doddarangappa S, Pal U. Evaluation of local recurrence in giant-cell tumor of bone treated by neoadjuvant denosumab. *Clin Orthop Surg*. 2019;11:352-360.
- Errani C, Tsukamoto S, Leone G, et al. Denosumab may increase the risk of local recurrence in patients with giant-cell tumor of bone treated with curettage. *J Bone Joint Surg Am*. 2018;100:496-504.
- Shiels WE II, Mayerson JL. Percutaneous doxycycline treatment of aneurysmal bone cysts with low recurrence rate: a preliminary report. *Clin Orthop Relat Res*. 2013;471:2675-2683.
- Thomas DM, Skubitz KM. Giant cell tumour of bone. *Curr Opin Oncol*. 2009;21:338-344.
- Pelle DW, Ringler JW, Peacock JD, et al. Targeting receptor-activator of nuclear kappaB ligand in aneurysmal bone cysts: verification of target and therapeutic response. *Transl Res*. 2014;164:139-148.
- Zehtabi F, Ispas-Szabo P, Djerir D, et al. Chitosan-doxycycline hydrogel: an MMP inhibitor/sclerosing embolizing agent as a new approach to endoleak prevention and treatment after endovascular aneurysm repair. *Acta Biomater*. 2017;64:94-105.
- Gomes KDN, Alves APNN, Dutra PGP, Viana GSB. Doxycycline induces bone repair and changes in Wnt signalling. *Int J Oral Sci*. 2017;9:158-166.
- Puig S, Aref H, Brunelle F. Double-needle sclerotherapy of lymphangiomas and venous angiomas in children: a simple technique to prevent complications. *AJR Am J Roentgenol*. 2003;180:1399-1401.
- Werner M. Giant cell tumour of bone: morphological, biological and histogenetical aspects. *Int Orthop*. 2006;30:484-489.
- van der Heijden L, Dijkstra PD, Campanacci DA, Gibbons CL, van de Sande MA. Giant cell tumor with pathologic fracture: should we curette or resect? *Clin Orthop Relat Res*. 2013;471:820-829.
- Ruggieri P, Mavrogenis A, Ussia G, et al. Recurrence after and complications associated with adjuvant treatments for sacral giant cell tumor. *Clin Orthop Relat Res*. 2010;468:2954-2961.
- Kumta SM, Huang L, Cheng YY, et al. Expression of VEGF and MMP-9 in giant cell tumor of bone and other osteolytic lesions. *Life Sci*. 2003;73:1427-1436.
- Shiels WE II, Beebe AC, Mayerson JL. Percutaneous doxycycline treatment of juxtaphyseal aneurysmal bone cysts. *J Pediatr Orthop*. 2016;36:205-212.
- Lee CZ, Xu B, Hashimoto T, et al. Doxycycline suppresses cerebral matrix metalloproteinase-9 and angiogenesis induced by focal hyperstimulation of vascular endothelial growth factor in a mouse model. *Stroke*. 2004;35:1715-1719.
- Naghsh N, Razavi SM, Minaiyan M, et al. Evaluation of the effects of two different bone resorption inhibitors on osteoclast numbers and activity: an animal study. *Dent Res J*. 2016;13:500-507.

Received 17 September 2019; accepted 18 September 2019

Citation: *World Neurosurg*. X (2020) 5:100061.

<https://doi.org/10.1016/j.wnsx.2019.100061>

Journal homepage: www.journals.elsevier.com/world-neurosurgery-x

Available online: www.sciencedirect.com

2590-1397/© 2019 The Author(s). Published by Elsevier Inc.

This is an open access article under the CC BY-NC-ND

license (<http://creativecommons.org/licenses/by-nc-nd/4.0/>).