

Directly ventricular septal defect closure without using arteriovenous wire loop: Our adult case series using transarterial retrograde approach

Nihat Pekel, Ertuğrul Ercan, Mehmet Emre Özpelit, Ferhat Özyurtlu¹, Akar Yılmaz, Caner Topaloğlu, Serkan Saygi, Serkan Yakan², İstemihan Tengiz

Department of Cardiology, İzmir Medicalpark Hospital; İzmir-Turkey

¹Department of Cardiology, Private Grandmedical Hospital; Manisa-Turkey

²Department of Cardiology, Private Kardiya Cardiology Branch Center; İzmir-Turkey

ABSTRACT

Objective: The standard transcatheter ventricular septal defects (VSD) closure procedure is established with arteriovenous (AV) loop and is called as antegrade approach. The directly retrograde transarterial VSD closure without using AV loop might be better option as shortens the procedure time and decreases radiation exposure.

Methods: Our series consist of twelve sequential adult cases with congenital VSDs (seven with perimembranous, four with muscular, one with postoperative residual VSD). The mean age was 26.9 (Range 18–58), the mean height was 168.75 cm (Range 155–185cm), and the mean body mass index was 23.4 (Range 17.3–28.4). Maximum and minimum defect sizes were 10 and 5 mm and the mean defect size was 6.24 mm. The procedure was performed with left heart catheterization and advancing the delivery sheath over the stiff exchange wire then VSD occlusion from left side.

Results: The defects were successfully closed with this technique in eleven patients. In sixth patient, the defect could not be cannulated by the delivery sheath, as the tip of the sheath did not reach the defect and VSD was closed with same sheath by standard transvenous approach using AV loop. We didn't encounter any complication related to semilunar or atrioventricular valves. Atrioventricular conduction system was not affected by the procedure in any patients. The median procedure and fluoroscopy times were 66 and 16.5 minutes respectively.

Conclusion: Transarterial retrograde VSD closure without using AV loop simplifies the procedure, decreases the radiation exposure, and shortens the procedure time. The only limitation in adult patients is delivery sheath length. (*Anatol J Cardiol* 2017; 17: 461-8)

Keywords: ventricular septal defects, catheterization closure devices

Introduction

The transtercatheter closure of VSD has become a widespread procedure with the introduction of Amplatzer VSD occlusion devices (St. Jude Medical, St. Paul, Minnesota) in the 2000s (1); after these years this procedure has been adopted as an alternative to surgery in many centers. Amplatzer occluders are the most commonly used closure devices; however, occluder devices manufactured under other brands have also been used with high success rates in large series of patients (2–4). In most centers, the procedure is performed using antegrade method and transvenous approach by creating an arteriovenous guide wire loop (5, 6). Some reports have described retrograde placement of the device from arterial route in cases where venous closure cannot be performed due to technical difficulties (7–9).

Recently, Amplatzer muscular occluder device (10, 11) and Amplatzer Ductal Occluder 2 (ADO II) (12) device have been implanted successfully using the retrograde technique, without creating an arteriovenous guide wire loop in adolescents and children with congenital VSD. Also there are few adult case reports whose defects was closed successfully with retrograde technique (13–15). Compared to conventional methods, this technique involves fewer steps and possesses the potential to significantly reduce fluoroscopy and total procedure time. Case series of VSD closure often involves pediatric cases and there are a few case series specifically involving adult cases with VSD (16–18). The present study evaluated the feasibility of transcatheter retrograde transarterial directly closure of VSD in adult cases with congenital VSD and appraised procedure time, fluoroscopy time, and patient outcomes.

Address for correspondence: Dr. Ertuğrul Ercan, İzmir Medicalpark Hastanesi Kardiyoloji Bölümü
Yeni Girne Bvl. 1825 St. No: 12 Karşıyaka, İzmir-Türkiye
Phone: +90 232 399 50 50 Fax: +90 232 399 50 70 E-mail: ertugrulercan@yahoo.com

Accepted Date: 17.01.2017 **Available Online Date:** 21.02.2017

©Copyright 2017 by Turkish Society of Cardiology - Available online at www.anatoljcardiol.com
DOI:10.14744/AnatolJCardiol.2017.7507



Methods

Study desing and patient population

In our clinic, in percutaneous VSD closure procedures, if the aortic rim is sufficient the procedure is first started with the retrograde approach. This study retrospectively reviewed the percutaneous VSD closure procedures in our clinic between January 2013 and December 2015, which began with retrograde approach to the procedure. The study included 12 consecutive cases with congenital VSD in whom VSD closure was hemodynamically and clinically indicated. Our indications for VSD closure were that the Qp/Qs ratio in the hemodynamic study was greater than 1.5 and that the patient was symptomatic (ie NYHA functional class \geq 2). In perimembranous VSDs; those with aortic rim less than 5 mm and those with significant aortic valve prolapse and significant aortic insufficiency into the defect were excluded. Two patients were excluded from the study because of these anatomical criteria. Pulmoner to systemic flow ratios were obtained from catheterization in four of cases (case 3, 9, 10 and 11) and from echocardiography in others. The mean Qp/Qs was 1.71 (range: 1.5–2.03) and the mean systolic pulmonary arterial pressure (SPAP) was 37.08 mm Hg (range: 25–61 mm Hg). There was a septal aneurysm accompanying the defect in four patients with perimembranous VSD (patient numbers: 2, 3, 7, and 9). In third case pulmonary artery systolic pressure was 61 mm Hg (mean 46 mm Hg). In this case, there weren't any Eisenmenger clinical signs. For these reason we didn't perform pulmonary vasoreactivity test. Defect localization of the patients were that; seven had perimembranous, four had muscular-type (three at the base of the septum, one mid-muscular), and one had postoperative residual VSD. Demographic and clinical characteristics of the cases are summarized in Table 1. This study was approved by the Local Ethics Board.

Periprocedural implementetions

Informed consent was obtained from all patients before the procedure. All procedures were performed under conscious sedation. The principles of ALARA (As Low as Reasonably Achievable) have been followed in all patients, except patient number 12, in order to reduce radiation exposure to the patient and operator. Each procedure was done by same primary operator and two different secondary operator. Primary operator has a long-term cathlab experience and has been exerting special attention on the congenital heart defects and also has sophisticated knowledge in the field of radiation protection. The frame rate was 2 frame/sec in fluoroscopic procedures and 7.5 frame/sec in cine acquisitions. Transesophageal echocardiographic (TEE) guidance was used during the procedure in all patients except patient number 5, who underwent echocardiographic control during the procedure using transthoracic echocardiography (TTE). All patients received intravenous heparin 100 units/kg and intravenous cefazolin 1 gr. All patients were discharged one day after the procedure. The patients were administered prophylaxis with oral antibiotics for two weeks and dual antiplatelet therapy with acetylsalicylic acid 100 mg/day and clopidogrel 75 mg/day for the duration of six months. The patients underwent echocardiography follow-up at one month after the procedure and then once every three mounths.

Description of technique

Firstly, the femoral artery was punctured and a 6 to 8-F arterial sheath was inserted. Then, a ventriculography was performed using a pigtail catheter to clearly visualize the defect located in the left anterior oblique (LAO) position with a cranial angulation. The diameter of VSD and relation with aortic valve were confirmed. VSD diameter was determined using TEE and angiography images (Fig. 1a, b). The defects was passed with an exchangeable 0.035-inch angulated floppy hydrophilic guide wire (Radiofocus, Terumo cooperation, Tokyo, Japan) from the left

Table 1. Demographic features of the cases, anatomic characteristics of the defects, and data of hemodynamic studies

Case no	Age	Gender	Height/Weight BMI, kg/m ²	Defect diameter, mm	Defect type	Aortic rim, mm	Qp/Qs	SPAP, mm Hg
1	24	M	185/80 (23.4)	5	pm	5.6	1.5	29
2	25	M	172/80 (27)	7.6	pm	7.6	2.0	41
3	18	F	164/67 (24.9)	10	pm	7.7	2.03	61
4	31	F	159/51 (20.2)	5	m (mid)	>10	1.55	38
5	19	F	170/50 (17.3)	6.7	m (base)	7	1.7	25
6	22	M	173/85 (28.4)	7	m (base)	8	1.51	32
7	19	M	182/72 (21.7)	7	pm	5.1	1.65	39
8	24	F	165/58 (21.3)	7	m (base)	5	1.6	35
9	30	F	155/55 (23.8)	7	pm (residual)	5.4	1.8	36
10	58	F	168/64 (22.6)	7.4	pm	8	1.9	38
11	19	M	170/76 (26.2)	7.2	pm	5	1.7	37
12	34	F	162/64 (24.4)	5	pm	5	1.68	34

BM - body mass index; F - female; M - male; m - muscular; pm - perimembranous; Qp/Qs - pulmonary to systemic flow ratio; SPAP - systolic pulmonary artery pressure

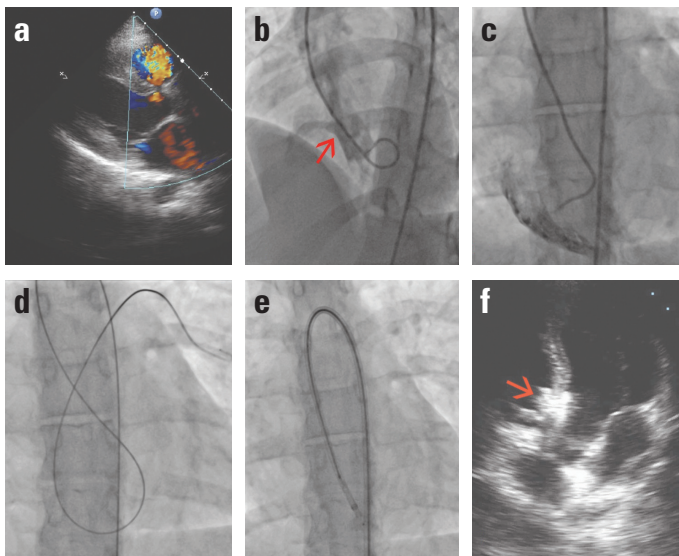


Figure 1. The steps of procedure in Case no 5. (a, b) The appearance of the defect on TEE and left ventriculography. (c) Right ventriculography taken after an Amplatzer right catheter was passed the defect. (d) The appearance of the an extra-stiff exchangeable wire after advancement to pulmonary artery. (e) The appearance of the device of 8 mm AMVSD-O while pulling back to defect as right ventricular disc unfolded. (f) The appearance of device after releasing on TTE

ventricle through a diagnostic coronary artery catheter (mostly Judkins right, Amplatzer right or IMA catheter, Medtronic, Minnesota, USA) (Fig. 1c). The catheter was advanced to the pulmonary artery (PA) or superior vena cava (SVC) or less frequently to inferior vena cava using a hydrophilic wire, which was then replaced with an extra-stiff wire with a soft tip and rigid shaft (Amplatzer Extra Stiff Guidewire, Cook Medical Inc. Bloomington, USA) (Fig. 1d). A long delivery sheath was advanced through the defect into the right ventricle (RV) over the rigid wire. After passing across the defect, only the sheath was advanced to the apex

of the RV while withdrawing the dilator slowly to avoid traumatization of the RV. It was deemed sufficient to pass 3–5 cm beyond the defect with the delivery sheath. A device 1 to 2 mm larger than the VSD diameter was selected and loaded on the pusher cable and advanced in the delivery catheter. When the device was positioned at the tip of the delivery catheter, the complete system was withdrawn and the RV disc was exteriorized 1–2 cm distal to the defect while avoiding entrapment of the chordal elements of the tricuspid valve (Fig. 1e). The whole system was withdrawn to place the right disc on the RV aspect of the defect and waist of the device and then the LV disc of the device was deployed. A control angiography was performed through the side arm of the delivery sheath by hand injection to confirm the final position of the device before its release. The placement of the device on the defect, function of the tricuspid, mitral, and aortic valves and residual regurgitation were evaluated using TEE or TTE (Fig. 1f). The device was released after confirming secure placement of the device on the defect and the absence of any impairment in the function of atrioventricular and semilunar valves.

Occluder devices

Two different devices were used: Amplatzer (St. Jude Medical, St. Paul, Minnesota, USA) and Cera occluder (Lifetech Scientific, Shenzhen, China). Amplatzer devices are the most used occluder devices in the Worldwide. Cera occluders are bearing very similarity to Amplatzer device in terms of design and implantation technique (4). The availability of the device at operation day was the main factor in the choice of devices.

Results

All patients except one underwent successful implantation of VSD occluder device using retrograde approach. The procedural details are presented in Table 2. In sixth patient, the de-

Table 2. Procedural details of cases

Case no	Defect size, mm/ Defect type/ Occluder Size, mm	Occluder type- company	Delivery system size (Fr)-type	Residual shunting	FT, min	PT, min	Total radiation exposure, mGy	DAP, Gycm ²
1	5/pm/6	m- Amplatzer	7-TorqVue 45	no	18	55	35.7	3.341
2	7.6/pm/8	m-Amplatzer	7-TorqVue 45	trivial	15	48	29.7	2.783
3	10/pm/10	pm-Lifetech Cera Symmetrical	7-Steerease 180	trivial	25	79	35.3	3.576
4	5/m/6	m-Lifetech Cera	6-Steerease 180	no	40	134	57.1	5.682
5	6.7/m/8	m-Amplatzer	8-TorqVue 180	no	7.2	42	7.6	0.834
6	7/m/8	m-Amplatzer	8-TorqVue 45	no	33.9	109	38.2	3.36
7	7/pm/8	m-Amplatzer	7-TorqVue 180	no	6.7	51	14.0	1.608
8	7/m/8	m-Amplatzer	7-TorqVue 180	no	8.9	67	22.1	0.818
9	7/pm/7	pm-Amplatzer	7-TorqVue 180	trivial	14.4	65	28.6	2.672
10	7.4/pm/8	m-Amplatzer	7-TorqVue 180	no	7.7	34	15.3	1.571
11	7.2/pm/8	m-Amplatzer	6-TorqVue 180	no	41.8	90	71.2	7.834
12	5/pm/6	m-Amplatzer	7-TorqVue 180	trivial	100.9	202	1775	151.97

DAP - dose area product; FT - fluoroscopy time; m - muscular; pm - perimembraneous; PT - procedure time

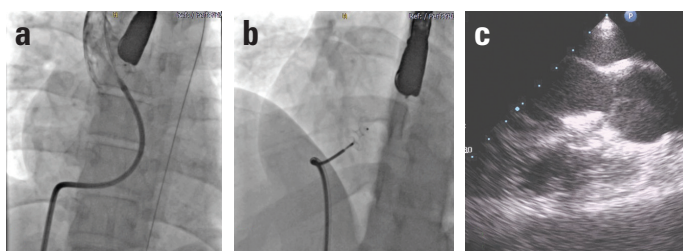


Figure 2. The steps of procedure in Case no 6. (a) The appearance of the delivery catheter while being in the ascending aorta. (b) The appearance of device before just releasing while both disc of it opened. (c) The appearance of device after releasing on TTE

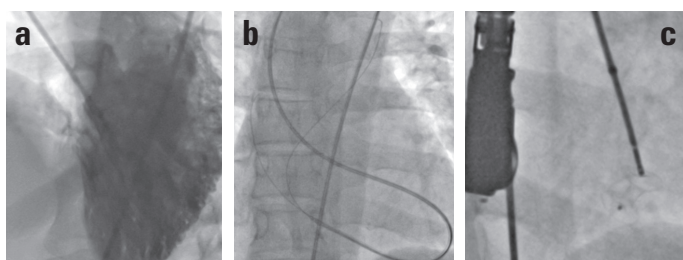


Figure 3. The steps of procedure in Case no 4. (a) The appearance of the mid-muscular VSD on left ventriculogram. (b) Two different hydrophilic wire was sent to different locations after the guiding catheter formed a loop in the left ventricle. (c) The device was deployed the defect

fect could not be cannulated because of the tip of the sheath did not reach the defect while the maximum possible length of the sheath advanced in the body. We attempted to advance the device fixed on the pusher catheter via an 8F right coronary guiding catheter. However, we were unable to insert the pusher catheter connected to the occluder device into the guiding catheter. All options available in the catheterization room were taken into consideration; however, due to a lack of any delivery system that would allow retrograde implantation of the device, VSD was closed with same sheath by standard transvenous approach by using an AV loop (Fig. 2a–c).

In patient number 3, a 7 mm Cera occluder was used initially; however, the device was dislodged from the defect into the LV with mild traction after the two discs were opened. The system was withdrawn and it was realized during the assessment that the diameter of the defect was underestimated. The device was passed through the defect for the second time and 10 mm device was implanted without residual shunting.

The patient number 4 had mid-muscular defect (Fig. 3a). There was no resistance in passage through the defect from the LV to RV using a hydrophilic wire; however, 7F long sheath was unable to pass through the defect over stiff wire. This long sheath showed angulation within the left ventricle while attempting to pass through the defect due to mid-positioning of the defect. Then, 6F multipurpose guiding catheter was attempted and same resistance was encountered. Thereafter, the catheter engaged in the defect by creating a loop in the left ventricular apex and placed co-axially. This ensured that the wire and the catheter were in the same axis with the defect and improved passage and transmission through the defect. Using this tech-

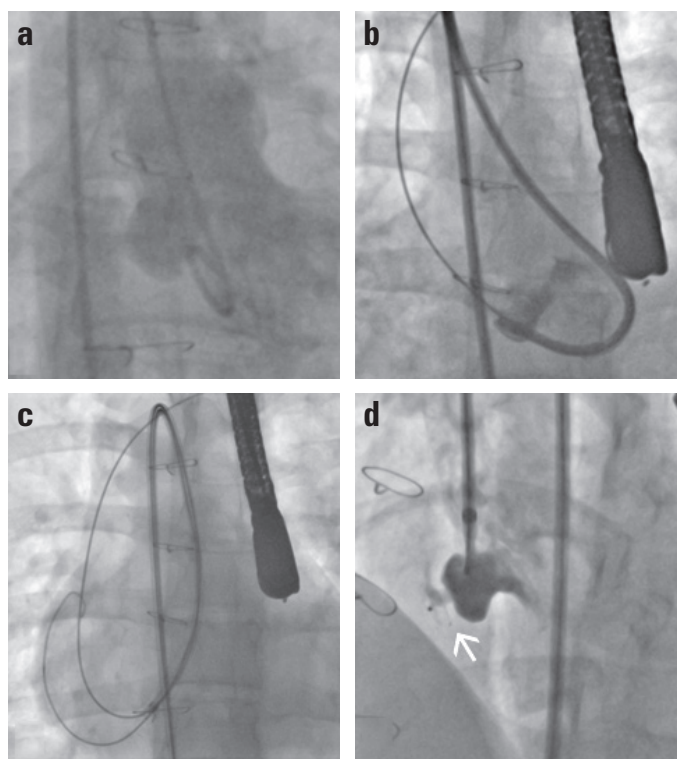


Figure 4. The steps of procedure in Case no 9. (a) Postoperative residual VSD originating from a large aneurysmatic sac is seen on left ventriculogram. (b) The buckling occurring on the delivery sheath is seen. (c) Delivery sheath can pass through the defect after second 0.038 inch standard wire advanced to distal. (d) Control ventriculogram taken with contrast given through the delivery sheath (white arrow: platinum marker), minimal residual shunt is seen

nique, a second hydrophilic wire was passed through the defect; one to the SVC and the other was advanced to the PA (Fig. 3b). The method proved useful, and a 6F long sheath, one size smaller than the first sheath was passed through the defect into the RV without using dilator. A 6-mm device was successfully placed to the defect (Fig. 3c).

Patient number 9 had postoperative residual VSD originating from a large aneurysmatic sac (Fig. 4a). There was resistance while passing the long sheath through the defect. Upon introduction of the tip of the sheath into the defect, the adjacent distal portion of the sheath showed angulation and buckling within the LV due to a narrow turning angle (Fig. 4b). As in patient number 4, a second 0.038-inch standard wire was passed through the defect and advanced distally in the right system. Two 0.038-inch wires passing through the same defect created a more stable line resistant to kinking and the delivery sheath was passed through the defect without using dilator (Fig. 4c). A 7 mm amplatzer perimembraneous occluder was implanted in this patient. The asymmetric disc was left in the side of the RV. A platinum marker was pointed toward the RV apex (Fig. 4d).

Patient number 12 had a perimembraneous tunnel-shaped VSD. The defect was opening to the RV after having a tunnel-like course with superior angulation from the origin of subaortic area (Figure 5a). After a hydrophilic wire was passed through the de-

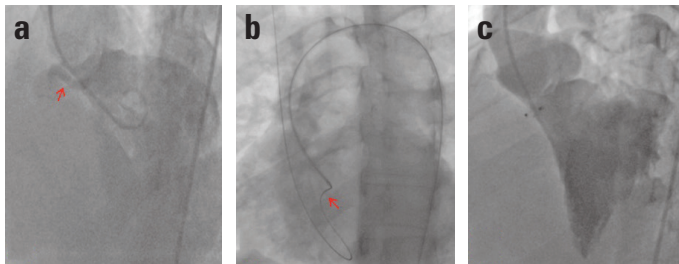


Figure 5. The steps of procedure in Case no 12. (a) Tunnel shaped perimembranous defect with superior angulation. (b) 5F terrumo glidecath pushed on the hydrophilic wire is seen while passing the defect (red arrow). (c) Final ventriculogram

fect, standard diagnostic catheters failed to pass through the defect into the RV. However, soft 5F Terumo Radifocus Glidecath was able to pass into the RV (Fig. 5b). A stiff wire was passed through the Glidecath into the SVC. However, two attempts to pass the delivery sheath across the defect failed and the stiff wire was dislodged from the defect in all attempts. After repeating these steps for the third time, the delivery sheath was advanced into the RV with its dilator, which was different from our standard approach. Our standard approach was to withdraw the dilator gradually while advancing the sheath after passing the dilator and the delivery sheath through the defect in order to avoid right ventricular trauma. This final attempt successfully placed the device in the defect (Fig. 5c). This case had the longest fluoroscopy and procedure times due to the need to pass through the defect repeatedly.

In other patients, the selected occluder device was successfully implanted on the first attempt using the retrograde approach. The mean procedure and fluoroscopy times were 81.3 min (median 66 min; range: 34–202 min) and 26.6 min (median 16.5; range: 6.7–100.9 min), respectively (Table 2). None of the patients experienced device embolism. TEE and control angiography did not show residual shunting in any patients, except patient numbers 2, 3, 9, and 12. Minimal residual shunting in these four patients disappeared during the controls. Aortic, tricuspid, and mitral valve functions remained unaffected in all patients. Severe arrhythmia or AV conduction disorder was not observed during or after the procedure in these patients. The mean duration of follow-up was 22 months (range 3–37 months). Case number 3 with highest pulmonary arterial pressure measurement (systolic 61 mm Hg, mean 46 mm Hg) did show regression to normal pulmonary arterial pressure level during follow-up.

Discussion

In the current case series retrograde technique was implemented successfully in all patients except one. The procedure was completed easily in seven patients so that mean fluoroscopy time in these patients was only 11.1 minutes (range 6.7–18). But on the other hand, we encountered some technical difficulties related to anatomical factors in three of our cases (case 4, 9 and 12) caused prolonged procedure and fluoroscopy times.

Unlike the retrograde technique, the antegrade technique requires the creation of an arterio-venous wire loop. The main advantage of the antegrade technique is the creation of a stable line through which the closure device can be advanced and a lower risk of trauma to the arterial structures in young children due to the advancement of the delivery system via venous access. Previously, the retrograde approach was described as the technique used in the failure of advancing occluder device via the venous route in cases in which the antegrade technique was used (7–9). The main reasons for not passing the device through the venous system reported in the literature include kinking of the delivery catheter after removal of the dilator and wire due to angulation in some cases, and spiral entrapment of the chordal elements of the tricuspid valve with the guide wire, which results in the inability to advance the delivery sheath. In the directly retrograde transarterial approach, the delivery system is advanced over the long exchangeable wire without creating an AV loop and passed through the defect from the LV side and deployed the RV disc of the occluder device first. This procedure involves fewer steps compared to the antegrade technique and avoids the factors associated with the advancement failure of the device via the venous route. This technique seems to reduce the procedure time, and radiation exposure of the operator and the patient, and cost of the procedure. While the small diameter of the arterial vessels in infants poses an obstacle for the selection of the retrograde approach, changes in the profile of the delivery systems allowed the use of transarterial implantation technique in older children and adolescents. Recently, with this technique the Amplatzer muscular occluder device (10, 11) and ADO II device (12) have been implanted successfully in adolescents and children with congenital VSD. There are also scant case reports in that retrograde technique was used (13–15). To our knowledge, the present series of patients is the first case series in the literature in which the directly retrograde technique has been used as the first line option in adults.

In our series, there was only one unsuccessful retrograde procedure that was due to the insufficient length of the delivery sheath. This condition has been reported in another adult patient in the literature. Different from our case, this patient underwent device implantation using antegrade approach in which the length of the sheath advanced via the venous route remained insufficient due to patient's height and the device could be implanted successfully using additional equipment after 6 months. However, the authors did not indicate the additional equipment with which they performed device implantation (17). When we retrospectively evaluated our own case, 6 or 7F, 120 cm long Amplatzer TorqVue 2 delivery sheath had sufficient length, allowing placement of the device in the defect. However, the standard transvenous approach was used due to the fact that the supplier was unable to provide this system at the time of procedure. In retrograde implantation, the distance to the defect from the vascular access site is longer compared to antegrade implantation due to fact that the delivery system has to be passed across the defect after rotation in the aortic arch. The length of the delivery system

Table 3. Procedure and flouroscopy times of available studies for comparison in context of implemented technique and age group

Ref (no)	Case number	Implantation technique		Flouroscopy time			Procedure time		
		Antg	Retrg	Mean	Median	Range	Mean	Median	Range
Our series	12	1	11	26.6	16.5	6.7-100.9	81.3	66	34-202
Al-Kashkari (17)	28	28	0	NA	23	13.2-76.8	NA	94	46-303
Chessa (16)	40	41	0	30.9	26.5	5-80	114	90	50-300
Koneti (12)	13	0	13	18.8	NA	8.2-45	NA	NA	NA
Jameel (10)	7	0	7	33.8	NA	13.7-74.3	91.1	NA	55-121

Antg - antegrade; NA - non applicable; Ref - reference; Retrg - retrograde

becomes much more important with the addition of anatomic factors related to patients with higher weight and height. The present case weighed 85 kg and was 173 cm tall, with a BMI of 28. Although patient number 1 was taller, the length of the sheath was sufficient, suggesting that patient height is not the only factor.

Previous studies have indicated kinking of delivery catheter after removal of the dilator and wire due to angulation on the transvenous path as the reason for switching from the transvenous approach to the transarterial approach (7–9). However, Hijazi et al. (7) and Koneti et al. (12) reported that kinking resistance could also occur during the retrograde approach and keeping 0.018 inches wire within the catheter until the closure device is pushed to the tip of the delivery catheter would overcome this problem. Jameel et al. (10) reported difficulty to cannulate the defect and prolonged procedure time due to repeated kinking of the delivery sheath in a patient with apically located muscular defect (fluoroscopy time was 74.3 min, and procedure time was 95 min). We also experienced problems in three cases while passing delivery catheter through the defect due to angulations of the transarterial path, which we considered to be related to the localization and anatomic features of the defect. Forced attempts to advance the delivery sheath posed a risk of dislodging of the all systems from the defect. In two case (case 4 and 9), we passed a coronary guiding catheter through the defect over first wire and advanced a second wire through this guiding catheter. We therefore achieved a more stable line using two wires passing through the same defect. The defect could be passed by advancing the delivery sheath without dilator inside over the two wires on this line. In our cases, the delivery catheter did not show kinking after removal of the wires as reported by Hijazi et al. (7) and Koneti et al. (12).

Use of muscular type occluders in perimembranous defects

If the distance to aortic valve is sufficient in perimembranous VSDs (aortic rim ≥ 5 mm), muscular type VSD occluders have been successfully used in the closure of perimembranous defects (8, 9). In addition, the risk for the development of AV block has been reported to be lower with muscular type VSD closure devices (9). The present study used muscular type occluders in six patients with perimembranous VSD. We were able to achieve complete or near complete (ie, tiny residual shunt flow that disappear in follow up) closure of the defects in all patients and we did not encounter any AV conduction disorder.

Disc inversion

Amin et al. (19) showed in an animal model that complete endothelialization occurs in Amplatzer devices within three months. To date, no complications have been reported related to disc inversion after the use of the retrograde technique. The only difference between antegrade and retrograde techniques in the placement of symmetric VSD occluders is that the screwing knob is left at the LV side and not in the RV side. However, this is not the case in eccentric devices. We preferred the eccentric type Amplatzer device in patient number 9. The defect was in the aneurysm sac in this patient, and it was not likely that the device would affect the aortic valve or produce unfavorable hemodynamic influence on the exit path (Fig. 4a). The another problem would may be the interaction of the eccentric disc of the device with the tricuspid valve septal leaflet (8, 20, 21). Indeed this condition some degree was more likely because of longer inferior left ventricular wings of the eccentric device and the more right position of the device caused by rightward shift of the aneurysm wall. On the other hand, the rims of the defect on which the discs of the closure device would adhere were thin. It was considered that the wings of the muscular device with a waist length of 7 mm would not attach firmly to the defect and the left ventricular disc of the asymmetric Amplatzer device remaining in the RV would not produce problems. Thus, the device was firmly attached to the defect and remained completely within the aneurysm sac. There was minimal shunting in the left ventriculography obtained by the administration of the opaque material through the sheath (Fig. 4d) and this shunting completely disappeared in the control echocardiography. Also there wasn't any negative interaction of tricuspid valve septal leaflet with the eccentric wings of the device. The authors consider the presence of aneurysm an advantage for perimembranous type defects (8, 22, 23). This reduces the risk of interaction between the device and the aortic valve, but also reduces the risk of AV block since the aneurysm sac does not contain conduction pathways. Hence, our case also had no cardiac rhythm problems.

Fluoroscopy and procedure times

It is accepted by the authors that transcatheter VSD closure is considered one of the interventional procedures of cardiology with a high level of difficulty (5). Even large case series reported by experienced centers indicate considerably prolonged fluoroscopy and procedure times in some cases. For example, the

maximum procedure time was 300 minutes and 342 minutes in the European registry (6) involving 403 cases and in a single center Chinese study (3) conducted on 848 cases, respectively. In some cases, whether the antegrade approach or retrograde approach is employed, difficulties in advancement of the delivery catheter through the defect and kinking of the delivery catheter may prolong fluoroscopy and procedure times. This was also the case in the present patients due to complex anatomic features of the defects (mid-muscular VSD, postresidual perimembranous VSD with large aneurysmal hole, and tunnel-shaped perimembranous VSD). Procedure and fluoroscopy times of two adult series implemented antegrade technique and two pediatric cases implemented retrograde technique and our series are summarized in Table 3. Our times are shorter than the two case series that included adult cases of VSD that underwent closure with an antegrade approach. When compared to two pediatric series that employed a technique similar to our study, our timings were somewhat longer than the figures in the study by Koneti et al. (12) and similar to that reported in the study by Jameel et al. (10) The retrograde implantation technique was easily employed in the majority of our cases, such that the fluoroscopy time was less than 20 minutes in seven cases (mean 11.1 min) and less than 10 minutes in four cases. The adoption of ALARA principles reduced radiation exposure in these patients (Table 2). The longest procedure was 202 minutes, which was performed in patient number 12. Due to technical difficulties encountered in this patient, high cumulative radiation doses have been reached due to the fact that the primary operator (corresponding author) used both low dose radiation mode and standard dose radiation mode during the scopy.

Study limitations

Due to the sufficient distance to the aortic valve in all patients, the symmetric type VSD occluders were successfully implanted using the retrograde technique. Due to the fact that asymmetric (eccentric) perimembranous VSD occluders must be used in patients with a very short aortic rim (<2 mm), it is obvious that the retrograde technique may not be used with the available design.

Our study was done by same primary operator at single center. Also the study population was small and the follow-up duration was short. The population was heterogeneous in terms of age, type of defect and device, which is limiting to make a comment for the best treatment option for the particular patient group. The results of this study should be supported by a multi-centre study involving many operators.

Conclusion

In the presence of favorable anatomic conditions, this technique may shorten procure and fluoroscopy times and significantly reduce radiation exposure. The only limitation in adult patients is the length of the delivery sheath. Safe placement of the

device using the retrograde method requires advancement of the delivery sheath at least 2 cm distal to the defect. In the catalogue of the manufacturers, recommended sheaths for VSD closure have two different size options as 60 cm and 80 cm. These sheath lengths are sufficient in children; however, taller patients with high BMI require a delivery sheath length of at least 100 cm.

The results of the present study suggest that retrograde approach may be implemented successfully in VSD closure without creating AV loop in adult patients. We suggest that the procedure must be initiated using the retrograde approach involving fewer steps and switched to the antegrade approach if the anatomic characteristics do not allow. We propose to use low frame rate scopy during these procedures for lowering radiation exposure to patients and operators.

Acknowledgements: Results of first six patients of our case series has been presented as a poster presentation at EuroPCR 2014 meeting (Euro14A-POS229).

Conflict of interest: None declared.

Peer-review: Externally peer-reviewed.

Authorship contributions: Concept – N.P., E.E., İ.T., M.E.Ö.; Design – E.E., N.P., M.E.Ö., F.Ö., A.Y.; Supervision – E.E., N.P., M.E.Ö., F.Ö., A.Y., C.T.; Fundings – E.E.; Materials – S.S., S.Y., C.T., F.Ö., A.Y.; Data collection &/ or processing – E.E., M.E.Ö., M.P., S.S., S.Y., İ.T.; Analysis &/or interpretation – N.P., M.E.Ö., E.E., S.S., S.Y., İ.T.; Literature search – S.S., S.Y., F.Ö., A.Y., N.P.; Writing – N.P., E.E.; Critical review – M.E.Ö., S.S., S.Y., İ.T., F.Ö., C.T., A.Y.

References

1. Thanopoulos BD, Tsaousis GS, Konstadopoulou GN, Zarayelyan AG. Transcatheter closure of muscular ventricular septal defects with the Amplatzer ventricular septal defect occluder: initial clinical application in children. *J Am Coll Cardiol* 1999; 33: 1395-9.
2. Qin Y, Chen J, Zhao X, Liao D, Mu R, Wang S, et al. Transcatheter closure of perimembranous ventricular septal defect using a modified double-disk occluder. *Am J Cardiol* 2008; 101: 1781-6.
3. Yang J, Yang L, Wan Y, Zuo J, Zhang J, Chen W, et al. Transcatheter device closure of perimembranous ventricular septal defects: mid-term outcomes. *Eur Heart J* 2010; 31: 2238-45.
4. Esteves CA, Solarewicz LA, Cassar R, Neves JR, Esteves V, Arrieta R. Occlusion of the perimembranous ventricular septal defect using Cera devices. *Catheter Cardiovasc Interv* 2012; 80: 182-7.
5. Holzer R, Balzer D, Cao QL, Lock K, Hijazi ZM; Amplatzer Muscular Ventricular Septal Defect Investigators. Device closure of muscular ventricular septal defects using the Amplatzer muscular ventricular septal defect occluder: immediate and mid-term results of a U.S. registry. *J Am Coll Cardiol* 2004; 43: 1257-63.
6. Carminati M, Butera G, Chessa M, De Giovanni J, Fisher G, Gewillig M, et al; Investigators of the European VSD Registry. Transcatheter closure of congenital ventricular septal defects: results of the European Registry. *Eur Heart J* 2007; 28: 2361-8.
7. Hijazi ZM, Hakim F, Al-Fadley F, Abdelhamid J, Cao QL. Transcatheter closure of single muscular ventricular septal defects using the

- amplatzer muscular VSD occluder: initial results and technical considerations. *Catheter Cardiovasc Interv* 2000; 49: 167-72.
8. Arora R, Trehan V, Kumar A, Kalra GS, Nigam M. Transcatheter closure of congenital ventricular septal defects: experience with various devices. *J Interv Cardiol* 2003; 16: 83-91.
 9. Szkutnik M, Kusa J, Białkowski J. Percutaneous closure of perimembranous ventricular septal defects with Amplatzer occluders - a single centre experience. *Kardiologia Pol* 2008; 66: 941-7.
 10. Jameel AA, Arfi AM, Arif H, Amjad K, Omar GM. Retrograde approach for device closure of muscular ventricular septal defects in children and adolescents, using the Amplatzer muscular ventricular septal defect occluder. *Pediatr Cardiol* 2006; 27: 720-8.
 11. Muthusamy K. Retrograde closure of perimembranous ventricular septal defect using muscular ventricular septal occluder: a single-center experience of a novel technique. *Pediatr Cardiol* 2015; 36: 106-10.
 12. Koneti NR, Penumatsa RR, Kanchi V, Arramraj SK, S J, Bhupathiraju S. Retrograde transcatheter closure of ventricular septal defects in children using the Amplatzer Duct Occluder II. *Catheter Cardiovasc Interv* 2011; 77: 252-9.
 13. Ergene O, Nazlı C, Kocabaş U, Duygu H, Akyıldız ZI, Hijazi ZM. Percutaneous closure of perimembranous ventricular septal defect with an Amplatzer Duct Occluder in a dextrocardia patient. *Int J Cardiol* 2011; 150: e77-80.
 14. Singh V, Badheka AO, Bokhari SS, Ghersin E, Clark PM, O'Neill WW. Retrograde percutaneous closure of a ventricular septal defect after myectomy for hypertrophic obstructive cardiomyopathy. *Tex Heart Inst J* 2013; 40: 468-71.
 15. Retzer EM, Dill KE, Shah AP. Novel transcatheter closure of an iatrogenic perimembranous ventricular septal defect. *Catheter Cardiovasc Interv* 2015; 85: 161-5.
 16. Chessa M, Butera G, Negura D, Bussadori C, Giamberti A, Fesslova V, et al. Transcatheter closure of congenital ventricular septal defects in adult: mid-term results and complications. *Int J Cardiol* 2009; 133: 70-3.
 17. Al-Kashkari W, Balan P, Kavinsky CJ, Cao QL, Hijazi ZM. Percutaneous device closure of congenital and iatrogenic ventricular septal defects in adult patients. *Catheter Cardiovasc Interv* 2011; 77: 260-7.
 18. Ergene O, Eren NK, Akyıldız ZI, Nazlı C. Percutaneous closure of ventricular septal defects in adult patients: our initial experience. *Turk Kardiyol Dern Ars* 2009; 37: 312-6.
 19. Amin Z, Gu X, Berry JM, Bass JL, Titus JL, Urness M, et al. New device for closure of muscular ventricular septal defects in a canine model. *Circulation* 1999; 100: 320-8.
 20. Christiani LA, Bergman F, Tress JC, Vanzillotta PP, Pedra CA. Severe tricuspid stenosis during percutaneous occlusion of perimembranous ventricular septal defect with the new Amplatzer device. *Congenit Heart Dis* 2006; 1: 239-43.
 21. Mertens L, Meyns B, Gewillig M. Device fracture and severe tricuspid regurgitation after percutaneous closure of perimembranous ventricular septal defect: a case report. *Catheter Cardiovasc Interv* 2007; 70: 749-53.
 22. Carminati M, Butera G, Chessa M, Drago M, Negura D, Piazza L. Transcatheter closure of congenital ventricular septal defect with Amplatzer septal occluders. *Am J Cardiol* 2005; 96: 52L-8L.
 23. Ergene O, Kahya Eren N, Nazlı C, Duygu H, Kocabaş U. Percutaneous closure of perimembranous ventricular septal defects associated with septal aneurysm in adults. *Turk Kardiyol Dern Ars* 2015; 43: 699-704.