

# Transdermal estrogen gel and oral aspirin combination therapy improves fertility prognosis via the promotion of endometrial receptivity in moderate to severe intrauterine adhesion

YUGANG CHI<sup>1</sup>, PING HE<sup>2</sup>, LI LEI<sup>2</sup>, YI LAN<sup>2</sup>, JIANGUO HU<sup>1</sup>, YING MENG<sup>1</sup> and LINA HU<sup>1</sup>

<sup>1</sup>Department of Gynecology and Obstetrics, The Second Affiliated Hospital of Chongqing Medical University, Chongqing 400010; <sup>2</sup>Department of Gynecology and Obstetrics, Chongqing Health Center for Women and Children, Chongqing 400020, P.R. China

Received September 22, 2017; Accepted January 19, 2018

DOI: 10.3892/mmr.2018.8685

**Abstract.** Intrauterine adhesion (IUA) is one of the most common gynecological diseases in women of reproductive age. IUA, particularly in moderate to severe forms, accounts for a large percentage of infertility cases. Clinically, the first-line treatment strategy for IUA is transcervical resection of adhesion (TCRA), followed by adjuvant postoperative treatment. Estrogen is one of the classic chemotherapies used following TCRA and contributes to preventing re-adhesion following surgery. However, estrogen has limited effects in promoting pregnancy, which is the ultimate goal for IUA management. In the present study, a transdermal estrogen gel and oral aspirin combination therapy was used in patients with IUA following TCRA. Compared with in the control group (transdermal estrogen only therapy), the combination therapy significantly increased endometrial receptivity marker ( $\alpha\beta3$  and laminin) expression in endometrium tissues. Additionally, ultrasonic examination revealed the pulsatility index and resistant index of the uterine artery were lower in the combination therapy group. Combination therapy promoted angiogenesis and prevented fibrosis following TCRA more effectively than estrogen-only therapy. Collectively, the evaluation indices, including American Fertility Society score, endometrial parameters and pregnancy rate, indicated that patients with combination therapy had better prognoses in endometrial repair and pregnancy. In conclusion, postoperative combination therapy with transdermal estrogen gel and oral aspirin may be more efficacious in enhancing endometrial receptivity by increasing uterine blood and angiogenesis, contributing to

improved fertility prognosis. The findings of the present study may provide novel guidance to the clinical treatment of IUA.

## Introduction

Intrauterine adhesion (IUA), also known as Asherman syndrome, was defined by Joseph Asherman in 1948 (1). IUA comprises of a filmy or dense fibrous adhesive band within the uterine cavity resulting in the adherence of opposing endometrium (1). The prevalence of IUA has increased over the last 20 years due to the increased use of hysteroscopic surgeries, including dilation or curettage (2). The main clinical manifestations of IUA appear as menstrual abnormalities, hypomenorrhea, secondary infertility, recurrent miscarriage and pelvic pain (3). Among the symptoms, secondary infertility may affect a patients' life most severely. Therefore, treatment is necessary in cases of moderate or severe IUA only for patients with reproductive requirements (3). **In clinical practice, transcervical resection of adhesion (TCRA) is widely regarded as the standard strategy for the treatment of moderate to severe IUA (4); however, IUA has a high rate of recurrence following TCRA, which may be  $\geq 62\%$  in severe IUA (5). Due to its high recurrence rate, IUA management requires adjuvant treatment following surgery and pharmacological therapies, and physical barriers are applied to prevent postoperative re-adhesion (6,7). Postoperative estrogen therapy is widely utilized to prevent recurrent adhesion; however, the effects of estrogen therapy alone for moderate to severe IUA remains less than impressive and reproductive prognosis is poor (8). Thus, more effective strategies to improve IUA patient fertility rates are necessary.**

Endometrial receptivity (ER) is a transitory period when the endometrium is acceptable to embryo implantation, which is closely associated with embryo implantation rate and pregnancy rate (9). Almost two-thirds of implantation failures correlate with poor ER (10,11); as such, ER is one of the most important prognostic factors of fertility (9). In the field of artificial assisted reproduction technology (ART), ER, as well as the number of embryos and embryo quality, are decisive factors for fertility outcomes. In addition, in the evaluation of IUA therapy, ER also serves as a crucial prognostic factor of fertility. Integrin  $\alpha\beta3$  and laminin (LAM) are acknowledged

---

*Correspondence to:* Dr Lina Hu, Department of Gynecology and Obstetrics, The Second Affiliated Hospital of Chongqing Medical University, 76 Lin Jiang Road, Chongqing 400010, P.R. China  
E-mail: cqhulina@126.com

**Key words:** intrauterine adhesion, endometrial receptivity, transdermal estrogen, aspirin, fibrosis, angiogenesis, fertility

as valuable indicators of ER. Integrin  $\alpha\beta3$  is a member of the integrin family, which is a group of cell membrane bound proteins that connect the cytoskeleton and extracellular matrix (ECM) (12).  $\alpha\beta3$ , also known as the vitronectin (VN) receptor, contains 2 subunits,  $\alpha$  and  $\beta$  (13). It is reported to bind to a variety of ECM proteins, including VN, fibronectin, fibrinogen, osteopontin and bone sialic 1 (14). It has been reported that  $\alpha\beta3$  and LAM are ER markers (15).

Aspirin is a non-steroidal anti-inflammatory drug (NSAID), the main component of which is acetylsalicylic acid (16). It is widely used in numerous different types of diseases and conditions, including alleviating fever and pain, inflammation, myocardial infarction, cardiovascular morbidity and certain types of cancer (16-18). Aspirin has been reported to increase pregnancy rates in patients undergoing *in vitro* fertilization (IVF) by enhancing ER (19). Aspirin has been scarcely reported for use in IUA treatment; however, oral estrogen therapy alone has deficits. The first-pass elimination of oral estrogen by the liver or gut wall limits blood concentration (20). In addition, the side effects of orally taken estrogen on organs (21,22) restrict the use of estrogen in IUA postoperative treatment. Most importantly, estrogen therapy alone contributes little to increasing pregnancy rates in IUA patients (23). Thus, the present study investigated whether a therapeutic combination of transdermal estrogen gel and oral aspirin may enhance ER and fertility prognosis.

Previous research has demonstrated that patients with transdermal estrogen gel therapy exhibit better outcomes (24) and lower thrombotic risk (25) compared with oral estrogen therapy. In addition, to avoid oral drug interaction, the present study used transdermal estrogen therapy instead of oral estrogen therapy. The results indicated that the combination of transdermal estrogen gel and oral aspirin may significantly enhance ER by increasing the resistant (RI) and pulsatility indices (PI) and by promoting angiogenesis. Combination therapy revealed a higher efficacy in preventing fibrosis than estrogen therapy alone. The advantage in enhancing ER makes the combination of transdermal estrogen gel and oral aspirin a more promising treatment for IUA postoperative management. The findings of the present study may provide novel ideas for the clinical treatment of IUA.

## Materials and methods

**Patient samples.** The patients selected in the present study were admitted to the Chongqing Health Center for Women and Children (Chongqing, China) between September 2016 and February 2017, and were diagnosed with IUA by hysteroscopy. A total of 40 female patients were randomly selected; however, only 38 cases completed the study (1 case in the control group was removed in the middle of the study due to an allergy to alcohol, which was a solvent component in the control group; 1 case in the control group failed to appear for a scheduled follow-up). The present study was approved by the Ethics Committee of Chongqing Health Center for Women and Children, and written informed consent was obtained from all patients prior to their inclusion in the present study. The patients were aged 21 to 45 years, with a mean age of 29 years. All of the pathologies were confirmed by pathological examination. Patients, who had additional endometrial complications, including dysfunctional uterine bleeding, adenomyosis,

polycystic ovary syndrome and other hormone dependent diseases, were excluded. All of the patients included in the present study had regular menstrual cycles, had not received hormone therapy during the 3 months prior to surgery and were not pregnant or lactating during the study period.

**Postoperative artificial menstrual cycle therapy and follow up.** Patients with moderate or severe IUA were treated by TCRA combined with intrauterine balloon placement following American Fertility Society (AFS)-score determination (26). The patients were randomly divided into 2 groups: Group A and group B. Patients (n=18) in group A (control group) were postoperatively administered 5 g/day transdermal estrogen gel (EstradiolGel; Besins Manufacturing Belgium Co., Ltd., Drogenbos, Belgium) while patients in group B (treatment group; n=20) were postoperatively given 5 g/day transdermal estrogen and 100 mg/day oral aspirin. Patients in the 2 groups were treated for 2 consecutive months. During the second month, urinary luteinizing hormone (LH) test strips were used to monitor ovulation in all patients. Once ovulation was detected, a reasonable size (10-20 mm<sup>3</sup>) of endometrium was excised and processed based on the subsequent experimental requirements. Following the 2 months of therapy, follow-up examinations were performed on all patients once their first menstrual period ended. For patients that failed to recover their menstrual cycle, the follow-up was arranged immediately following 2 months of therapy. During the follow-up, details of their menstrual cycle, ultrasonic examination and hysteroscopy were used to assess the efficacy of the therapies, by measuring menstrual flow, uterine length, endometrium thickness, endometrial volume, average AFS-score, and artery RI and PI during the follow-up examinations. TCRA was performed again if necessary.

Estrogen has been well established as the most important drug for IUA patients following TCRA (7), thus, the present study did not include a group of patients treated with aspirin only; however, comparisons between the estrogen only treatment group and the combination therapy of estrogen and aspirin groups may provide equivalent evidence to demonstrate the effects of aspirin in IUA patients.

**Histological staining, H&E staining and immunohistochemistry (IHC).** Endometrial tissues were fixed in 4% paraformaldehyde solution at room temperature for 24 h, embedded in paraffin and sliced into 4  $\mu$ m sections. Deparaffinized sections were stained according to Masson's Trichrome staining protocol (BJS Biological Technology Co., Ltd., Nanjing, China). The percentage of blue staining indicated the extent of endometrial fibrosis. For H&E staining, deparaffinized sections were stained using a Solarbio H&E staining kit according to its manufacturer's protocols (G1120; Beijing Solarbio Science & Technology Co., Ltd., Beijing, China). For IHC, tissue paraffin sections were deparaffinized in xylene and rehydrated using an alcohol gradient. Antigen retrieval was performed by heating in a microwave (>95°C) and endogenous peroxidase activity was quenched by immersing the samples in 3% H<sub>2</sub>O<sub>2</sub>. The samples were blocked with normal goat serum (ZSGB-Bio, Beijing, China) at 37°C for 10 min. Then samples were incubated overnight at 4°C with anti-rabbit transforming growth factor- $\beta$  (TGF- $\beta$ ; 1:100; bs-0086R; BIOSS, Beijing, China), anti-rabbit CCCTC-binding factor (CTGF; 1:100;

bs-0743R; BLOSS), anti-rabbit vascular endothelial growth factor (VEGF; 1:100; bs-1313R; BLOSS), anti-rabbit  $\alpha\beta 3$  antibody (1:100; bs-0342R; BLOSS), anti-rabbit collagen I (COI; 1:100; bs-0578R; BLOSS), anti-rabbit collagen III (COIII; 1:100; bs-0948R; BLOSS) or anti-rabbit cluster of differentiation (CD31; 1:100; bs-20320R; BLOSS) primary antibodies. The slides were washed with PBS and incubated with secondary antibody (1:1, Rabbit Streptavidin-Biotin Detection system, SP9001; OriGene Technologies, Inc.) at 37°C for 15 min. The slides were then stained with 3,3-diaminobenzidine (DAB) at room temperature for 3 min. Cell nuclei were stained with hematoxylin at room temperature for 3 min. All images were observed under an optical microscope (magnification, x200; Eclipse 50i; Nikon Corporation, Tokyo, Japan) with NIS-Element DS-Ri1-U3 software (Nikon Corporation). Each image of H&E staining, Masson's staining or IHC staining was captured at x200 magnification.

**Reverse transcription-quantitative polymerase chain reaction (RT-qPCR).** Total RNA of endometrium tissues was isolated using a High PureRNA Isolation kit (BioTeke Corporation, Beijing, China) according to the manufacturer's protocols. cDNA was synthesized using aniSCRIPT cDNA Synthesis kit (GeneCopoeia, Inc., Rockville, MD, USA) with following procedure: adding 1  $\mu\text{g}$  oligo dT primer into RNA, 65°C for 10 min; adding the remaining agents, 37°C for 1 h, 85°C for 5 min. The primers were synthesized by GeneCopoeia, Inc. The primers sequences were as follows: TGF- $\beta$  forward, 5'-TGGTGGAAACCCACAACGAA-3' and reverse, 5'-GAGCAACACGGGTTTCAGGTA-3'; CTGF forward, 5'-TGACCCCTGCGACCCACA-3' and reverse, 5'-TACACCGACCCA CCGAAGACACAG-3'; VEGF forward, 5'-ATGAACTTTCTGCTGTCTTGG-3' and reverse, 5'-TCACCGCCTCGGCTTGTCACA-3'; CD31 forward, 5'-TGTTGACATGAAGAGCCTGC-3' and reverse, 5'-ACAGTTGACCCTCACGATCC-3';  $\alpha\text{v}$  forward, 5'-TCCGATTCCAAACTGGGAGC-3' and reverse, 5'-AAGGCCACTGAAGATGGAGC-3';  $\beta 3$  forward, 5'-CGAGTGCCCTCTGTGGTCAAT-3' and reverse, 5'-AGAAGTCGTCACTCGCAG-3'; LAM forward, 5'-AAGTGGCACACGGTCAAGAC-3' and reverse, 5'-GACAAGAGCTGCATATCCGC-3'; COI forward, 5'-AGGCTTCAGTGGTTTGGATG-3' and reverse, 5'-CACCAACAGCACCATCGTTA-3'; COIII forward, 5'-CCCAACCCAGAGATCCATT-3' and reverse, 5'-GAAGCACAGGAGCAGGTGTAGA-3'; and GAPDH forward, 5'-ACTCCACTCACGGCAAATTC-3' and reverse, 5'-TCTCCATGGTGGTGAAGACA-3'. The SYBR-Green RT-qPCR kit (2X All-in-One qPCR Mix) was purchased from GeneCopoeia Inc. Relative quantification of mRNA was performed using the comparative quantification cycles (Cq) method; GAPDH was used as the reference gene. This value was used to plot the gene expression employing the formula  $2^{-\Delta\Delta Cq}$  (27). qPCR cycling conditions were as follows: 95°C for 10 min, followed by 40 cycles of 95°C for 30 sec, 60°C for 20 sec and 72°C for 10 sec. The experiments were performed in triplicate for each sample.

**Western blotting.** Tissues were lysed with a radio immune precipitation assay buffer containing protease inhibitors. Proteins were quantified using a Bicinchoninic Acid protein assay kit (Beyotime Institute of Biotechnology, Beijing,

China) according to the manufacturer's protocols. Aliquots of the lysates containing 40  $\mu\text{g}$  total protein were separated via 8 or 10% SDS-PAGE. The proteins were transferred to a polyvinylidene fluoride membrane and blocked via incubation with TBST (20 mM TrisHCl, pH 7.4, 150 mM NaCl, 0.05% Tween-20) containing 5% non-fat milk powder for 1 h at room temperature. The membrane was incubated with anti-rabbit TGF- $\beta$  antibody (1:100; BLOSS), anti-rabbit CTGF antibody (1:100; BLOSS), anti-rabbit VEGF antibody (1:100; BLOSS), anti-rabbit  $\alpha\beta 3$  antibody (1:100; BLOSS), anti-rabbit COI antibody (1:100; BLOSS), anti-rabbit COIII antibody (1:100; BLOSS) or anti-rabbit CD31 antibody (1:100; BLOSS) overnight at 4°C. The membrane was then incubated with horseradish peroxidase-conjugated secondary antibodies (1:1,000, ab6721; Abcam, Cambridge, UK) for 1 h at 37°C. The western blotting bands were visualized via enhanced chemiluminescence (Nanjing Keygen Biotech Co., Ltd., Nanjing, China). The bands were captured by a gel imaging system (ChemiDoc MP; Bio-Rad Laboratories, Inc., Hercules, CA, USA) and analyzed with Quantity One software, version 4.6.2 (Bio-Rad Laboratories, Inc.) and calculated by comparison against the internal control (anti-rabbit GAPDH antibody; 1:1,000; bs-10900R; BLOSS).

**Statistical analysis.** Statistical analyses were performed using SPSS version 17 software (SPSS, Inc., Chicago, IL, USA). Each experiment was performed in triplicate. Data were presented as the mean  $\pm$  standard deviation. Multiple comparisons were performed using Dunnett's analysis of variance, and differences between two groups were calculated using a t-test.  $P < 0.05$  was considered to indicate a statistically significant difference.

## Results

**Demographic data in study groups.** The baseline demographics and clinical characteristics, including age, parity and most probable etiology of IUA, of the 38 patients included in the present study revealed no statistically significant effects in recruiting the cases (Table I).

**IUA patients with a combination of transdermal estrogen gel and aspirin therapy exhibit better effects than simple transdermal therapy.** All patients from both groups received TCRA and the placement of an intrauterine balloon in the uterus. The typical hysteroscopic views of patients prior to and following TCRA are presented in Fig. 1. During the postoperative follow-up examinations, there was no clinical evidence of postoperative infection or abdominal pain reported in any of the cases. The outcomes of the two different therapies were assessed by the following indicators: Uterine length, menstrual flow, postoperative adhesion score according to the AFS standard (26), endometrium thickness and pregnancy condition. Short-term follow-ups were scheduled  $\sim 1$  year ( $1 \pm 0.2$  years) and the number of pregnancy cases was recorded. The results revealed that patients with a combined therapy of transdermal estrogen gel and oral aspirin had significant improvements in average AFS-score, with an absence of adhesions recorded in 8 out of 18 cases (44.44%) in group A and 15 out of 20 cases (75.00%) in group B (Table II). The two groups demonstrated significant differences in uterine length and menstrual flow when comparing the preoperative and

Table I. Demographic data in study groups.

Variable	Group A (n=18)	Group B (n=20)
Average age (years)	30±4.80	29±5.81
Parity (average times)	1±0.45	1±0.63
IUA grade (n)		
Moderate	11 (61.11%)	12 (60.00%)
Severe	7 (38.89%)	8 (40.00%)
Most probable etiology of IUA		
Caesarean section history (n)	8 (44.44%)	9 (45.00%)
Dilatation section and curettage (average times)	3±0.45	3±0.67
Pelvic inflammatory disease	No	No
Excision of uterine septum	No	No
Genital tuberculosis	No	No

Data are presented as the mean ± standard deviation or n (%). Group A, transdermal estrogen gel therapy; group B, combination therapy of transdermal estrogen gel and oral aspirin therapy; IUA, intrauterine adhesion.

postoperative values within the same group. In addition, group B exhibited greater improvements (Table II). From the pregnancy data, patients with combination therapy had a relatively higher rate of pregnancy compared with patients with estrogen-alone therapy (Table II). However, long-term follow-ups are required to obtain data that are more specific. These data indicated that, compared with simple transdermal estrogen therapy, combination therapy with transdermal estrogen gel and oral aspirin may improve the postoperative prognosis and increase the rate of pregnancy in patients with IUA.

*Combination therapy with transdermal estrogen gel and oral aspirin enhances ER during endometrium rehabilitation in patients with IUA.* In the present study,  $\alpha\text{v}\beta 3$  and LAM, two ER markers, were analyzed to evaluate ER in patients. IHC was used to assess the expression of  $\alpha\text{v}\beta 3$  or LAM in tissues from the two groups of patients. Tissues were collected on the 20-24th day of the second postoperative menstrual cycle when patients detected ovulation with a LH rapid test strip. The IHC results demonstrated that  $\alpha\text{v}\beta 3$  and LAM were mildly expressed or not detected in preoperative samples. Postoperatively,  $\alpha\text{v}\beta 3$  and LAM stained strongly in group B, while revealing only moderate expression in group A (Fig. 2A). Furthermore, the mRNA expression levels of  $\alpha\text{v}\beta 3$  and LAM were investigated with RT-qPCR and the protein expression levels of these two markers were analyzed by western blotting in postoperative tissues from the two groups. Consistent with the IHC results,  $\alpha\text{v}\beta 3$  and LAM were highly expressed in group B at the mRNA (Fig. 2B) and protein levels (Fig. 2C) in postoperative tissues when compared with group A. These data indicated that a combination therapy of transdermal estrogen and oral aspirin improved ER during endometrium rehabilitation in patients with IUA.

*Combination therapy improves neovascularization during endometrium rehabilitation in patients with IUA.* In the present

Table II. Outcome measures in study groups.

Variable	Group A (n=18)	Group B (n=20)
Uterine length (cm)		
Preoperative	5.92±1.34	6.11±1.27
Postoperative	6.97±1.46	7.72±1.41
Menstrual flow (days)		
Preoperative	3±0.73	3±0.81
Postoperative	5±1.36 <sup>b</sup>	5±1.71 <sup>a,b</sup>
Endometrium thickness (mm)		
Preoperative	4.25±0.72	4.18±0.91
Postoperative	7.64±1.54 <sup>b</sup>	9.12±1.78 <sup>a,b</sup>
Menstrual volume (ml)		
Preoperative	38.77±7.46	40.76±8.92
Postoperative	64.78±6.33 <sup>b</sup>	69.72±8.01 <sup>a,b</sup>
Postoperative adhesion cases (n)		
No	8 (44.44%)	15 (75.00%) <sup>a</sup>
Mild	4 (22.22%)	3 (15.00%)
Moderate	3 (16.67%)	1 (5.00%)
Severe	3 (16.67%)	1 (5.00%)
Postoperative average AFS-score	6±0.45	3±0.73 <sup>a</sup>
Postoperative pregnant cases (n)	3 (16.67%)	6 (30.00%) <sup>a</sup>

Data are presented as the mean ± standard deviation or n (%). <sup>a</sup>P<0.05 vs. group A; <sup>b</sup>P<0.05 vs. preoperative values within the same group. Group A, transdermal estrogen gel therapy; group B, combination therapy of transdermal estrogen gel and oral aspirin therapy; AFS, American Fertility Society.

study, based on ultrasonography, the RI and PI were analyzed (Fig. 3A). The results revealed that patients from group B exhibited lower RI and PI, indicating that the combination therapy had vasodilatory effects on the uterus, potentially due to endometrial neovascularization. Microvessel density (MVD) was determined based on H&E staining in the postoperative endometrial patient samples (Fig. 3B). It was observed that samples from group B had a 1.8-fold increase in MVD when compared with group A (Fig. 3B). Also, the expression of the angiogenesis markers CD31 and VEGF (28) were determined by IHC (Fig. 3C), RT-qPCR and western blotting in postoperative samples. Compared with group A, VEGF was highly expressed at the mRNA (Fig. 3D) and protein levels in group B (Fig. 3E). These data suggested that combination therapy with transdermal estrogen gel and oral aspirin may have improved neovascularization during endometrium rehabilitation in patients with IUA.

*Transdermal estrogen gel and oral aspirin combination therapy inhibits endometrial fibrosis during endometrium rehabilitation in patients with IUA.* Endometrial fibrosis is accepted as an important factor for IUA formation. Fibrosis was determined in the tissues by Masson's Trichrome staining. The results revealed that the endometrial tissues from the combination therapy group had less fibroses compared with the tissues from the estrogen therapy group (Fig. 4A). Additionally, the expression levels of the fibrotic markers (TGF- $\beta$ , CTGF, COI and COIII) in tissues

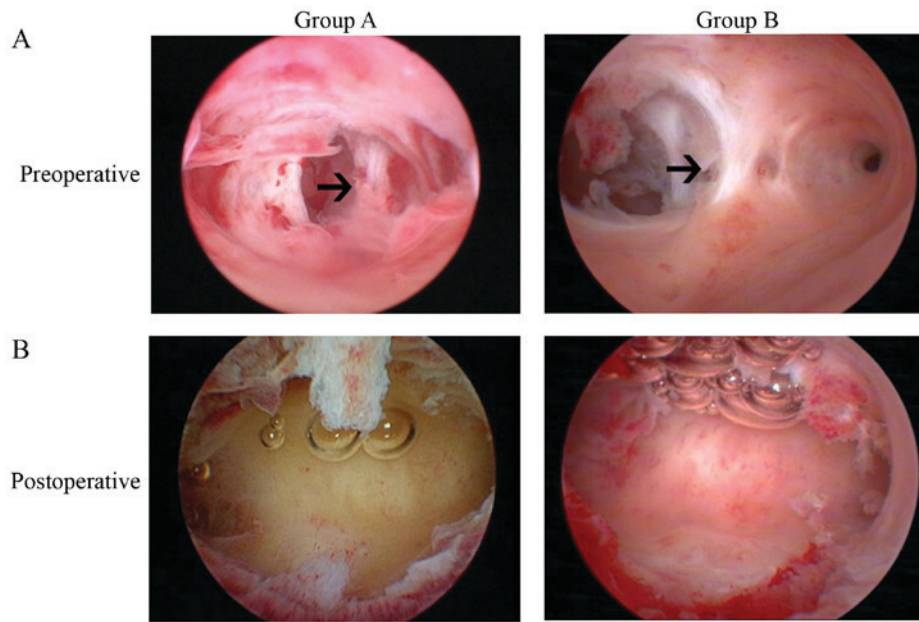


Figure 1. Hysteroscopic view of intrauterine tissues. (A) In the preoperative photos, adhesion (indicated by arrows) was detected in the central portion of the cavity in the two groups. (B) Postoperative photos were captured immediately following transcervical resection of adhesion; adhesion was completely divided in the two groups. Group A, transdermal estrogen gel therapy; group B, combination therapy of transdermal estrogen gel and oral aspirin therapy.

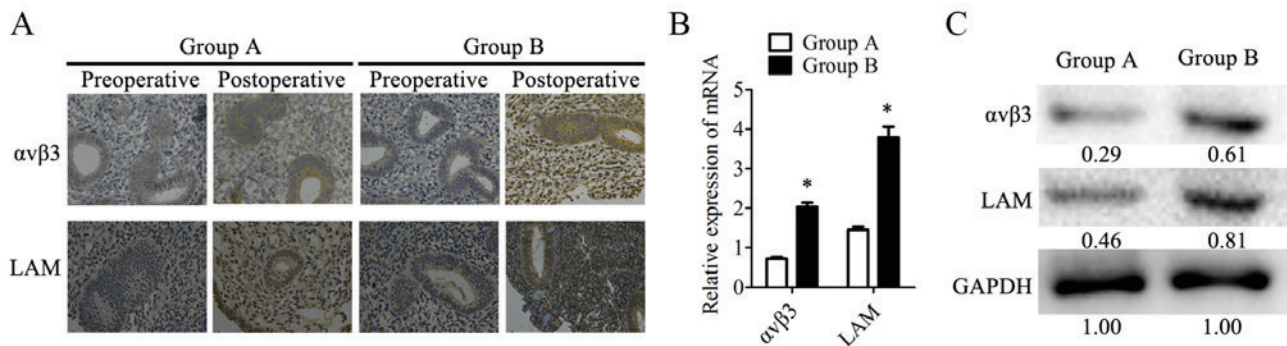


Figure 2. Endometrial receptivity is significantly increased in endometrium tissues from the combination therapy group following treatment. (A) Expression of  $\alpha v \beta 3$  and LAM were detected by immunohistochemistry;  $\alpha v \beta 3$  and LAM were detected primarily in the cytoplasm of gland cells and stroma cells. Magnification,  $\times 200$ . The expression of  $\alpha v \beta 3$  and LAM in human endometrial tissues was determined at the mRNA level by (B) reverse transcription-quantitative polymerase chain reaction and at the protein level by (C) western blotting. The relative quantity of proteins was calculated by comparison against the internal control (GAPDH) and noted below the bands. Postoperative tissues were obtained during the follow-up at the 20-24th day of the second menstrual cycle following transcervical resection of adhesion. \* $P < 0.05$  vs. group A. Group A, transdermal estrogen gel therapy; group B, combination therapy of transdermal estrogen gel and oral aspirin therapy; LAM, laminin.

were analyzed by IHC staining (Fig. 4B). TGF- $\beta$ , CTGF, COI and COIII were expressed in the cytoplasm and nucleus of the epithelial and stromal cells. There was also strong staining in the preoperative endometrial tissues from the two groups. However, these four proteins were mildly expressed or were undetected in the postoperative tissues from group B, while the postoperative tissues from group A exhibited higher expression levels of these markers. In postoperative tissues, the expression levels of fibrotic markers were examined at the mRNA level by RT-qPCR and at the protein level by western blotting. In samples from group B, the TGF- $\beta$  mRNA expression levels were 75% lower than in group A. Similarly, the mRNA expression levels of CTGF, COI and COIII were 48, 31 and 24% lower, respectively, in group B than in group A (Fig. 4C). The relative protein expression levels determined by western blotting (Fig. 4D) were consistent with the results of RT-qPCR. These data indicated that combination

therapy with transdermal estrogen gel and oral aspirin may have inhibited postoperative endometrial fibrosis during endometrium rehabilitation in patients with IUA.

## Discussion

IUA is one of the most common reproductive system diseases in women of childbearing age (23). The incidence is rising due to the increasing use of intrauterine operations, including curettage, dilation and hysteromyomectomy (29). A total of ~40-50% of severe IUA patients have secondary infertility, which is the most severe symptom and requires treatment (30,31). Transcervical resection of adhesion is the mainstay treatment for moderate and severe IUA (5). However, high rates of postoperative recurrence of IUA and low pregnancy rates pose great challenges to clinical management (3). A wide range of

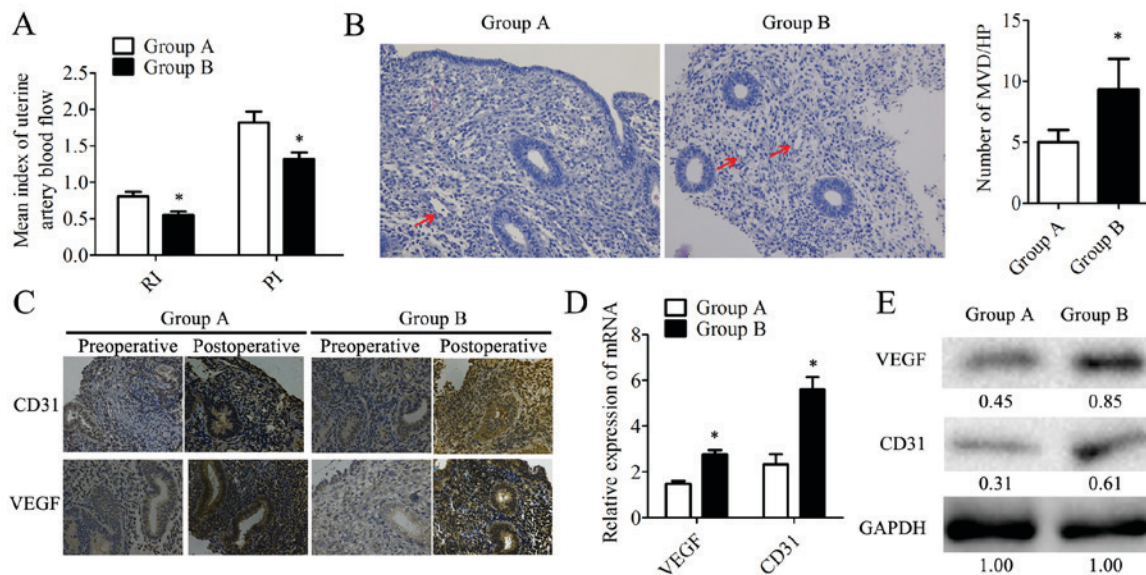


Figure 3. Angiogenesis is significantly increased in endometrium tissues within the combination therapy group following treatment. (A) RI and PI were determined based on the ultrasonic examination. (B) Microvessels (indicated by arrows) were observed by hematoxylin staining. MVD was counted in 10 different HP fields. Magnification,  $\times 200$ . (C) The expression of CD31 and VEGF was detected by immunohistochemistry. Magnification,  $\times 200$ . The expression of CD31 and VEGF in human endometrial tissues was determined at the mRNA level by (D) reverse transcription-quantitative polymerase chain reaction and at the protein level by (E) western blotting. The relative quantity of proteins was calculated by comparison against the internal control, GAPDH, and noted below the bands. The postoperative tissues were obtained during the follow-up at the 20-24th day of the second menstrual cycle following transcervical resection of adhesion. Data are presented as the mean  $\pm$  standard deviation. \* $P < 0.05$  vs. group A. CD31, cluster of differentiation 31; group A, transdermal estrogen gel therapy; group B, combination therapy of transdermal estrogen gel and oral aspirin therapy; HP, high power; MVD, microvessel density; PI, pulsatility indices; RI, resistant indices; VEGF, vascular endothelial growth factor.

treatment techniques are applied to prevent re-adhesion (5); however, these treatments are seldom successful in improving pregnancy rates for patients. Oral estrogen is widely used in IUA patients following TCRA and a previous study has reported that estrogen may help with endometrium repair, inhibition of fibrosis and angiogenesis (4). However, oral estrogen therapy presents notable barriers. The first-pass elimination of oral estrogen impairs its blood concentration in some patients. Thus, transdermal estrogen gel was employed in the present study, which has been proven to have equivalent effects in treating IUA following surgery (24). Additionally, transdermal estrogen causes less harm to the liver and has lower thrombotic risk (25). The majority of patients with IUA are of reproductive age; however, the effect of estrogen on improving fertility is not ideal (4,24). Aspirin is an NSAID that is widely used to relieve pain and reduce the risk of cardiac diseases, such as myocardial infarction (16,17). It has been reported that low-dose-aspirin (LDA) may improve the prognosis of IVF (19); however, whether aspirin is effective in the treatment of IUA requires further investigation. In the present study, the effects of a combination therapy constituting transdermal estrogen gel and oral aspirin in IUA patients were analyzed. The results demonstrated that the combination therapy exhibited better effects in improving ER when compared with transdermal estrogen gel therapy alone. These effects may be the result of the decreased RI and PI of the uterine artery, and increased MVD produced by the combination therapy, which also exhibited greater antifibrotic effects that may reduce the re-adhesion rate over time.

For the majority patients with IUA, successfully becoming pregnant is the ultimate goal (3). The present study reported that the expression of  $\alpha v \beta 3$  and LAM was higher in tissues from the combination therapy group than in those from the

estrogen-alone therapy group. These results indicated that the combination therapy of transdermal estrogen gel and oral aspirin may enhance ER; higher ER may lead to an increased chance of success in achieving pregnancy. Previously, it had been reported that LDA exhibited a positive effect on ER and implantation in ART (32,33), which is consistent with the results reported in the present study. Ultrasound examination-revealed lower PI and RI in IUA patients with combination therapy in the present study. Previously, LDA increased uterine blood flow (34), which is also consistent with the present study. Lower RI and PI are associated with lower impedance to uterine artery blood flow, which leads to a greater blood flow to the endometrium. The anticoagulant drug aspirin has a vasodilatory effect (35) and suppresses the formation of thromboxane A without affecting prostaglandin I<sub>2</sub> (36). This may explain the reduction in PI and RI observed more significantly with the combination therapy than with estrogen-only therapy. In addition, the expression levels of CD31 and VEGF were higher in the tissues from the combination therapy group. MVD was also higher in the combination therapy group. These results indicated that combination therapy promoted angiogenesis in IUA. It has been previously reported that the use of estrogen may promote angiogenesis in IUA following surgery (4), which provides suitable conditions for endometrial repair. Aspirin has been reported to inhibit angiogenesis (18); however, the use of estrogen compensated the effect to a certain degree in the combination therapy in IUA, though, further study is required to investigate the effects of aspirin on angiogenesis, when combined with estrogen, for the treatment of IUA.

In the present study, the expression levels of fibrosis markers (TGF- $\beta$ , CTGF, COI and COIII) were lower in tissues from the combination group than from estrogen therapy.

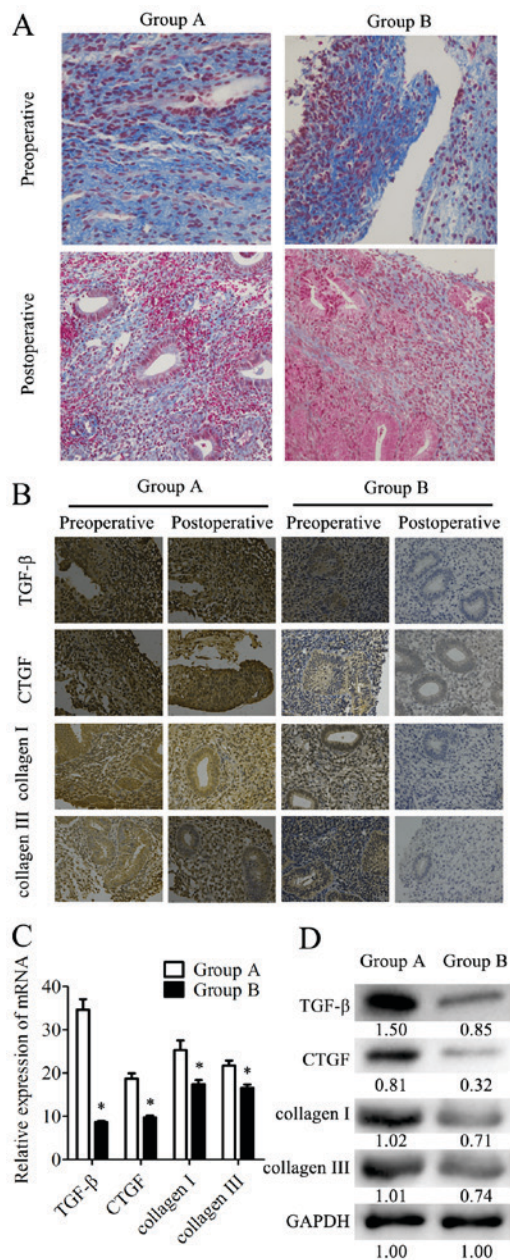


Figure 4. Fibrosis is significantly decreased in endometrium tissues within the combination therapy group following treatment. (A) Fibrosis was detected by Masson's Trichrome staining. Magnification, x200. Fibrotic areas were stained blue. (B) Expression of fibrosis markers (TGF-β, CTGF, collagen I and collagen III) was detected by immunohistochemistry. Magnification, x200. The expression of fibrosis markers in endometrial tissues was determined at the mRNA level by (C) reverse transcription-quantitative polymerase chain reaction and at the protein level by (D) western blotting. The relative quantity of proteins was calculated by comparison against the internal control (GAPDH) and noted below the bands. The postoperative tissues were obtained during the follow-up at the 20-24th day of the second menstrual cycle following transcervical resection of adhesion. Data are presented as the mean ± standard deviation. \*P<0.05 vs. group A. CTGF, CCCTC-binding factor; group A, transdermal estrogen gel therapy; group B, combination therapy of transdermal estrogen gel and oral aspirin therapy; TGF-β, transforming growth factor-β.

Accordingly, Masson's Trichrome staining demonstrated fewer fibrotic tissues in the combination therapy group. These data indicated that the combination therapy of transdermal estragon gel and oral aspirin was a more effective anti-fibrotic strategy for the management of postoperative IUA. Inflammation is

one of the causes of fibrosis (37,38). TGF-β is overexpressed in inflamed tissues and induces the TGF-β signaling pathway, which stimulates an increase of COI and COIII secretion and deposition (39). Inflammation itself results in tissue necrosis and edema, consequently leading to fibrosis during the tissue repair process. As an anti-inflammatory agent, aspirin has been reported to revert fibrosis in a chronic pulmonary murine model (40). Estrogen has been demonstrated to prevent fibrosis via suppression of the TGF-β signaling pathway in IUA (39). These findings may explain the synergy between the antifibrotic effects of aspirin and estrogen. Collectively, the combination of transdermal estrogen gel and oral aspirin is more effective in enhancing ER and preventing re-adhesion in the postoperative treatment of IUA.

However, the present study has some limitations: One potential weakness is that the present study lacked a comparison of differing methods of estrogen delivery. It was considered that first-pass elimination and the individual differences of patients may determine the uncertainty of treatment results, and provide a suitable comparison between a combination therapy of transdermal estrogen gel with oral aspirin group and a transdermal estrogen therapy group, without including different estrogen delivery schemes. Additionally, pregnancy data acquired from longer-period follow-ups are necessary in future studies to confirm whether combination therapy induces a greater prognosis in fertility. As well as the longer-term data, an IUA mice model may be constructed to confirm the findings of the present study and investigate the potential underlying mechanisms.

In conclusion, the combination of transdermal estrogen gel and oral aspirin therapy may be a better strategy than transdermal estrogen therapy alone in the treatment of IUA. For postoperative management, combination therapy is more efficacious in enhancing ER by increasing uterine blood and MVD. This may contribute to improved fertility prognoses. The findings of the present study may provide novel guidance into the clinical treatment of IUA.

#### Acknowledgements

Not applicable.

#### Funding

The present study was supported by The Foundation of Health and Family Planning Commission of Chongqing (grant nos. 2016MSXM092 and 20142099).

#### Availability of data and materials

The data sets used and/or analyzed during the current study are available from the corresponding author on reasonable request.

#### Authors' contribution

YC, LL, YL, JH, YM and LH were involved in the protocol and project development process, and the collection and/or management of the data. PH also aided the data collection/management process and performed the data analyses. YC and LH produced the manuscript, which was critically revised for important intellectual content by LH and YM.

## Ethics approval and consent to participate

The present study was approved by the Ethics Committee of Chongqing Health Center for Women and Children (Chongqing Health Center), and written informed consent was obtained from all patients prior to their inclusion in the study.

## Consent for publication

The patients or their guardians have provided written informed consent for the publication of any associated data and accompanying images.

## Competing interests

The authors declare that they have no competing interests.

## References

- Asherman JG: Amenorrhoea traumatica (atretica). *J Obstet Gynaecol Br Emp* 55: 23-30, 1948.
- Dalton VK, Saunders NA, Harris LH, Williams JA and Lebovic DI: Intrauterine adhesions after manual vacuum aspiration for early pregnancy failure. *Fertil Steril* 85: 1823, 2006.
- Deans R and Abbott J: Review of intrauterine adhesions. *J Minim Invasive Gynecol* 27: 555-569, 2010.
- Johary J, Xue M, Zhu X, Xu D and Velu PP: Efficacy of estrogen therapy in patients with intrauterine adhesions: Systematic review. *J Minim Invasive Gynecol* 21: 44-54, 2014.
- Capella-Allouc S, Morsad F, Rongieres-Bertrand C, Taylor S and Fernandez H: Hysteroscopic treatment of severe Asherman's syndrome and subsequent fertility. *Hum Reprod* 14: 1230-1233, 1999.
- AORhue AA, Aziken ME and Igbefoh JO: A comparison of two adjunctive treatments for intrauterine adhesions following lysis. *Int J Gynaecol Obstet* 82: 49-56, 2003.
- Pabuccu R, Onalan G, Kaya C, Selam B, Ceyhan T, Ornek T and Kuzudisli E: Efficiency and pregnancy outcome of serial intrauterine device-guided hysteroscopic adhesiolysis of intrauterine synechiae. *Fertil Steril* 90: 1973-1977, 2008.
- Xiao S, Wan Y, Xue M, Zeng X, Xiao F, Xu D, Yang X, Zhang P, Sheng W, Xu J, *et al*: Etiology, treatment, and reproductive prognosis of women with moderate-to-severe intrauterine adhesions. *Int J Gynaecol Obstet* 125: 121-124, 2014.
- Makker A and Singh MM: Endometrial receptivity: Clinical assessment in relation to fertility, infertility, and antifertility. *Med Res Rev* 26: 699-746, 2006.
- Simon C, Moreno C, Remohi J and Pellicer A: Cytokines and embryo implantation. *J Reprod Immunol* 39: 117-131, 1998.
- Lédée-Bataille N, Laprée-Delage G, Taupin JL, Dubanchet S, Frydman R and Chaouat G: Concentration of leukaemia inhibitory factor (LIF) in uterine flushing fluid is highly predictive of embryo implantation. *Hum Reprod* 17: 213-218, 2002.
- Giancotti FG and Ruoslahti E: Integrin signaling. *Science* 285: 1028-1032, 1999.
- Krutzsch HC, Choe BJ, Sipes JM, Guo Nh and Roberts DD: Identification of an alpha3beta1 integrin recognition sequence in thrombospondin-1. *J Biol Chem* 274: 24080-24086, 1999.
- Lessey BA, Damjanovich L, Coutifaris C, Castelbaum A, Albelda SM and Buck CA: Integrin adhesion molecules in the human endometrium: Correlation with the normal and abnormal menstrual cycle. *J Clin Invest* 90: 188-195, 1992.
- Lessey BA: Endometrial receptivity and the window of implantation. *Baillieres Best Pract Res Clin Obstet Gynaecol* 14: 775-788, 2000.
- Patrono C: Aspirin as an antiplatelet drug. *N Engl J Med* 330: 1287-1294, 1994.
- Krasopoulos G, Brister SJ, Beattie WS and Buchanan MR: Aspirin 'resistance' and risk of cardiovascular morbidity: Systematic review and meta-analysis. *BMJ* 336: 195-198, 2008.
- Cuzick J, Otto F, Baron JA, Brown PH, Burn J, Greenwald P, Jankowski J, La Vecchia C, Meyskens F, Senn HJ, *et al*: Aspirin and non-steroidal anti-inflammatory drugs for cancer prevention: An international consensus statement. *Lancet Oncol* 10: 501-507, 2009.
- Rubinstein M, Marazzi A and Polak de Fried E: Low-dose aspirin treatment improves ovarian responsiveness, uterine and ovarian blood flow velocity, implantation, and pregnancy rates in patients undergoing in vitro fertilization: A prospective, randomized, double blind placebo controlled assay. *Fertil Steril* 71: 825-829, 1999.
- Kenigsberg L, Balachandrar S, Prasad K and Shah B: Exogenous pubertal induction by oral versus transdermal estrogen therapy. *J Pediatr Adolesc Gynecol* 26: 71-79, 2013.
- Shukla A, Jamwal R and Bala K: Adverse effect of combined oral contraceptive pills. *Asian J Pharma & Clin Res* 10: 17-21, 2017.
- Vigen C, Hodis HN, Chandler WL, Lobo RA and Mack WJ: Postmenopausal oral estrogen therapy affects hemostatic factors, but does not account for reduction in the progression of subclinical atherosclerosis. *J Thromb Haemost* 5: 1201-1208, 2007.
- Johary J, Xue M, Zhu X, Xu D and Velu PP: Efficacy of estrogen therapy in patients with intrauterine adhesions: Systematic review. *J Minim Invasive Gynecol* 21: 44-54, 2014.
- Chi Y, Yang X, He P, Lei L, Yi Lan Y and Liu L: Efficiency of estradiol gel in treatment of moderate or severe intrauterine adhesion. *J Reprod Med* 25: 691-695, 2016 (In Chinese).
- Bagot CN, Marsh MS, Whitehead M, Sherwood R, Roberts L, Patel RK and Arya R: The effect of estrone on thrombin generation may explain the different thrombotic risk between oral and transdermal hormone replacement therapy. *J Thromb Haemost* 8: 1736-1744, 2010.
- American Fertility Society (1988) The American Fertility Society classifications of adnexal adhesions, distal tubal occlusion, tubal occlusion secondary to tubal ligation, tubal pregnancies, Mullerian anomalies and intrauterine adhesions. *Fertil Steril* 49, 944-955, 1988.
- Livak KJ and Schmittgen TD: Analysis of relative gene expression data using real-time quantitative PCR and the 2(-Delta Delta C(T)) method. *Methods* 25: 402-408, 2001.
- Carmeliet P and Jain RK: Angiogenesis in cancer and other diseases. *Nature* 407: 249-257, 2000.
- Al-Inany H: Intrauterine adhesions. An update. *Acta Obstet Gynecol Scand* 80: 986-993, 2001.
- Socolov R, Anton E, Butureanu S and Socolov D: The endoscopic management of uterine synechiae. A clinical study of 78 cases. *Chirurgia (Bucur)* 105: 515-518, 2010.
- Capella-Allouc S, Morsad F, Rongieres-Bertrand C, Taylor S and Fernandez H: Hysteroscopic treatment of severe Asherman's syndrome and subsequent fertility. *Hum Reprod* 14: 1230-1233, 1999.
- Schisterman EF, Gaskins AJ and Whitcomb BW: Effects of low-dose aspirin in in-vitro fertilization. *Curr Opin Obstet Gynecol* 21: 275-278, 2009.
- Zhao M, Chang C, Liu Z, Chen LM and Chen Q: Treatment with low-dose aspirin increased the level LIF and integrin beta3 expression in mice during the implantation window. *Placenta* 31: 1101-1105, 2010.
- Kang X, Wang T, He L, Xu H, Liu Z and Zhao A: Effect of low-dose aspirin on midluteal phase uterine artery blood flow in patients with recurrent pregnancy loss. *J Ultrasound Med* 35: 2583-2587, 2016.
- Lazzarin N, Vaquero E, Exacoustos C, Bertoniotti E, Romanini ME and Arduini D: Low-dose aspirin and omega-3 fatty acids improve uterine artery blood flow velocity in women with recurrent miscarriage due to impaired uterine perfusion. *Fertil Steril* 92: 296-300, 2009.
- Burch JW, Stanford N and Majerus PW: Inhibition of platelet prostaglandin synthetase by oral aspirin. *J Clin Invest* 61: 314-319, 1978.
- Kershenovich Stalnikowitz D and Weissbrod AB: Liver fibrosis and inflammation. A review. *Ann Hepatol* 2: 159-163, 2003.
- Stramer BM, Mori R and Martin P: The inflammation-fibrosis link? A Jekyll and Hyde role for blood cells during wound repair. *J Invest Dermatol* 127: 1009-1017, 2007.
- Jiang HS, Zhu LL, Zhang Z, Chen H, Chen Y and Dai YT: Estradiol attenuates the TGF-beta1-induced conversion of primary TAFs into myofibroblasts and inhibits collagen production and myofibroblast contraction by modulating the Smad and Rho/ROCK signaling pathways. *Int J Mol Med* 36: 801-807, 2015.
- Benjamin CF, Guilherme RDF, Nogueira TDO, Neves JS and Canetti CDA: Aspirin-triggered Resolvin D1, atrdv1, reverts chronic pulmonary fibrosis in a murine model pulmonary fibrosis. *American J Resp Crit Care Med* 193: A4938, 2016.



This work is licensed under a Creative Commons Attribution-NonCommercial-NoDerivatives 4.0 International (CC BY-NC-ND 4.0) License.