




Since January 2020 Elsevier has created a COVID-19 resource centre with free information in English and Mandarin on the novel coronavirus COVID-19. The COVID-19 resource centre is hosted on Elsevier Connect, the company's public news and information website.

Elsevier hereby grants permission to make all its COVID-19-related research that is available on the COVID-19 resource centre - including this research content - immediately available in PubMed Central and other publicly funded repositories, such as the WHO COVID database with rights for unrestricted research re-use and analyses in any form or by any means with acknowledgement of the original source. These permissions are granted for free by Elsevier for as long as the COVID-19 resource centre remains active.



## Review article

## COVID-19-associated psychosis: A systematic review of case reports

Colin M. Smith<sup>a,b,\*</sup>, Elizabeth B. Gilbert<sup>a,b</sup>, Paul A. Riordan<sup>b,c</sup>, Nicole Helmke<sup>a,b</sup>,  
Megan von Isenburg<sup>d</sup>, Brian R. Kincaid<sup>a,b</sup>, Kristen G. Shirey<sup>a,b</sup>

<sup>a</sup> Department of Medicine, Duke University School of Medicine, Durham, NC, USA

<sup>b</sup> Department of Psychiatry and Behavioral Sciences, Duke University School of Medicine, Durham, NC, USA

<sup>c</sup> Department of Psychiatry, Durham Veteran Affairs Medical Center, Durham, NC, USA

<sup>d</sup> Duke University Medical Center Library, Duke University Medical Center, Durham, NC, USA



## ARTICLE INFO

**Keywords:**  
COVID-19  
SARS-CoV-2  
Psychosis  
Psychiatry  
Neuropsychiatry  
Delirium

## ABSTRACT

**Objectives:** To describe the comorbidities, presentations, and outcomes of adults with incident psychosis and a history of COVID-19.

**Methods:** We completed a descriptive systematic review of case reports according to PRISMA guidelines, including cases of adult patients with incident psychosis and antecedent or concurrent COVID-19. We extracted patient demographics, comorbidities, clinical course, and outcomes, and assessed cases for quality using a standardized tool.

**Results:** Of 2396 articles, we included 40 reports from 17 countries, comprising 48 patients. The mean age of patients was 43.9 years and 29 (60%) were males. A total of 7 (15%) had a documented psychiatric history, 6 (13%) had a substance use history and 11 (23%) had a comorbid medical condition. Delusions were the most common (44 [92%]) psychiatric sign and psychosis lasted between 2 and 90 days. A total of 33 (69%) patients required hospitalization to a medical service and 16 (33%) required inpatient psychiatric admission. The majority (26 [54%]) of cases did not assess for delirium and 15 (31%) cases were judged to be of high risk of bias.

**Conclusions:** Despite the growing awareness of COVID-19's association with incident psychosis at a population level, cases of COVID-19-associated psychosis often lacked clinically relevant details and delirium was frequently not excluded.

**PROSPERO registration number:** CRD42021256746.

## 1. Introduction

Acute and persistent neuropsychiatric sequelae associated with COVID-19, the clinical disease resulting from SARS-CoV-2 infection, are common [1,2]. Although rare, cases of putative COVID-19-associated psychosis have received widespread attention in the media [3]. Questions remain concerning the legitimacy of this connection [4]. The protean causes of psychosis [5] and mortality associated with psychotic illness [6,7] warrant elucidating the relationship between COVID-19 and incident psychosis.

Psychosis has been associated with pandemic respiratory viruses for centuries [8]. A rapid review of the literature identified incident cases of psychosis linked to an infection with SARS, MERS, and influenza (H1N1) in 0.9% to 4% of infections [9]. Individual cases of COVID-19 psychosis have been reported since the outset of the COVID-19 pandemic, followed by small retrospective descriptive studies [10] and large surveillance

studies [11]. More recently, a large population level study showed an increased risk of new onset psychosis in patients with COVID-19 infections [1]. Taquet et al. conducted a retrospective cohort study using electronic health record data demonstrating an increase in incident diagnosis of psychotic disorders in the 6 months following SARS-CoV-2 infection compared to influenza infection [1]. However, newly diagnosed psychotic disorders were more common in older patients, patients hospitalized for COVID-19 and those with encephalopathy [1]. Some have hypothesized that, in addition to emergence of a new clinical entity, this association might represent diagnostic confusion between psychotic disorders and delirium, since delirium was likely under-reported in this study [12] and since psychotic disorders are often misdiagnosed in cases of delirium [13,14]. New diagnoses of psychosis might also represent emergence of undocumented mental illness, as electronic health records are limited in their ability to capture mental health diagnoses [15] and patients with psychotic disorders are at

\* Corresponding author at: Department of Psychiatry and Behavioral Sciences, Duke University School of Medicine, 2301 Erwin Road, Durham, NC 27710, USA.  
E-mail address: [colin.smith@duke.edu](mailto:colin.smith@duke.edu) (C.M. Smith).

increased risk for COVID-19 infection [16].

As others have argued, it is important to distinguish COVID-19 cases with psychotic symptoms as part of a broader syndrome (e.g., delirium) from a distinct clinical psychotic disorder related to infection [4]. Although case reports are limited in their ability to lead to causal claims, well-constructed cases often provide rich details that are absent in larger, population level studies. Systematic reviews of case reports have a role in documenting common presentations, comorbidities, and outcomes in rare diseases and generating hypotheses [17–20]. A recent review described cases of psychosis in persons with COVID-19, but this was narrative in nature and additional cases have been reported since this publication [4].

The primary objective of this descriptive systematic review of case reports is to describe the clinical comorbidities, presentations and outcomes of adults presenting with incident non-delirious psychosis after or during a SARS-CoV-2 infection and to assess the quality of reports.

## 2. Methods

### 2.1. Protocol and registration

This systematic review is reported in accordance with the Preferred Reporting Items for Systematic Reviews and Meta-Analyses (PRISMA) statement (Supplement 1) [21] and is registered in the PROSPERO online database (PROSPERO Identifier: CRD42021256746).

### 2.2. Search strategy and information sources

An academic librarian (MVI) developed a search strategy combining terms for COVID-19 and psychosis (Supplement 2) and systematically searched PubMed, PsycINFO, and Embase from inception through September 22, 2021. We also conducted backward and forward reference searches through September 2021.

### 2.3. Eligibility criteria

We included studies that met the following inclusion criteria: 1) adult patients (18 ≥ years) 2) patients with a history of documented COVID-19 infection 3) patients with incident psychosis (described by authors) after or concurrent with COVID-19 infection 4) articles identified as case reports, case series, letters to the editor, correspondences, and commentaries describing patient presentations and 5) articles written in English or any language with an English abstract to consider suitability for inclusion. We excluded cases of 1) nonadult patients 2) reports where there was no history of COVID-19 or psychosis 3) cases with a history of psychosis prior to infection 4) articles where authors determined psychosis was explained by another etiology entirely (e.g., substances or medications) 6) studies with no case description and 7) abstracts or articles that were not available as full text. We also excluded cases where authors attributed psychosis entirely to delirium, as COVID-19 is a well-established cause of delirium [22] and psychotic symptoms are common in delirium [14].

### 2.4. Study selection

Using an online systematic review software (Covidence systematic review software, Veritas Health Innovation, Melbourne, Australia), two reviewers (CS, EG) independently screened references in two successive stages after removing duplicates. Reviewers initially reviewed titles and abstracts and removed those that did not meet inclusion criteria or were not available but kept abstracts with insufficient information for full-text evaluation. Reviewers then independently evaluated full text articles and excluded those not meeting inclusion criteria or those that were unavailable. The authors resolved disagreement by discussion with a third author (PR). A physician collaborator (RR) fluent in Spanish translated the single non-English (Spanish) article available as a full text.

### 2.5. Data extraction

Pairs (PR, CS; NH, CS; EG, CS) of authors independently extracted data from articles using a standardized template. Authors extracted 1) patient demographics (i.e., patient age and sex) and study characteristics (i.e., country and year of publication) 2) comorbidities (i.e., medical, psychiatric and substance use history, and recent psychosocial stressor) 3) medical and psychiatric course of illness (i.e., presence and duration of psychiatric and medical signs and symptoms) and 4) clinical interventions (i.e., hospitalization, receipt of oxygen, intensive care admission, ECT, psychotropic and non-psychotropic medications).

### 2.6. Quality of studies

Case reports are inherently biased. However, standardized tools have been developed to assess their methodological quality in systematic reviews [23]. Therefore, two authors (CS, PR) independently assessed study quality using a standardized tool adapted from Murad et al. [23,24]. Studies were rated as having low, moderate, or high risk of bias. Because delirium is a clinically distinct but important cause of psychotic signs and symptoms, we also extracted whether authors excluded delirium in their reports and, if so, provided clinical reasoning for doing so. However, we did not include the presence or absence of a delirium evaluation in determining level of bias as this is not equally relevant in each case.

### 2.7. Data analysis

Given the descriptive nature of this review, we used descriptive statistics to report demographics and clinical characteristics, with means and standard deviation for continuous variables and frequencies and percentages for dichotomous variables. We reported duration of symptoms as a range due to inconsistent and approximate reporting of this information across studies.

## 3. Results

### 3.1. Study characteristics and patient demographics

A PRISMA flow diagram of selected studies is presented in Fig. 1. A total of 2396 references were identified, 942 duplicates were removed, and 1323 articles were excluded based on title and abstract review. The

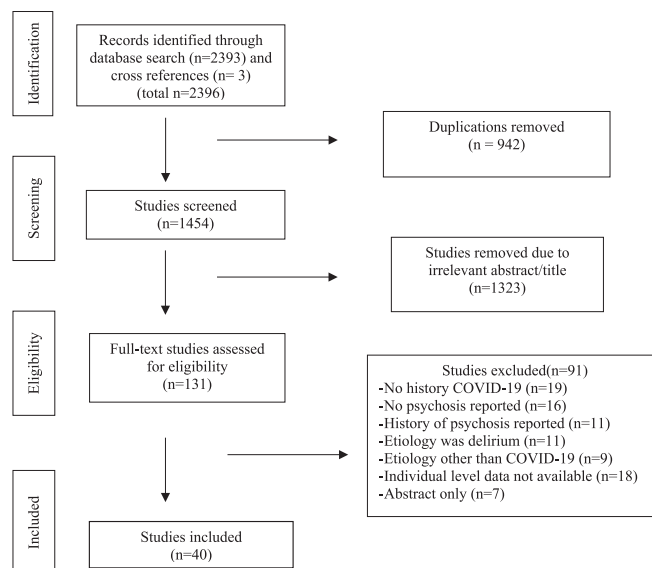


Fig. 1. PRISMA Flow Diagram.

remaining 131 articles were reviewed in full and 91 were excluded. Of excluded articles, 19 described no history of COVID-19, 16 reported no psychosis, and 11 identified premorbid psychotic symptoms. Another 11 articles attributed symptoms entirely to delirium, and 9 articles attributed symptoms to an etiology other than COVID-19. Finally, 18 articles did not include individual level data and 7 articles were available as abstracts only. A total of 40 articles met inclusion criteria, comprising 48 individual patients from 17 countries (Table 1) [25–64]. All but a single study [54] were in English and 20 (42%) cases were reported in the United States, where the largest proportion of these cases were documented. Of the 48 patient cases, 29 (60%) were male and the mean (SD) age of patients across studies was 43.9 years (11.8). A total of 7 (15%) patients had a documented history of mental illness, 6 (13%) a history of substance use and 11 (23%) a comorbid medical condition. Comorbidities for mental illness, substance use and medical conditions were not reported in 2 (4%), 12 (25%), and 14 (29%) cases, respectively (Table 2).

### 3.2. Clinical characteristics of patients with COVID-19-associated psychosis

Details of patients' clinical presentations are available in Table 1. Documented psychiatric symptoms lasted between approximately 2 and 90 days. The most common reported sign or symptom of psychosis was delusions (44 [92%]), followed by hallucinations (33 [69%]), disorganized behavior (23 [48%]), disorganized speech (12 [25%]), and catatonia (7 [15%]). Auditory hallucinations (29 [60%]) were the most common form of hallucination, followed by visual (11 [23%]) and tactile (2 [4%]) hallucinations. Mania was reported in 8 (17%) cases and depression in 4 (8%) cases (Table 3). A total of 35 (73%) patients presented with COVID-19 related physical symptoms, lasting between approximately 0 and 35 days. Respiratory symptoms were most common (26 [54%]), followed by fever (16 [33%]), neurologic symptoms (14 [29%]), and gastrointestinal symptoms (7 [15%]). Nonpsychiatric symptoms went unreported in 7 (15%) cases. (Table 3).

### 3.3. Clinical interventions

Of 48 patients, 44 (92%) were hospitalized in some capacity. A total of 33 (69%) patients were hospitalized to a medical/surgical floor (e.g., medicine or neurology), 16 (33%) to a psychiatric facility and 10 (21%) were initially admitted to a medical/floor and transferred to inpatient psychiatry. For medical treatment of COVID-19, 13 (27%) patients received oxygen and 5 (10%) were admitted to the intensive care unit. Chloroquine derivatives were prescribed in 14 (29%) cases, steroids in 9 (19%) cases, remdesivir and tocilizumab in 3 (6%) cases each, and favipiravir in 2 (4%) cases (Table 3). For psychiatric treatment, almost all (46 [96%]) patients received an antipsychotic, while 29 (60%) received a benzodiazepine, 6 (13%) received a mood stabilizer and 6 (13%) received an antidepressant and (Table 3).

### 3.4. Quality assessment

Using a standardized tool, 15 (31%) studies were determined to be high risk of bias, 16 (33%) were moderate risk and 17 (35%) were of low risk. A total of 9 (19%) cases did not adequately describe the exposure (method of COVID-19 diagnosis) and 3 (6%) cases did not adequately describe psychosis. Moreover, 29 (60%) cases did not rule out other alternative causes of psychosis and 15 (31%) cases did not cite all relevant data. Finally, 26 (54%) cases did not consider delirium and 13 (27%) considered delirium but did not describe a formal assessment. Quality assessment of individual studies is described in detail in Supplement 3.

## 4. Discussion

This descriptive systematic review identified 48 cases of incident psychosis in patients with antecedent or concurrent COVID-19. The mean age of patients in our sample was 43.9 years and medical comorbidities were present 23% of cases. Delusions were present in 92% of patients and psychiatric symptoms lasted for approximately 2 to 90 days, while nonpsychiatric symptoms for approximately 0 to 35 days. A total of 69% of patients required medical hospitalization and 33% required psychiatric hospitalization. Nearly all patients received anti-psychotic medications. Over half of reports did not consider delirium and 31% of cases were judged to be of high risk of bias. To our knowledge this is the first systematic review of COVID-19-associated psychosis cases.

Consistent with a large retrospective cohort study that showed an increased incidence of new onset psychosis in patients with COVID-19 [1], the mean age of our sample (43.9 years) was higher than expected for new onset psychosis in the general population [65]. Although this age distribution is likely skewed given that we included only adults in our sample, few cases of COVID-19-associated psychosis have been documented in the pediatric population based on our search results. This gap might also reflect underlying vulnerability in older populations to developing psychosis while medically ill [66].

Understanding comorbid medical and substance use history in individuals presenting with psychosis is clinically important since such conditions can precipitate and lengthen duration of psychosis [5,67]. Between 13% and 23% of our sample had a comorbid psychiatric, substance use or medical condition, lower than would be expected for individuals with new psychotic illness [68]. However, approximately 25% of cases did not explicitly document details on substance use or medical history.

Nearly all the patients in our sample presented with delusions and the majority presented with hallucinations at similar rates to those reported in an early retrospective descriptive study of 10 patients presenting with COVID-19 and new onset psychosis [10]. Symptoms were often self-limited in our review, consistent with findings from the Spanish influenza pandemic, where psychosis had resolved in most cases at 5-year follow up [69]. The most common nonpsychiatric symptoms in our sample were respiratory in nature, the prevalence of which was similar to those in a large systematic review of patients with COVID-19 (54% vs. 57%) [70]. Although fewer patients were medically asymptomatic in our sample compared to a large population study of patients with SARS-CoV-2 infection (13% vs 33%) [71], 15% of cases did not detail whether patients presented with nonpsychiatric symptoms.

Given the novelty and uncertainty of COVID-19-associated psychosis as a distinct diagnostic entity, we did not narrow our search to cases where authors documented that psychosis was caused only by COVID-19. Indeed, many cases provided only provisional diagnoses. Potential confounders or mediators between our exposure of interest (COVID-19) and outcome (psychosis) were common across studies. Despite excluding cases where authors attributed psychosis entirely to delirium, 77% of reports in our review either did not explicitly rule out delirium or did not describe how delirium was assessed. It is possible that delirium was not considered in many cases because patients had few physical symptoms present. Another 15% of cases reported a recent episode of delirium during the current illness and many patients received delirio-genic medications (steroids [19%], tocilizumab [6%], favipiravir [4%], chloroquine derivatives [29%] and benzodiazepines [60%]), which further confounds the relationship between COVID-19 and subsequent psychosis, although the temporal relationship between these medication receipt and symptom onset was not always clear. A total of 10% of the cases required intensive care admission, where rates of delirium are particularly high [72] and 23% of cases had visual hallucinations, a common marker of delirious psychosis [13]. Importantly, delirium commonly presents with signs and symptoms of psychosis [13,14], is common in COVID-19 [22] and might be a contributor to the increased

**Table 1**  
Details of COVID-19-associated psychosis cases.

Study reference	Age, sex, country	Psychiatric presentation	Non-psychiatric presentation	Psychiatric history	Medical history	Studies	Treatment and Outcome	Reported and approximated DSM-5 Diagnosis	Confounders/ limitations
Alba et al., 2021 [25]	40, M, ES	Sudden onset of disorganized behavior and speech, with delusions of death, mystical VH in the form of angels and demons, and the thought that he was possessed.	Flu-like symptoms	None	Not reported	“Confirmed SARS-CoV-2”. Labs otherwise reported as normal, but no values provided. CT chest showed mild pulmonary infiltrates in both lungs.	No COVID-19 treatment. Treated for psychosis with aripiprazole 5 mg and diazepam 15 mg. Psychotic symptoms improved after 1 week home psychiatric admission.	<u>Reported Dx:</u> Brief psychosis related to COVID-19 infection  <u>DSM-5 Dx:</u> Psychotic disorder due to COVID-19	No labs reported
Al-Busaidi et al., 2021 [26]	45, M, OM	Two weeks after discharge requiring mechanical ventilation for COVID-19, he jumped out of window after being commanded by God. Was noted to be agitated, suspicious and relate AH from of God.	Shortness of breath, cough fatigue, anorexia and myalgia for 3 days prior to initial admission for COVID-19 requiring ventilation.	None	None	“Tested positive for COVID-19.” CBC, CMP, thyroid studies were reported as “within normal range.” UDS was negative. CT brain and CXR with no abnormalities. “No arrhythmia [or] ischemic heart disease noted.”	During initial admission required mechanical ventilation, HCQ 600 mg BID, dexamethasone 8 mg for 5 days.  For psychosis, haloperidol and promethazine PRN, olanzapine 5 mg QHS with resolution of symptoms by 14 days.	<u>Reported Dx:</u> acute psychosis or transient psychotic disorders  <u>DSM-5 Dx:</u> Brief psychotic disorder	Recent mechanical ventilation, treatment with dexamethasone and HCQ.
Alvarez-Cisneros et al., 2021 [27]	43, M, MX	Tachylalia, disorganized ideas, restlessness, delusions of grandeur, emotional lability, and aggression towards his mother presenting 3 days after father diagnosed with COVID-19.	No symptoms	A history of hetero-aggressive episodes which usually resolved over 48 h.	None	+ SARS-CoV-2 PCR. K 3.3 mmol/L, AST 54 U/L, ALT 69 U/L, total bilirubin 2.07 mg/dL, indirect bilirubin 1.73 mg/dL, ferritin 595 ng/m. Normal CRP, ESR, PCT, fibrinogen, CSF viral PCR, Chinese ink stain. Brain MRI and CT chest unrevealing	No treatment and patient discharged home with family due to isolation protocol in the hospital and planned for outpatient follow up.	<u>Reported Dx:</u> Manic psychosis and COVID-19  <u>DSM-5 Dx:</u> Brief psychotic disorder	History of transient aggressive episodes.
Ariza-Varón et al., 2021 [28]	48, F, CO	Developed paranoid and self-referential ideas, fluctuating behavior, and inversion of sleep wake cycle 4 days after diagnosis of COVID-19. Presented with paranoid and mystical delusions and AH that she was on a “mission from God.”	History of cough, fever, malaise, and fatigue for 5 days prior to presenting for care	Borderline intellectual functioning	None	+ “antigenic” SARS-CoV-2 test. Hypoxemia and tachycardia. Lymphocytosis, normal CMP, troponin T, glucose. “High” CRP. Lung CT with opacities. Head CT normal, brain MRI showed bilateral hippocampal hyperintensities. EEG without seizure activity. LP negative for NMDA Antibodies	For COVID-19, ampicillin/sulbactam. Respiratory symptoms resolved after 3 days.  For psychosis related to suspected viral encephalitis, acyclovir, high dose methylprednisolone for 5 days. Haloperidol and lorazepam for agitation. Significant improvement even after discontinuing antipsychotics.	<u>Reported Dx:</u> Psychosis associated with probable encephalitis associated with SARS-CoV-2  <u>DSM-5 Dx:</u> Psychotic disorder due to autoimmune encephalitis	History of borderline intellectual functioning and “thinking with a high level of pervious mysticism.”  Receipt of ampicillin/sulbactam before onset of symptoms.
Austgen et al., 2021 [29]	52, F, US	Insomnia and anxiety after receiving steroids for “mild COVID-19,” which progressed to paranoia and depression over 1 month requiring hospitalization. Again hospitalized 48 h later for suicidal thoughts,	Mild upper respiratory symptoms	None	HTN, T2DM	+ SARS-CoV-2 PCR. MRI brain, EEG, Smith Ab, DNA Ab, SS-A and SS-B, ANA, RF, Anti-TPO, C4, C3), CSF (SARS-CoV-2, JCV, West Nile, encephalitis panel) were negative or normal. CSF IgG was mildly elevated (4.15). Elevated ferritin (238 ng/mL),	For COVID-19, prednisone 1 month prior to admission.  During initial admission, methylprednisolone 1 g for 5 days, escitalopram 10 mg for 3 days, sertraline 100 mg for 5 days, risperidone 3 mg for 8 days, aripiprazole 15 mg for 10 days, olanzapine 15 mg for	<u>Reported Dx:</u> psychosis and depression; catatonia  <u>DSM-5 Dx:</u> Psychotic disorder due to COVID-19, with delusions; catatonia due to COVID-19	Recent treatment with steroids preceding psychosis.

(continued on next page)

Table 1 (continued)

Study reference	Age, sex, country	Psychiatric presentation	Non-psychiatric presentation	Psychiatric history	Medical history	Studies	Treatment and Outcome	Reported and approximated DSM-5 Diagnosis	Confounders/ limitations
Baral et al., 2021 [30]	53, M, US	psychomotor slowing, paranoia and catatonia. After 5 weeks of COVID-19, he experienced delusional thoughts that people, including his wife, were plotting to kill him.	Fever, cough and weakness for 2 days	None	None	CRP (1.35 mg/dL), ESR (34 mm/h) and IL-6 (pg/mL). + SARS-Cov-2 PCR. Normal EKG, CMP, CBC, UDS, HIV, RPR, LDH, D-dimer, TSH, UA, troponin, INR, LFTs, B12, folate. Ferritin 400.9 ng/mL. Normal CXR and CT head.	10 days. During readmission, olanzapine 10 mg, sertraline 100 mg, ECT and lorazepam. Recovered by day 47. Symptoms improved within 24 h of “coping skills” from consult service and receipt of haloperidol 5 mg.	<u>Reported Dx:</u> Brief psychotic disorder post-COVID-19  <u>DSM-5 Dx:</u> Brief psychotic disorder, with marked stressor	Social isolation and fear over 5 weeks preceding psychotic symptoms.
Caan et al., 2020 [31]	43, M, US	Two weeks after upper respiratory symptoms and fever, presented with anxiety about possible COVID-19, insomnia, staring, poor self-care and delusions about “the devil” and AH. After admission, holding abnormal posture, hovering feet above bed and held arms in decorticate posture.	Headache, fever, shortness of breath, cough, weakness, and back pain	None	None	+ SARS-CoV-2 PCR. Tachycardic and hypertensive. ALT 281 U/L, AST 79 U/L, INR 1.5. Normal hemoglobin, WBC, TFTs, serum drug screen, lactic acid, PCT, glucose. CXR and CT head normal. LP with negative gram stain; 2 red cells/uL, 1 white cell/uL, protein of 23 mg/dL and glucose of 69 mg/dL.	For COVID-19, azithromycin, albuterol, benzonatate for cough and methocarbamol for pain.  For catatonia, lorazepam 1 mg QID and then tapering to 1 mg with good clinical response with only residual psychomotor retardation.	<u>Reported Dx:</u> Catatonia associated with acute COVID-19; Brief psychotic disorder  <u>DSM-5 Dx:</u> Catatonia due to COVID-19; Brief psychotic disorder with stressor	Authors suspected delirium likely impacted catatonic presentation.  Significant stress about possibly having COVID-19 prior to + test.
Chacko et al., 2020 [32]	52, M, US	One week of decreased speech, delusions that he caused the COVID-19 pandemic.	None	None	OSA	-SARS-CoV-2 PCR, +IgG. Elevated LFTs (no values provided), ESR 40 mm/h, CRP 1.5 mg/L, D-dimer 1003 µg/mL. UA reported to be consistent with dehydration. CT chest consistent with multifocal pneumonia.	Ceftriaxone and azithromycin for infection and lorazepam 1 mg BID, fluoxetine 20 mg, olanzapine 5 mg BID, sertraline 100 mg, clonazepam 0.25 mg BID, trazodone 50 mg po QHS and ECT for psychosis.	<u>Reported Dx:</u> COVID-19-induced psychosis  <u>DSM-5 Dx:</u> Psychotic disorder due to COVID-19, with delusions	No CSF labs
DeLisi, 2021 [33]	34, M, US	Paranoid delusions that the world would end soon, hyper religiosity and grandiosity that he was on a special mission to help God. Fear led him to consider jumping off a bridge.	Headache	Alcohol misuse	None	“Positive for SARS-CoV-2.” Normal CMP, CK, IgG, IgM, herpes ab, ANA, thyroid hormone. CXR and CT head normal. MRI scan showed a few punctate nonspecific hyperintense foci in the right centrum semiovale.	Improved after 6 ECT sessions. No COVID-19 treatment. Psychosis treated with risperidone 4 mg.  Eventually improved and discharged from psychiatric hospital with risperidone.	<u>Reported Dx:</u> COVID-Schizophreniform illness  <u>DSM-5 Dx:</u> Psychotic disorder due to COVID-19, with delusions	Recent significant social stressors (job loss and isolation), and heavy drinking that escalated over 2 months.
Desai et al., 2021 [34]	55, F, US	3 weeks after a medical admission for COVID-19, presented with pressured speech and AVH of God asking her to save the earth.	Symptoms not reported but had recent admission 3 weeks prior for COVID-19 requiring oxygen, steroids and remdesivir.	None	HTN, T2DM, Obesity	Reported COVID-19 3 weeks prior. - SARS-CoV-2 PCR on admission. HR. 130 bpm. BP 147/119. LDH 825 units/L, WBC 4500 cells/mm3. “Infectious disease work-up negative.” MRI and CT brain unrevealing. UDS negative.	For COVID-19, steroids, oxygen and remdesivir weaned off before admission to psychiatry.  For psychosis, haloperidol, diphenhydramine and lorazepam for agitation	<u>Reported Dx:</u> New-onset psychosis following COVID-19 infection  <u>DSM-5 Dx:</u> Psychotic disorder due to COVID-19 vs.	Recent treatment with steroids and remdesivir  Family history of bipolar disorder and psychosis due to steroids

(continued on next page)

Table 1 (continued)

Study reference	Age, sex, country	Psychiatric presentation	Non-psychiatric presentation	Psychiatric history	Medical history	Studies	Treatment and Outcome	Reported and approximated DSM-5 Diagnosis	Confounders/ limitations
Elfil et al., 2021 [35]	20, F, US	Insomnia and panic attacks progressed over a 2-weeks, leading to disorganized thoughts, paranoia, flight of ideas, forgetfulness, and VH of her recently deceased grandmother.	Fatigue	None	Mild intermittent asthma and atopic dermatitis	+ SARS-CoV-2 PCR. Normal UDS, BAC, CSF, heavy metals, meningitis panel, HIV, <i>treponema pallidum</i> , CBC, ESR, CRP, CK, TSH, folic acid, B12, CSF, AIE panel. EEG, CT/MRI head normal.	followed by aripiprazole 10 mg daily and valproate 1000 mg daily with improved symptoms by 14 days. Quetiapine and high dose lorazepam.  Discharged home on lorazepam taper for catatonia.	substance/medication-induced psychotic disorder  <u>Reported Dx:</u> COVID-19-induced Psychosis; Hyperactive catatonia  <u>DSM-5 Dx:</u> Psychotic disorder due to COVID-19, with hallucinations; Catatonic disorder due to COVID-19	Labs for infectious evaluation not reported SARS-CoV-2 infection was 2 weeks prior.
Faisal et al., 2021 [36]	48, M, ID	Anxiety with AVH, followed by depression during confinement.	Dyspnea and dry cough on day of admission with fever 5 days prior. Nausea, vomiting and diarrhea 10 days prior to admission.	None	None	+SARS-CoV-2 PCR. Elevated D-dimer (2360 mg/L), fibrinogen (408 mg/dL), CRP (30 mg/L), ferritin and LFTs (ALT 106 U/L, AST 56 U/L), lymphopenia (17%). CT brain normal, CXR with multifocal ground glass opacity.	For COVID-19, oseltamivir, HCQ, azithromycin and vitamin C. For psychosis, haloperidol on day 1 and 2 as needed and risperidone and lorazepam  Symptoms resolved by day 13.	<u>Reported Dx:</u> Brief psychotic disorder  <u>DSM-5 Dx:</u> Brief psychotic disorder, with marked stressor	Received HCQ, but after symptoms started.  No CSF labs.
Ferrando et al., 2020 [37]	30, M, US	Bizarre behavior, anxiety, suicidal ideation, agitation AH of people who were chasing him, decreased sleep, and potomania.	None	None	Not reported	“Positive for COVID-19.” CRP 0.67 mg/dL, ferritin 421 µg/L. CBC, CMP normal. CT head, CXR normal.	No treatment for COVID-19. Quetiapine for psychosis.  Improved after 4 days of quetiapine 25 mg.	<u>Reported Dx:</u> Psychosis associated with COVID-19  <u>DSM-5 Dx:</u> Psychotic disorder due to COVID-19, with hallucinations	Limited history available.
Ferrando et al., 2020 [37]	34, F, US	Inattention, pressured speech, disorganization, and agitation. Focused on “fire burning up inside” and migratory numbness and tingling.	None	Panic disorder	Not reported	“COVID-positive.” WBC 2.8 k/mm <sup>3</sup> , CRP 1.89 mg/dL, ferritin, and CMP normal. CT head, CXR normal.	Lorazepam, aripiprazole, and clonazepam for psychosis. HCQ and azithromycin for COVID-19.  Improved after admission.	<u>Reported Dx:</u> Psychosis associated with COVID-19  <u>DSM-5 Dx:</u> Psychotic disorder due to COVID-19, with hallucinations	History of panic disorder diagnosis.
Ferrando et al., 2020 [37]	33, M, US	Persecutory delusions and AH of ex-wife and others outside trying to kill him for 4 days.	None	Opioid use disorder	Not reported	“COVID-19 positive.” CRP 1.9 mg/dL, ferritin, D-dimer, CBC and CMP reported as normal. CT head and CXR normal.	Quetiapine for psychosis.  Transferred out of psychiatric unit.	<u>Reported Dx:</u> Psychosis associated with COVID-19  <u>DSM-5 Dx:</u> Psychotic disorder due to COVID-19, with hallucinations	On Methadone for OUD.
Gillet et al., 2020 [38]	37, M, UK	Insomnia, concern about infecting his family, preoccupation with biblical passages, and reports of seeing the devil.	Five-day history of fever, cough, SOB myalgia, and severe insomnia.	None	None	+ SARS-CoV-2 PCR. Leukocytosis with lymphopenia. Normal CRP, BMP, UDS. CSF/serum autoimmune markers normal.	Prolonged ICU admission for surgical wounds with difficulty weaning from sedation for COVID-19. Olanzapine and diazepam for	<u>Reported Dx:</u> Delirium vs. single acute psychotic episode vs. manic episode	Occupation as a healthcare worker may have contributed to his presentation.

(continued on next page)

Table 1 (continued)

Study reference	Age, sex, country	Psychiatric presentation	Non-psychiatric presentation	Psychiatric history	Medical history	Studies	Treatment and Outcome	Reported and approximated DSM-5 Diagnosis	Confounders/ limitations
		He was responding internally to AH and lacerated own neck.				CT head normal. CT chest with pneumomediastinum and ground glass opacifications	psychosis. Psychosis resolved on transfer to floor.	<u>DSM-5 Dx:</u> Delirium due to COVID-19 acute, hyperactive vs. Psychotic disorder due to COVID-19, with hallucinations	Family history of psychotic episodes. Possible concomitant delirium.
Haddad, et al. 2020 [39]	30, M, QA	Developed anxiety after positive COVID-19 test, followed by paranoid delusions and AH 1 week later.	Mild symptoms of COVID-19 were anosmia and ageusia	Anxiety	None	+SARS-CoV-2 PCR. Normal CBC/CMP. Ferritin 623 µg/L, CRP normal (<5 mg/L). CRP 12.3 mg/L prior to illness. CXR, CT brain normal	Azithromycin, ceftriaxone and HCQ. Lorazepam 1 mg QID, mirtazapine 30 mg QHS, risperidone 1 mg BID x 4 weeks.  Discharge from hospital after 3.5 weeks.	<u>Reported Dx:</u> Brief psychotic disorder with marked stressor (brief reactive psychosis)  <u>DSM-5 Dx:</u> Brief psychotic disorder, with marked stressor	Received HCQ early in his course.
Huarcaya-Victoria et al., 2020 [40]	23, F, PE	After COVID-19 diagnosis presented with insomnia, incoherent speech, reports of hearing voices calling her and religious delusions.	Fever	None	Not reported	“Positive IgM/IgG antibodies against COVID-19.” Normal CBC	For psychosis, IV midazolam, ziprasidone 40 mg, olanzapine 15 mg. For COVID 19, none reported.  Discharged from hospital after 9 days with no symptoms.	<u>Reported Dx:</u> Acute psychotic disorder  <u>DSM-5 Dx:</u> Brief psychotic disorder, with marked stressor	Limited details provided.
Huarcaya-Victoria et al., 2020 [40]	38, F, PE	Presented with 2 weeks of insomnia, 1 week of increased speech quantity and 3 days of mystical religious delusions.	Not reported	Depression	Not reported	“Positive IgM/IgG antibodies against COVID-19.” Normal CBC. CRP 6 mg/L	Ziprasidone 20 mg, olanzapine 20 mg, VPA 1000 mg/day, 1 mg/day clonazepam for psychosis. No treatment for COVID-19 reported.  Discharge after 10 days with remission of psychotic symptoms.	<u>Reported Dx:</u> Acute psychotic disorder  <u>DSM-5 Dx:</u> Brief psychotic disorder, without marked stressor	History of affective disorder. Limited details provided.
Huarcaya-Victoria, et al., 2020 [40]	47, F, PE	Presented with 4 months of grief following mother’s death and 3 weeks of command AH, delusions, and suicide attempts.	Not reported	None	Not reported	“Positive IgM/IgG antibodies against COVID-19”. WBC 5.1, Hbg 13.9 g/dL, Plt 384 × 10 <sup>9</sup> /L, CRP 1.5 mg/L.	Haloperidol 15 mg, quetiapine 300 mg/day, 50 mg/day sertraline, VPA 500 mg/day for psychosis. No treatment for COVID-19 reported.  Discharged from hospital after 10 days with remission of psychosis and suicidal ideation.	<u>Reported Dx:</u> Acute psychotic disorder  <u>DSM-5 Dx:</u> Brief psychotic disorder, with marked stressor	Recent death of mother with antecedent depressed mood.
Jaworowski et al., 2020 [41]	Not reported, M, IL	Acutely psychotic with grandiose and religious delusions.	Mild respiratory symptoms	None	Not reported	“Tested positive for COVID-19.” No other labs reported.	IM haloperidol and lorazepam for psychosis. None reported for COVID-19.  Recovery of psychosis over 2 days.	<u>Reported Dx:</u> Brief psychotic disorder  <u>DSM-5 Dx:</u> Brief psychotic disorder	Limited case details.  Limited case details.

(continued on next page)



Table 1 (continued)

Study reference	Age, sex, country	Psychiatric presentation	Non-psychiatric presentation	Psychiatric history	Medical history	Studies	Treatment and Outcome	Reported and approximated DSM-5 Diagnosis	Confounders/ limitations
Jaworowski et al., 2020 [41]	Not reported, M, IL	Psychotic with grandiose and religious delusions.				“Tested positive for COVID-19.” No other labs reported.	IM olanzapine and lorazepam for psychosis. None reported for COVID-19.  Recovery of psychosis over 2 days without any further meds.	<u>Reported Dx:</u> Brief psychotic disorder  <u>DSM-5 Dx:</u> Brief psychotic disorder, with marked stressor	
Jaworowski et al., 2020 [41]	Not reported, M, IL	Psychosis with paranoid, grandiose and religious delusions.	Fever and cough	Daily cannabis use	Not reported	“Tested positive for COVID-19.” No other labs reported.	IM haloperidol and lorazepam for psychosis. None reported for COVID-19.  Recovery of psychosis over 2 days.	<u>Reported Dx:</u> Brief psychotic disorder  <u>DSM-5 Dx:</u> Brief psychotic disorder	Ongoing substance use.  Limited case details.
Kashaninasab et al., 2020 [42]	25, M, IR	Irritable mood, claiming to communicate with God, laughing to himself, walking down the street naked.	Respiratory symptoms	Not reported	Not reported	“COVID disease.” CT chest with “possible COVID-19”. Normal CT brain after ECT.	HCQ prior to admission and Lopinavir-ritonavir 400 mg BID on admission for COVID-19. For psychosis, haloperidol 20 mg, chlorpromazine 100 mg, VPA 1500 mg and ECT.  Psychotic and mood symptoms improved after 6 session ECT.	<u>Reported Dx:</u> Bipolar I disorder, current episode manic, severe, with psychotic features  <u>DSM-5 Dx:</u> Bipolar I disorder, current episode manic, severe, with mood congruent psychotic features	Received HCQ but after symptoms started.  Limited case details.
Kazi et al., 2021 [43]	49, F, US	Admitted to psychiatry with 2 weeks of thoughts of jumping in front of a train, weight loss, agitation, guilt about her grandmother’s death 40 years ago and “paranoid delusions.”	3-week history of intermittent cough and anorexia.	None	None	“Tested positive for SARS-CoV-2.” CBC, glucose, BMP, LFTs, TFTs normal. UA with moderate leukocytes, + ketones. Urine microscopy with few bacteria, 25–50 white cells, 5–10 red cells. UDS, lithium, carbamazepine, and valproic acid levels were negative. CXR, EKG and CT head unremarkable.	For COVID-19, azithromycin PO and hydroxychloroquine PO for 5 days.  Psychosis initially treated with aripiprazole 7 mg and lorazepam 2 mg, but changed to olanzapine 25 mg. Depression treated with escitalopram 20 mg and mirtazapine 15 mg with discharge at 21 days. Olanzapine stopped as outpatient due to akathisia and readmitted 8 months later with mania for 21 days.	<u>Reported Dx:</u> Psychosis related to COVID-19  <u>DSM-5 Dx:</u> Psychotic disorder due to COVID-19, with delusions	Recently stopped working and had a breakup with her partner 2 months before admission.
Kazi et al., 2021 [43]	56, F, US	Hallucinations and bizarre delusions “talking about numbers on the wall” prior to admission. While admitted, had AVH that God was speaking with her, and “inflated self-esteem.”	Presented with 2 weeks of dyspnea, chills and cough in the setting of positive SARS-CoV-2 test, requiring admission for acute hypoxic respiratory failure.	None	T2DM (A1c 14.4), HTN	“Tested positive for SARS-CoV-2 infection.” Hypoxemia. CRP, ESR, D-Dimer “elevated.” A1c 14.4. UDS, RPR, HIV negative. QTc 550 ms. CXR with consolidation. CT angiogram of chest with pulmonary infiltrates. CT head normal.	Received high flow O2, vitamin C, vitamin D, zinc, monoclonal antibody, tocilizumab, dexamethasone (10 days), remdesivir (5 days).  For neuropsychiatric symptoms, received aripiprazole 5 mg and olanzapine 5 mg.	<u>Reported Dx:</u> Psychosis related to COVID-19  <u>DSM-5 Dx:</u> Psychotic disorder due to COVID-19, with hallucinations	Ongoing acute hypoxic respiratory failure  Received multiple deliriogenic medications.
	52, M, QA			None					

(continued on next page)

Table 1 (continued)

Study reference	Age, sex, country	Psychiatric presentation	Non-psychiatric presentation	Psychiatric history	Medical history	Studies	Treatment and Outcome	Reported and approximated DSM-5 Diagnosis	Confounders/ limitations
Khatib et al., 2021 [44]		Re-presented to hospital with physical aggression and grandiose delusions that he was a “master of yoga” after discharge for COVID-19 delirium.	Fever and respiratory symptoms on day 8.		Seizure disorder, T2DM	+ SARS-CoV-2 nasopharyngeal swab. Ferritin 1293 ng/mL, LDH 407 U/L, CRP 309 mg/dL, Na nadir of 123 mmol/L. CT brain normal. MRI brain with subtle white matter changes.	Azithromycin, cefuroxime, HCQ, dexamethasone, quetiapine and for COVID-19. Risperidone and clonazepam during 2nd hospitalization for psychosis.  Improved after 3-week psych hospitalization and discharged on risperidone 2 mg.	<u>Reported Dx:</u> Bipolar disorder associated with COVID-19; Acute confusional state  <u>DSM-5 Dx:</u> Bipolar and related disorder due to COVID-19, with mood congruent psychotic features; Delirium, acute, hyperactive, due to COVID-19	Received HCQ and steroids.  Hyperthyroid and recent hyperactive delirium requiring ICU.  No CSF labs.
Kozato et al., 2021 [45]	50, M, UK	After discharge from COVID admission on oral steroids, developed anxiety, insomnia, tactile visual and auditory hallucinations, and eventually developed head banging and physical agitation.	Patient was admitted with hypoxia and breathlessness requiring ICU admission.	None	T2DM, NAFLD, HTN	+SARS-CoV-2 PCR. Normal CRP, and WBC. CXR with bilateral patchy consolidations, CT with fibrosis and organizing pneumonia. MRI brain normal.	Dexamethasone, remdesivir, tocilizumab, amoxicillin, clarithromycin, and Piperacillin-Tazobactam for COVID-19. Risperidone for psychosis.  Self-harm resolved when psychosis improved.	<u>Reported Dx:</u> Acute and transient psychotic disorder/ brief psychotic disorder with stressor  <u>DSM-5 Dx:</u> Brief psychotic disorder, with marked stressor	Occurred in the setting of steroids and after ICU admission.
Kumar et al., 2021 [46]	62, F, IN	Fearfulness, AH, violence and calling people to report family plotting against her.	Not reported	Depression	Not reported	Not reported	For psychosis, Risperidone 0.5 mg BID, and lorazepam 1 mg QHS, leading to complete recovery.	<u>Reported Dx:</u> New onset psychosis in the post-COVID recovery period  <u>DSM-5 Dx:</u> Psychotic disorder due to COVID-19, with hallucinations	History of depression.  Limited case details.
Lanier et al., 2020 [47]	58, M, US	Confusion, aggressive behavior, disorganized speech, and hallucinations.	Cough, body aches, chills, nausea, and vomiting.	Panic disorder, alcohol, and cocaine use	CAD, HCV, liver disease	+SARS-CoV-2 PCR. ALT 114 U/L, AST 126 U/L, ammonia 40 µmol/L, WBC 2.4, UDS/ BAC neg. CRP 6.5 mg/L, ferritin 110 ng/mL, CK 723 IU/L. CT brain with no acute intracranial processes. Liver US with ascites	Haloperidol and lorazepam for psychosis. HCQ and supportive care for COVID-19.  Symptoms resolved with antipsychotic and benzodiazepine.	<u>Reported Dx:</u> Psychosis (unspecified)  <u>DSM-5:</u> Psychotic disorder due to COVID-19, with hallucinations	Antecedent hepatic encephalopathy, severe sepsis.
Lim et al., 2020 [48]	55, F, UK	Readmitted 2 days after medical discharge with new onset delusions, hallucinations, agitation, and disorientation.	Fever, myalgia, cough, dyspnea, loss of taste/smell and headache.	None	History of renal calculi	“Nasopharyngeal swab positive for COVID-19.” CRP 121.2 mg/L, D-dimer 1200 µg/L, fibrinogen 7.28 g/L, ferritin 1291 µg/L, TNF-alpha 6.47 pg/mL. paraneoplastic Ab negative, HIV, syphilis, TSH, B12 wnl. CSF <1 WBC, protein 0.18 g/L. CT chest with bilateral ground-glass opacities. MRI brain and. EEG normal.	Lorazepam, haloperidol, and risperidone for psychosis. Treated symptomatically with fluids and oxygen for COVID-19.  Discharged after 20-day psychiatric hospitalization with full remission of psychiatric symptoms by day 52.	<u>Reported Dx:</u> Persistent psychotic symptoms following a COVID-19 infection  <u>DSM-5 Dx:</u> Psychotic disorder due to COVID-19, with hallucinations	Recent episode of delirium.

(continued on next page)

Table 1 (continued)

Study reference	Age, sex, country	Psychiatric presentation	Non-psychiatric presentation	Psychiatric history	Medical history	Studies	Treatment and Outcome	Reported and approximated DSM-5 Diagnosis	Confounders/ limitations
Lorenzo-Villalba et al., 2020 [49]	33, F, FR	Presented with 1 day of AH, disrupted sleep and disorganized speech, after being found nude in a building basement.	None	None	None	WBC $22.3 \times 10^3$ cells/ $\mu$ L, CRP 98 mg/L. ABG with pO <sub>2</sub> 72 mmHg. Urine/serum tox negative. CT brain normal. CT chest with ground-glass opacities.	Olanzapine 10 mg daily for psychosis. Treated with supplemental oxygen for 7 days for COVID-19.  Oxygen requirement resolved by day 7 and psychosis resolved by day 14.	<u>Reported Dx:</u> First episode of psychosis probably triggered by SARS-CoV-2 infection  <u>DSM-5 Dx:</u> Psychotic disorder due to COVID-19, with hallucinations	Limited case details.
Majadas et al., 2020 [50]	63, M, ES	Persistent delirium after COVID 19 admission and was readmitted with delusions and AH.	Respiratory symptoms	None	None	+SARS-CoV-2 PCR. Elevated D dimer. CT angiography showed a low-risk pulmonary embolism. MRI brain normal.	COVID-19 was treated with lopinavir-ritonavir, tocilizumab, HCQ, and 3 days of steroids. Psychosis treated with risperidone to 6 mg daily.  Psychotic symptoms resolved during hospitalization.	<u>Reported Dx:</u> Psychotic disorder due to another medical condition  <u>DSM-5 Dx:</u> Psychotic disorder due to COVID-19, with hallucinations	Recent episode of delirium  No CSF studies.
Makivic, 2021 [51]	46, M, AT	On day 21 of symptoms, patient developed hallucinations and discharged on risperidone, then readmitted a few hours later with suspected psychogenic seizures.	Cough hemoptysis, headache, dysgeusia, vomiting and diarrhea on home quarantine.	None	obesity	+SARS-CoV-2 PCR. D-dimer 17 mg/L, LDH 267 u/L, elevated CRP. CT angiography with pulmonary embolism. MRI and CT brain normal.	Risperidone, lorazepam, valproic acid and quetiapine for psychosis. Enoxaparin and edoxaban for pulmonary embolism and ceftriaxone for COVID-19.  Improvement in psychotic symptoms by 1 month outpatient follow up.	<u>Reported Dx:</u> Acute psychosis  <u>DSM-5 Dx:</u> Psychotic disorder due to COVID-19, with hallucinations	Concurrent massive pulmonary embolism.
McAlpine et al., 2021 [52]	30, M, US	Developed erratic sleep, disorganized speech, and religious delusions, eventually presenting to emergency department on day 22 for aggression and discharged with haloperidol, only to represent on day 34 with anxiety and aggression.	Fever and malaise	None	None	+SARS-CoV-2 PCR. UDS negative. CSF with no WBC, protein 41.2 mg/dL, no oligoclonal bands, but elevated CSF IgG 4.8 mg/dL. AIE panel negative. Ferritin 1124 ng/mL, D dimer 1.90 mg/L, TSH 2.52 uIU/mL, CRP 1.7 mg/L. CT and MRI brain unrevealing. 12-h EEG normal.	For psychosis, initially treated with haloperidol and then lorazepam. Treated with IVIG 2 g/kg over 3 days on day 35. For COVID-19, received supportive treatment.  He had improvement in cognitive and psychotic symptoms on day 1 after IVIG and was discharged without antipsychotics.	<u>Reported Dx:</u> COVID-19-associated autoimmune subacute psychosis  <u>DSM-5 Dx:</u> Psychotic disorder due to autoimmune encephalitis, with delusions	Presence of novel neuronal antibody.
Mirza et al., 2020 [53]	53, M, US	Suicide attempt by drinking bleach, responding to internal stimuli, auditory hallucinations telling him to harm himself.	Tachycardia, fever, rigors, and hypoxic respiratory failure due to pneumonia.	None	None	+SARS-CoV-2 PCR. Elevated BUN and transaminases but not reported. CT scan head within normal limits.	Olanzapine 5 mg intramuscular x3 over course of stay for psychosis. Ceftriaxone, azithromycin, HCQ and supplemental oxygen for COVID-19.  Back to baseline by discharge	<u>Reported Dx:</u> Delirium vs. stress-induced "reactive" psychosis  <u>DSM-5 Dx:</u> Delirium, acute, hyperactive, due to COVID-19 vs. Brief psychotic disorder	Possible subsyndromal delirium responsible for symptoms.  Lab values not reported.
	43, M, ES		Not reported	None	None	+ SARS-CoV-2 PCR. Hemoglobin, renal function,	Olanzapine 10 mg for 2 weeks for psychosis. COVID-19	<u>Reported Dx:</u> Brief reactive psychosis	Isolation due to quarantine.

(continued on next page)

Table 1 (continued)

Study reference	Age, sex, country	Psychiatric presentation	Non-psychiatric presentation	Psychiatric history	Medical history	Studies	Treatment and Outcome	Reported and approximated DSM-5 Diagnosis	Confounders/ limitations
Mollà Roig et al., 2021 [54]		Paranoid delusions of being spied on at home through his WIFI.				liver function CRP, normal. Qualitative urine toxin negative.	treatment not reported.  Improvement after 1 week and resolution by 4 months.	<u>DSM-5 Dx:</u> Brief psychotic disorder, with marked stressor	Inflammatory markers not assessed.
Noone et al., 2020 [55]	49, M, US	One week of insomnia and odd statements, oriented only to year, AH, grandiose delusions, passive suicidal ideation and affective lability.	Anorexia	None	HTN, T2DM, HLD	+ “for COVID-19.” Ferritin 1289 ng/mL, D-dimer 20 mg/L. CSF unremarkable. MRI and EEG normal.	Haloperidol 2 mg PRN and olanzapine 2.5 mg, followed by quetiapine 150 mg for psychosis. For COVID-19, received azithromycin.  Improvement over next 2.5 weeks with meds tapered off with residual speech latency and psychomotor slowing	<u>Reported Dx:</u> New onset psychosis and mania  <u>DSM-5 Dx:</u> Psychotic disorder due to COVID-19, with delusions	Receipt of multiple antibiotics prior to presentation.
Noone et al., 2020 [55]	34, F, US	Bizarre behavior (disrobing in front of strangers), insomnia, persecutory delusions about landlord and belief she was being watched.	Shortness of breath	None	None	“SARS-CoV-2 remained positive.” CSF: Negative for HIV, HSV, VDRL, enterovirus PCR, oligoclonal bands, cryptococcal antigen, fungal and bacterial cultures. Autoimmune panel negative. Negative UDS. MRI with nonspecific T2 hyperintensities, and EEG with focal cerebral dysfunction (R > L).	Risperidone 1 mg for psychosis and acyclovir for possible encephalitis. No specific treatment for COVID-19 mentioned.  Initially sent home, with 4 presentations to emergency department, and then admitted to medicine, transferred to inpatient psychiatry for a week with symptom resolution.	<u>Reported Dx:</u> New onset psychosis and mania  <u>DSM-5 Dx:</u> Psychotic disorder due to COVID-19, with delusions	EEG with focal cerebral dysfunction.
Panariello et al., 2020 [56]	23, M, IT	Hospitalized after 3 days of psychotic symptoms, including thought disorganization, persecutory delusions and command auditory hallucinations,	Diagnosed with COVID-19, complicated by fever and oxygen desaturation.	Substance use disorder (THC, cocaine and PCP)  Other psychiatric history not reported	None	“SARS-CoV-2 infection.” Fever and desaturation to 90%. CBC, CMP “unremarkable.” Alcohol negative. UDS + THC. CXR/CT chest with opacities. CT head normal. EEG with theta activity at 6 Hz, no asymmetry. First LP with no CNS infection. After decline, CSF autoimmune panel showed NMDA receptor antibodies. IL-6 elevated (39 pg/mL). SARS-CoV-2 negative.	For COVID-19, received HCQ and darunavir/cobicistat.  For psychosis, was initially treated with haloperidol, promazine and intranasal midazolam, intramuscular aripiprazole, and oral quetiapine with no benefit. Valproate for seizure prophylaxis. High doses of dexamethasone and IVIG were administered at 4 weeks for NMDAR encephalitis with clinical improvement.	<u>Reported Dx:</u> Anti-NMDAR encephalitis associated to immunoreactivity related to SARS-CoV-2  <u>DSM-5 Dx:</u> Psychosis due to autoimmune encephalitis	Active substance use
Parker et al., 2021 [57]	57, M, US	Psychomotor agitation, acute fearfulness, nonsensical thought process with loose associations, response to internal stimuli with paranoid delusions that wife poisoning him.	Recently recovered from a mild cough, nasal congestion, anosmia and dysgeusia	None	T2DM, HTN, CAD	+SARS-CoV-2 PCR. UDS negative, CRP 0.46 mg/dL. Blood glucose >300 mg/dL, normal renal function. UA and urine culture normal. ESR 9 mm/h and CRP 4.6 mg/L. Ammonia, HIV, RPR, TSH, B12, ANA, beta-hydroxybutyrate, serum heavy meatal normal. CSF	For psychosis, received haloperidol and lorazepam in the emergency department followed by aripiprazole titrated to 20 mg and then cross-tapered to risperidone 6 mg daily.  Improvement after a few days of antipsychotics, but	<u>Reported Dx:</u> Psychosis secondary to COVID-19 infection  <u>DSM-5 Dx:</u> Psychotic disorder due to COVID-19, with hallucinations	Impairments on cognitive testing

(continued on next page)

Table 1 (continued)

Study reference	Age, sex, country	Psychiatric presentation	Non-psychiatric presentation	Psychiatric history	Medical history	Studies	Treatment and Outcome	Reported and approximated DSM-5 Diagnosis	Confounders/ limitations
Santos et al., 2021 [58]	61, M, PT	Convinced his spouse was being unfaithful and that she was having “erotic” conversations with unknown person on audio recordings on his phone. Noted to have “functional” AH on exam. Symptoms began 2 days before myalgia, fever, and COVID-19 diagnosis, but presented to ED 30 days later.	1 week of cough myalgia and fever due to COVID-19	None	Not reported	with elevated glucose and + toxoplasmosis IgG, but negative IgM. MRI of the brain with only mild cerebral volume loss. Unremarkable EEG. + SARS-CoV-2 PCR. CBC, “Biochemical profile,” UA, “serologic tests,” TFTs, “drug tests,” and “vitamin levels” were unremarkable. Head CT was normal.	paranoid delusions an AH did not improve, so switched to risperidone and transferred to psychiatry after admitted to neurology and improved with no psychosis on follow up. No treatment mentioned for COVID-19 and cough, myalgia resolved after 1 week.  For psychosis, risperidone 2 mg daily and 3 mg QHS and lorazepam 0.5 mg TID, weaned as outpatient. Discharged after 15 days with resolution of symptoms and did not return at 3 month follow up on 1 mg risperidone.	<u>Reported Dx:</u> Organic delusional disorder due to COVID-19  <u>DSM-5 Dx:</u> Psychotic disorder due to COVID-19, with delusions	Limited case details. No lumbar puncture.
Sen et al., 2021 [59]	33, F, TR	Paranoid delusions that children were under effects of bad spirits and that husband having an affair. Also with insomnia, irritability, anxiety, dysphoric and manic	Not reported	None	None	+SARS-CoV-2 IgM. WBC $9.6 \times 10^3$ cells/ $\mu$ L, CRP 123 mg/dL, fibrinogen 625 mg/dL, ferritin 214 microg/L, D-Dimer 1.25 mg/mL, all else wnl. MRI brain showed hyperintense signal in splenium of corpus callosum, resolved on day 5.	For psychosis, received haloperidol 20 mg daily and biperiden 10 mg daily. Transitioned to olanzapine 20 mg daily. For COVID-19, received HCQ and Favipiravir.  Discharged day 14 on olanzapine 20 mg daily	<u>Reported Dx:</u> SARS-CoV-2-associated first episode of acute mania with psychotic features  <u>DSM-5 Dx:</u> Bipolar and related disorder due to COVID-19, with mood congruent psychotic features	No CSF studies
Smith et al., 2020 [60]	36, F, US	Paranoid delusions that she was being tracked by cell phone and that someone was attempting to steal her stimulus check. Attempted to pass children through a drive through window.	Rhinorrhea and nasal congestion	None	Erythema multiforme	+ SARS-CoV-2 PCR. WBC $11.5 \times 10^3$ cells/ $\mu$ L, CRP 2.37 mg/dL, D-dimer 2274 ng/mL, normal electrolytes, ferritin, renal function, urine analysis, UDS and CSF. MRI brain within normal limits	Olanzapine 2.5 mg and 5 mg which was transitioned to risperidone 3 mg daily and clonazepam. Supportive treatment for COVID-19.  Near resolution of symptoms despite discontinuation of medication 1-week post-discharge	<u>Reported Dx:</u> Brief psychotic disorder associated with COVID-19  <u>DSM-5 Dx:</u> Brief psychotic disorder, with marked stressor	Recent domestic dispute with psychosocial distress.
Tuna et al., 2021 [61]	52, F, TR	Admitted after trying to jump out window of house, with AH telling her to kill herself	Not reported	None	None	+ SARS-CoV-2 PCR. Low dose CT chest consistent with COVID-19 pneumonia. “Neuroimaging” did not have pathology.	Hydroxychloroquine x 5 days for COVID-19 and haloperidol 10 mg for psychosis.  Improvement in symptoms after 1 week.	<u>Reported Dx:</u> Schizophreniform disorder  <u>DSM-5 Dx:</u> Schizophreniform disorder	Limited case details. Symptoms began 1 month ago and unclear when infected with SARS-CoV-2
Vepa et al., 2020 [62]	40, M, UK	Hallucinations of staff constantly talking about him, paranoid delusions that staff were against	Six days of cough, dyspnea and nasal congestion with prodrome of fever,	None	None	+ SARS-CoV-2 PCR. WBC $12 \times 10^3$ cells/ $\mu$ L, ANC 10.3, CRP 19 mg/dL, 0 WBC in CSF. CT	Haloperidol and eventually intubation for psychosis.  Improved after 24 h of	<u>Reported Dx:</u> COVID-19 induced acute psychosis	Did not consider delirium despite mention of acute confusion.

(continued on next page)

Table 1 (continued)

Study reference	Age, sex, country	Psychiatric presentation	Non-psychiatric presentation	Psychiatric history	Medical history	Studies	Treatment and Outcome	Reported and approximated DSM-5 Diagnosis	Confounders/ limitations
		him, attempted suicide, derealization and depersonalization	anosmia and diarrhea for 4 days			chest showing ground glass consolidated opacities.	intubation and ventilation with symptoms resolving about 2 days after extubating.	<u>DSM-5 Dx:</u> Psychotic disorder due to COVID-19, with hallucinations	
Yesilkaya et al., 2021 [63]	41, F, TR	Paranoid thoughts of “viral occupation of body” with suicidal ideation 2 months after treatment for COVID 19	Anosmia, myalgia, and sore throat	None	None	+ SARS-CoV-2 PCR. Only reported “blood tests indicated no systemic inflammation”	Olanzapine 20 mg daily and then ECT 8 sessions for psychosis. Favipravir and HCQ for COVID-19.  Improvement in psychiatric symptoms.	<u>Reported Dx:</u> First episode psychosis accompanied by Cotard’s Syndrome  <u>DSM-5 Dx:</u> Psychotic disorder due to COVID-19, with delusions	Limited case details.  Recent treatment with favipravir and HCQ.
Zain et al., 2021 [64]	69, F, US	Bizarre behavior, paranoid delusions, VH and loose associations with catatonic signs of agitations, rigidity, and echolalia	Cold like symptoms with severe cough 2 months prior to presentation	None	COPD, HTN, T2DM	+ SARS-CoV-2 IgG. AST 68 ALT 38, UDS negative, Cr 0.4, total CK 628 U/L, Troponin I 0.147 ng/mL, WBC $6.1 \times 10^3$ cells/ $\mu$ L, CRP <0.9 mg/dL. TTE normal.	Psychosis treated with haloperidol 2 mg daily, followed by lorazepam 0.5 mg TID, clonazepam 1 mg BID at discharge.  Symptoms resolved at follow-up.	<u>Reported Dx:</u> COVID-induced brief psychotic disorder with catatonia  <u>DSM-5 Dx:</u> Psychotic disorder due to COVID-19, with hallucinations	Negative SARS-CoV-2 PCR

Table abbreviations: Ab, Antibody; ABG, Arterial blood gas; ANA, Antinuclear antibody; AH, auditory hallucinations; AIE, Autoimmune encephalitis; ANC, Absolute neutrophil count; ALT, Alanine transaminase; AST, Aspartate aminotransferase; AT, Austria; AVH, Auditory visual hallucinations; BAC, Blood alcohol concentration; BID, twice daily; BMP, Basic metabolic panel; BUN, Blood urea nitrogen; CBC, Complete blood count; CK, Creatine kinase; CMP, Complete metabolic panel; COPD, Chronic Obstructive Pulmonary Disease; COVID-19, Coronavirus Disease 2019; CRP, C-reactive protein; CSF, Cerebrospinal fluid; CT, Computer tomography; CXR, Chest radiograph; DSM-5, Diagnostic and Statistical Manual of Mental Disorders. Fifth Edition; Dx, Diagnosis; ECT, Electroconvulsive therapy; EEG, Electroencephalogram; EKG, Electrocardiogram; ES, Spain; ESR, Erythrocyte sedimentation rate; FR, France; Hgb, hemoglobin; HBV, Hepatitis B Virus; HCQ, Hydroxychloroquine; HCV, Hepatitis C Virus; HIV, Human Immunodeficiency virus; HTN, Hypertension; ICU, intensive care unit; ID, Indonesia; Ig, Immunoglobulin; IL, Israel; IN, India; INR, International normalized ratio; IR, Iran; IT, Italy; K, Potassium; LDH, Lactate dehydrogenase; LFT, Liver function test; MA, Morocco; MRI, Magnetic resonance imaging; MX, Mexico; NAFLD, Nonalcoholic fatty liver disease; OSA, Obstructive sleep apnea; OUD, Opioid use disorder; PCR, Polymerase chain reaction; PCT, Procalcitonin; PE, Peru; Plt, Platelet; QA, Qatar; QHS, nightly; QID, Four times daily; RPR, Rapid Plasma Reagin; SARS-CoV-2, Severe acute respiratory syndrome coronavirus 2; SOB, Shortness of breath; T2DM, Type 2 diabetes; TNF, Tumor necrosis factor; TR, Turkey; TSH, Thyroid stimulating hormone; TTE, Transesophageal echocardiogram; UDS, Urine drug screen; UK, United Kingdom; UA, Urinalysis; US, Ultrasound; VDRL, venereal disease research laboratory test; USA, United States of America; VPA, Valproic acid; VH, Visual hallucinations; WBC, White blood cells.

**Table 2**  
Characteristics of patients with COVID-19-associated psychosis cases.

Variable	
Age (Mean [SD])	43.9 (11.8)
Sex: n (%)	
Male	29 (60%)
Country: n (%)	
Austria	1 (2%)
Colombia	1 (2%)
France	1 (2%)
India	1 (2%)
Indonesia	1 (2%)
Iran	1 (2%)
Israel	3 (6%)
Italy	1 (2%)
Mexico	1 (2%)
Oman	1 (2%)
Peru	3 (6%)
Portugal	1 (2%)
Qatar	2 (4%)
Spain	3 (6%)
Tukey	3 (6%)
United Kingdom	4 (8%)
United States	20 (42%)
Comorbidity: n (%)	
Mental health	7 (15%)
Not reported	2 (4%)
Substance use	6 (13%)
Not reported	12 (25%)
Medical	11 (23%)
Not reported	14 (29%)

*N* = 48, except for age (*n* = 45).

incidence of psychotic disorder diagnoses in patients with COVID-19 [12]. Indeed, we excluded 11 reports of psychosis due to COVID-19 delirium in our review. Unlike a previous narrative review [4], which included cases of psychosis in individuals without COVID-19 [73], we included only those with a reported infection. However, 31% of patients also had a recent psychosocial stressor, which are known to precipitate psychosis in vulnerable individuals [74,75].

In this review, there were a few examples of low bias cases that convincingly excluded delirium. There were also two cases of psychosis attributed autoimmune encephalitis which improved with steroids [28,52], one of which identified a novel autoantibody [52]. So, although COVID-19-associated psychosis could represent a distinct clinical entity, we suggest that non-delirious psychosis in COVID-19 is less common than has been reported in epidemiologic studies [1], consistent with previous commentary on the subject [12].

The numerous confounders between SARS-CoV-2 and incident psychosis highlighted by this review should give clinicians pause when attributing psychosis to COVID-19 without a detailed clinical assessment. Clinical evaluation should include a thorough review of medical, psychiatric and substance use history along with a detailed clinical exam. Given that delirium is common in COVID-19 [22], and that delirium requires distinct evaluation and treatment compared to other psychotic disorders, physical and mental status exam should include an assessment for delirium using a validated screening tool [76], something that was commonly missing from evaluations in this review. Clinicians should also clearly assert whether they suspect psychotic signs and symptoms are related to delirium. If delirium is present, psychiatrists should work with medical specialists to identify the underlying etiology and treat accordingly. Based on the American Psychiatric Association practice guidelines for schizophrenia [77], neuroimaging and lumbar puncture should be considered in the presence of focal neurological deficits, new onset seizures, later age onset, or concern for autoimmune encephalitis (e.g., personality change, rapid onset of deficits over 3 months or less, lethargy or decreased level of consciousness). Given reported cases of autoimmune encephalitis in COVID-19-associated psychosis [28,52], the threshold for obtaining these studies in cases of

**Table 3**  
Clinical presentation and interventions for patients with COVID-19-associated psychosis (*n* = 48).

Variable	n (%)
Clinical presentation	
Psychiatric presentation	
Delusions	44 (92%)
Hallucinations	33 (69%)
Auditory hallucinations	29 (60%)
Visual hallucinations	11 (23%)
Tactile hallucinations	2 (4%)
Disorganized behavior (other than catatonia)	23 (48%)
Catatonia	7 (15%)
Disorganized speech	12 (25%)
Mania	8 (17%)
Depression	4 (8%)
Days of psychiatric symptoms (range)	2–90
Not reported	6 (13%)
Nonpsychiatric presentation	
Asymptomatic	6 (13%)
Symptomatic	35 (73%)
Fever	16 (33%)
Respiratory	26 (54%)
Neurologic	14 (29%)
Gastrointestinal	7 (15%)
Not reported	7 (15%)
Days of nonpsychiatric symptoms (range)	0–35
Not reported	22 (46%)
Clinical Interventions	
Variable	n (%)
Hospitalization	44 (92%)
Medical	33 (69%)
Psychiatric	16 (33%)
Medical and Psychiatric	10 (21%)
ICU	5 (10%)
Service not reported	5 (10%)
Oxygen requirement	13 (27%)
Nonpsychotropic medication	
Steroids	9 (19%)
Tocilizumab	3 (6%)
Favipiravir	2 (4%)
Remdesivir	3 (6%)
Chloroquine derivative	14 (29%)
Psychotropic medication	
Antipsychotic	46 (96%)
Benzodiazepine	29 (60%)
Antidepressant	6 (13%)
Mood stabilizer	6 (13%)
ECT	4 (8%)

psychosis associated with COVID-19 that have excluded delirium should be low.

There are several limitations of this retrospective review. First, case reports are inherently anecdotal, provide a non-random sample, and do not allow for claims of causality in many cases [78]. Given our clinical expertise is limited to adult medicine and psychiatry and the small number of COVID-19-associated psychosis cases in the pediatric population, the scope of the review was limited to adults. The review was based on non-systematic reporting of clinical information and many cases lacked relevant clinical details or were of low quality. We conducted a comprehensive search, including citation analysis, however, there were some studies for which only an abstract was available. Finally, we did not include patients from retrospective descriptive studies that aggregated data and excluded individual case details [10,11,79]. Despite these limitations, the strength of this study is the use of a systematic approach and standardized assessment of quality in cases of COVID-19-associated psychosis.

## 5. Conclusions

Psychosis is a complex condition with many etiologies, and there have been an increasing number of case reports describing psychosis in

patients with COVID-19. The findings of this descriptive systematic review suggest that the clinical presentations and case descriptions often lacked clinically relevant details, including how or if delirium was excluded in patients with COVID-19-associated psychosis. Reports of non-delirious psychosis related to COVID-19 might therefore be over-reported. Prospective studies are warranted to further clarify the relationship between COVID-19 and incident psychosis.

### Disclaimer

The content is solely the responsibility of the authors and does not necessarily represent the official views of Duke University, the U.S. Government or any of its agencies.

### Funding/Support

Not applicable.

### Declaration of competing interest

None reported.

### Acknowledgements

The authors appreciate the assistance of Robert Rolfe, MD for language services during the review process.

### Appendix A. Supplementary data

Supplementary data to this article can be found online at <https://doi.org/10.1016/j.genhosppsych.2021.10.003>.

### References

- Taquet M, Geddes JR, Husain M, Luciano S, Harrison PJ. 6-month neurological and psychiatric outcomes in 236 379 survivors of COVID-19: a retrospective cohort study using electronic health records. *Lancet Psychiatry* 2021 May;8(5):416–27. [https://doi.org/10.1016/S2215-0366\(21\)00084-5](https://doi.org/10.1016/S2215-0366(21)00084-5). Epub 2021 Apr 6. PMID: 33836148; PMCID: PMC8023694.
- Rogers JP, Chesney E, Oliver D, Pollak TA, McGuire P, Fusar-Poli P, et al. Psychiatric and neuropsychiatric presentations associated with severe coronavirus infections: a systematic review and meta-analysis with comparison to the COVID-19 pandemic. *Lancet Psychiatry* 2020 Jul;7(7):611–27. [https://doi.org/10.1016/S2215-0366\(20\)30203-0](https://doi.org/10.1016/S2215-0366(20)30203-0). Epub 2020 May 18. PMID: 32437679; PMCID: PMC7234781.
- Belluck P. Small number of COVID patients develop severe psychotic symptoms. <https://www.nytimes.com/2020/12/28/health/covid-psychosis-mental.html>; 2020, December 28.
- Watson CJ, Thomas RH, Solomon T, Michael BD, Nicholson TR, Pollak TA. COVID-19 and psychosis risk: real or delusional concern? *Neurosci Lett* 2021 Jan 10;741:135491. <https://doi.org/10.1016/j.neulet.2020.135491>. Epub 2020 Nov 18, 33 220366.
- Radua J, Ramella-Cravaro V, Ioannidis JPA, Reichenberg A, Phiphophatsanee N, Amir T, et al. What causes psychosis? An umbrella review of risk and protective factors. *World Psychiatry* 2018 Feb;17(1):49–66. <https://doi.org/10.1002/wps.20490>. PMID: 29352556; PMCID: PMC5775150.
- Simon GE, Stewart C, Yarborough BJ, Lynch F, Coleman KJ, Beck A, et al. Mortality rates after the first diagnosis of psychotic disorder in adolescents and young adults. *JAMA Psychiatry* 2018 Mar 1;75(3):254–60. <https://doi.org/10.1001/jamapsychiatry.2017.4437>. PMID: 29387876; PMCID: PMC5885951.
- Suvisaari J, Partti K, Perälä J, Viertiö S, Saarni SE, Lönnqvist J, et al. Mortality and its determinants in people with psychotic disorder. *Psychosom Med* 2013 Jan;75(1):60–7. <https://doi.org/10.1097/PSY.0b013e31827ad512>. Epub 2012 Dec 20, 23257931.
- Kulaga SS, Miller CWT. Viral respiratory infections and psychosis: A review of the literature and the implications of COVID-19. *Neurosci Biobehav Rev* 2021 Aug;127:520–30. <https://doi.org/10.1016/j.neubiorev.2021.05.008>. Epub 2021 May 13, 33992695.
- Brown E, Gray R, Lo Monaco S, O'Donoghue B, Nelson B, Thompson A, et al. The potential impact of COVID-19 on psychosis: a rapid review of contemporary epidemic and pandemic research. *Schizophr Res* 2020 Aug;222:79–87. <https://doi.org/10.1016/j.schres.2020.05.005>. Epub 2020 May 6. PMID: 32389615; PMCID: PMC7200363.
- Parra A, Juanes A, Losada CP, Álvarez-Sesmero S, Santana VD, Martí I, et al. Psychotic symptoms in COVID-19 patients. A retrospective descriptive study. *Psychiatry Res* 2020 Sep;291:113254. <https://doi.org/10.1016/j.psychres.2020.113254>. Epub 2020 Jun 24. PMID: 32603930; PMCID: PMC7311337.
- Varatharaj A, Thomas N, Ellul MA, Davies NWS, Pollak TA, Tenorio EL, et al. Study Group. Neurological and neuropsychiatric complications of COVID-19 in 153 patients: a UK-wide surveillance study. *Lancet Psychiatry* 2020 Oct;7(10):875–82. [https://doi.org/10.1016/S2215-0366\(20\)30287-X](https://doi.org/10.1016/S2215-0366(20)30287-X). Epub 2020 Jun 25. Erratum in: *Lancet Psychiatry*. 2020 Jul 14; PMID: 32593341; PMCID: PMC7316461.
- Rogers JP, David AS. A longer look at COVID-19 and neuropsychiatric outcomes. *Lancet Psychiatry* 2021 May;8(5):351–2. [https://doi.org/10.1016/S2215-0366\(21\)00120-6](https://doi.org/10.1016/S2215-0366(21)00120-6). Epub 2021 Apr 6. PMID: 33836149; PMCID: PMC8023693.
- Webster R, Holroyd S. Prevalence of psychotic symptoms in delirium. *Psychosomatics*. 2000 Nov-Dec;41(6):519–22. <https://doi.org/10.1176/appi.psy.41.6.519>. 11110116.
- Paik SH, Ahn JS, Min S, Park KC, Kim MH. Impact of psychotic symptoms on clinical outcomes in delirium. *PLoS One* 2018 Jul 13;13(7). <https://doi.org/10.1371/journal.pone.0200538>. e0200538. PMID: 30005081; PMCID: PMC6044533.
- Madden JM, Lakoma MD, Rusinak D, Lu CY, Soumerai SB. Missing clinical and behavioral health data in a large electronic health record (EHR) system. *J Am Med Inform Assoc* 2016 Nov;23(6):1143–9. <https://doi.org/10.1093/jamia/ocw021>. Epub 2016 Apr 14. PMID: 27079506; PMCID: PMC5070522.
- Taquet M, Luciano S, Geddes JR, Harrison PJ. Bidirectional associations between COVID-19 and psychiatric disorder: retrospective cohort studies of 62 354 COVID-19 cases in the USA. *Lancet Psychiatry* 2021 Feb;8(2):130–40. [https://doi.org/10.1016/S2215-0366\(20\)30462-4](https://doi.org/10.1016/S2215-0366(20)30462-4). Epub 2020 Nov 9. Erratum in: *Lancet Psychiatry*. 2021 Jan;8(1):e1. PMID: 33181098; PMCID: PMC7820108.
- Otasowie J, Paraiso A, Bates G. Pervasive refusal syndrome: systematic review of case reports. *Eur Child Adolesc Psychiatry* 2021 Jan;30(1):41–53. <https://doi.org/10.1007/s00787-020-01536-1>. Epub 2020 Apr 27. PMID: 32342195; PMCID: PMC7222039.
- Singhai K, Kuppili PP, Nebhinani N. Atypical neuroleptic malignant syndrome: a systematic review of case reports. *Gen Hosp Psychiatry* 2019 Sep-Oct;60:12–9. <https://doi.org/10.1016/j.genhosppsych.2019.06.009>. Epub 2019 Jun 20, 31299470.
- Carroll AJ, Goergen J, Wafford QE, Flaherty JD, Grady KL, Feingold KL. Psychiatric conditions in patients presenting with Takotsubo syndrome: a systematic review and synthesis of case studies. *Gen Hosp Psychiatry* 2020 Jul-Aug;65:54–63. <https://doi.org/10.1016/j.genhosppsych.2020.05.010>. Epub 2020 May 28, 32497926.
- Abdel-Wahab N, Lopez-Olivo MA, Pinto-Patarroyo GP, Suarez-Almazor ME. Systematic review of case reports of antiphospholipid syndrome following infection. *Lupus* 2016 Dec;25(14):1520–31. <https://doi.org/10.1177/0961203316640912>. Epub 2016 Apr 7. PMID: 27060064; PMCID: PMC7508159.
- Moher D, Liberati A, Tetzlaff J, Altman DG, PRISMA Group. Preferred reporting items for systematic reviews and meta-analyses: the PRISMA Statement. *Open Med* 2009;3(3). e123–30. Epub 2009 Jul 21. PMID: 21603045; PMCID: PMC3090117.
- Pun BT, Badenes R, Heras La Calle G, Orun OM, Chen W, Raman R, et al. Prevalence and risk factors for delirium in critically ill patients with COVID-19 (COVID-D): a multicentre cohort study. *Lancet Respir Med* 2021 Mar;9(3):239–50. [https://doi.org/10.1016/S2213-2600\(20\)30552-X](https://doi.org/10.1016/S2213-2600(20)30552-X). Epub 2021 Jan 8. Erratum in: *Lancet Respir Med*. 2021 Jan 27; PMID: 33428871; PMCID: PMC7832119.
- Murad MH, Sultan S, Haffar S, Bazerbachi F. Methodological quality and synthesis of case series and case reports. *BMJ Evid Based Med* 2018 Apr;23(2):60–3. <https://doi.org/10.1136/bmjebm-2017-110853>. Epub 2018 Feb 2. PMID: 29420178; PMCID: PMC6234235.
- Wang M, Wang W, Gao Z, Yin X, Chen T, Jiang Z, et al. Dyskinesia-hyperpyrexia syndrome in Parkinson's disease: a systematic review. *Clin Auton Res* 2021 Apr 7. <https://doi.org/10.1007/s10286-021-00801-w>. Epub ahead of print. 33826041.
- Alba L, Coll C, Sáez S, Alonso L, Pérez H, Palma S, et al. New-onset psychosis: a case report of brief psychosis related to COVID-19 infection. *Psychiatry Res* 2021 Jul;301:113975. <https://doi.org/10.1016/j.psychres.2021.113975>. Epub 2021 Apr 29. PMID: 33990069; PMCID: PMC8084280.
- Al-Busaidi S, Al Huseini S, Al-Shehri R, Zishan AA, Moghadas M, Al-Adawi S. COVID-19 induced new-onset psychosis: a case report from Oman. *Oman Med J* 2021. <https://doi.org/10.5001/omj.2022.25> [Epub ahead of print].
- Alvarez-Cisneros T, Lara-Reyes A, Sansón-Tinoco S. Hiccups and psychosis: two atypical presentations of COVID-19. *Int J Emerg Med* 2021 Jan 20;14(1):8. <https://doi.org/10.1186/s12245-021-00333-0>. PMID: 33472577; PMCID: PMC7816133.
- Ariza-Varón M, Beltrán MA, Marín-Medina DS, González AF, Ávila AM. Psychosis associated with suspected SARS-CoV-2 encephalitis with response to steroids: a case report [published online ahead of print, 2021 Sep 22]. *Infect Dis (Lond)* 2021: 1–5. <https://doi.org/10.1080/23744235.2021.1977381>.
- Austgen G, Meyers MS, Gordon M, Livingston R. The use of electroconvulsive therapy in neuropsychiatric complications of coronavirus disease 2019: a systematic literature review and case report [published online ahead of print, 2021 Aug 4]. *J Acad Consult Liaison Psychiatry* 2021. <https://doi.org/10.1016/j.jaclp.2021.07.010>. S2667–2960(21)00127–0.
- Baral N, Adhikari G, Karki S, Champine A, Sud P. Does social stigma and neglect post-COVID-19 matter? A case report on brief psychotic disorder post-COVID-19 and self-quarantine. *Cureus* 2021 Jan 28;13(1). <https://doi.org/10.7759/cureus.12973>. e12973. PMID: 33654634; PMCID: PMC7913998.
- Caan MP, Lim CT, Howard M. A case of catatonia in a man with COVID-19. *Psychosomatics* 2020;61(5):556–60. <https://doi.org/10.1016/j.psym.2020.05.021>.
- Chacko M, Job A, Caston 3rd F, George P, Yacoub A, Cáceda R. COVID-19-induced psychosis and suicidal behavior: case report. *SN Compr Clin Med* 2020 Sep 26:1–5.



- <https://doi.org/10.1007/s42399-020-00530-7>. Epub ahead of print. PMID: 33015547; PMCID: PMC7519695.
- [33] DeLisi LE. A commentary revisiting the viral hypothesis of schizophrenia: onset of a schizophreniform disorder subsequent to SARS CoV-2 infection. *Psychiatry Res* 2021 Jan;295:113573. <https://doi.org/10.1016/j.psychres.2020.113573>. Epub 2020 Nov 16. PMID: 33223274.
- [34] Desai S, Sheikh B, Belzile L. New-onset psychosis following COVID-19 infection. *Cureus* 2021;13(9). <https://doi.org/10.7759/cureus.17904>. e17904. Published 2021 Sep 12.
- [35] Elfil M, Selby L, Van Schooneveld TC, Fadul N. Acute psychosis associated with recent SARS-CoV-2 infection: a case report. *IDCases* 2021;24. <https://doi.org/10.1016/j.idcr.2021.e01140>. e01140. Epub 2021 Apr 27. PMID: 33936950; PMCID: PMC8076759.
- [36] Faisal HKP, Taufik FF, Sugihen TGT, Prasenhadi Juliani T, Yunus F. Brief psychotic disorder in COVID-19 patient with no history of mental illness. *J Infect Dev Ctries* 2021 Jun 30;15(6):787–90. <https://doi.org/10.3855/jidc.14830.34242187>.
- [37] Ferrando SJ, Klepac L, Lynch S, Tavakkoli M, Dornbush R, Baharani R, et al. COVID-19 psychosis: a potential new neuropsychiatric condition triggered by novel coronavirus infection and the inflammatory response? *Psychosomatics* 2020 Sep-Oct;61(5):551–5. <https://doi.org/10.1016/j.psym.2020.05.012>. Epub 2020 May 19. PMID: 32593479; PMCID: PMC7236749.
- [38] Gillett G, Jordan I. Severe psychiatric disturbance and attempted suicide in a patient with COVID-19 and no psychiatric history. *BMJ Case Rep* 2020 Oct 31;13(10). <https://doi.org/10.1136/bcr-2020-239191>. e239191. PMID: 33130587; PMCID: PMC7783370.
- [39] Haddad PM, Al Abdulla M, Latoo J, Iqbal Y. Brief psychotic disorder associated with quarantine and mild COVID-19. *BMJ Case Rep* 2020 Dec 16;13(12). <https://doi.org/10.1136/bcr-2020-240088>. e240088. PMID: 33328211; PMCID: PMC7745456.
- [40] Huaracaya-Victoria J, Meneses-Saco A, Luna-Cuadros MA. Psychotic symptoms in COVID-19 infection: a case series from Lima, Peru. *Psychiatry Res* 2020 Nov;293:113378. <https://doi.org/10.1016/j.psychres.2020.113378>. Epub 2020 Aug 9. PMID: 32805590; PMCID: PMC7415343.
- [41] Jaworowski S, Weiser M, Gropp C, Malka M. Three cases of COVID-19-related first onset brief reactive psychosis. *Isr Med Assoc J* 2020 Oct;22(10):612. <https://doi.org/10.3307083>.
- [42] Kashaninasab F, Panahi Dashdebi R, Ghalehbandi MF. Comorbidity of Coronavirus disease (COVID-19) and the first episode of bipolar disorder and its treatment challenges: A case report. *Med J Islam Repub Iran* 2020 Aug 22;34:103. <https://doi.org/10.34171/mjiri.34.103>. PMID: 33315969; PMCID: PMC7722969.
- [43] Kazi S, Akhter S, Periasamy D, et al. Acute psychosis and COVID-19 infection: psychiatric symptoms in hospitalized patients. *Cureus* September 20, 2021;13(9): e18121. <https://doi.org/10.7759/cureus.18121>.
- [44] Khatib MY, Mahgoub OB, Elzain M, Ahmed AA, Mohamed AS, Nashwan AJ. Managing a patient with bipolar disorder associated with COVID-19: A case report from Qatar. *Clin Case Rep* 2021 Mar 11;9(4):2285–8. <https://doi.org/10.1002/ccr3.4015>. PMID: 33936680; PMCID: PMC8077261.
- [45] Kozato N, Mishra M, Firdosi M. New-onset psychosis due to COVID-19. *BMJ Case Rep* 2021 Apr 26;14(4). <https://doi.org/10.1136/bcr-2021-242538>. e242538. PMID: 33906867; PMCID: PMC8076917.
- [46] Kumar P, Kamal S, Tuli S, Gupta N. COVID-19 and manifest psychological morbidity: A case series. *Indian J Psychiatry* 2021 May-Jun;63(3):294–6. [https://doi.org/10.4103/indianjpsychiatry.indianjpsychiatry\\_152\\_21](https://doi.org/10.4103/indianjpsychiatry.indianjpsychiatry_152_21). Epub 2021 Jun 17. PMID: 34211225; PMCID: PMC8221209.
- [47] Lanier CG, Lewis SA, Patel PD, Ahmed AM, Lewis PO. An unusual case of COVID-19 presenting as acute psychosis. *J Pharm Pract* 2020 Dec;7. <https://doi.org/10.1177/0897190020977721>. 897190020977721. Epub ahead of print. PMID: 33280502.
- [48] Lim ST, Janaway B, Costello H, Trip A, Price G. Persistent psychotic symptoms following COVID-19 infection. *BJPsych Open* 2020 Jul 22;6(5). <https://doi.org/10.1192/bjo.2020.76>. e105. PMID: 32696735; PMCID: PMC7477483.
- [49] Lorenzo-Villalba N, Jannot X, Syrovatková A, Michel V, Andrès E. SARS-CoV-2 infection and psychiatric manifestations in a previous healthy patient. *Caspian J Intern Med* 2020 Fall;11(Suppl. 1):566–8. <https://doi.org/10.22088/cjim.11.0.566>. PMID: 33425277; PMCID: PMC7780860.
- [50] Majadas S, Pérez J, Casado-Espada NM, Zambrana A, Bullón A, Roncero C. Case with psychotic disorder as a clinical presentation of COVID-19. *Psychiatry Clin Neurosci* 2020 Oct;74(10):551–2. <https://doi.org/10.1111/pcn.13107>. Epub 2020 Jul 31. PMID: 32639089; PMCID: PMC7361769.
- [51] Makivic N, Stöllberger C, Schauer D, Bernhofer L, Pawelka E, Erfurth A, et al. Pulmonary embolism and acute psychosis, a case report of an outpatient with a mild course of COVID-19. *SN Compr Clin Med* 2021 Apr 27:1–6. <https://doi.org/10.1007/s42399-021-00925-0>. Epub ahead of print. PMID: 33937635; PMCID: PMC8078897.
- [52] McAlpine LS, Liffland B, Check JR, Angarita GA, Ngo TT, Pleasure SJ, et al. Remission of subacute psychosis in a COVID-19 patient with an antineuronal autoantibody after treatment with intravenous immunoglobulin. *Biol Psychiatry* 2021 Aug 15;90(4):e23–6. <https://doi.org/10.1016/j.biopsych.2021.03.033>. Epub 2021 Apr 12. PMID: 34001372; PMCID: PMC8041149.
- [53] Mirza J, Ganguly A, Ostrovskaya A, Tusher A, Viswanathan R. Command suicidal hallucination as initial presentation of coronavirus disease 2019 (COVID-19): a case report. *Psychosomatics* 2020 Sep-Oct;61(5):561–4. <https://doi.org/10.1016/j.psym.2020.05.022>. Epub 2020 May 30. PMID: 32593478; PMCID: PMC7260551.
- [54] Mollá Roig P. Psicosis reactiva breve a situación de confinamiento por PCR positiva para SARS-CoV-2. A propósito de un caso clínico. *Psiquiatría Biológica* 2021;28(1): 22–4. <https://doi.org/10.1016/j.psiq.2020.10.003>.
- [55] Noone R, Cabassa JA, Gardner L, Schwartz B, Alpert JE, Gabbay V. Letter to the Editor: New onset psychosis and mania following COVID-19 infection. *J Psychiatr Res* 2020 Nov;130:177–9. <https://doi.org/10.1016/j.jpsychires.2020.07.042>. Epub 2020 Aug 8. PMID: 32823051; PMCID: PMC7414775.
- [56] Panariello A, Bassetti R, Radice A, et al. Anti-NMDA receptor encephalitis in a psychiatric Covid-19 patient: A case report. *Brain Behav Immun* 2020;87:179–81. <https://doi.org/10.1016/j.bbi.2020.05.054>.
- [57] Parker C, Slan A, Shalev D, Critchfield A. Abrupt Late-onset psychosis as a presentation of Coronavirus 2019 Disease (COVID-19): A longitudinal case report. *J Psychiatr Pract* 2021 Mar 5;27(2):131–6. <https://doi.org/10.1097/PRA.0000000000000533>. PMID: 33656820; PMCID: PMC8043329.
- [58] Santos NF, Alho AP, Costa ID, Ferreira LP, Sêco EH. First-episode psychosis with delusional jealousy during SARS-CoV-2 infection: COVID-19 secondary psychosis or a trigger for a primary psychotic disorder? *Prim Care Companion CNS Disord* 2021;23(5). <https://doi.org/10.4088/PCC.21cr03070>. 21cr03070. Published 2021 Sep 30.
- [59] Sen M, Yesilkaya UH, Balcioglu YH. SARS-CoV-2-associated first episode of acute mania with psychotic features. *J Clin Neurosci* 2021 May;87:29–31. <https://doi.org/10.1016/j.jocn.2021.02.012>. Epub 2021 Mar 1. PMID: 33863529; PMCID: PMC7919506.
- [60] Smith CM, Komisar JR, Mourad A, Kincaid BR. COVID-19-associated brief psychotic disorder. *BMJ Case Rep* 2020 Aug 11;13(8). <https://doi.org/10.1136/bcr-2020-236940>. e236940. PMID: 32784244; PMCID: PMC7418683.
- [61] Tuna O, Salman S, Darcin AE. COVID-19 pandemic in delusions: two cases. *Psychiatr Danub* 2020 Autumn;32(3–4):584–6. <https://doi.org/10.24869/psyd.2020.584>. PMID: 33370771.
- [62] Vepa A, Saleem A, Dharmaraj D, Afzaal Q. COVID-19 diagnostic difficulties and acute psychosis. *Br J Med Pract* 2020 Aug 11;13(8). Retrieved from: <https://www.bjpm.org/content/covid-19-diagnostic-difficulties-and-acute-psychosis>.
- [63] Yesilkaya UH, Sen M, Karamustafalioglu N. New variants and new symptoms in COVID-19: First episode psychosis and Cotard's Syndrome two months after infection with the B.1.1.7 variant of coronavirus. *Schizophr Res* 2021 Jun 16. <https://doi.org/10.1016/j.schres.2021.06.001>. S0920–9964(21)00213–9. Epub ahead of print. PMID: 34176695; PMCID: PMC8206628.
- [64] Zain SM, Muthukanagaraj P, Rahman N. Excited Catatonia - A Delayed Neuropsychiatric Complication of COVID-19 Infection. *Cureus* 2021 Mar 15;13(3): e13891. <https://doi.org/10.7759/cureus.13891>. PMID: 33880247; PMCID: PMC8045148.
- [65] Kessler RC, Amminger GP, Aguilar-Gaxiola S, Alonso J, Lee S, Ustün TB. Age of onset of mental disorders: a review of recent literature. *Curr Opin Psychiatry* 2007 Jul;20(4):359–64. <https://doi.org/10.1097/YCO.0b013e32816ebc8c>. PMID: 17551351; PMCID: PMC1925038.
- [66] Brunelle S, Cole MG, Elie M. Risk factors for the late-onset psychoses: a systematic review of cohort studies. *Int J Geriatr Psychiatry* 2012 Mar;27(3):240–52. <https://doi.org/10.1002/gps.2702>. Epub 2011 Apr 6. <https://doi.org/10.1002/gps.2702>.
- [67] Weibell MA, Hegelstad WTV, Auestad B, Bramness J, Evensen J, Haahr U, et al. The effect of substance use on 10-year outcome in first-episode psychosis. *Schizophr Bull* 2017 Jul 1;43(4):843–51. <https://doi.org/10.1093/schbul/sbw179>. PMID: 28199703; PMCID: PMC5472130.
- [68] Strakowski SM, Tohen M, Stoll AL, Faedda GL, Mayer PV, Kolbrener ML, et al. Comorbidity in psychosis at first hospitalization. *Am J Psychiatry* 1993 May;150(5):752–7. <https://doi.org/10.1176/ajp.150.5.752>. 8480821.
- [69] Menninger KA. Influenza and schizophrenia. An analysis of post-influenzal "dementia precox," as of 1918, and five years later further studies of the psychiatry aspects of influenza. *Am. J. Psychiatry* 1926;82:469–529. <https://doi.org/10.1176/ajp.151.6.182>.
- [70] Grant MC, Geoghegan L, Arbyn M, Mohammed Z, McGuinness L, Clarke EL, et al. The prevalence of symptoms in 24,410 adults infected by the novel coronavirus (SARS-CoV-2; COVID-19): A systematic review and meta-analysis of 148 studies from 9 countries. *PLoS One* 2020 Jun 23;15(6):e0234765. <https://doi.org/10.1371/journal.pone.0234765>. PMID: 32574165; PMCID: PMC7310678.
- [71] Oran DP, Topol EJ. The proportion of SARS-CoV-2 infections that are asymptomatic: A systematic review. *Ann Intern Med* 2021 May;174(5):655–62. <https://doi.org/10.7326/M20-6976>. Epub 2021 Jan 22. PMID: 33481642; PMCID: PMC7839426.
- [72] Salluh JJ, Soares M, Teles JM, Ceraso D, Raimondi N, Nava VS, et al. Delirium epidemiology in critical care (DECCA): an international study. *Crit Care* 2010;14(6):R210. <https://doi.org/10.1186/cc9333>. Epub 2010 Nov 23. PMID: 21092264; PMCID: PMC3220001.
- [73] D'Agostino A, D'Angelo S, Giordano B, et al. Brief psychotic disorder during the National Lockdown in Italy: an emerging clinical phenomenon of the COVID-19 pandemic. *Schizophr Bull* 2021;47(1):15–22. <https://doi.org/10.1093/schbul/sbaa112>.
- [74] Johns LC, Cannon M, Singleton N, Murray RM, Farrell M, Brugha T, et al. Prevalence and correlates of self-reported psychotic symptoms in the British population. *Br J Psychiatry* 2004 Oct;185:298–305. <https://doi.org/10.1192/bjp.185.4.298>. 15458989.
- [75] Wiles NJ, Zammit S, Bebbington P, Singleton N, Meltzer H, Lewis G. Self-reported psychotic symptoms in the general population: results from the longitudinal study of the British National Psychiatric Morbidity Survey. *Br J Psychiatry* 2006 Jun;188: 519–26. <https://doi.org/10.1192/bjp.bp.105.012179>. 16738341.
- [76] Wilson JE, Mart MF, Cunningham C, et al. Delirium published correction appears in *Nat Rev Dis Primers*6(1); 2020 Dec 1. p. 94. <https://doi.org/10.1038/s41572-020-00223-4>.

- [77] Keepers GA, Fochtmann LJ, Anzia JM, et al. The American Psychiatric Association practice guideline for the treatment of patients with schizophrenia. *Am J Psychiatry* 2020;177(9):868–72. <https://doi.org/10.1176/appi.ajp.2020.177901>.
- [78] Nissen T, Wynn R. The clinical case report: a review of its merits and limitations. *BMC Res Notes* 2014 Apr 23;7:264. <https://doi.org/10.1186/1756-0500-7-264>. PMID: 24758689; PMCID.
- [79] Iqbal Y, Al Abdulla MA, Albrahim S, Latoo J, Kumar R, Haddad PM. Psychiatric presentation of patients with acute SARS-CoV-2 infection: a retrospective review of 50 consecutive patients seen by a consultation-liaison psychiatry team. *BJPsych Open* 2020;6(5):e109. Published 2020 Sep 10, <https://doi.org/10.1192/BJO.2020.85>.