

Available online at www.sciencedirect.com

ScienceDirect

journal homepage: www.elsevier.com/locate/radcr

Case Report

Cesarean scar ectopic pregnancy: Case report[☆]

Sophia Brancazio, MPH^{a,*}, Israel Saramago, MD^b, William Goodnight, MD MSCR^c,
Katrina McGinty, MD^c

^a University of North Carolina, School of Medicine, 321 S. Columbia St., Chapel Hill, NC 27516

^b University of North Carolina, Department of Radiology, 2006 Old Clinic CB#7510, Chapel Hill, NC 27516

^c University of North Carolina, Department of Obstetrics and Gynecology, Maternal Fetal Medicine, 3010 Old Clinic CB # 7516, Chapel Hill, NC 27599

ARTICLE INFO

Article history:

Received 27 November 2018

Revised 2 December 2018

Accepted 2 December 2018

Available online 13 December 2018

Keywords:

Cesarean scar ectopic

Obstetrics

Ectopic pregnancy

ABSTRACT

Cesarean scar ectopic pregnancies are a rare form of extrauterine pregnancies, yet their incidence is increasing given the rise in cesarean deliveries. Similar to other ectopic pregnancies, cesarean scar ectopic pregnancies pose a great risk for maternal hemorrhage and ultimately maternal mortality. This study presents the case of a cesarean scar ectopic pregnancy in a patient with 3 prior cesarean deliveries. Here, we highlight the importance of early diagnosis and treatment of cesarean scar ectopic pregnancies.

© 2018 The Authors. Published by Elsevier Inc. on behalf of University of Washington.

This is an open access article under the CC BY-NC-ND license.

(<http://creativecommons.org/licenses/by-nc-nd/4.0/>)

Introduction

An ectopic pregnancy is a pregnancy that occurs outside of the uterine cavity [1,7,12]. Ectopic pregnancies occur in approximately 2% of all pregnancies in the United States [3,7,10]. While the presentation of ectopic pregnancy can be variable, its most common sign is early pregnancy vaginal bleeding [11]. Further, ectopic pregnancy accounts for 6% of all pregnancy-related deaths and is the highest contributor to hemorrhage-related deaths [1,6]. Risk factors for an ectopic pregnancy include a prior extrauterine pregnancy, use of assisted reproductive technology, history of tubal ligation, increased maternal

age, intrauterine device placement, and active sexually transmitted infection [3,7]. Despite these known risk factors, however, many women may present without any of these characteristics [1].

The most common location for an ectopic pregnancy is in the ampulla of the fallopian tube [1,7]. However, an ectopic pregnancy can occur in a variety of anatomic locations including the myometrium, cervix, ovaries, and abdomen [7]. Cesarean scar pregnancies are rare, occurring in approximately 1 in 2000 pregnancies, although the incidence is increasing [7,15,16,5]. The increasing rate of cesarean scar ectopic pregnancies mirrors the increasing rate of cesarean delivery

[☆] Each author certifies that he or she has no commercial associations (eg consultancies, stock ownership, equity interest, patent/licensing arrangements, etc.) that might pose a conflict of interest in connection with the submitted article. All ICMJE Conflict of Interest Forms for authors are on file with the publication and can be viewed on request. Investigation performed at University of North Carolina Hospitals, Chapel Hill, North Carolina.

* Corresponding author.

E-mail address: sbrancaz@med.unc.edu (S. Brancazio).

<https://doi.org/10.1016/j.radcr.2018.12.001>

1930-0433/© 2018 The Authors. Published by Elsevier Inc. on behalf of University of Washington. This is an open access article under the CC BY-NC-ND license. (<http://creativecommons.org/licenses/by-nc-nd/4.0/>)

[5,7,15]. Despite more than half of these patients experiencing greater than 2 cesarean deliveries, the risk for a cesarean scar ectopic does not necessarily increase with the number of cesarean deliveries [13,16]. Disruption of the endometrium and myometrium after cesarean delivery predisposes to improper implantation at the site of the prior hysterotomy [8]. Without normal surrounding myometrium, untreated cesarean scar ectopic pregnancies can result in uterine rupture with severe maternal hemorrhage and death [13,16].

Here, we present the case of a cesarean scar pregnancy. Although there are varying guidelines in place for management of a cesarean scar ectopic pregnancy, this case study describes the imaging findings associated with cesarean scar ectopic pregnancy, which are necessary to allow prompt diagnosis and therapy.

Case report

A 29-year-old woman (G4P3003) presented from an outside facility with vaginal bleeding and discharge. The patient did not have abdominal pain or any discomfort. The patient had a history of 3 cesarean deliveries in the past due to hypertension in her first pregnancy and 2 subsequent scheduled cesarean deliveries after normal pregnancies. Her most recent pregnancy was 3 years prior to presentation. She had no other significant medical history other than a body mass index of 38, had regular menses, and had no history of sexually transmitted infections. Three weeks prior to presentation, a transvaginal ultrasound at an outside obstetrics appointment suggested an intrauterine pregnancy at 7 weeks and 5 days with a gestational sac visualized in the lower uterine segment.

At presentation, her vitals were within normal limits and stable. Physical exam was only notable for moderate clear-white discharge in the vaginal vault without blood and a closed cervix on speculum evaluation. The patient's hemoglobin and hematocrit were within normal limits, as was her white blood cell count. Basic metabolic panel, wet prep, KOH, and STIs were negative. Quantitative Beta-hCG was 67,142 IU/L at presentation. At the outside facility, she had a transvaginal ultrasound that showed a single live intrauterine pregnancy low in the left uterine segment with a $1.9 \times 1.3 \times 1.0$ cm perigestational hemorrhage present to the right of the gestational sac. Transvaginal ultrasound did not reveal free fluid in the pelvis.

Transvaginal ultrasound at the treating hospital demonstrated a gestational sac (dated at 10 weeks and 4 days) located at the level of the internal cervical os. A fetal pole was noted with the presence of fetal cardiac motion. The gestational sac was located in an anterior position toward the anterior lower uterine segment at the level of prior cesarean scar with little visible myometrium noted anterior to the gestational sac in the lower uterine segment. The gestational sac was found to communicate with the endometrial cavity, while being located in the lower uterine segment of uterus, and was without involvement of the cervix. Given concern for cesarean scar ectopic pregnancy, possibility of implantation on the prior cesarean scar compared to within the scar with lower risk of morbidity, and limitations of the ultrasound given the mater-

nal BMI of 38, an MRI was performed. MRI of the abdomen and pelvis without contrast revealed a gestational sac located in the anterior aspect of the lower uterine segment superior to the internal cervical os at the site of prior cesarean scar. Disruption of the myometrium was suspected between the gestational sac and bladder, with only intact uterine serosa suspected, most consistent with implantation into the prior cesarean scar.

After discussion with the patient regarding her imaging findings, potential complications of continuation of cesarean scar pregnancy, and reproductive goals, the patient stated that she desired permanent sterilization. She underwent an uncomplicated total laparoscopic hysterectomy with removal of the cesarean scar pregnancy, bilateral salpingectomy, and cystoscopy. She was discharged postoperative day 1 and scheduled for close follow-up with obstetrics and gynecology.

Discussion

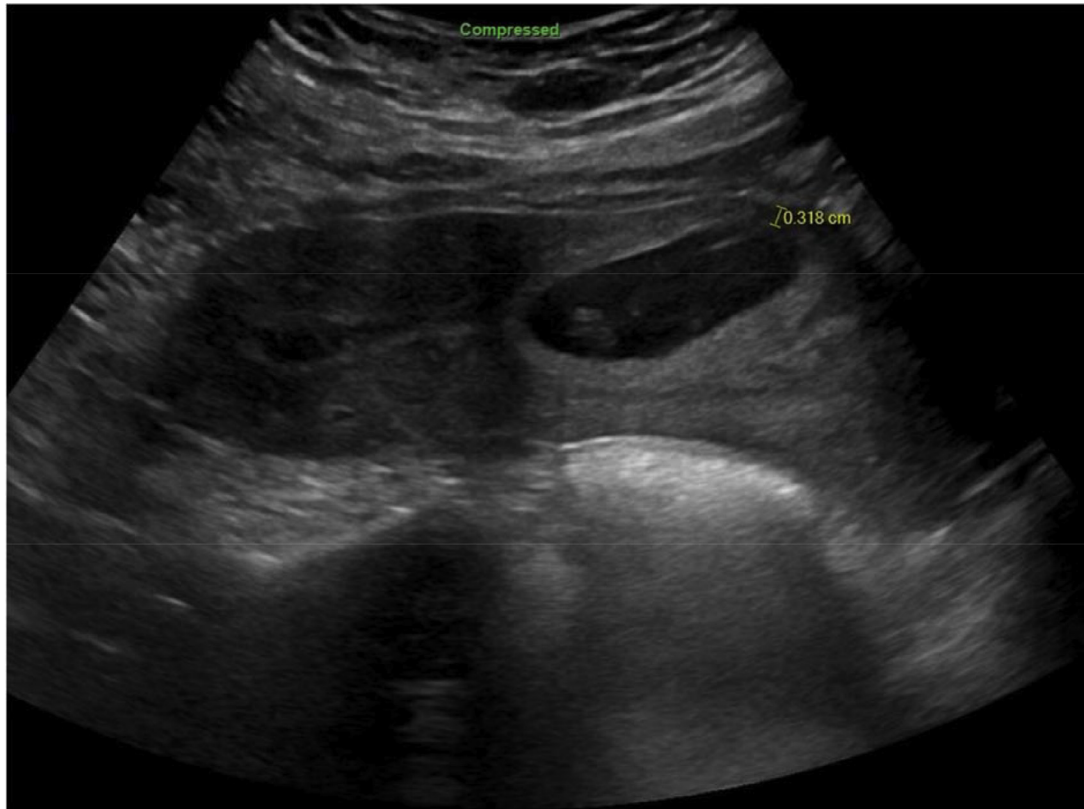
Here, we present the case of a patient with 3 prior cesarean deliveries who presented with a cesarean scar ectopic pregnancy. She was diagnosed via transvaginal ultrasound and noncontrast pelvic MRI, and she underwent surgical management.

It is important to have a high clinical suspicion for a cesarean scar ectopic in a patient who presents with first trimester bleeding and multiple previous cesarean deliveries. Although the incidence of cesarean scar ectopic pregnancy is uncommon, its incidence is indeed increasing given the rise of cesarean deliveries [7,15,16,5]. These pregnancies are life-threatening as they pose a great risk for maternal hemorrhage [13]. Thus, it is important to identify and treat cesarean scar ectopic pregnancies to avoid significant morbidity and mortality (Figs 1, 2 and 3).

Although there are no specific diagnostic criteria for cesarean scar ectopic pregnancies, ultrasound findings should indicate an enlarged lower uterine segment with thin myometrium at the implantation site [16]. Furthermore, the trophoblast must be located between the bladder and anterior uterine wall, fetal parts cannot be located within the uterine cavity, and there should be discontinuity of the anterior uterine wall on a sagittal view [18]. Upon implantation on the uterine scar, cesarean scar ectopics can either extend into the cervico-isthmic space and into the uterine cavity (as occurred in this case study) or extend deeper into the myometrium toward to serosal surface of the uterus [13,18]. Both forms can result in substantial hemorrhage, although the latter also precludes a viable pregnancy [13,18]. Thus, suggested criteria for a cesarean scar ectopic pregnancy include: (a) gestational sac embedded eccentrically in the lower uterine segment, (b) implantation in the location of a prior cesarean delivery scar, (c) empty uterine cavity and cervical canal, (d) attenuated myometrium over the scar, and (e) extensive Doppler vascular flow in the area of the cesarean delivery scar [17]. Additionally, Kaelin Atgen *et al.* [2] distinguished implantation of the placenta “into” the prior cesarean scar compared to attachment “onto” the prior scar in the first trimester among continuing cesarean scar pregnancies. Implantation of the

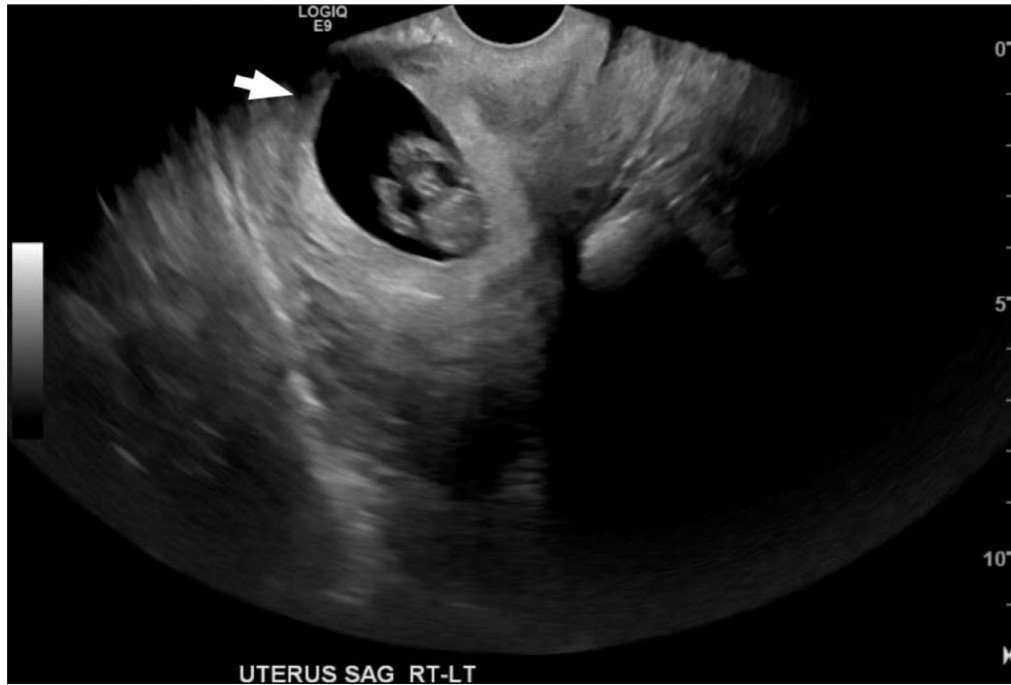

Fig. 1 – Sagittal transvaginal ultrasound showing an ectopic cesarean scar pregnancy (EGA 10 weeks, 4 days). The arrow indicates thinning of the anterior aspect of the myometrium.



Figs. 2 – Sagittal transabdominal ultrasound demonstrating the characteristics of cesarean scar ectopic pregnancy: Thin myometrium between gestational sac and uterine serosa.

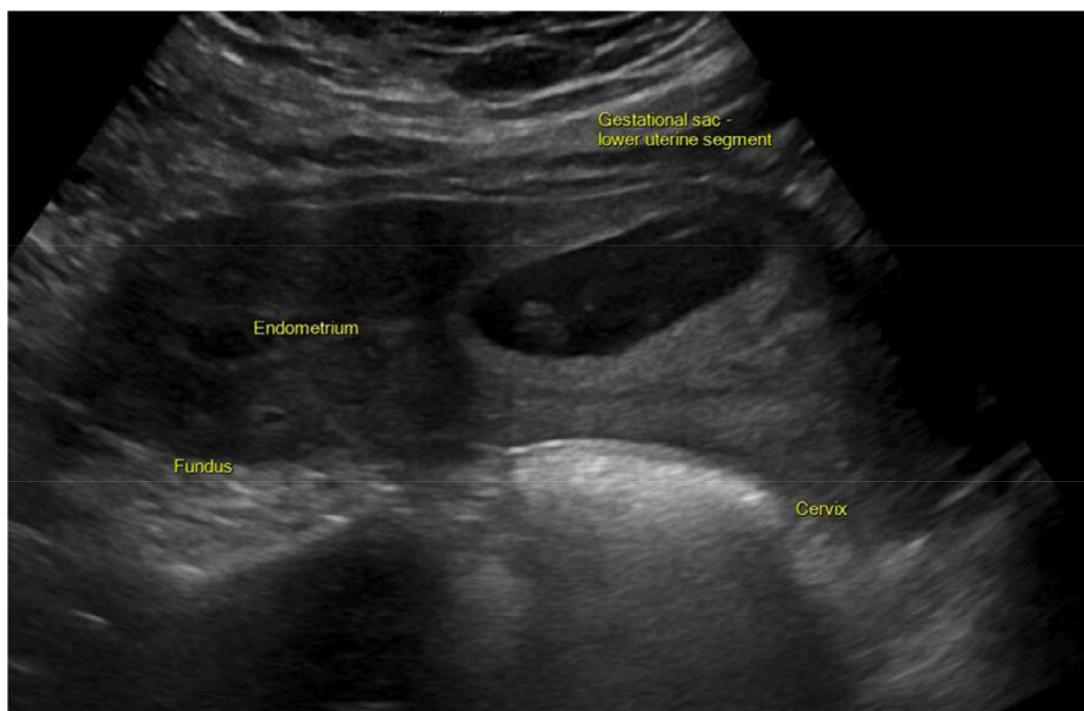


Fig. 3 – Sagittal transabdominal ultrasound demonstrating the characteristics of cesarean scar ectopic pregnancy: Low, anterior implantation of the gestational sac, absence of cervical involvement, extension toward the endometrium, and lack of normal endometrial cavity location.

placenta into the scar and myometrial thickness < 4 mm in the first trimester all resulted in cesarean hysterectomy for morbidly adherent placenta, with lower birth weight and earlier gestational age at delivery among those with implantation into the prior scar. An MRI may provide additional confirmation of the ultrasound findings and characterize the myometrial interface if the pregnancy is difficult to distinguish from other pregnancy complications such as a cervical ectopic pregnancy or consideration for expectant management of pregnancy is considered (Figs. 4–6) [13].

Although ultrasound remains the primary imaging modality for this diagnosis, MRI may be useful in the setting of equivocal cases and also may aid in the detection of possible placental implantation or bladder wall invasion. Sagittal T2-weighted images are best for visualizing the cesarean section scar, which appears as low signal. Imaging features include thinning of the myometrium in the region of the scar next to a gestational sac with a correspondingly empty endometrial canal and cervix [4]. Sagittal T2-weighted imaging can also be helpful in determining growth pattern of the gestational sac (ie whether it is primarily within the scar or within the isthmus). This may have implications in management and risk of rupture [14]. Additionally, T1 pre contrast imaging may be helpful in the detection of blood products in the canal and pelvis.

The case presented here highlights the importance of early diagnosis and management of a cesarean scar ectopic pregnancy. This patient's presentation was similar to other case reports found in the literature. She presented with painless first trimester vaginal bleeding [9,18]. This patient's gestational age

is also consistent with previous studies indicating a presentation between 5 and 12 weeks of gestation [13]. Because of the high clinical suspicion for a cesarean scar ectopic, the patient was able to undergo proper diagnosis and timely management. Imaging findings here demonstrate the eccentric location of the gestational sac, implantation of the placenta into the prior cesarean scar and thin residual (3 mm) myometrium. As the patient in this case study desired sterilization, surgical management was pursued with a total laparoscopic hysterectomy.

In patients who desire fertility after treatment of an ectopic pregnancy, physicians can offer medical and more conservative surgical management uterine wedge dissection [5,13]. Systemic methotrexate with or without intrasac methotrexate can be used in patients with a gestational age of less than 8 weeks without fetal cardiac activity [9,13]. However, medical treatment alone may leave the cesarean scar defect unrepaired and susceptible to complications in subsequent pregnancies [8,13]. Physicians should counsel patients who desire fertility, as 30% of these patients have difficulty conceiving after ectopic pregnancy treatment [3]. Moreover, physicians should discuss the long-term risks of these pregnancies on subsequent pregnancies including risk of recurrent ectopic pregnancy, uterine rupture, and placental attachment abnormalities [16].

In summary, there should remain a high clinical suspicion for a cesarean scar ectopic in a patient with a history of cesarean deliveries presenting with first trimester bleeding. These patients should be diagnosed with transvaginal ultrasound with confirmation with MRI if diagnosis is unable

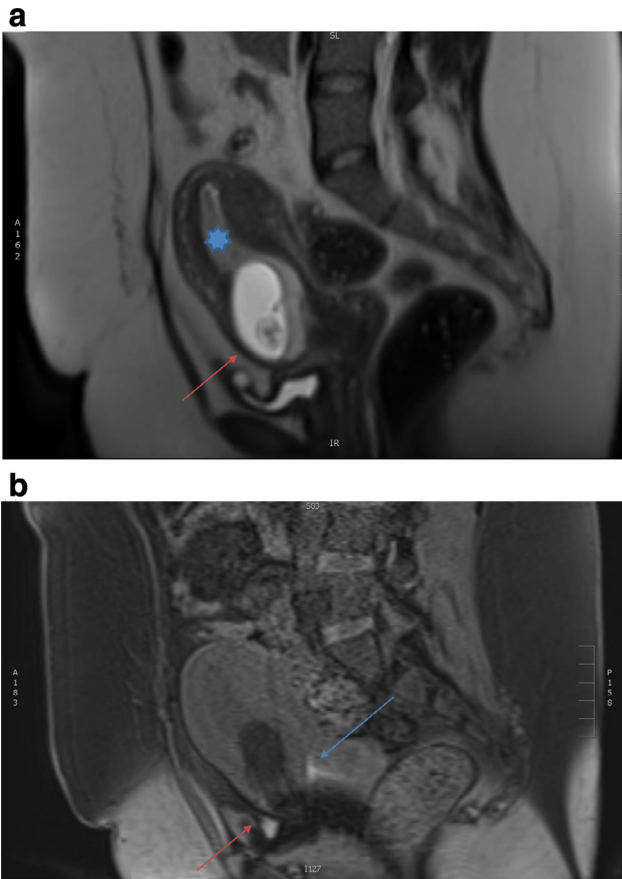


Fig. 4 – (a) Sagittal T2-weighted imaging demonstrating thinning of the anterior myometrium with low T2 signal (red arrow) and empty endometrial canal (*). (b) Sagittal T1 fat suppressed imaging demonstrating T1 hyperintense material in the pelvis (red arrow) and cervix (blue arrow) indicative of blood products.

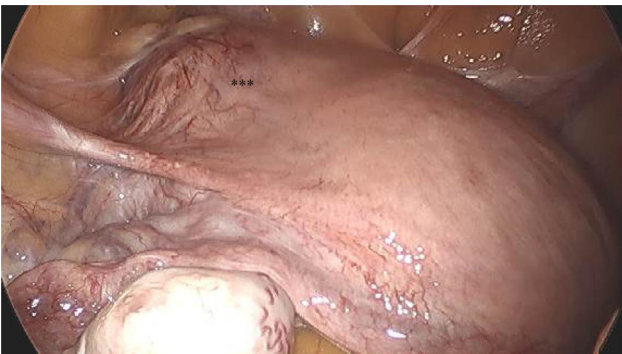

Fig. 5 – Intraoperative image of uterus, round ligament and fallopian tube. The cesarean scar ectopic is noted deforming the left lower anterior wall of the uterus with increased vascularity (*)**

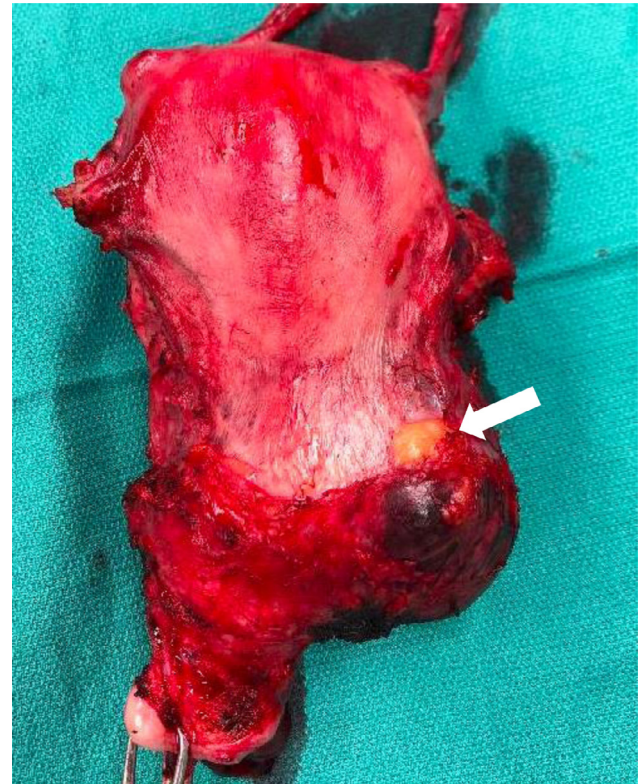

Fig. 6 – Pathologic specimen following laparoscopic hysterectomy. Ectopic gestation is noted to the left lower uterine segment with disruption of the myometrium.

to be made via ultrasound. To prevent maternal hemorrhage, a patient presenting with a cesarean scar ectopic pregnancy should undergo prompt treatment depending on her clinical status and reproductive preferences.

Supplementary materials

Supplementary material associated with this article can be found, in the online version, at doi:[10.1016/j.radcr.2018.12.001](https://doi.org/10.1016/j.radcr.2018.12.001).

REFERENCES

- [1] ACOG Committee on Practice Bulletins Tubal ectopic pregnancy: ACOG practice bulletin. Clin Manage Guidelines Obstet Gynecol 2018;131(3):e91–103. <https://doi.org/10.1097/AOG.0000000000002560>.
- [2] Kaelin Agten A, Cali G, Monteagudo A, Oviedo J, Ramos J, Timor-Tritsch I. The clinical outcome of cesarean scar pregnancies implanted “on the scar” versus “in the niche”. Am J Obstet Gynecol 2017;216(510):e1–6.
- [3] Alkatout I, Honemeyer U, Strauss A, Tinelli A, Malvasi A, Jonat W, et al. Clinical diagnosis and treatment of ectopic

- pregnancy. *Obstet Gynecol Surv* 2013;68(8):571–81. <https://doi.org/10.1097/OGX.0b013e31829cdbeb>.
- [4] El-sayed El-badawy A, El-agwany SA, El-habashy MA, Elmansy A. Lower uterine segment pregnancy (Cesarean Scar Pregnancy and early placenta accreta: a rising complication from cesarean section with possible and similar early ultrasound diagnoses and management. *Egypt J Radiol Nucl Med* 2015;46(4):977–80.
- [5] Cömert EH, Şal H, Ekici YS, Seda E, Guven G. Cesarean scar pregnancy: a case report. *Turkiye Klinikleri Jinekoloji Obstetrik* 2018;26(1):37–9. <https://doi.org/10.5336/gynobstet.2016-53978>.
- [6] Deutchman M, Tubay AT, Turok DK. First trimester bleeding. *Am Fam Phys* 2009;79(11):985–92. www.aafp.org/afpAmericanFamilyPhysician985.
- [7] Fylstra DL. Ectopic pregnancy not within the (distal) fallopian tube: etiology, diagnosis, and treatment. *Am J Obstet Gynecol* 2012;206(4):289–99. <https://doi.org/10.1016/j.ajog.2011.10.857>.
- [8] Fylstra DL, Pound-Chang T, Grant Miller M, Cooper A, Miller KM. Ectopic pregnancy within a cesarean delivery scar: a case report. *Am J Obstet Gynecol* 2002;187:302–4. <https://doi.org/10.1067/mob.2002.125998>.
- [9] Godin PA, Bassil S, Donnez J. An ectopic pregnancy developing in a previous caesarian section scar. *Fertil Steril* 1997;67(2):398–400. [https://doi.org/10.1016/S0015-0282\(97\)81930-9](https://doi.org/10.1016/S0015-0282(97)81930-9).
- [10] Hoover KW, Tao G, Kent CK. Trends in the diagnosis and treatment of ectopic pregnancy in the United States. *Am Coll Obstet Gynecol* 2010;115:495–502. <https://doi.org/10.1097/AOG.0b013e3181d0c328>.
- [11] Jurkovic D, Wilkinson H. Diagnosis and management of ectopic pregnancy. *BMJ* 2011;342(d3397):1353–7. <https://doi.org/10.1136/bmj.d3397>.
- [12] Marion LL, Meeks GR. Ectopic pregnancy: history, incidence, epidemiology, and risk factors. *Clin Obstet Gynecol* 2012;55(2):376–86. <https://doi.org/10.1097/GRF.0b013e3182516d7b>.
- [13] Patel MA. Scar ectopic pregnancy. *J Med Biol Eng* 2015;65(6):372–5. <https://doi.org/10.1007/s13224-015-0817-3>.
- [14] Peng K-W, Lei Z, Xiao T-H, Jia F-G, Zhong W-X, Gao Y, et al. First trimester caesarean scar ectopic pregnancy evaluation using MRI. *Clin Radiol* 2014;69(2):123–9.
- [15] Rosen T. Placenta accreta and cesarean scar pregnancy: overlooked costs of the rising cesarean section rate. *Clin Perinatol* 2008;35:519–29. <https://doi.org/10.1016/j.clp.2008.07.003>.
- [16] Rotas MA, Haberman S, Levгур M. Cesarean scar ectopic pregnancies etiology. *Am Coll Obstet Gynecol* 2006;107:1373–81. <https://doi.org/10.1097/01.AOG.0000218690.24494.ce>.
- [17] Timor-Tritsch IE, Monteagudo A, Cali G, El Refaey H, Kaelin Agten A, Arslan AA. Easy sonographic differential diagnosis between intrauterine pregnancy and cesarean delivery scar pregnancy in the early first trimester. *Am J Obstet Gynecol* 2016;215:225.e1–225.e7.
- [18] Vial Y, Petignat P, Hohlfeld P. Pregnancy in a cesarean scar. *Ultrasound Obstet Gynecol* 2000;16(6):592–3. <https://doi.org/10.1046/j.1469-0705.2000.00300-2.x>.