

[CASE REPORT]

Patency Capsule Aspiration

Keita Takeda^{1,2}, Hiroyuki Tashimo¹, Kazuko Miyakawa¹, Masahiro Shimada¹,
Nobuharu Ohshima¹, Atsuhisa Tamura¹, Hideaki Nagai¹ and Hirotoshi Matsui¹

Abstract:

A 77-year-old man with anemia who had undergone 2 abdominal surgeries for colon and gastric cancer experienced dyspnea after swallowing a patency capsule before endoscopy for investigating the cause of anemia. Chest radiography and computed tomography revealed that the patency capsule was located within the bronchus intermedius. It was successfully removed by flexible bronchoscopy. The balloon was placed over the capsule and inflated. Subsequently, the catheter was pulled, while thus dragging the capsule with it and preventing its destruction. In cases of patency capsule aspiration, the capsule must be removed without deformity, before it causes inflammation by releasing barium into the airway.

Key words: bronchial aspiration, complications, patency capsule

(Intern Med 59: 1071-1073, 2020)

(DOI: 10.2169/internalmedicine.4012-19)

Introduction

The use of capsule endoscopy, which is a relatively non-invasive method of mucosal examination, has increased worldwide. Since retention in the digestive tract is the most frequent complication of capsule endoscopy (1-3), a patency capsule is used to determine the risk of capsule retention before the procedure in patients with suspected small bowel stenosis (4, 5). Although capsule aspiration is a rare complication, only occurring in 0.003-0.130% of patients (1, 2, 6), the number of reports of aspiration has increased, and the potential risk of patency capsule aspiration has been discussed in the literature (7).

We herein describe the first reported case of patency capsule aspiration.

Case Report

A 77-year-old man with a medical history of sigmoid colon and partial small-bowel resection for colon cancer, proximal gastrectomy for gastric cancer, chronic right pneumothorax, and ischemic stroke was admitted to the emergency department due to dyspnea and bloody stool.

Laboratory tests revealed anemia with a hemoglobin con-

centration of 5.7 g/dL. Dyspnea improved after blood transfusion, and capsule endoscopy was subsequently planned to investigate the cause of the bloody stool. A patency capsule (PillCam Patency Capsule; Covidien, Tokyo, Japan) was administered first in order to avoid retention of the capsule endoscope, given the possibility of small-intestine stenosis after the operation. Just after swallowing the patency capsule, he complained of respiratory distress, with a percutaneous arterial oxygen saturation of 90% at room air. Chest radiography and computed tomography revealed that the capsule was located within the bronchus intermedius (Fig. 1, 2). He was referred to our hospital for the removal of the patency capsule.

Flexible bronchoscopy without tracheal intubation under local anesthesia revealed that the patency capsule was still in the bronchus intermedius (Fig. 3). We successfully retrieved the capsule without crushing it using a balloon catheter (Olympus B5-2C, Olympus, Tokyo, Japan). The balloon was placed over the capsule in the bronchus intermedius and inflated by injecting 2 cc of air using a 2.5-cc syringe, thus preventing the capsule from migrating into the narrower bronchi. Subsequently, the catheter was pulled, dragging the capsule with it and preventing damage (Fig. 4). The patency capsule was removed 7 hours after aspiration, without deforming it, and the patient's respiratory symptoms dimin-

¹Center for Pulmonary Diseases, National Hospital Organization Tokyo National Hospital, Japan and ²Department of Basic Mycobacteriology, Graduate School of Biomedical Science, Nagasaki University, Japan

Received: October 5, 2019; Accepted: November 24, 2019; Advance Publication by J-STAGE: January 9, 2020

Correspondence to Dr. Keita Takeda, takeda.keita.ax@mail.hosp.go.jp

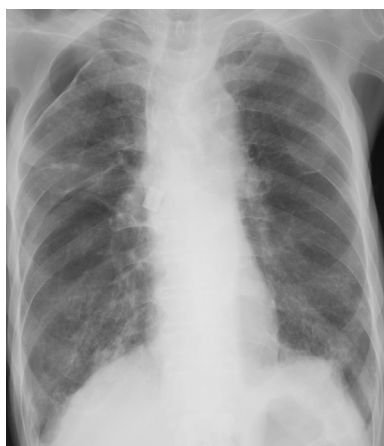

Figure 1. Chest radiography showing that the capsule is located within the bronchus intermedius and right pneumothorax.

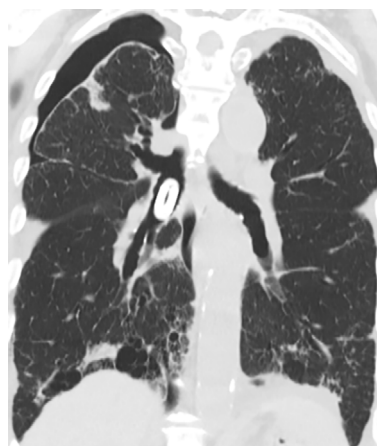


Figure 2. A coronal section of a computed tomography scan showing that the capsule is located in the bronchus intermedius and right pneumothorax.

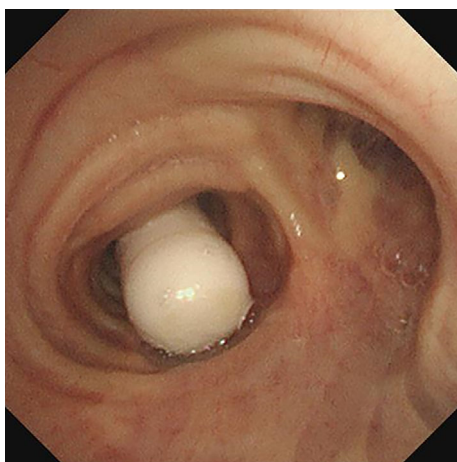


Figure 3. A bronchoscopic view showing that the patency capsule was still present in the bronchus intermedius.

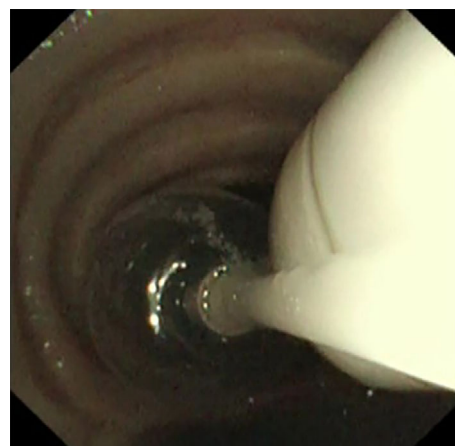


Figure 4. The patency capsule was dragged out by pulling the balloon catheter.

ished after removal of the capsule.

Discussion

A patency capsule is used to determine the risk of capsule retention before capsule endoscopy. It is identical in shape and size to a capsule endoscope (11 mm in diameter and 26 mm in length). The capsule, filled with lactose admixed with barium, dissolves spontaneously on contact with the digestive secretions 30-40 hours later and is not retained in the digestive tract (3, 8).

The possibility of patency capsule aspiration, which is similar to that of capsule endoscope aspiration, should be considered (7). Although the presence of dysphagia was ruled out based on the lack of any episodes of aspiration pneumonia or choking on food, the patient was considered at risk of silent aspiration due to his advanced age and history of ischemic stroke (9).

When a patient aspirates the patency capsule, it might disintegrate within the respiratory tract and thus release the

contrast medium into the airways, thereby causing inflammation (10). Therefore, the capsule must be removed without deforming it before its spontaneous dissolution in the airway.

Bronchoscopy is usually required for the removal of an aspirated capsule. Flexible bronchoscopy is preferred over rigid bronchoscopy under general anesthesia for the removal of a foreign body in elderly patients (11), although most aspirated capsule endoscopes have reportedly been removed using rigid bronchoscopy and basket forceps. In the present case, the risks of exacerbating chronic pneumothorax using general anesthesia and breaking the patency capsule using forceps or basket forceps were considered.

We concluded that, in cases of patency capsule aspiration, the capsule must be removed without deformity before it causes inflammation by releasing barium into the airway. To our knowledge, this is the first report of a case of patency capsule aspiration.

This case report was approved by the Institutional Review Board of NHO Tokyo National Hospital. This work was carried

out in accordance with the Declaration of Helsinki.

The authors state that they have no Conflict of Interest (COI).

References

1. Rondonotti E, Herrerias JM, Pennazio M, Caunedo A, Mascarenhas-Saraiva M, de Franchis R. Complications, limitations, and failures of capsule endoscopy: a review of 733 cases. *Gastrointest Endosc* **62**: 712-716, 2005.
2. Fernandez-Urién I, Carretero C, Gonzalez B, et al. Incidence, clinical outcomes, and therapeutic approaches of capsule endoscopy-related adverse events in a large study population. *Rev Esp Enferm Dig* **107**: 745-752, 2015.
3. Buscot M, Leroy S, Pradelli J, et al. Bronchial aspiration of capsule endoscope. *Respiration* **93**: 122-125, 2017.
4. Ho KK, Joyce AM. Complications of capsule endoscopy. *Gastrointest Endosc Clin N Am* **17**: 169-178, 2007.
5. Barkin JS, O'Loughlin C. Capsule endoscopy contraindications: complications and how to avoid their occurrence. *Gastrointest Endosc Clin N Am* **14**: 61-65, 2004.
6. Yung DE, Plevris JN, Koulaouzidis A. Short article: aspiration of capsule endoscopes: a comprehensive review of the existing literature. *Eur J Gastroenterol Hepatol* **29**: 428-434, 2017.
7. Mannami T, Ikeda G, Seno S, et al. Capsule endoscope aspiration after repeated attempts for ingesting a patency capsule. *Case Rep Gastroenterol* **9**: 347-352, 2015.
8. Tanabe H, Ando K, Ohdaira H, et al. Successful medical treatment for a Crohn's disease patient with a perforation by a second-generation patency capsule. *Endosc Int Open* **6**: E1436-E1438, 2018.
9. Kikuchi R, Watabe N, Konno T, Mishina N, Sekizawa K, Sasaki H. High incidence of silent aspiration in elderly patients with community-acquired pneumonia. *Am J Respir Crit Care Med* **150**: 251-253, 1994.
10. Ohkuma K, Saraya T, Tsujimoto N, Takizawa H. Massive barium sulfate aspiration in the bronchial tree. *Intern Med* **54**: 2081, 2015.
11. Lucendo AJ, González-Castillo S, Fernández-Fuente M, De Rezende LC. Tracheal aspiration of a capsule endoscope: a new case report and literature complication of an increasingly reported complication. *Dig Dis Sci* **56**: 2758-2762, 2011.

The Internal Medicine is an Open Access journal distributed under the Creative Commons Attribution-NonCommercial-NoDerivatives 4.0 International License. To view the details of this license, please visit (<https://creativecommons.org/licenses/by-nc-nd/4.0/>).