

Small Septal Branch Artery Thrombus Inducing Ventricular Fibrillation: To Intervene or Not to Intervene

Vratika Agarwal¹, Peter C Olson² , Jad Mroue², Yefim Olkovsky¹, Soad Bekheit³ and James Lafferty¹

¹Department of Cardiology, Staten Island University Hospital, Northwell Health, Staten Island, NY, USA. ²Department of Internal Medicine, Staten Island University Hospital, Northwell Health, Staten Island, NY, USA. ³Department of Electrophysiology, Staten Island University Hospital, Northwell Health, Staten Island, NY, USA.

Clinical Medicine Insights: Case Reports
Volume 12: 1–3
© The Author(s) 2019
Article reuse guidelines:
sagepub.com/journals-permissions
DOI: 10.1177/1179547619828717



ABSTRACT: A 64-year-old woman presented for chest pain and was diagnosed with anteroseptal ST segment elevation myocardial infarction (STEMI). Emergent angiography showed 95% stenosis at the ostium of the second septal branch, consistent with thrombus, and no other significant lesions. The lesion was not amenable to intervention due to small caliber. Post angiography, the patient's electrical rhythm deteriorated into ventricular fibrillation. Following resuscitation, repeat angiography confirmed same findings. Electrophysiology study at 3 months was positive for inducing fibrillation. Due to patient risk factors, she had placement of a dual chamber defibrillator. A 5-month follow-up echocardiogram showed a small area of ventricular septal wall bowing, consistent with blood supply from septal territory.

KEYWORDS: Acute Coronary Syndrome, intervention, complications

RECEIVED: November 9, 2018. **ACCEPTED:** January 13, 2019.

TYPE: Case Report

FUNDING: The author(s) received no financial support for the research, authorship, and/or publication of this article.

DECLARATION OF CONFLICTING INTERESTS: The author(s) declared no potential conflicts of interest with respect to the research, authorship, and/or publication of this article.

CORRESPONDING AUTHOR: Peter C Olson, Department of Internal Medicine, Staten Island University Hospital, Northwell Health, Staten Island, NY, USA.
Email: polson3@northwell.edu

Introduction

Over the years, acute coronary syndrome (ACS) has been subject to a number of research papers and guidelines. As a result, the major cardiology societies have generally reached a consensus regarding treatment of ST segment elevation myocardial infarction (STEMI), non-ST segment elevation myocardial infarction (NSTEMI), and unstable angina in the major coronary arteries.¹ Despite this agreement, septal branch artery events present a difficulty for interventional cardiologists. Septal branch arteries supply most of the inter-ventricular septum, which constitutes about a third of the left ventricular wall area. In addition, these arteries supply the His bundles and AV node in about 50% of patients.^{2–4} Due to this anatomy, septal infarctions lead to angina, arrhythmias, and biventricular failure.⁵ Rarely, thrombosis of larger diameter septal branch arteries causes ACS. Due to the rarity of septal branch artery ACS, the literature has a lack of data for interventional cardiologists regarding intervention on these lesions.³ Without proper literature, data, and guidelines, the cardiologist community often leans away from intervention on septal branch ACS. The community offers a variety of reasons for this decision. These reasons include the typical small caliber of septal branch vessels, typically higher rates of in-stent restenosis, inability to access the vessels surgically, and vessel origin acute angulation.^{2,4} While these are valid reasons, declining to intervene on a patient with septal artery disease causing ACS runs the risk of complications such as malignant arrhythmias, septal rupture, and death. In our case, we present a patient with STEMI secondary to a septal

branch thrombus and the subsequent complications after the interventional cardiologist decided to treat the lesion with medical therapy. Subsequently, we suggest that interventional cardiologists should remain vigilant for septal branch ACS cases that are available for intervention.

Case

A 64-year-old woman presented with chest pain and diaphoresis for 4 hours prior to presentation. She was known to have a past medical history of coronary artery disease with 3 prior coronary interventions, hypertension, hyperlipidemia, type 2 diabetes mellitus, and ischemic cardiomyopathy. In the emergency room, the patient had a troponin of <0.02, but was found to have ST segment elevations in V3, V4, and V5 and diagnosed with STEMI. Subsequently, the patient was taken for emergent angiography to the cardiac catheterization lab.

Angiography showed a lesion on the second septal branch, which was described as a 95% tubular stenosis at the ostium of the vessel origin. The lesion had a small filling defect, consistent with possible thrombus and TIMI 1 flow. Given these data, the interventional cardiologist suspected the lesion as the culprit lesion, but described the thrombus as not amenable to intervention. The remainder of the angiography showed no significant occlusion, and sites of old percutaneous coronary intervention (PCI) had 0% occlusion. At that time, left ventricular ejection fraction (LVEF) was noted to be 60%.

Following angiography, the patient was transferred to the critical care unit (CCU) for observation and monitoring.



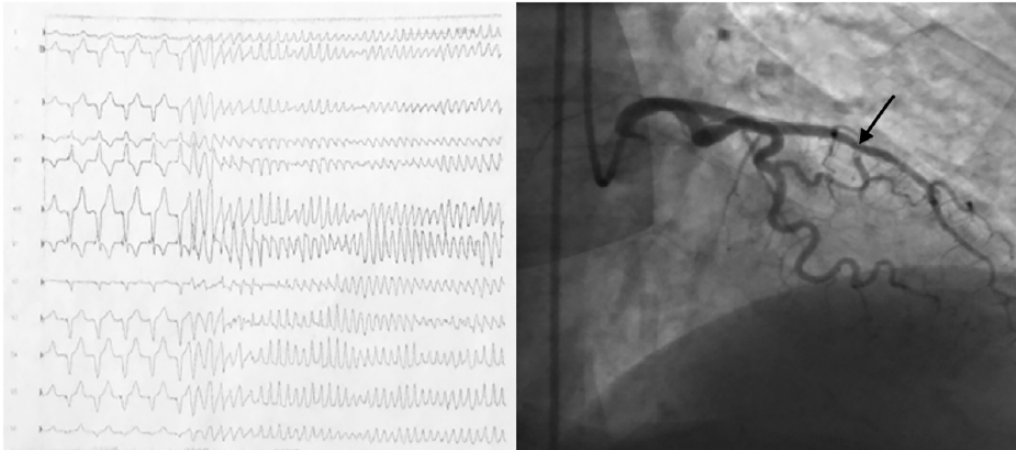


Image 1. EKG image from electrophysiological study showing induced ventricular fibrillation and angiographic image showing septal occlusion with thrombus.

Two hours post angiography, the patient's electrical rhythm deteriorated into ventricular tachycardia and then ventricular fibrillation. Advanced cardiac life support protocol was initiated, and the patient was successfully resuscitated. The patient was then taken again to the cardiac catheterization lab for emergent angiography, with the exact same findings as prior. Subsequent same-day echocardiography showed a LVEF of 25% to 30%, grade 1 diastolic dysfunction, and hypokinesia of basal mid-anterior, basal mid-anteroseptal, and apical walls. Troponin T levels peaked on the same day at 18.23 (normal value < 0.02).

Three days after resuscitation efforts, the patient had repeat echocardiography showing a LVEF of 45% to 50%, grade 1 diastolic dysfunction, and hypokinesia of anteroseptal and mid-inferoseptal walls.

Consultation with electrophysiology was completed, with suggestion that the thrombus of the second septal branch was the cause of the patient's ventricular arrhythmia. The patient was discharged when stable with a wearable defibrillator, to follow up for electrophysiological study after 3 months.

Three months after the above sequence of events, the patient returned to the electrophysiology service for study, with ventricular programmed stimulation. The study was positive for inducing fibrillation, which required 360J external shock (Image 1). Due to the patient's risk factors, which included cardiomyopathy, coronary artery disease not amenable to revascularization, presence of LV scar, and positive electrophysiology study for induced ventricular fibrillation, she was determined to be at risk for future ventricular arrhythmias and subsequent cardiac death. Given this assessment, the patient was determined to need high-dose beta blocker and antiarrhythmic therapy. Patient also had placement of a dual-chamber implantable cardioverter defibrillator (ICD) for treatment of ventricular arrhythmias and atrial pacing for suppression of ventricular arrhythmias.

Two months after placement of ICD, and 5 months after initial event, the patient returned to her outpatient cardiologist

for follow-up. She has tolerated the ICD and medical therapy well, with no adverse events since. Echocardiogram was done, which showed a normal LVEF and a small area of ventricular septal wall bowing, consistent with blood supply from septal territory (Image 1).

Discussion

Coronary artery disease of septal branch arteries is common. Symptoms most often present as angina, arrhythmias, conduction abnormalities, and congestive heart failure secondary to ventricular dysfunction.⁵ Rarely, patients present with acute ACS secondary to septal branch artery occlusion. Currently, guidelines are unclear regarding intervention on these lesions, leaving interventional cardiologists without proper data to make decisions.¹ Cardiologists must decide between PCI and medical management, with aspiration thrombectomy an occasional choice.⁶

Due to the intra-septal course of septal branch arteries, intervention options on these vessels are limited. Angiography with PCI has shown some success, although current literature suggests that in-stent stenosis rates are elevated when compared with stenting of other coronary vessels.^{2,4,7,8} Unfortunately, there is currently no role for coronary artery bypass grafting given the inaccessible, interior course of these arteries. Case reports have suggested a possibility for aspiration thrombectomy as a solution, although further research is needed before this option is used more widely.⁵ Given the dearth of options available, interventional cardiologists often proceed with medical therapy for treatment of septal artery occlusion due to thrombus.

Our case demonstrates the risks taken when choosing the option of medical therapy on these lesions. As with any acute myocardial infarction, when a patient is treated medically as opposed to with revascularization, they have an increased risk of arrhythmia, heart failure, and death. Our patient suffered a fatal arrhythmia, but was resuscitated by the medical team. Subsequent electrophysiological study confirmed that this

arrhythmia occurred as a direct effect of infarction of the myocardial tissue involving her septal conduction system.

Despite the infrequency of septal branch artery ACS events, cardiologists should consider the intervention possibilities and the possible complications that may follow. Interventional cardiologists should remain vigilant for opportunities to provide revascularization to these patients whenever possible. We also call for more research to be done on the topic, such that guidelines may further help guide the interventional cardiology community.

Authors' Note

Vratika Agarwal is now affiliated with Department of Interventional Cardiology, Columbia University, New York -Presbyterian, New York NY, USA.

Author Contributions

Conceived and designed the experiments: VA and PO. Analyzed the data: VA and PO. Wrote the first draft of the manuscript: PO. Contributed to the writing of the manuscript: JM, VA, and YO. Agree with manuscript results and conclusions: VA, PO, JM, YO, SB, and JL. Jointly developed the structure and arguments for the paper: VA, PO, and JM. Made critical revisions and approved final version: VA, YO, SB, and JL. All authors reviewed and approved of the final manuscript: VA, PO, JM, YO, SB, and JL.

Informed Consent

The author(s) provided and received informed consent from the patient for the writing and reproduction of this case report.

ORCID iD

Peter C Olson  <https://orcid.org/0000-0002-7022-4291>

REFERENCES

1. Kushner FG, Hand M, Smith SC, et al. 2009 focused updates: ACC/AHA guidelines for the management of patients with ST-elevation myocardial infarction (updating the 2004 guideline and 2007 focused update) and ACC/AHA/SCAI guidelines on percutaneous coronary intervention (updating the 2005 guideline and 2007 focused update) a report of the American College of Cardiology Foundation/American Heart Association Task Force on Practice Guidelines. *J Am Coll Cardiol.* 2009;54:2205–2241.
2. Cohen ID, Khosla S, Levin TN, Feldman T. Rotational atherectomy for left anterior descending artery septal perforator stenosis. *Catheter Cardiovasc Interv.* 1999;46:79–82.
3. Regar E, Kozuma K, Ligthart J, Carlier SG, de Vries A, Serruys PW. Coronary stent implantation in a septal perforator artery: case report and review of the literature. *Jpn Circ J.* 2000;64:802–804.
4. Ozdemir M, Timurkaynak T, Cemri M, et al. Stenting of the septal perforator coronary artery. *J Invasive Cardiol.* 2001;13:694–697.
5. Dorfman TA, Resar JR. Thrombotic occlusion of a large septal perforator presenting as ST-segment elevation in V1-V2 and treated with aspiration thrombectomy: a brief review of the literature. *J Invasive Cardiol.* 2011;23:E255–E259.
6. Tomcsanyi J, Bozsik B, Zsoldos A, Simor T. Isolated spontaneous septal myocardial infarction. *J Electrocardiol.* 2012;45:280–282.
7. Topaz O, DiSciascio G, Vetrovec GW, et al. Application of coronary angioplasty to the septal perforator arteries. *Cathet Cardiovasc Diagn.* 1991;22:7–13.
8. Vemuri DN, Kocher GS, Maniet AR, Banka VS. Angioplasty of the septal perforators: acute outcome and long-term clinical efficacy. *Am Heart J.* 1993;125:682–686.