



## CASE REPORT

## REVISED Case Report: Transient cortical blindness following coronary angiography [version 2; peer review: 2 approved]

Yudi Her Oktaviono <sup>1</sup>, Maureen Victoria Kawilarang<sup>1</sup>, Michael Kawilarang<sup>1</sup>, Ruth Irena Gunadi<sup>1</sup>, Petrina Theda Philothra<sup>2</sup>, Makhyan Jibril Al Farabi<sup>1</sup>

<sup>1</sup>Departement of Cardiology and Vascular Medicine, Soetomo General and Academic Hospital, Faculty of Medicine, Universitas Airlangga, Surabaya, Indonesia

<sup>2</sup>Department of of Physical Medicine and Rehabilitation, Soetomo General and Academic Hospital, Faculty of Medicine, Universitas Airlangga, Surabaya, Indonesia

**V2** First published: 03 Jun 2021, 10:439  
<https://doi.org/10.12688/f1000research.50821.1>

Latest published: 24 Aug 2022, 10:439  
<https://doi.org/10.12688/f1000research.50821.2>

### Abstract




Temporary blindness, also known as transient cortical blindness, is an uncommon impediment of contrast agent usage during angiography procedures. The occurrence of blindness after a cardiac catheterization procedure is rare and its pathophysiology remains largely speculative. The most probable mechanism seems to be contrast agent-related disruption of the blood-brain barrier, possibly initiated by several predisposing factors. This case reports a 52-year-old man with transient vision loss that occurred following coronary angiography. Brain magnetic resonance imaging (MRI) showed no acute pathology and his vision spontaneously returned within approximately 15 hours post-procedure without any requirement of specific therapy. Suggesting that transient cortical blindness may have occurred following coronary angiography which subsequently self-resolved.



### Keywords

transient blindness during coronary angiography, contrast induced blindness, transient cortical blindness, contrast reaction, case report

### Open Peer Review

Approval Status  

	1	2
<b>version 2</b>		
(revision)		
24 Aug 2022	<a href="#">view</a>	<a href="#">view</a>
		
<b>version 1</b>		
03 Jun 2021		
	<a href="#">view</a>	<a href="#">view</a>

1. **Antonia Anna Lukito** , Siloam Hospitals Lippo Village, Tangerang, Indonesia
2. **Zhen-Vin Lee** , University Malaya Medical Centre, Kuala Lumpur, Malaysia

Any reports and responses or comments on the article can be found at the end of the article.



This article is included in the **Eye Health** gateway.

**Corresponding author:** Yudi Her Oktaviono ([yoktaviono@gmail.com](mailto:yoktaviono@gmail.com))

**Author roles:** **Oktaviono YH:** Conceptualization, Data Curation, Resources, Validation; **Kawilarang MV:** Data Curation, Investigation, Methodology, Writing – Original Draft Preparation; **Kawilarang M:** Investigation, Resources, Supervision; **Gunadi RI:** Formal Analysis, Supervision, Validation, Writing – Review & Editing; **Philothra PT:** Funding Acquisition, Investigation, Methodology, Project Administration; **Al Farabi MJ:** Investigation, Methodology, Writing – Original Draft Preparation, Writing – Review & Editing

**Competing interests:** No competing interests were disclosed.

**Grant information:** The writing and publication of this study was supported by LPDP (Indonesian Endowment Fund for Education). *The funders had no role in study design, data collection and analysis, decision to publish, or preparation of the manuscript.*

**Copyright:** © 2022 Oktaviono YH *et al.* This is an open access article distributed under the terms of the [Creative Commons Attribution License](#), which permits unrestricted use, distribution, and reproduction in any medium, provided the original work is properly cited.

**How to cite this article:** Oktaviono YH, Kawilarang MV, Kawilarang M *et al.* **Case Report: Transient cortical blindness following coronary angiography [version 2; peer review: 2 approved]** F1000Research 2022, 10:439 <https://doi.org/10.12688/f1000research.50821.2>

**First published:** 03 Jun 2021, 10:439 <https://doi.org/10.12688/f1000research.50821.1>

**REVISED Amendments from Version 1**

Figure 1 was revised since there are swapped image.

**Any further responses from the reviewers can be found at the end of the article**

**Introduction**

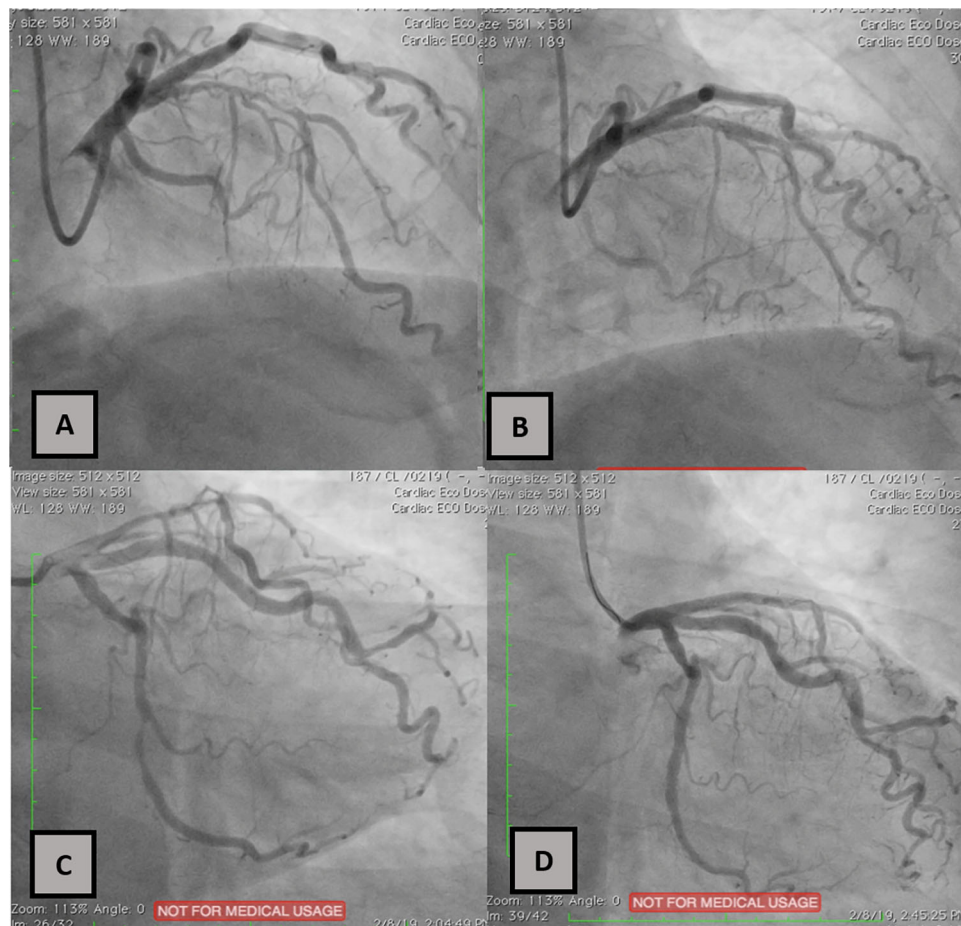
Coronary angiography is a dependable diagnostic technique with low risk (below 0.5%) of significant complications (acute cardiac failure, cerebrovascular accidents), and mortality rate under 0.2%. Contrast-induced vision loss in coronary angiography is one of its rare complication.<sup>1</sup> We describe a rare incident of transitory cortical blindness following a coronary angiography procedure, followed by discussion comparing previous temporary cortical blindness as contrast-related complication in angiographic procedures.

**Case report****Patient information**

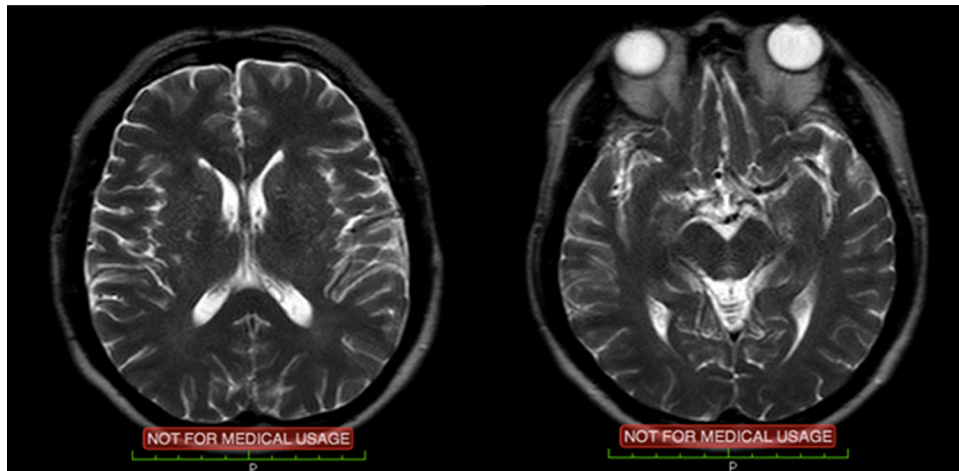
A 52-year-old male (Asian, private employee) with stable angina pectoris came to the Cardiac Catheterization Unit in July 2019 to have a diagnostic coronary angiography (DCA). He frequently experienced chest pain and fatigue during strenuous activity, with a history of hypertension, smoking and allergic reactions to amoxicillin and shrimp. There was no family history of cardiac disease and the patient had not previously undergone a coronary angiography.

**Clinical findings**

Physical examinations, electrocardiography (ECG), and laboratory data were all in normal limits.



**Figure 1.** Percutaneous coronary intervention was performed at the left anterior descending (LAD) artery (A: before; B: after) and the left circumflex (LCx) artery (C: before; D: after).



**Figure 2.** Brain magnetic resonance imaging (MRI) showing no signs of acute infarction or hemorrhagic processes.

### Diagnostic assessment

The patient underwent DCA using Iopamiro contrast (non-ionic, low-osmolar iodinated contrast agent), which then revealed significant stenosis of 85% in the distal left circumflex (LCx) artery and proximal left anterior descending (LAD) branches. Percutaneous coronary intervention (PCI) was subsequently performed, however, during the stenting procedure he suddenly complained of total blindness (Visus 0/0). There were no other complaints, and vital signs was stable. Two stents were installed at LCx and LAD arteries with thrombolysis in myocardial infarction (TIMI) 3-flow results are shown in [Figure 1](#).

Post PCI procedure the patient referred to the neurology department and underwent urgent non-contrast brain magnetic resonance imaging (MRI) followed by a non-contrast magnetic resonance angiography (MRA). Neither tests displayed any acute ischemic cerebral infarction ([Figure 2](#)). Nevertheless, there were signs of chronic ischemic infarction in the left corona radiata and chronic infarction in the left paramedian cerebral pons, with multiple bilateral small vessels ischemia in the corona radiata, centrum semiovale and subcortical parietal.

### Therapeutic intervention

The patient was then given 10 mg dexamethasone intravenous (IV) bolus, maintained with 5 mg dexamethasone injection every six hours, alongside citicoline 1 gr and methylcobalamine 500mcg injection to reduce the damage that may have occurred while the blindness persisted.

### Follow up and outcome

Approximately 15 hours post PCI procedure, the patient fully regained his eyesight. There were no blurred vision or other complaints, vital signs and physical examination were within normal limits. The patient was discharged two days later with an additional diagnosis of contrast induced transient blindness.

### Discussion

Transient cortical vision loss is a complication that may occur in various types of angiographic procedures, particularly vertebral artery angiography, nevertheless this event is rare in coronary angiography.<sup>2,3</sup> Cortical blindness is characterized by total or partial eyesight loss, while ocular movement and pupil responses are not affected.<sup>4</sup> Estimated incidence of events during/after coronary angiography is 0.05%.<sup>5</sup> The types of contrast agents (ionic and non-ionic contrast and also isotonic iodixanol) are associated with these complications.<sup>2</sup> The final outcome of these events are mostly satisfactory, with spontaneous gain of vision within 24-48 hours of onset without requiring any treatment.

The pathophysiology of cortical blindness itself is still unclear, various mechanism hypotheses have been propositioned such as direct toxicity from contrast agents, micro emboli, hypoxia, or cerebral oedema.<sup>1,3</sup> Immunological mechanisms are thought to be associated with the incidence of cortical blindness related to radiocontrast.<sup>6</sup> Usage of hyperosmolar solutions can increase the permeability of the blood-brain barrier in the occipital region which may facilitate contrast agents enter the visual cortex area due to poor localization during the procedure.<sup>7</sup> Patients with chronic hypertension may have higher susceptibility to increased blood-brain barrier permeability.<sup>8</sup> Once the contrast agent has been excreted, vision will

return as blood-brain barrier protective function returns.<sup>9</sup> One of the main risk factors for this complication is the type of contrast agent used. The incidence of transient cortical blindness is more frequent with hyperosmolar contrast agents. Other important risk factors are uncontrolled hypertension, hypotension, kidney failure, use of immunosuppressant drugs and dehydration.<sup>10</sup> Viscosity, hyperosmolarity, and contrast agent solubility profile may contribute to increased risk of neurotoxicity, but the role of contrast volume is still debatable.<sup>11</sup> Symptoms typically begin to appear during the procedure or within the following 12 hours, with various symptoms such as cephalgia, disorientation, nausea, vomiting, decrease of consciousness, followed by sudden onset of total vision loss.<sup>12</sup>

The diagnostic approach to cortical blindness involved brain imaging, which remains the gold standard to rule out other causes of acute vision loss, such as bleeding and embolic stroke, especially after intra-arterial procedures.<sup>13</sup> MRI with T2 and FLAIR is the best modality to rule out other acute causes. There are case reports of FLAIR hyper intensity in the occipital region with diffusion weighted imaging (DWI) which is nearly normal and showed a perfect resolution on repeated MRI. However, the majority of acute vision loss cases show normal MRI results. MRI is still the best diagnostic tool to detect ischemic changes in early stages, specifically for case of periprocedural cortical blindness.<sup>14</sup>

Various contrast agent formulations containing iodine have been used for several years to visualize blood vessels. All of these formulations have similar iodine concentrations, but differ significantly in their structure, osmolality, and viscosity.<sup>15</sup> Types of contrast agents are divided into three generation categories, the first is high-osmolality contrast media (HOCM) generation, the second is low-osmolality contrast media (LOCM) generation, and the latest generation is isoosmolar contrast media (IOCM) where its osmolality is similar to blood.<sup>16</sup>

Contrast reactions can be chemotoxic reactions or hypersensitivity reactions. Chemotoxic reactions are mostly related with the chemical nature of agent. The chemotoxic reaction also depends on the contrast dose and the speed of the contrast administration. These include volume overload, vasovagal reactions, cardiotoxicity, and nephrotoxicity. Hypersensitivity reactions, or allergic reactions, are idiosyncratic and do not depend on the rate or volume of the contrast infusion. They commonly occur immediately, within seconds to the first hour after exposure. Combination of symptoms such as pruritus, urticaria, rashes, angioedema, laryngospasm, bronchospasm, hypotension, syncope, shock, or even death may also occur. The incidence rate of mild hypersensitivity reactions is approximately 9%, and severe hypersensitivity reactions are 0.2% to 1.6%.<sup>17</sup> Death events are <1/100.000 patients.<sup>18</sup> These incidence rates are seven times higher in elderly.<sup>19</sup>

The pathophysiology of hypersensitivity reactions are still poorly understood. Clinical manifestations may be similar to anaphylactic reactions; however, most hypersensitivity contrast reactions are not mediated by IgE.<sup>20</sup> The most possible aetiology is an anaphylactoid reaction involving direct activation of mast cells and massive degranulation of histamine. Activation of the coagulation and kinin cascade, serotonin release, and inhibition of platelets may also play a role.<sup>21</sup> Ionic contrast such as HOCM causes more hypersensitivity reactions than non-ionic contrast LOCM. Hypersensitivity reactions occur even less frequently with non-ionic IOCM Iodixanol contrast.<sup>22</sup> An important risk factor is history of previous anaphylactic reactions to contrast media, as well as history of previous allergies or asthma.<sup>23</sup> Glucocorticoids therapy in anaphylactoid contrast reaction may improve symptoms, such as 125 mg IV methylprednisolone may be given to prevent repeated reactions in the hours following the procedure.<sup>15</sup>

## Conclusion

Transient cortical blindness is a rare complication that occurs in various types of angiographic procedures, one of which is coronary angiography. The possible predisposing factors for this event include chronic hypertension and history of previous allergies. Brain MRI remains the principal diagnostic tool, with additional benefit to rule out other causes of acute vision loss, such as bleeding and embolic stroke, especially after intra-arterial procedures. Final outcome of transient cortical blindness is generally promising, with spontaneous return of vision within 24-48 hours without requiring specific therapy. Means of prevention and specific treatment are not established yet, more data and studies are required to further investigate this rare event.

## Patient perspective

From the patient's perspective, sudden blindness after diagnostic coronary angiography was unexpected and made him afraid of permanent blindness as a consequence. The patient also considered this as a subtle medical error. However, when the patient's sight returned, the patient was extremely relieved.

## Data availability

All data underlying the results are available as part of the article and no additional source data are required.

## Consent

Written informed consent for publication of their clinical details and clinical images was obtained from the patient.

## References

1. de Lara JG, Vázquez-Rodríguez JM, Salgado-Fernández J, et al.: **Transient Cortical Blindness Following Cardiac Catheterization: An Alarming but Infrequent Complication With a Good Prognosis.** *Rev Esp Cardiol (English Ed)*. 2008; **61**(1): 88–90.  
[PubMed Abstract](#) | [Publisher Full Text](#)
2. Merchut MP, Richie B: **Transient Visuospatial Disorder From Angiographic Contrast.** *Arch Neurol*. 2002; **59**(5).  
[PubMed Abstract](#) | [Publisher Full Text](#)
3. Sticherling C, Berkefeld J, Auch-Schwelk W, et al.: **Transient bilateral cortical blindness after coronary angiography.** *Lancet*. 1998; **351**(9102): 570.  
[PubMed Abstract](#) | [Publisher Full Text](#)
4. Fischer-Williams M, Gottschalk PG, Browell JN: **Transient cortical blindness: An unusual complication of coronary angiography.** *Neurology*. 1970; **20**(4): 353–353.  
[PubMed Abstract](#) | [Publisher Full Text](#)
5. Studdard WE, Davis DO, Young SW: **Cortical blindness after cerebral angiography.** *J Neurosurg*. 1981; **54**(2): 240–244.  
[PubMed Abstract](#) | [Publisher Full Text](#)
6. Demirtas M, Birand A, Usal A: **Transient cortical blindness after second coronary angiography: is immunological mechanism possible?** *Cathet Cardiovasc Diagn*. 1994; **31**(2): 161.  
[PubMed Abstract](#) | [Publisher Full Text](#)
7. Junck L, Marshall WH: **Neurotoxicity of radiological contrast agents.** *Ann Neurol*. 1983; **13**(5): 469–484.  
[PubMed Abstract](#) | [Publisher Full Text](#)
8. Tamaki K, Sadoshima S, Heistad DD: **Increased susceptibility to osmotic disruption of the blood-brain barrier in chronic hypertension.** *Hypertension*. 1984; **6**(5): 633–638.  
[PubMed Abstract](#) | [Publisher Full Text](#)
9. Zwicker JC, Sila CA: **MRI findings in a case of transient cortical blindness after cardiac catheterization.** *Catheter Cardiovasc Interv*. 2002; **57**(1): 47–49.  
[PubMed Abstract](#) | [Publisher Full Text](#)
10. Suri V, Jadhao N, Agarwal R, et al.: **Cortical blindness after contrast-enhanced CT scan in a patient of sarcoidosis - Is it related to posterior reversible encephalopathy syndrome?** *Ann Indian Acad Neurol*. 2011; **14**(4): 298.  
[PubMed Abstract](#) | [Publisher Full Text](#) | [Free Full Text](#)
11. Ibrahim Al-irri K: **Transient Cortical Blindness Following Coronary Angiography.** *J Clin Exp Cardiol*. 2016; **07**(04).  
[Publisher Full Text](#).
12. Henzlova MJ, Coghlan HC, Dean LS, et al.: **Cortical blindness after left internal mammary artery to left anterior descending coronary artery graft angiography.** *Cathet Cardiovasc Diagn*. 1988; **15**(1): 37–39.  
[PubMed Abstract](#) | [Publisher Full Text](#)
13. Yazici M, Ozhan H, Kinay O, et al.: **Transient cortical blindness after cardiac catheterization with iobitridol.** *Texas Hear Inst J*. 2007; **34**(3): 373–375.  
[PubMed Abstract](#) | [Free Full Text](#)
14. Baguma M, Younan N, London F, et al.: **Contrast-associated transient cortical blindness: three cases with MRI and electrophysiology findings.** *Acta Neurol Belg*. 2017; **117**(1): 195–199.  
[PubMed Abstract](#) | [Publisher Full Text](#)
15. Mukherjee D, Bates ER, Roffi M, et al.: **Cardiovascular Catheterization and Intervention.** 2010.  
[Publisher Full Text](#)
16. Piao ZE, Murdock DK, Hwang MH, et al.: **Hemodynamic abnormalities during coronary angiography: Comparison of hypaque-76, hexabrix, and omnipaque-350.** *Cathet Cardiovasc Diagn*. 1989; **16**(3): 149–154.  
[PubMed Abstract](#) | [Publisher Full Text](#)
17. Thomsen HS, Morcos SK: **Management of acute adverse reactions to contrast media.** *Eur Radiol*. 2004; **14**(3): 476–481.  
[PubMed Abstract](#) | [Publisher Full Text](#)
18. Caro JJ, Trindade E, McGregor M: **The risks of death and of severe nonfatal reactions with high- vs low-osmolality contrast media: a meta-analysis.** *Am J Roentgenol*. 1991; **156**(4): 825–832.  
[PubMed Abstract](#) | [Publisher Full Text](#)
19. Cashman JD, McCredie J, Henry DA: **Intravenous contrast media: use and associated mortality.** *Med J Aust*. 1991; **155**(9): 618–623.  
[PubMed Abstract](#)
20. Laroche D, Aimone-Gastin I, Dubois F, et al.: **Mechanisms of severe, immediate reactions to iodinated contrast material.** *Radiology*. 1998; **209**(1): 183–190.  
[PubMed Abstract](#) | [Publisher Full Text](#)
21. Simon RA, Schatz M, Stevenson DD, et al.: **Radiographic contrast media infusions.** *J Allergy Clin Immunol*. 1979; **63**(4): 281–288.  
[Publisher Full Text](#)
22. Sutton AGC, Finn P, Campbell PG, et al.: **Early and late reactions following the use of iopamidol 340, iomeprol 350 and iodixanol 320 in cardiac catheterization.** *J Invasive Cardiol*. 2003; **15**(3): 133–138.  
[PubMed Abstract](#)
23. Katayama H, Yamaguchi K, Kozuka T, et al.: **Adverse reactions to ionic and nonionic contrast media. A report from the Japanese Committee on the Safety of Contrast Media.** *Radiology*. 1990; **175**(3): 621–628.  
[PubMed Abstract](#) | [Publisher Full Text](#)

# Open Peer Review

Current Peer Review Status:  

---

## Version 2

Reviewer Report 31 August 2022

<https://doi.org/10.5256/f1000research.137751.r148426>

© 2022 Lukito A. This is an open access peer review report distributed under the terms of the [Creative Commons Attribution License](#), which permits unrestricted use, distribution, and reproduction in any medium, provided the original work is properly cited.



**Antonia Anna Lukito** 

Department of Cardiology and Vascular Medicine, Siloam Hospitals Lippo Village, Tangerang, Indonesia

Congratulations again to the authors.

The authors have addressed the concerns raised in the peer review report appropriately. I have no further comments to make.

**Competing Interests:** No competing interests were disclosed.

**Reviewer Expertise:** I am an interventional cardiologist

**I confirm that I have read this submission and believe that I have an appropriate level of expertise to confirm that it is of an acceptable scientific standard.**

Reviewer Report 26 August 2022

<https://doi.org/10.5256/f1000research.137751.r148425>

© 2022 Lee Z. This is an open access peer review report distributed under the terms of the [Creative Commons Attribution License](#), which permits unrestricted use, distribution, and reproduction in any medium, provided the original work is properly cited.



**Zhen-Vin Lee** 

Cardiology Unit, Department of Medicine, University Malaya Medical Centre, Kuala Lumpur, Malaysia

The appropriate revisions have been made.

**Competing Interests:** No competing interests were disclosed.

**Reviewer Expertise:** Interventional Cardiology, General Cardiology, Preventive Cardiology

**I confirm that I have read this submission and believe that I have an appropriate level of expertise to confirm that it is of an acceptable scientific standard.**

---

### Version 1

Reviewer Report 02 February 2022

<https://doi.org/10.5256/f1000research.53909.r121225>

© 2022 Lee Z. This is an open access peer review report distributed under the terms of the [Creative Commons Attribution License](#), which permits unrestricted use, distribution, and reproduction in any medium, provided the original work is properly cited.



**Zhen-Vin Lee**

Cardiology Unit, Department of Medicine, University Malaya Medical Centre, Kuala Lumpur, Malaysia

I first wish to congratulate the authors for successfully reporting a case that has significant educational value. I personally had a similar experience managing a patient with this rare condition in which the case had been previously published<sup>1</sup>. The condition causes significant anxiety to both the treating physician and the patient. It has to be mentioned that whilst transient cortical blindness is a cause of sudden bilateral loss of vision, its incidence is extremely rare and remains a diagnosis of exclusion.

Given that the incident happened during an invasive procedure, the possibility of other, more sinister, complications would have to be entertained and this calls for a prompt multidisciplinary involvement to ensure that the appropriate diagnosis is made and necessary therapeutic measures can be swiftly taken.

I agree with Dr Lukito that Figure 1A needs to be swapped with Figure 1B to correctly reflect the figure legend.

#### References

1. Lee Z, Arjan Singh R: Transient Cortical Blindness After Coronary Angiography, Bypass Graft Angiography, and Coronary Angioplasty. *Cureus*. 2021. [Publisher Full Text](#)

**Is the background of the case's history and progression described in sufficient detail?**

Yes

**Are enough details provided of any physical examination and diagnostic tests, treatment given and outcomes?**



Yes

**Is sufficient discussion included of the importance of the findings and their relevance to future understanding of disease processes, diagnosis or treatment?**

Yes

**Is the case presented with sufficient detail to be useful for other practitioners?**

Yes

**Competing Interests:** No competing interests were disclosed.

**Reviewer Expertise:** Interventional Cardiology, General Cardiology, Preventive Cardiology

**I confirm that I have read this submission and believe that I have an appropriate level of expertise to confirm that it is of an acceptable scientific standard, however I have significant reservations, as outlined above.**

Author Response 28 Feb 2022

**Yudi Her Oktaviono**, Soetomo General Hospital, Faculty of Medicine, University of Airlangga,, Surabaya, Indonesia

Thank you very much Zhen-Vin Lee for your review and constructive feedback.

It is indeed a rare complication which we need to be prepared.

Yes I acknowledge that the image was swapped, I will revise it soon.

Best Regards  
Yudi Her

**Competing Interests:** No competing interests were disclosed.

Reviewer Report 20 October 2021

<https://doi.org/10.5256/f1000research.53909.r96948>

© 2021 Lukito A. This is an open access peer review report distributed under the terms of the [Creative Commons Attribution License](#), which permits unrestricted use, distribution, and reproduction in any medium, provided the original work is properly cited.



**Antonia Anna Lukito**

Department of Cardiology and Vascular Medicine, Siloam Hospitals Lippo Village, Tangerang, Indonesia

Congratulations to the author for this interesting case which also has a learning point. The writing

is clear and concise. The cortical blindness during the percutaneous coronary intervention procedure is a shocking and unexpected event both for the patient and the physician. The author reported the real situation of the horrible adverse event of the percutaneous coronary intervention procedure, and provided the possible causes and the timely management, which delivered a lesson to learn for the physician. However, there is a misplacement of the procedure figures. The figures A and B, as before and after stenting figures, are apparently swapped.

**Is the background of the case's history and progression described in sufficient detail?**

Yes

**Are enough details provided of any physical examination and diagnostic tests, treatment given and outcomes?**

Yes

**Is sufficient discussion included of the importance of the findings and their relevance to future understanding of disease processes, diagnosis or treatment?**

Yes

**Is the case presented with sufficient detail to be useful for other practitioners?**

Yes

**Competing Interests:** No competing interests were disclosed.

**Reviewer Expertise:** I am an interventional cardiologist

**I confirm that I have read this submission and believe that I have an appropriate level of expertise to confirm that it is of an acceptable scientific standard, however I have significant reservations, as outlined above.**

Author Response 30 Nov 2021

**Yudi Her Oktaviono**, Soetomo General Hospital, Faculty of Medicine, University of Airlangga,, Surabaya, Indonesia

Thank you very much for the feedback. It is an honor for me to be reviewed by Dr. Antonia Anna Lukito.

We will revise the figure accordingly.

Best Regards  
Yudi

**Competing Interests:** No competing interests were disclosed.

Author Response 28 Feb 2022

**Yudi Her Oktaviono**, Soetomo General Hospital, Faculty of Medicine, University of

Airlangga,, Surabaya, Indonesia

Thank you very much Dr Antonia Anna Lukito for all of the constructive feedback.

Yes the figure is swapped, I will revise it accordingly.

Regards  
Yudi Her

**Competing Interests:** No competing interests were disclosed.

The benefits of publishing with F1000Research:

- Your article is published within days, with no editorial bias
- You can publish traditional articles, null/negative results, case reports, data notes and more
- The peer review process is transparent and collaborative
- Your article is indexed in PubMed after passing peer review
- Dedicated customer support at every stage

For pre-submission enquiries, contact [research@f1000.com](mailto:research@f1000.com)

**F1000Research**