

Benign uptake of ¹⁸F-fluorodeoxyglucose in the gallbladder on positron emission tomography-computed tomography

ABSTRACT

¹⁸F-fluorodeoxyglucose (FDG) positron emission tomography (PET) has been established as the indisputable tool in the oncological arena to diagnose, stage/restage, and report treatment response for various tumor malignancies. FDG uptake mostly identifies pathological uptake in oncological scans with the tracer on PET studies; however, benign uptakes are also commonly seen. Reported here is a benign case of increased uptake of the FDG on a PET with computed tomography scan in the gallbladder (GB) of a patient being screened for a known carcinoma breast. The benign accumulation of the tracer is seen in the GB to various degrees and this phenomenon may occur as a result of FDG excretion into the bile. When interpreting clinical PET images, recognition of this phenomenon is important to avoid misdiagnosing physiological GB FDG uptake as pathological so as to avoid misinterpretations of the findings.

Keywords: Benign uptake, ¹⁸F-fluorodeoxyglucose, gallbladder, positron emission tomography-computed tomography

INTRODUCTION

¹⁸F-fluorodeoxyglucose (FDG) positron emission tomography (PET) has been established as the indisputable tool in the oncological arena to diagnose, stage/restage, and report treatment response for various tumor malignancies.^[1] The imaging is based on the concept of over than normal utilization of glucose by malignancies which shows up as hot areas on the imaging views. However, caution is to be practiced in reading of these areas of uptake, also known as the hot areas, as various physiological processes or benign etiologies also show FDG uptake.^[2]

FDG uptake in the gallbladder (GB) in the face of known malignancy of the organ is well known. It shows uptake in malignant causes such as adenocarcinoma of GB.^[3] FDG uptake is also seen in inflammatory conditions such as cholecystitis with or without cholelithiasis. Focal fundal tracer uptake is also seen in adenomyosis of GB.^[4] Diffuse and focal GB uptake without malignancy has also been reported.^[5]

We report a case of benign diffuse GB uptake in a patient of carcinoma breast.

CASE REPORT

A middle age female diagnosed case of carcinoma right breast status postmastectomy and chemotherapy underwent scanning for the evaluation of instituted treatment response. Her previous FDG PET with computed tomography (CT), done 4 months back, reported a faintly metabolic, small soft tissue nodule in the upper lobe of the left lung for which suspicion was raised and follow-up was advised.

Follow-up scanning failed to show the previously reported nodules in the left lung (benign lesion); however, an interval development of increased metabolic activity overlying GB was identified which had not been seen previously [Figures 1-3].

RIFFAT PARVEEN HUSSAIN, SADAF NAUSHEEN, NAVEED AHMED, TARIQ MAHMOOD

Department of Radiology, PET-CT, Jinnah Postgraduate Medical Center, Karachi, Pakistan


Address for correspondence: Dr. Riffat Parveen Hussain, 18/2 Khayaban-e Ghazi, DHA Phase 5, Karachi, Pakistan.
E-mail: riffat214@gmail.com

Submission: 08-Nov-19, **Accepted:** 14-Nov-19, **Published:** 22-Jul-20

This is an open access journal, and articles are distributed under the terms of the Creative Commons Attribution-NonCommercial-ShareAlike 4.0 License, which allows others to remix, tweak, and build upon the work non-commercially, as long as appropriate credit is given and the new creations are licensed under the identical terms.

For reprints contact: WKHLRPMedknow_reprints@wolterskluwer.com

How to cite this article: Hussain RP, Nausheen S, Ahmed N, Mahmood T. Benign uptake of ¹⁸F-fluorodeoxyglucose in the gallbladder on positron emission tomography-computed tomography. World J Nucl Med 2020;19:288-90.

Access this article online	
Website: www.wjnm.org	Quick Response Code 
DOI: 10.4103/wjnm.WJNM_82_19	

The concomitant CT images revealed no morphological abnormality (swelling or wall thickening of GB) to explain the unusual uptake [Figure 2].

An ultrasound was also undertaken to rule out any pathology which showed an adequately distended GB with no evidence of calculus/sludge, mass lesion, or any pericholecystic fluid observed. No lesion was identified in the adjacent hepatic area either [Figure 4].

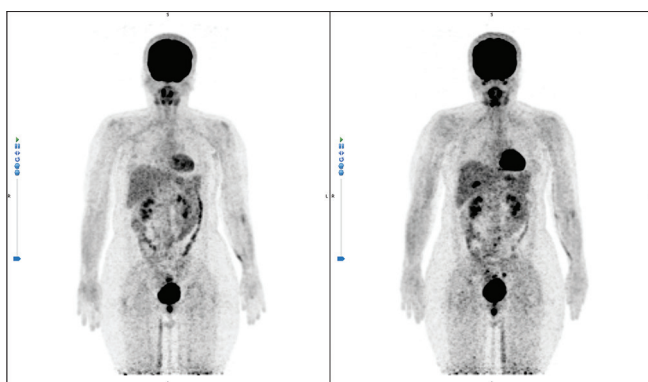


Figure 1: Maximum intensity projection image of baseline (left) and current (right) scan

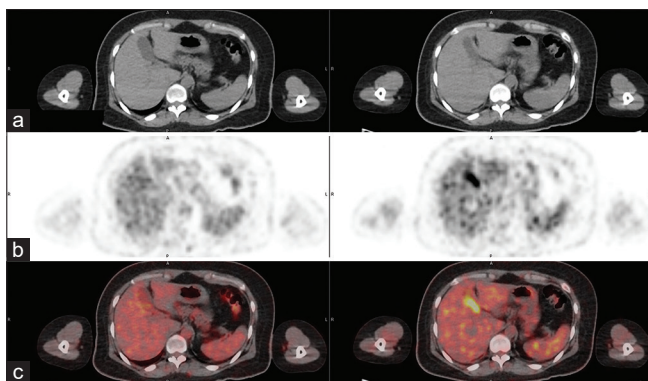


Figure 2: Axial cross-section of computed tomography (a), functional image (b), and computed tomography-positron emission tomography fused image (c)

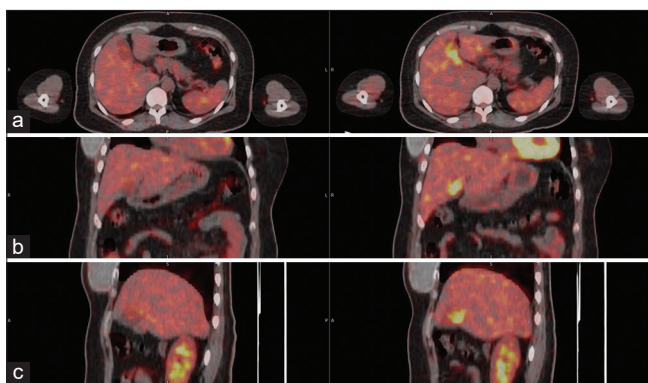


Figure 3: Axial (a), coronal (b), and sagittal fuse (c) images of baseline (left) and current (right) showing gallbladder area

Laboratory workup, inclusive of liver profile, was all within the normal limits.

The patient gave no history of any complaints related to GB or otherwise.

Clinical findings and follow-up observations, made during a 7-month period, did not reveal any abnormality.

We conclude that the patient had no GB disease and that the reported uptake around it was benign.

DISCUSSION

¹⁸F-FDG PET is known to show uptake in malignant conditions, and hence, it is touted utility in oncology. This uptake is defined as “sensitive” but suffers specificity showing uptake in benign processes also, the most common of which are in infections/inflammations. Few unexplained uptakes, without causes, have also been reported and careful scrutiny of these must be taken into consideration during reporting of unusual uptakes or regions of uptake.^[1,2]

Regarding the GB, normally in the FDG PET-CT studies, the GB does not show any tracer accumulation.^[6] However, reports in literature have been made of the accumulation of tracer despite the absence of any GB disease which sometimes have been higher than the activity of the liver. It is important to be cognizant of this physiology as it will help in wrongfully attributing the uptake to a pathological cause.^[5,6]

GB uptake in the face of known malignancy of the organ is well known with adenocarcinoma of GB being the most common.^[3,4] Most patients with malignancies of the GB have advanced or unrespectable disease at diagnosis. This has been attributed to the fact that these cancers have a tendency to metastasize early and widely, spreading through lymphatics, hematogenously, and intraperitoneal. The early stage of the disease is mostly diagnosed incidentally after a cholecystectomy for presumed benign disease. On PET-CT, a malignancy of the GB shows a diffuse increased tracer uptake and to report this as malignant is not a problem as the most carcinomas produce abnormal CT findings such as a massive tumor or wall thickening.^[3]

FDG uptake is also seen in inflammatory conditions such as cholecystitis with or without cholelithiasis resulting in a false-positive study in acute cholecystitis;^[7] the increased activity has been described as involving the entire GB wall with a ring-like appearance. Rim-like FDG uptake in the GB wall secondary to cholestasis from common bile duct obstruction has also been described, although the cause for the increased

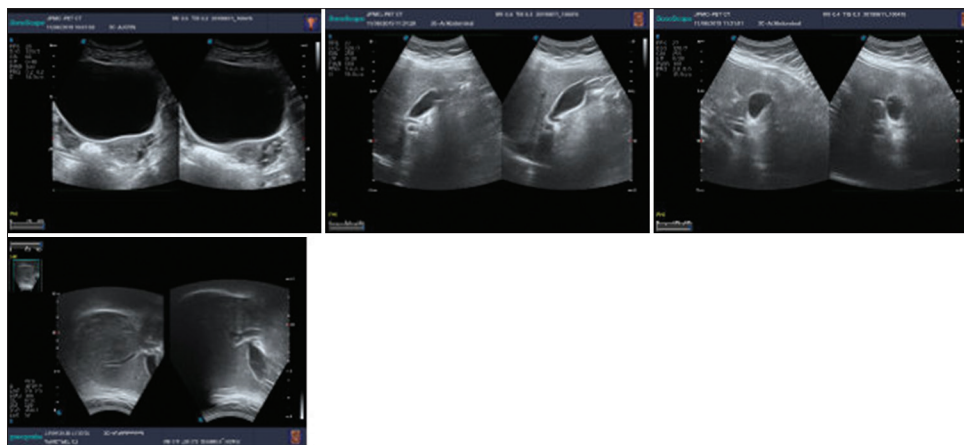


Figure 4: Ultrasound of gallbladder

metabolic activity, in that case, was not clear.^[4] Another benign uptake is also reported in the adenomyosis of the GB where there is a focal fundal tracer uptake, rather than in the lumen of GB, is seen. In addition to all of these, diffuse and focal GB uptake without malignancy has also been reported.^[5]

Normal physiological uptake of the GB as noted above has also been described. Differentiating this physiological uptake from a malignant cause is usually not difficult as physiological cases do not exhibit any abnormal CT findings,^[6] as was also shown in our study.

Another cause for tracer accumulation in the GB has been made for imaging time with accumulation increasing with increase of time from injection.^[6] FDG appears, in these conditions, to be distributed within the GB and not the wall because it is secreted into the bile. In our study, however, both studies were done at 60 min (± 10 min).

The sensitivity of the FDG PET in distinguishing a benign from a malignant GB mass has been reported as 75%–80% and specificity as 82%–88%. Hence, activity that is seen within the GB should be carefully scrutinized.^[3]

CONCLUSION

¹⁸F-FDG uptake mostly identifies pathological uptake in oncological scans with the tracer on PET studies; however, benign uptakes are also commonly seen.

The benign accumulation of the tracer is seen in the GB to various degrees and this phenomenon may occur as a result of FDG excretion into the bile. When interpreting clinical PET images, recognition of this phenomenon is important to avoid misdiagnosing physiological GB FDG uptake as pathological so as to avoid misinterpretations of the findings.

Declaration of patient consent

The authors certify that they have obtained all appropriate patient consent forms. In the form the patient(s) has/have given his/her/their consent for his/her/their images and other clinical information to be reported in the journal. The patients understand that their names and initials will not be published and due efforts will be made to conceal their identity, but anonymity cannot be guaranteed.

Financial support and sponsorship

Nil.

Conflicts of interest

There are no conflicts of interest.

REFERENCES

1. Kostakoglu L, Hardoff R, Mirtcheva R, Goldsmith SJ. PET-CT fusion imaging in differentiating physiologic from pathologic FDG uptake. *Radiographics* 2004;24:1411-31.
2. Rossi J, Mariluis CA, Delgado E, Choba R, Vietti CM. Pitfalls in Oncologic Diagnosis with PET CT. Nononcologic Hypermetabolic Findings. In: European Society of Radiology (EPOS)-ECR 2012. Vienna, Austria; 2012. p. 1-16.
3. Leung U, Pandit-Taskar N, Corvera CU, D'Angelica MI, Allen PJ, Kingham TP, *et al.* Impact of pre-operative positron emission tomography in gallbladder cancer. *HPB (Oxford)* 2014;16:1023-30.
4. Maldjian PD, Ghesani N, Ahmed S, Liu Y. Adenomyomatosis of the gallbladder: Another cause for a "hot" gallbladder on ¹⁸F-FDG PET. *AJR Am J Roentgenol* 2007;189:W36-8.
5. Bai X, Wang X, Zhuang H. FDG accumulation in the lumen of the gallbladder without related pathology. *Clin Nucl Med* 2018;43:383-5.
6. Murata Y, Watanabe H, Kubota K, Toda K, Nakamura S, Okouchi K, *et al.* PET/CT evaluation of the physiologic accumulation of ¹⁸F-FDG within the gallbladder vesicle. *Nucl Med Biol* 2007;34:961-6.
7. Shaikh F, Awan O, Khan SA. ¹⁸F-FDG PET/CT imaging of gallbladder adenocarcinoma – A pictorial review. *Cureus* 2015;7:e298.