

# Pro: endoscopic realignment for pelvic fracture urethral injuries

Daniel M. Stein, Richard A. Santucci

DMC Medical Group Urology, College of Osteopathic Medicine, Michigan State University, Detroit, MI 48201, USA

*Correspondence to:* Richard A. Santucci, MD, FACS. Specialist-in-Chief, Urology, The Detroit Medical Center; Director, The Center for Urologic Reconstruction™; Clinical Professor, College of Osteopathic Medicine, Michigan State University, 4160 John R. Suite 1017, Detroit, MI 48201, USA. Email: rsantucc@dmc.org.

**Abstract:** Patients with pelvic fracture urethral distraction injuries may benefit from early endoscopic realignment. Realignment is associated with a low risk of immediate complications and has a high success rate for achieving catheter placement. Review of over thirty studies assessing for subsequent urethral stenosis, including at least a dozen that directly compare realignment to suprapubic diversion along, conclude that there is a benefit averaging at least 35% in favor of realignment. Furthermore, realignment may result in easier subsequent urethroplasty and possibly shorter stenoses.

**Keywords:** Urethral stenosis; trauma; urethral catheterization

Submitted Nov 17, 2014. Accepted for publication Jan 22, 2015.

doi: 10.3978/j.issn.2223-4683.2015.01.11

**View this article at:** <http://dx.doi.org/10.3978/j.issn.2223-4683.2015.01.11>

## Background

In patients with pelvic fracture urethral distraction injury, there are two basic methods of early treatment. The first is early realignment over a catheter, usually using gentle blind or endoscopic techniques. The second is placement of a suprapubic tube, and subsequent open urethroplasty after the nearly inevitable urethral stenosis forms.

The benefits of early realignment over a catheter are potentially many. It is generally simple, avoids the need for placement of a suprapubic catheter, may decrease the overall impact of the urethral injury by promoting earlier return to spontaneous voiding, and may decrease the chance and degree of subsequent urethral obliteration.

## Realignment method

There are several methods to place a urethral catheter into the bladder across a disrupted urethra. Most experts start with a simple retrograde catheterization attempt (1-3). If this fails, most modern authors choose retrograde flexible cystoscopy next (4,5). Retrograde flexible or rigid urethroscopy through a suprapubic tube can be attempted next (6). This procedure is claimed to require only 5-10 minutes when successful (5,6), while retrograde rigid

cystoscopy has been reported to require an average of 22 minutes (7). If this fails, other authors have used two cystoscopes: one rigid one placed anterograde and a second flexible scope placed retrograde to bridge the gap (8,9).

Despite many documented techniques for realignment, our preferred stepwise approach is a single attempt at gentle blind passage of a catheter followed by retrograde flexible cystoscopy then rigid cystoscopy then suprapubic flexible cystoscopy (with or without simultaneous rigid cystoscopy).

Other techniques described involve placing a wire placed anterograde or retrograde across the defect and then placing a Council-tipped Foley catheter over the wire (10) or using a feeding tube placed in the penis which is placed into the bladder and grasped through a cystostomy (11). Direct placement of a Foley catheter anterograde through a cystostomy (1) or urethral cystoscopy towards a Goodwin sound placed through a cystostomy has also been described (12). Two blindly-placed anterograde and retrograde catheters with strong magnets on the end have been used to safely traverse the defect, but unfortunately these catheters are not commercially available (13). Older reports generally report open techniques using Davis interlocking sounds (2) or a metal sound in the urethra guided by a finger in the bladder neck (14), requiring a mean of 80 minutes to complete in one 1,983 study (2). A technique using anterograde

**Table 1** Rate of stenosis (%) by urethral management

Authors	Year	Suprapubic cystostomy	Realignment
Gelbard <i>et al.</i> (12)	1989	–	100
Olapada-Olaopa <i>et al.</i> (7)	2010	–	21
Mitchell (21)	1968	–	24
Salehipour <i>et al.</i> (22)	2005	–	24
Fowler <i>et al.</i> (23)	1986	–	30
Crassweller <i>et al.</i> (24)	1977	–	32
Deweerd (25)	1959	–	36
Tazi <i>et al.</i> (26)	2003	–	36
Patterson <i>et al.</i> (2)	1983	–	38
Healy <i>et al.</i> (27)	2007	–	40
Quint <i>et al.</i> (28)	1993	–	40
Barry (29)	1989	–	42
Moudouni <i>et al.</i> (30)	2001	–	49
Kotkin <i>et al.</i> (31)	1996	–	50
Jepson <i>et al.</i> (32)	1999	–	50
Kielb <i>et al.</i> (5)	2000	–	50
Londergan (16)	1997	–	50
Porter <i>et al.</i> (13)	1997	–	50
Gibson (33)	1974	–	62
Jackson <i>et al.</i> (34)	1974	–	65
Rehman <i>et al.</i> (9)	1989	–	66
Elliott <i>et al.</i> (1)	1997	–	68
Cass (35)	1978	–	70
Guille <i>et al.</i> (8)	1991	–	75
Cohen <i>et al.</i> (10)	1991	–	80
Sahin <i>et al.</i> (36)	1998	–	80
Kim <i>et al.</i> (17)	2013	–	53
Leddy <i>et al.</i> (18)	2012	–	79
McAninch (37)	1981	89	–
Morehouse <i>et al.</i> (38)	1980	95	–
Dhabuwala <i>et al.</i> (39)	1990	100	–
Ku <i>et al.</i> (40)	2002	65	60
Asci <i>et al.</i> (3)	1999	83	45
Follis <i>et al.</i> (14)	1992	85	15
Jackson (34)	1974	88	75
Husmann <i>et al.</i> (41)	1990	95	94
Koraitim (42)	1996	97	53
Podesta <i>et al.</i> (20)	1997	100	100
Al-Ali <i>et al.</i> (19)	1983	100	100
Hadjizacharia <i>et al.</i> (4)	2008	100	14
Mouraviev <i>et al.</i> (43)	2004	100	49
Herschorn (15)	1992	100	54
Coffield <i>et al.</i> (44)	1977	100	78
Webster <i>et al.</i> (45)	1983	100	92
Mean	–	94	56

or retrograde placement of catheters required less than 75 minutes (1).

### Immediate procedural success of realignment and timing of attempts

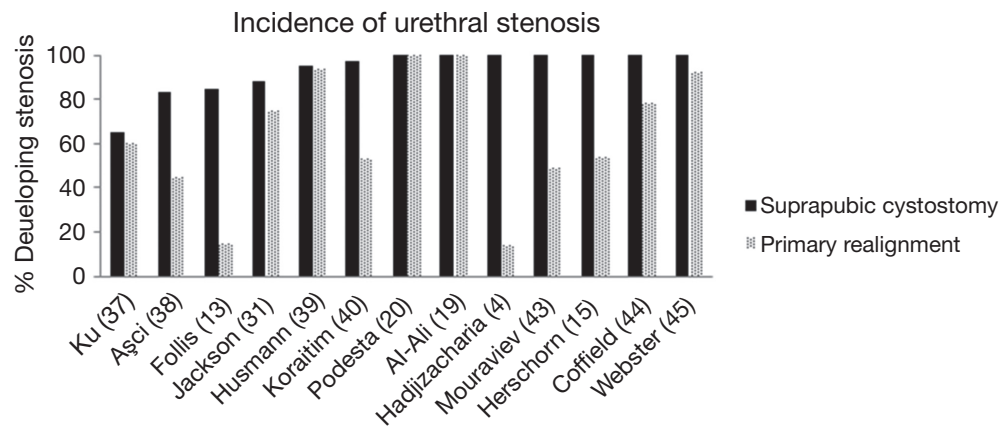
The published procedural success rate of any realignment technique is variable depending on the author, and ranges from 70-100% (4,13-18). One series where authors gained experience in the technique over a 5 year period showed an increase in successful realignment rates from 80% up to 93% with time (7).

Most surgeons place the catheter as soon as practically possible (10) and this is generally achievable after a mean of 32 hours from injury (10). A single immediate blind placement of a Foley catheter is attempted at most centers soon after the injury is diagnosed (10). Some have delayed realignment up to 7-19 days (11) with good results. Authors have suggested that after initial failure, realignment can be attempted 2-3 days later with some success (4). A single report of a small number of early (72 hours) and more delayed realignment cases were compared and had similar rates of subsequent stenosis (9).

The recommended time that the catheter should be left in is highly variable, ranging from 3-6 weeks (2,4, 10-13,19,20) with some recommend longer catheterization up to 8 weeks (9,19). We leave the catheter 6 weeks before voiding cystourethrogram or peri-catheter retrograde urethrogram is attempted. If there is no extravasation the Foley catheter is removed. If a suprapubic tube is also present, it is capped but left in place for at least 4 weeks to ensure there is no interim stenosis prior to removal.

### Incidence of stenosis

Long term success of realignment is most importantly defined by the incidence of subsequent urethral stenosis; however, stenosis outcomes and the screening and diagnoses of urethral stenosis have been variable. A review of the literature demonstrated a wide rate of stenosis among series of patients undergoing realignment ranging from 14-100%; however, realignment appears to be associated with a lower chance of subsequent urethral obliteration by about 40% when compared to placement of a suprapubic tube alone (*Table 1*) (*Figure 1*). These findings are consistent with a recent meta-analysis of studies comparing primary realignment to cystostomy, in which, the authors report a significantly lower rate of stenosis among the primary alignment group with an absolute risk



**Figure 1** Incidence of urethral stenosis (4,13,15,19,20,31,37-40,43-45).

reduction of 37% (46).

In a recent case series of 19 patients undergoing primary endoscopic realignment, the authors report a failure rate of 79%, but of those failures three only required a single urethrotomy such that only 58% of the cohort went on to require urethroplasty (18). While we do not advocate for management with repetitive urethrotomies, these data imply that realignment allows for a less severe stenosis in some patients.

### Time to voiding and length of stenosis

In one series, the patients who underwent realignment had a significantly shorter time to spontaneous voiding (35 *vs.* 229 days) than those who had cystostomy (4).

Furthermore, some authors have suggested that realignment also aligns the urethral ends so that any subsequent urethroplasty is technically easier (6). While there is not much evidence to support claims of less severe stenosis, one series did find significantly shorter stenoses among the cohort treated with early realignment as compared to cystostomy (42).

### Complications of realignment

While most authors report good results from endoscopic realignment, some studies suggest that they decrease the success of any future urethroplasty. A report of 7 patients reported that in those that required urethroplasty, it was 1/2 as successful (43% for realigned group *vs.* 85% for uninstrumented group); however, this trend has not been demonstrated in other series. The authors hypothesized that endoscopic realignment causes inflammation and then fibrosis of the torn ends of the urethra,

although no proof for this is given (47).

Confirmed early complications from endoscopic realignment are rare and sporadic. Most series that actually analyzed complications report no significant complications from the procedure (1). Attempting and failing to get realignment with a catheter is not believed to harm the patient (14). One series report a 1/34 (3%) incidence of pelvic abscess (2). A single urethro scrotal fistula appeared in a series of 14 (7%) realigned patients (10) and a perineal abscess developed in 1/6 (16%) and 1/4 (35%) patients in other studies (22,23). Malposition of the catheter (including inadvertently “jumping” the catheter over the prostate and placing into the bladder via a bladder rupture) is a rare possibility and has been personally witnessed by the authors. Delayed realignment at a mean of 10 days caused septicemia in 15% of cases in one series (7) prompting us to avoid late attempts at realignment.

One series has reported that realignment was associated with increased need for multiple endoscopic procedures (48). Algorithmic approaches to any urethral stenosis/stricture patients should take into account the high likelihood of failure with repeated endoscopic procedures. As urethral disruption is associated with a high rate of stenosis, close follow-up after realignment is essential. If treated with a similar algorithm to any other urethral stenosis/stricture, that is, timely transition to urethroplasty after failed endoscopic management, there should not be a need for multiple interventions among urethral stenosis after realignment.

Erectile dysfunction and incontinence have been commonly reported following urethral distraction injuries; however, primary realignment does not appear to increase the baseline incontinence or erectile dysfunction rate (Tables 2,3). Variation seen in a variety of series with regard

**Table 2** Rate of incontinence (%) by urethral management

Authors	Year	Suprapubic cystostomy	Realignment
Gelbard <i>et al.</i> (12)	1989	–	0
Guille <i>et al.</i> (8)	1991	–	0
Healy <i>et al.</i> (27)	2007	–	0
Melekos <i>et al.</i> (49)	1992	–	0
Olapada-Olaopa <i>et al.</i> (7)	2010	–	0
Tazi <i>et al.</i> (26)	2003	–	0
Porter <i>et al.</i> (13)	1997	–	0
Salehipour (22)	2005	–	0
Quint <i>et al.</i> (28)	1993	–	10
Cass <i>et al.</i> (35)	1978	–	10
Kotkin <i>et al.</i> (31)	1996	–	17
Rehman <i>et al.</i> (9)	1998	–	17
Cohen <i>et al.</i> (10)	1991	–	20
Patterson <i>et al.</i> (2)	1983	–	3
Elliott <i>et al.</i> (1)	1997	–	4
Moudouni <i>et al.</i> (30)	2001	–	4
Londergan <i>et al.</i> (16)	1997	–	50
Jepson (32)	1999	–	6
Barry (29)	1989	–	8
Herschorn <i>et al.</i> (15)	1992	0	0
Husmann (41)	1990	12	12
Webster <i>et al.</i> (45)	1983	14	7
Mouraviev <i>et al.</i> (43)	2004	25	18
Koraitim (42)	1996	3	4
Asci <i>et al.</i> (3)	1999	6	10
Follis <i>et al.</i> (14)	1992	8	0
Mean	–	10	8

**Table 3** Rate of erectile dysfunction (%) by urethral management

Authors	Year	Suprapubic cystostomy	Realignment
Melekos <i>et al.</i> (49)	1992	–	0
Olapada-Olaopa <i>et al.</i> (7)	2010	–	0
Quint <i>et al.</i> (28)	1993	–	0
Barry (29)	1989	–	0
Porter <i>et al.</i> (13)	1997	–	14
Patterson <i>et al.</i> (2)	1983	–	15
Kotkin <i>et al.</i> (31)	1996	–	16
Selehipour <i>et al.</i> (22)	2005	–	16
Tazi <i>et al.</i> (26)	2003	–	19
Guille <i>et al.</i> (8)	1991	–	20
Jepson <i>et al.</i> (32)	1999	–	22
Moudouni <i>et al.</i> (30)	2001	–	22
Cass <i>et al.</i> (35)	1978	–	38
Healy <i>et al.</i> (27)	2007	–	40
Cohen <i>et al.</i> (10)	1991	–	60
Elliott <i>et al.</i> (1)	1997	–	8
McAninch (37)	1981	17	–
Herschorn <i>et al.</i> (15)	1992	100	42
Asci <i>et al.</i> (3)	1999	18	20
Koraitim (42)	1996	18	28
Webster <i>et al.</i> (45)	1983	36	52
Mouraviev <i>et al.</i> (43)	2004	42	34
Follis <i>et al.</i> (14)	1992	50	20
Husmann <i>et al.</i> (41)	1990	51	47
Mean	–	42	23

to erectile dysfunction and continence likely reflects the diversity of the initial injury rather than the method of urethral management (*Figures 2,3*).

### Limitations

Almost all reports used different methods of achieving urethral alignment, making direct comparisons difficult. Outcomes from old reports describing open, often highly invasive, techniques (e.g., removing hematoma or cutting the puboprostatic ligaments) cannot be properly compared to modern endoscopic techniques.

It is also possible that patients in whom realignment is

possible may have less serious injuries than those in which it fails. In some series the patients managed with suprapubic cystostomy had previously failed alignment attempts, and these patients probably have more significant injuries and longer urethral distraction distances than those in whom alignment was successful. One report of 16 patients determined that partial urethral tears as determined by urethrography were present in 33% of those in whom realignment was not possible and 46% of those in whom realignment was possible (15). The incidence of partial versus total urethral disruption found partial injuries to be much more common in the cystostomy group (7%) than the alignment group (39%) (15).

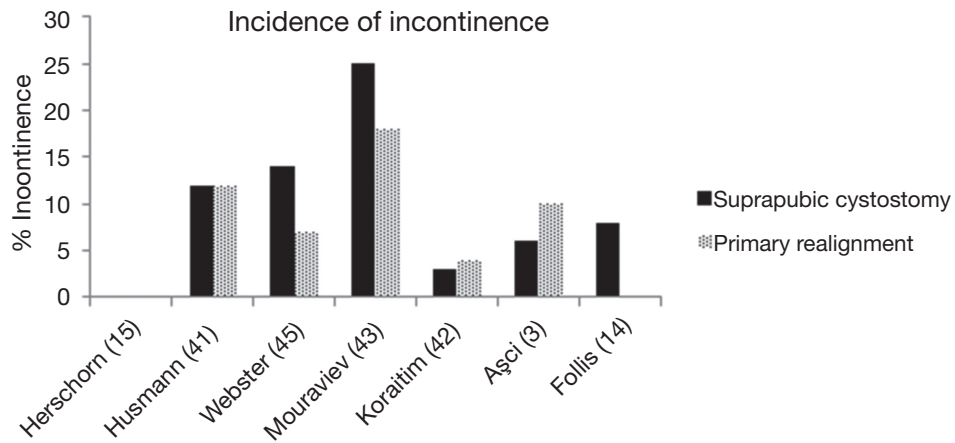


Figure 2 Incidence of incontinence (3,14,15,41-45).

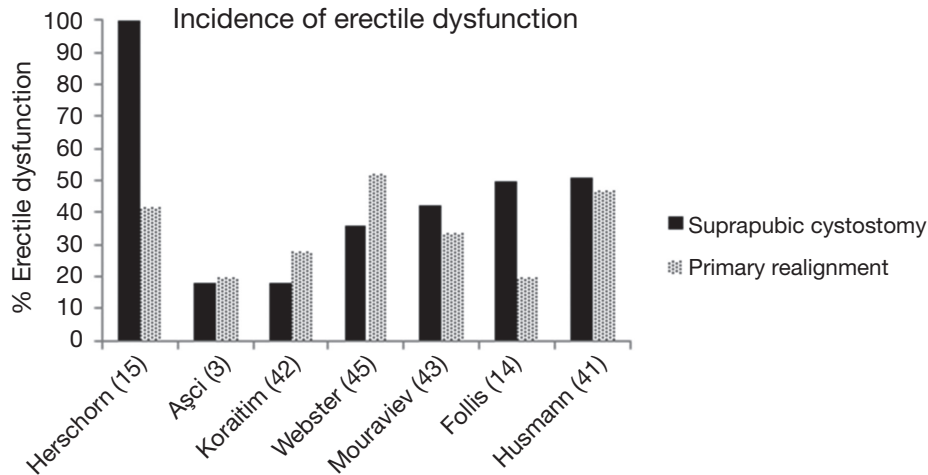


Figure 3 Incidence of erectile dysfunction (3,14,15,41-45).

**Conclusions**

Review of over thirty studies, including at least a dozen that directly compare realignment to suprapubic diversion along, conclude that there is a benefit averaging at least 35% in favor of realignment. Secondary benefits of realignment may include easier subsequent urethroplasty, when necessary, and possibly shorter stenoses. Endoscopic realignment is not associated with a higher rate of immediate or delayed complications. While the rate of subsequent urethral stenosis after realignment remains high, the potential to eliminate the need for complicated urethroplasty in up to a third of patients cannot be ignored.

**Acknowledgements**

None.

**Footnote**

*Conflicts of Interest:* The authors have no conflicts of interest to declare.

**References**

1. Elliott DS, Barrett DM. Long-term followup and evaluation of primary realignment of posterior urethral

- disruptions. *J Urol* 1997;157:814-6.
2. Patterson DE, Barrett DM, Myers RP, et al. Primary realignment of posterior urethral injuries. *J Urol* 1983;129:513-6.
  3. Aşci R, Sarikaya S, Büyükalpelli R, et al. Voiding and sexual dysfunctions after pelvic fracture urethral injuries treated with either initial cystostomy and delayed urethroplasty or immediate primary urethral realignment. *Scand J Urol Nephrol* 1999;33:228-33.
  4. Hadjizacharia P, Inaba K, Teixeira PG, et al. Evaluation of immediate endoscopic realignment as a treatment modality for traumatic urethral injuries. *J Trauma* 2008;64:1443-9; discussion 1449-50.
  5. Kielb SJ, Voeltz ZL, Wolf JS. Evaluation and management of traumatic posterior urethral disruption with flexible cystourethroscopy. *J Trauma* 2001;50:36-40.
  6. Gheiler EL, Frontera JR. Immediate primary realignment of prostatomembranous urethral disruptions using endourologic techniques. *Urology* 1997;49:596-9.
  7. Olapade-Olaopa EO, Atalabi OM, Adekanye AO, et al. Early endoscopic realignment of traumatic anterior and posterior urethral disruptions under caudal anaesthesia - a 5-year review. *Int J Clin Pract* 2010;64:6-12.
  8. Guillé F, Cippola B, el Khader K, et al. Early endoscopic realignment for complete traumatic rupture of the posterior urethra--21 patients. *Acta Urol Belg* 1998;66:55-8.
  9. Rehman J, Samadi D, Ricciardi R Jr, et al. Early endoscopic realignment as primary therapy for complete posterior urethral disruptions. *J Endourol* 1998;12:283-9.
  10. Cohen JK, Berg G, Carl GH, et al. Primary endoscopic realignment following posterior urethral disruption. *J Urol* 1991;146:1548-50.
  11. Balkan E, Kilic N, Dogruyol H. The effectiveness of early primary realignment in children with posterior urethral injury. *Int J Urol* 2005;12:62-6.
  12. Gelbard MK, Heyman AM, Weintraub P. A technique for immediate realignment and catheterization of the disrupted prostatomembranous urethra. *J Urol* 1989;142:52-5.
  13. Porter JR, Takayama TK, Defalco AJ. Traumatic posterior urethral injury and early realignment using magnetic urethral catheters. *J Urol* 1997;158:425-30.
  14. Follis HW, Koch MO, McDougal WS. Immediate management of prostatomembranous urethral disruptions. *J Urol* 1992;147:1259-62.
  15. Herschorn S, Thijssen A, Radomski SB. The value of immediate or early catheterization of the traumatized posterior urethra. *J Urol* 1992;148:1428-31.
  16. Londergan TA, Gundersen LH, van Every MJ. Early fluoroscopic realignment for traumatic urethral injuries. *Urology* 1997;49:101-3.
  17. Kim FJ, Pompeo A, Sehart D, et al. Early effectiveness of endoscopic posterior urethra primary alignment. *J Trauma Acute Care Surg* 2013;75:189-94.
  18. Leddy LS, Vanni AJ, Wessells H, et al. Outcomes of endoscopic realignment of pelvic fracture associated urethral injuries at a level 1 trauma center. *J Urol* 2012;188:174-8.
  19. Al-Ali IH, Husain I. Disrupting injuries of the membranous urethra--the case for early surgery and catheter splinting. *Br J Urol* 1983;55:716-20.
  20. Podestá ML, Medel R, Castera R, et al. Immediate management of posterior urethral disruptions due to pelvic fracture: therapeutic alternatives. *J Urol* 1997;157:1444-8.
  21. Mitchell JP. Trauma to the urethra. *Injury* 1975;7:84-8.
  22. Salehipour M, Khezri A, Askari R, et al. Primary realignment of posterior urethral rupture. *Urol J* 2005;2:211-5.
  23. Fowler JW, Watson G, Smith MF, et al. Diagnosis and treatment of posterior urethral injury. *Br J Urol* 1986;58:167-73.
  24. Crassweller PO, Farrow GA, Robson CJ, et al. Traumatic rupture of the supramembranous urethra. *J Urol* 1977;118:770-1.
  25. Deweerd JH. Management of injuries to the bladder, urethra and genitalia. *Surg Clin North Am* 1959;39:973-87.
  26. Tazi H, Ouali M, Lrhorfi MH, et al. Endoscopic realignment for post-traumatic rupture of posterior urethra. *Prog Urol* 2003;13:1345-50.
  27. Healy CE, Leonard DS, Cahill R, et al. Primary endourologic realignment of complete posterior urethral disruption. *Ir Med J* 2007;100:488-9.
  28. Quint HJ, Stanisis TH. Above and below delayed endoscopic treatment of traumatic posterior urethral disruptions. *J Urol* 1993;149:484-7.
  29. Barry JM. Visual urethrotomy in the management of the obliterated membranous urethra. *Urol Clin North Am* 1989;16:319-24.
  30. Moudouni SM, Patard JJ, Manunta A, et al. Early endoscopic realignment of post-traumatic posterior urethral disruption. *Urology* 2001;57:628-32.
  31. Kotkin L, Koch MO. Impotence and incontinence after immediate realignment of posterior urethral trauma: result of injury or management? *J Urol* 1996;155:1600-3.
  32. Jepson BR, Boullier JA, Moore RG, et al. Traumatic posterior urethral injury and early primary endoscopic realignment: evaluation of long-term follow-up. *Urology*

- 1999;53:1205-10.
33. Gibson GR. Urological management and complications of fractured pelvis and ruptured urethra. *J Urol* 1974;111:353-5.
  34. Jackson DH, Williams JL. Urethral injury: a retrospective study. *Br J Urol* 1974;46:665-76.
  35. Cass AS, Godec CJ. Urethral injury due to external trauma. *Urology* 1978;11:607-11.
  36. Sahin H, Bircan MK, Akay AF, et al. Endoscopic treatment of complete posterior urethral obliteration. *Acta Urol Belg* 1998;66:21-4.
  37. McAninch JW. Traumatic injuries to the urethra. *J Trauma* 1981;21:291-7.
  38. Morehouse DD, Belitsky P, Mackinnon K. Rupture of the posterior urethra. *J Urol* 1972;107:255-8.
  39. Dhabuwala CB, Hamid S, Katsikas DM, et al. Impotence following delayed repair of prostatomembranous urethral disruption. *J Urol* 1990;144:677-8.
  40. Ku JH, Jeon YS, Kim ME, et al. Comparison of long-term results according to the primary mode of management and type of injury for posterior urethral injuries. *Urol Int* 2002;69:227-32.
  41. Husmann DA, Wilson WT, Boone TB, et al. Prostatomembranous urethral disruptions: management by suprapubic cystostomy and delayed urethroplasty. *J Urol* 1990;144:76-8.
  42. Koraitim MM. Pelvic fracture urethral injuries: evaluation of various methods of management. *J Urol* 1996;156:1288-91.
  43. Mouraviev VB, Coburn M, Santucci RA. The treatment of posterior urethral disruption associated with pelvic fractures: comparative experience of early realignment versus delayed urethroplasty. *J Urol* 2005;173:873-6.
  44. Coffield KS, Weems WL. Experience with management of posterior urethral injury associated with pelvic fracture. *J Urol* 1977;117:722-4.
  45. Webster GD, Mathes GL, Selli C. Prostatomembranous urethral injuries: a review of the literature and a rational approach to their management. *J Urol* 1983;130:898-902.
  46. Barrett K, Braga LH, Farrokhyar F, et al. Primary realignment vs suprapubic cystostomy for the management of pelvic fracture-associated urethral injuries: a systematic review and meta-analysis. *Urology* 2014;83:924-9.
  47. Singh BP, Andankar MG, Swain SK, et al. Impact of prior urethral manipulation on outcome of anastomotic urethroplasty for post-traumatic urethral stricture. *Urology* 2010;75:179-82.
  48. Tausch TJ, Morey AF, Scott JF, et al. Unintended negative consequences of primary endoscopic realignment for men with pelvic fracture urethral injuries. *J Urol* 2014;192:1720-4.
  49. Melekos MD, Pantazakos A, Daouaher H, et al. Primary endourologic re-establishment of urethral continuity after disruption of prostatomembranous urethra. *Urology* 1992;39:135-8.

**Cite this article as:** Stein DM, Santucci RA. Pro: endoscopic realignment for pelvic fracture urethral injuries. *Transl Androl Urol* 2015;4(1):72-78. doi: 10.3978/j.issn.2223-4683.2015.01.11