

Management of the Infected Total Hip Arthroplasty

Abstract

In the United Kingdom approximately 80,000 total hip arthroplasties are undertaken on an average each year. The popularity and demand for this operation are continually increasing. Our understanding of arthroplasty surgery and its complications has evolved greatly, and as a result infection rates are undeniably at an all-time low. The increasing volume of operations being performed does, however, mean that we still continue to see an increased number of cases of infection. There is no doubt that periprosthetic joint infection (PJI) poses a complex clinical and diagnostic predicament to clinicians. Delay in the diagnosis and treatment of PJI can not only be detrimental in terms of patient morbidity, but it also poses a significant financial burden to health care institutions. It is therefore in the best interest of the patient, surgeon, and institution to optimize the diagnosis and treatment of this devastating complication. There remains considerable variability in terms of approach to diagnosis and treatment of PJI among orthopedic surgeons. In this review, we will, therefore, examine in detail the current body of evidence available on PJI. We will discuss the most robust and up-to-date methods of diagnosis and offer a comparison of management strategies.

Keywords: Arthroplasty, infection, peri-prosthetic joint infection, revision arthroplasty, total hip arthroplasty

MeSH terms: Hip, replacement, arthroplasty, surgical wound, infection, reoperation

Introduction

In the United Kingdom (UK) approximately 620,400 total hip arthroplasties (THAs) have been carried out between 2003 and 2013.¹ Currently, 80,000 THAs are undertaken on average each year.¹ These figures highlight the ever increasing popularity of this operation. This increase in number is not without risk, however. One of the more devastating complications encountered postoperatively is a deep periprosthetic joint infection (PJI). The risk of PJI is generally considered about 1%. However, there is considerable variability in this figure in the available literature, with figures ranging from 0.57% to 2.23%.² Although the likelihood of infection is relatively small, the impact, and long term implications can be catastrophic.

There is no doubt that PJI poses a difficult clinical and financial burden to orthopedic institutions as well as significant morbidity in patients. It has been previously demonstrated that the average cost for revision surgery in the UK due to infection is approximately \leq £21937, as compared to \leq £11897 for cases of revision for aseptic loosening.³ The patient morbidity and health

burden following PJI, on the other hand, is a much more difficult figure to quantify.

It is clear that the diagnosis and prompt treatment of PJI are beneficial to both the patient, as well as the health care institution. The aim of this article is, therefore, to assimilate the current evidence and offer an up-to-date diagnostic and treatment algorithm for PJI.

Pathophysiology

Infection of any prosthetic material in the body allows microorganisms to evade the host immune defenses. In prosthetic joint infections, bacteria organize into structures called biofilms along the surface of the prosthetic material. These biofilms are highly hydrated, extracellular matrix secreted by bacteria that attach to the surface of a prosthesis, much like a “slime.”⁴ Inside the slime, there is a depletion of metabolic substances and accumulation of waste products, and the bacteria enter a very slow “sesile” growing phase.⁴ In this state, the bacteria are 1000 times more resistant to growth dependent antimicrobials. The bacteria become organized within the biofilm with structural and functional heterogeneity.

In some cases, microorganisms enter the joint cavity at the time of insertion of the

**D’jon Lopez,
Isabel Leach,
Elinor Moore¹,
Alan R Norrish**

Departments of Orthopaedic Surgery and ¹Infectious Diseases, Addenbrooke’s Hospital, Cambridge University Hospitals, Cambridge, CB2 0QQ, UK

Address for correspondence:

Mr. D’jon Lopez,
83, Bailey House, Rustat
Avenue, Cambridge,
CB1 3PG, UK.
E-mail: djlopez@doctors.org.uk

Access this article online

Website: www.ijoonline.com

DOI:
10.4103/ortho.IJOrtho_307_16

Quick Response Code:



How to cite this article: Lopez D, Leach I, Moore E, Norrish AR. Management of the infected total hip arthroplasty. *Indian J Orthop* 2017;51:397-404.

This is an open access article distributed under the terms of the Creative Commons Attribution-NonCommercial-ShareAlike 3.0 License, which allows others to remix, tweak, and build upon the work non-commercially, as long as the author is credited and the new creations are licensed under the identical terms.

For reprints contact: reprints@medknow.com

prosthesis (direct inoculation). For others, the bacteria “seed” to the joint through the bloodstream (hematogenous spread). Hematogenous spread may be through either a clinically significant bacteremia, for example, 34% of staphylococcal bacteremia result in PJI⁵ or a quiescent bacteremia. A common source of bacteria would be from the oral cavity, particularly in those with dental disease. In some cases, the organisms involved can be very low virulence organisms, such as coagulase-negative staphylococci. These organisms are only able to persist due to the presence of prosthetic material and the biofilm. Low virulence infections tend to cause a chronic low-grade infection with a few systemic symptoms. Infections due to high virulence organisms can lead to septicemia and bacterial endocarditis (a typical high virulence organism would be *Staphylococcus aureus*).⁶

Staphylococci species are the most frequent causative organisms. Streptococci and enterococci account for about 10% of cases each, and Gram-negative bacteria account for about 8%.

Diagnosis

The diagnosis of PJI following THA can present a challenging clinical dilemma. In the context of a painful postoperative THA, a high index of suspicion regarding infection should be maintained. To precisely diagnose and treat PJI, it is important to have a suitable working definition. Historically, there has been considerable variation in the definition of PJI.

The Musculoskeletal Infection Society (MSIS) therefore convened in 2011 to propose a standardized definition for PJI.⁷ There were considerable variation and inconsistency in the definition before this. The result is now referred to as “the international consensus statement for PJI” and suggests the following:

A patient is classified as having an infected THA if they have: A sinus tract communicating with the prosthesis; or A pathogen is isolated by culture from two separate tissue or fluid samples obtained from the affected prosthetic joint; or Four of the following six criteria exist: (a) Elevated serum erythrocyte sedimentation rate (ESR) or serum C-reactive protein (CRP) concentration (b) Elevated synovial white blood cell (WBC) count (c) Elevated synovial neutrophil percentage (polymorphonuclear leukocyte % [PMN%]) (d) Presence of purulence in the affected joint (e) Isolation of a microorganism in one culture of periprosthetic tissue or fluid (f) Greater than five neutrophils per high-power field in five high-power fields observed from histologic analysis of peri-prosthetic tissue at 400 times magnification.

There is no single test that can reliably and reproducibly predict infection. This belies the fact the definition for PJI requires multiple criteria to be met. Therefore, a combination of clinical assessment, biochemical testing and diagnostic imaging should be utilized.

Clinical Assessment

A thorough history should be elicited from the patient. In particular, any postoperative issues such as superficial wound infection delayed wound healing and pain should be highlighted. It is also vital to look into the patient’s comorbidities. Several conditions have been shown to correlate with an increased infection risk. These include diabetes mellitus and uncontrolled hyperglycemia, hypothyroidism, immunosuppression, morbid obesity, active liver disease, smoking, renal disease, and HIV infection.⁸⁻¹¹ Also relevant, is a history of recurrent infections, in particular, poor dentition.¹² Finally, it is important within the history for the clinician to assess the onset and duration of symptoms.

Clinical examination is also of the utmost importance. Close inspection of the wound should be undertaken. In particular, any redness, swelling or tenderness should be noted. Although clinical assessment is vital, normal clinical findings do not definitively rule out an infection. Even in the absence of clinical signs, a clinician should maintain a high index of suspicion for infection where a patient has unexplained pain.

Laboratory Investigations

The ESR and serum CRP are key tests that should always be analyzed in assessment for PJI. However, these indicators can be affected by age and medical comorbidities. An ESR >30 mm/h and a CRP >10 mg/L have been shown to represent elevated levels.¹³ The sensitivity and specificity of ESR and CRP varies widely in the available literature.^{14,15} If both the ESR and CRP are normal, however, the probability of infection has been shown to be 3%.¹⁶

WBC count is analyzed, but its role in definitive diagnosis of PJI is limited as it often normal, even when there is a true PJI.

In addition to WCC, CRP, and ESR, novel markers, such as interleukin-6 (IL-6) have been suggested as useful in the diagnosis of PJI. These markers were not included in the MSIS definition of PJI, but an increasing body of evidence supports their use. Elgeidi *et al.* concluded that IL-6 above 10.4 pg/ml and CRP level above 18 mg/L could identify all patients with PJI.¹⁷ Their group found that the combination of CRP + IL-6 demonstrated a sensitivity 100% and negative predictive value of 100%. These figures are not replicated in other publications, but IL-6 appears to have potential to be used in the diagnosis of PJI. It should be noted that IL-6 is not a widely available modality, however.¹⁸

Joint Aspiration and Synovial Fluid Analysis

Joint aspiration has long been accepted as an essential modality in the diagnosis of PJI, and this is clearly borne out in the literature.^{15,16,19,20} The evidence suggests that

antibiotics should be withheld for a minimum of 2 weeks before aspiration. The analysis of the synovial fluid typically includes synovial WBC and synovial PMN%. In acute infections, a synovial WBC of 20,000 cells/ml and synovial PMN% of 89% are considered threshold values. These figures do differ in the context of chronic infection, however. The aspirate should be sent for enriched cultures and antimicrobial sensitivity.⁷

Analyzing synovial fluid using leukocyte esterase (LER) colorimetric testing has also been described. This involves the use of a simple urine dipstick and can provide an instant result. A leukocyte ++ result is generally referred to as a positive result. The drawback of LER testing is that blood stained fluid samples cannot be read and interpreted reliably. The sensitivity and specificity of this test varies in the literature. Parvizi *et al.* showed a sensitivity of 80.6% and a specificity of 100% with a leukocyte ++ reading.²¹ The sensitivity of 100% and a specificity of 97% were demonstrated more recently with a leukocyte ++ reading by Colvin *et al.*²² LER testing is quick, relatively sensitive, and cheap.

Another novel test that can be performed on the synovial fluid is that of alpha-defensin, commercially known as "Synovasure" (Zimmer Inc., Warsaw, USA). Alpha-defensin is a microbial peptide released by neutrophils in response to pathogens. The alpha-defensin PJI test allows a synovial sample to be analyzed intra-operatively and results can be read in 10 min. Synovasure has been shown to have a specificity of 98% and sensitivity of 100%.²³ Like LER testing this can be useful intra-operatively where a single stage versus two-stage revision for infection is being considered. The advantage of Synovasure over LER testing is that blood stained samples do not affect its ability to detect infection. The disadvantage of Synovasure is the price compared to LER testing. Deirmengian *et al.* showed that LER testing could not be done in approximately 17% of their patient group due to blood interference.²⁴ When used on the other samples it displayed a sensitivity of 69% and a specificity of 100%. They demonstrated a 100% sensitivity and specificity using Synovasure. This paper, therefore, supports the use of Synovasure over LER testing.

Molecular techniques such as polymerase chain reaction (PCR) and enzyme-linked immunosorbent assay can also be utilized in diagnosing PJI, in particular identifying the causative organism. Gallo *et al.* found significantly higher sensitivity, accuracy, and negative predictive values were calculated for PCR versus culture.²⁵ In this publication, there was also an 83% concordance between the results of intraoperative culture and PCR detection of causative bacteria.

In addition to the aforementioned synovial fluid tests, emerging biochemical markers have been suggested. These include synovial CRP, human β -defensin-2 and -3, and cathelicidin LL-37. Although they offer promise in the

diagnosis of PJI, there is a lack of clinical evidence to support their routine use at present.²⁶

Soft Tissue Microbiology Cultures

Soft tissue sampling should be undertaken intra-operatively during revision surgery and culture with antimicrobial sensitivities should be performed in the microbiology laboratory. Sensitivity and specificity varies greatly in the published literature for tissue sample culturing. A potential reason could be variation in the technique used to obtain the samples. Another could be the culture method. The MSIS consensus meeting stressed several points regarding sampling. First, with microbiological testing, the recommendation is that each tissue sample is taken with separate, sterile instruments. They also state that at least three, but no more than five samples should be taken and incubated in both aerobic and anaerobic environments. The use of sterile broth containing ballotini beads can increase the pick-up of low-grade organisms (83% sensitivity compared to 38% sensitivity with direct culture plates).²⁷ After the surgeon places the sample in the sterile broth pot, it can be shaken enabling the ballotini beads to dislodge the bacteria from the tissue samples, enhancing the chance of a positive culture, without risking contamination by multiple laboratory steps. An alternative approach to the use of broth pots is the use of standard blood culture bottles (87% sensitivity). Some studies favor the use of placing the prosthesis in a large sterile container of saline and using sonication to disrupt the bacterial biofilm before embarking on culture. The benefit of obtaining multiple samples for culture is not only to increase the yield of difficult to identify organisms but also to be able to decide when a bacteria is more likely to be a contaminant or not. For example, if 3 of 5 specimens culture an identical organism, there is a 96% chance that this is the true causative organism, compared to a 25% chance with 2 positive identical samples.

Histopathology

Histology can be a useful tool in the diagnosis of PJI. The presence of neutrophils in periprosthetic tissue is suggestive of PJI. The MSIS consensus group suggest that when examining for the presence of neutrophils, the histopathologist should disregard neutrophils entrapped in superficial fibrin or adherent to endothelium or small veins.⁷ They also warn of situations in which neutrophil presence may be a normal finding. These include recent periprosthetic fracture and inflammatory arthropathy.

Radiology

Plain X-ray radiographs

In acute PJI, radiographs can quite often be unremarkable. However, in the context of chronic PJI radiographic changes may occur. These include progressive loosening

and osteolysis. Although loosening may not necessarily be due to an underlying infection radiographs should be part of the routine imaging work up. Radiographs are also useful for preoperative planning in the event of revision surgery. It should be noted, however, that there are no features that can reliably differentiate between aseptic loosening and PJI on plain radiographs.

Nuclear medicine

A technetium-Tc-99m isotope bone scan can be performed in the assessment of a painful THA. These scans have been shown to have a high sensitivity, but the low specificity for infection limits their use. An alternative to Tc-99m is an indium-111-labeled white cell scan. These have a much higher sensitivity in infection. This has been shown to be 88%, with a specificity of 95%.²⁸ These can be combined with a single-photon emission computed tomography-computed tomography scan to precisely identify the site of the infection within the hip.²⁹

Treatment

In the treatment of PJI, it is vital to identify the goal of treatment after discussion with the patient. For some patients, the aim may be the eradication of infection while for others the aim may be suppression of infection. Patients should be encouraged to identify the key goals of their treatment, be it the cessation of pain, improvement in function of the limb or avoidance of life-threatening infection. The involvement of a multidisciplinary team is essential to allow shared decision making to determine the best treatment. This team should include specialists in orthopedics, plastic surgery, infectious diseases, microbiology, and radiology.

Antibiotic Suppression

In patients who are unable to undergo revision surgery due to medical comorbidities, long term oral antibiotic suppressive therapy can be considered.³⁰ Here, the objective is not necessarily a clinical cure of infection, but maintenance of the functional status of the patient. Although studies have been conducted looking at suppression therapy, the efficacy is difficult to quantify. In one study, 60% of patients undergoing suppressive therapy reported no major events at their 2 years followup.³¹ An event was considered persistent or recurrent infection, treatment discontinuation due to severe adverse events, related and unrelated death. When considering suppressive treatment, aspiration of the hip is vital to attempt identification of the causative organism. Some virulent organisms, such as *S. aureus* or Group A streptococci have a high risk of life-threatening septicemia if the suppression strategy fails, and this needs to be considered before undertaking this option. The identification of the causative organism also allows choice of narrow spectrum antibiotics with fewer side effects. This strategy does have unpredictable results and should only

be considered if surgery is not possible. The longer the antibiotics are used, the higher the chances of developing bacterial resistance to the antibiotics being used. The type and duration of antibiotics used should be based on the organism grown from an aseptic hip aspiration sample. If no organism is grown, then the opinion of a Microbiologist experienced in the treatment of PJI should be sought.

Resection Arthroplasty

Resection arthroplasty involves thorough debridement, irrigation, and implant removal. Leaving the proximal femur without an implant is possible; as is the case with a Girdlestone procedure, but it results in significant leg length discrepancy and a poor functional outcome.^{32,33} This option should, therefore, only be considered as a salvage option in patients who may not be able to tolerate revision surgery.

Debridement, Antibiotics and Implant Retention

Debridement, antibiotics, implant retention (“DAIR”) can be considered in acute PJI. Kuiper *et al.* found that 66% of their patient group were infection free at their 2 years followup following DAIR for PJI. The group also highlighted several factors that predict treatment failure. These include rheumatoid arthritis, late infection (>2 years after arthroplasty), ESR at presentation above 60 mm/h and infection caused by coagulase-negative *Staphylococcus*.³⁴ Symptom duration of <1 week was associated with treatment success. DAIR should, therefore, be given consideration in cases of acute PJI. The exact definition of acute PJI is variable in the literature, but <6 weeks appears to be the most widely recognized. This surgical strategy needs to be followed by a prolonged antibiotic course.³⁴ The length of antibiotic treatment is not agreed in the literature. Byren *et al.* found in analysis of DAIR outcomes that the duration of antibiotics after a certain period did not predict outcome.³⁵ Based on this paper, our usual practice is to give 3 months of antibiotics after an infected THA (6 weeks intravenously and 6 weeks orally).

Single-stage Revision

Single stage revision generally refers to a single operation where all components are removed, soft tissues aggressively debrided, irrigated, and a new prosthesis is re-implanted. This can be performed in multiple ways. Some centers, including our own, advocate closing the wound after the initial debridement and re-draping with new instruments. Success with single-stage revision is related to the quality of the debridement and 6 weeks of postoperative antibiotics.

Poor outcome in single-stage surgery is strongly linked with PJI due to virulent microorganisms. These include methicillin-resistant *S. aureus* (MRSA) and Group D *Streptococcus*.³⁶ A successful outcome is associated with less virulent organisms. Zahar and Gehrke have recently shown that the main requirement for single stage surgery

is the presurgical determination of the infective organism's sensitivity.³⁷ Furthermore, antibiotic-loaded cement can also be used. This is particularly effective if antibiotic sensitivities are known.

The advantages of performing single-stage revision surgery are clear. Avoiding the second operation can facilitate a quicker return to function for the patient and a potentially lower cost burden for the health institution. Furthermore, the risks associated with additional surgery for the patient are negated. The concern with this approach is that any remaining bacteria in the surgical field can form a biofilm on the new prosthesis, making it very difficult to treat with antibiotics thereafter. Although the evidence base is variable, several studies have demonstrated similar results to two-stage revision.^{36,37} Moore *et al.* recently showed a greater impact on patient well being in patients who had 2 stage revisions when compared to single stage.³⁸

Two-stage Revision

Two-stage exchange revision has long been thought of as the gold standard treatment in PJI.³⁹ This involves an initial debridement and irrigation of the infected joint followed by 6 weeks of antibiotics. Resolution of infection should be

confirmed with serial biochemical markers (ESR, CRP) or repeat joint aspiration. When the recurrent infection has been ruled out a second procedure is carried out to re-implant a prosthesis. It is quite common for temporary antibiotic cement spacers to be used during the first stage procedure.

The spacer provides appropriate limb lengths and soft tissue tension between stages. This has several advantages, including improved patient function, and prevention of soft-tissue contracture. This is advantageous to both the patient and surgeon. In addition to this, spacers can also be used as a source of local delivery of antibiotics.⁷

Currently, there are no prospective randomized controlled comparative studies comparing the outcomes of single versus two-stage revisions in infection. It is therefore difficult to definitively comment on the superiority of one or the other. Indeed, Beswick *et al.* showed no significant difference in re-infection rates between single- and two-stage revisions in their systematic review.⁴⁰

Choice of Antibiotics

The optimal antibiotic in each of these situations would be one that is narrow in its spectrum of cover (to avoid side

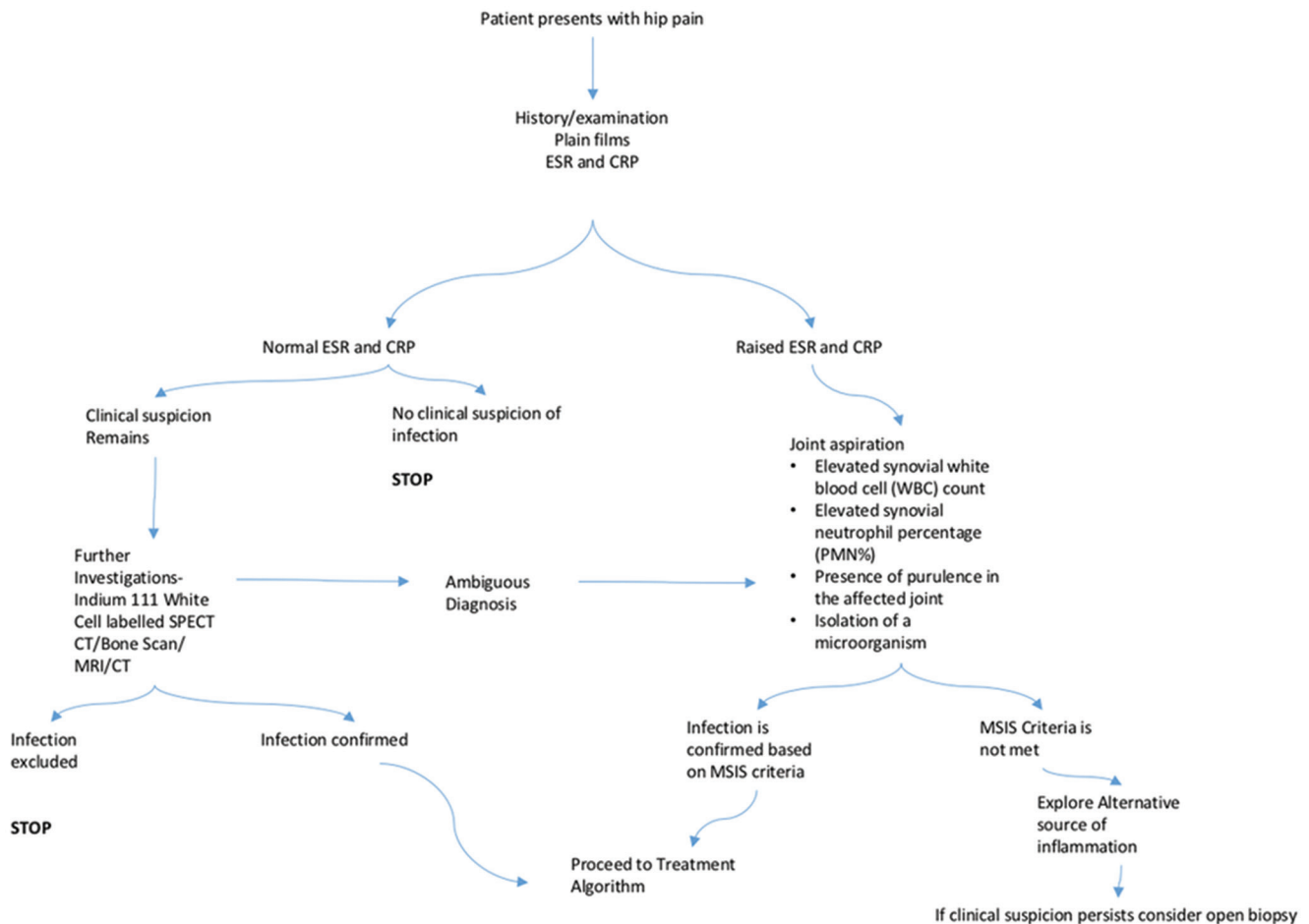


Figure 1: Diagnostic algorithm

effects from broad spectrum antimicrobial therapy) and penetrates the bone, joint, and biofilm well. In choosing a narrow spectrum antibiotic the causative organism and its sensitivities must be identified. Where cultures are negative, a broad spectrum antimicrobial that covers both Gram-positive and negative organisms is chosen. In patients highly exposed to environments with antibiotic resistant organisms (e.g., hospitals), cover for MRSA should also be included.

To achieve effective drug levels in the bone and joint, most antibiotics are more effective when given via the intravenous route, resulting in high serum levels compared to oral dosing. This is particularly true for beta-lactam antibiotics (e.g., penicillins and cephalosporins). Several antibiotics have good oral bioavailability and bone penetration, for example, quinolone antibiotics, rifampicin, linezolid, and clindamycin. This difference is reflected in the variety of recommendations in guidelines, with American-based guidelines⁴¹ recommending intravenous antibiotic therapy and European guidelines recommending

oral antibiotic therapy. The results of a large randomized controlled trial comparing the strategy of oral versus intravenous antibiotics for bone and joint infections will be published later this year.⁴²

There are very few antibiotics that effectively penetrate a biofilm. Rifampicin is a key antibiotic that can achieve this and should be used if possible when the prosthetic material remains *in situ*.

Conclusions

PJI is a devastating complication for the patient and surgeon alike. In this paper, we have given a thorough and up-to-date interpretation of the current evidence regarding the diagnosis and treatment of PJI.

A few salient points can be concluded. First, when faced with PJI, a key principle in the management should be the treatment of the patient within a multi disciplinary team framework. The inclusion of the microbiology or infectious diseases team from an early stage is paramount to success.

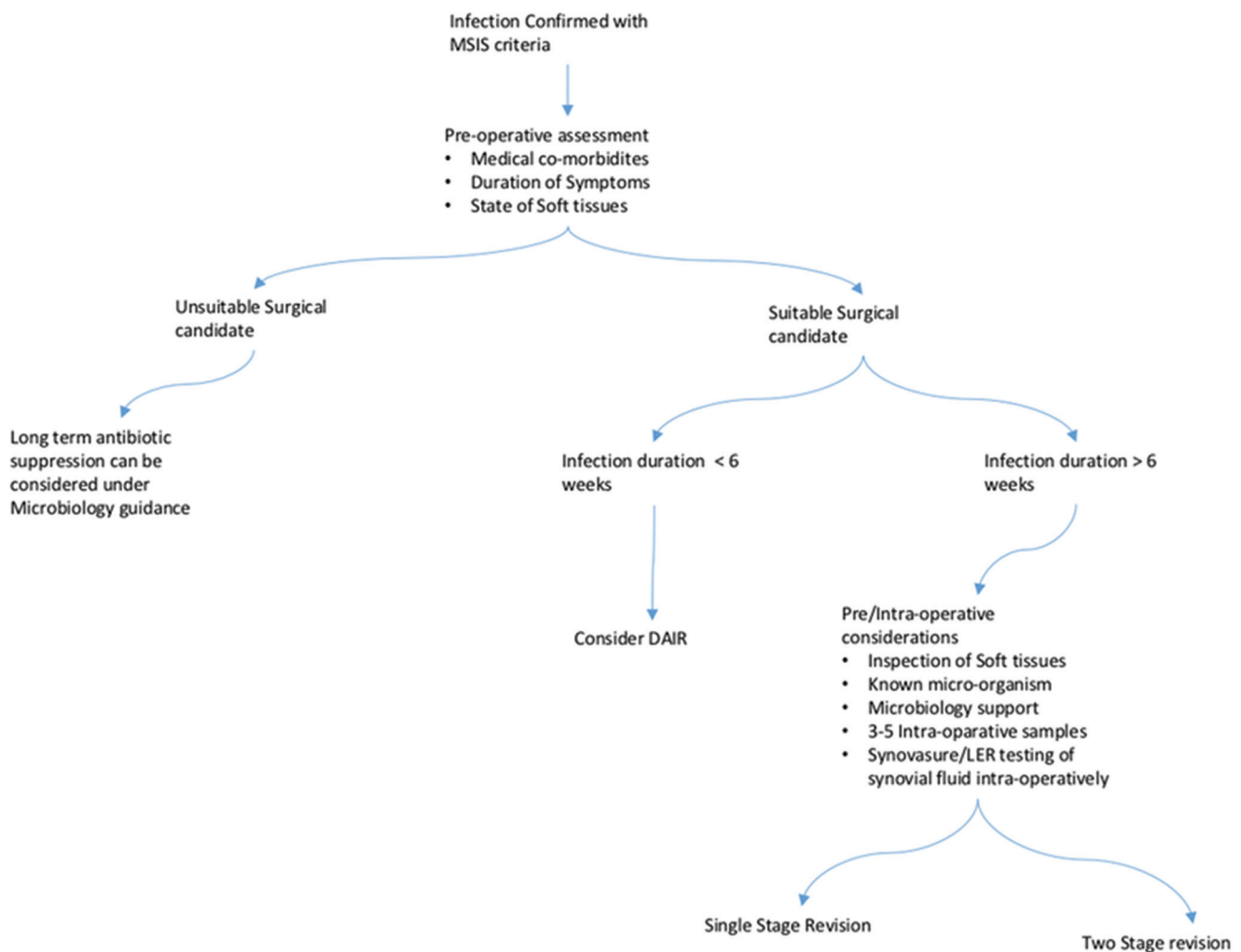


Figure 2: Treatment algorithm

Second, a well-organized and universally adopted protocol should be applied to ensure the prompt and accurate diagnosis of PJI. This, in turn, can lead to optimal treatment results being obtained. Although the diagnosis of PJI still remains a significant clinical challenge, the introduction of the MSIS consensus statement helps to streamline the process. An example of a simple protocol for diagnosis and treatment of PJI can be seen below [Figures 1 and 2]. PJI although devastating, is a relatively rare complication and not often seen by individual arthroplasty surgeons on a regular basis. The introduction of specialist bone infection units or networks may, therefore, offer some future promise in terms of providing the aforementioned multi disciplinary team approach.

The future of PJI diagnosis and treatment will undoubtedly hinge on the advancement of rapid, accurate, and affordable diagnostic modalities. Alpha-defensin detection has shown promise, but its cost may be a limiting factor. Research into alternative biochemical markers also holds potential for developing more robust tests. Beyond this, research into prevention of infection will also play a pivotal role in terms of reducing the overall PJI burden.

Financial support and sponsorship

Nil.

Conflicts of interest

There are no conflicts of interest.

References

- 11th Annual Report 2014. National Joint Registry for England, Wales and Northern Ireland.
- Phillips JE, Crane TP, Noy M, Elliott TS, Grimer RJ. The incidence of deep prosthetic infections in a specialist orthopaedic hospital: A 15-year prospective survey. *J Bone Joint Surg Br* 2006;88:943-8.
- Vanhegan IS, Malik AK, Jayakumar P, Ul Islam S, Haddad FS. A financial analysis of revision hip arthroplasty: The economic burden in relation to the national tariff. *J Bone Joint Surg Br* 2012;94:619-23.
- McConoughey SJ, Howlin R, Granger JF, Manring MM, Calhoun JH, Shirliff M, *et al.* Biofilms in periprosthetic orthopedic infections. *Future Microbiol* 2014;9:987-1007.
- Murdoch DR, Roberts SA, Fowler VG Jr., Shah MA, Taylor SL, Morris AJ, *et al.* Infection of orthopedic prostheses after *Staphylococcus aureus* bacteremia. *Clin Infect Dis* 2001;32:647-9.
- Connaughton A, Childs A, Dylewski S, Sabesan VJ. Biofilm disrupting technology for orthopedic implants: What's on the Horizon? *Front Med (Lausanne)* 2014;1:22.
- Workgroup Convened by the Musculoskeletal Infection Society. New definition for periprosthetic joint infection. *J Arthroplasty* 2011;26:1136-8.
- Falakassa J, Diaz A, Schneiderbauer M. Outcomes of total joint arthroplasty in HIV patients. *Iowa Orthop J* 2014;34:102-6.
- Tan TL, Rajeswaran H, Haddad S, Shahi A, Parvizi J. Increased risk of periprosthetic joint infections in patients with hypothyroidism undergoing total joint arthroplasty. *J Arthroplasty* 2016;31:868-71.
- Reina N, Delaunay C, Chiron P, Ramdane N, Hamadouche M; Société française de chirurgie orthopédique et traumatologique. Infection as a cause of primary total hip arthroplasty revision and its predictive factors. *Orthop Traumatol Surg Res* 2013;99:555-61.
- Berbari EF, Hanssen AD, Duffy MC, Steckelberg JM, Ilstrup DM, Harmsen WS, *et al.* Risk factors for prosthetic joint infection: Case-control study. *Clin Infect Dis* 1998;27:1247-54.
- Berbari EF, Osmon DR, Carr A, Hanssen AD, Baddour LM, Greene D, *et al.* Dental procedures as risk factors for prosthetic hip or knee infection: A hospital-based prospective case-control study. *Clin Infect Dis* 2010;50:8-16.
- Shih LY, Wu JJ, Yang DJ. Erythrocyte sedimentation rate and C-reactive protein values in patients with total hip arthroplasty. *Clin Orthop Relat Res* 1987; Dec: (225) 238-46.
- Berbari EF, Mabry T, Tsaras G, Spangehl M, Erwin PJ, Murad MH, *et al.* Inflammatory blood laboratory levels as markers of prosthetic joint infection: A systematic review and meta-analysis. *J Bone Joint Surg Am* 2010;92:2102-9.
- Spangehl MJ, Masri BA, O'Connell JX, Duncan CP. Prospective analysis of preoperative and intraoperative investigations for the diagnosis of infection at the sites of two hundred and two revision total hip arthroplasties. *J Bone Joint Surg Am* 1999;81:672-83.
- Fink B, Makowiak C, Fuerst M, Berger I, Schäfer P, Frommelt L. The value of synovial biopsy, joint aspiration and C-reactive protein in the diagnosis of late peri-prosthetic infection of total knee replacements. *J Bone Joint Surg Br* 2008;90:874-8.
- Elgeidi A, Elganainy AE, Abou Elkhier N, Rakha S. Interleukin-6 and other inflammatory markers in diagnosis of periprosthetic joint infection. *Int Orthop* 2014;38:2591-5.
- Deirmengian C, Kardos K, Kilmartin P, Cameron A, Schiller K, Parvizi J. Diagnosing periprosthetic joint infection: Has the era of the biomarker arrived? *Clin Orthop Relat Res* 2014;472:3254-62.
- Ali F, Wilkinson JM, Cooper JR, Kerry RM, Hamer AJ, Norman P, *et al.* Accuracy of joint aspiration for the preoperative diagnosis of infection in total hip arthroplasty. *J Arthroplasty* 2006;21:221-6.
- Fehring TK, Cohen B. Aspiration as a guide to sepsis in revision total hip arthroplasty. *J Arthroplasty* 1996;11:543-7.
- Parvizi J, Jacovides C, Antoci V, Ghanem E. Diagnosis of periprosthetic joint infection: The utility of a simple yet unappreciated enzyme. *J Bone Joint Surg Am* 2011;93:2242-8.
- Colvin OC, Kransdorf MJ, Roberts CC, Chivers FS, Lorans R, Beauchamp CP, *et al.* Leukocyte esterase analysis in the diagnosis of joint infection: Can we make a diagnosis using a simple urine dipstick? *Skeletal Radiol* 2015;44:673-7.
- Frangiamore SJ, Gajewski ND, Saleh A, Farias-Kovac M, Barsoum WK, Higuera CA. α -defensin accuracy to diagnose periprosthetic joint infection-best available test? *J Arthroplasty* 2016;31:456-60.
- Deirmengian C, Kardos K, Kilmartin P, Cameron A, Schiller K, Booth RE Jr., *et al.* The alpha-defensin test for periprosthetic joint infection outperforms the leukocyte esterase test strip. *Clin Orthop Relat Res* 2015;473:198-203.
- Gallo J, Kolar M, Dendis M, Loveckova Y, Sauer P, Zapletalova J, *et al.* Culture and PCR analysis of joint fluid in the diagnosis of prosthetic joint infection. *New Microbiol* 2008;31:97-104.
- Parvizi J, Zmistowski B, Berbari EF, Bauer TW, Springer BD, Della Valle CJ, *et al.* New definition for periprosthetic joint infection: From the Workgroup of the Musculoskeletal Infection Society. *Clin Orthop Relat Res* 2011;469:2992-4.
- Hughes HC, Newnham R, Athanasou N, Atkins BL, Bejon P,

- Bowler IC. Microbiological diagnosis of prosthetic joint infections: A prospective evaluation of four bacterial culture media in the routine laboratory. *Clin Microbiol Infect* 2011;17:1528-30.
28. Johnson JA, Christie MJ, Sandler MP, Parks PF Jr., Homra L, Kaye JJ. Detection of occult infection following total joint arthroplasty using sequential technetium-99m HDP bone scintigraphy and indium-111 WBC imaging. *J Nucl Med* 1988;29:1347-53.
 29. Palestro CJ. Nuclear medicine and the failed joint replacement: Past, present, and future. *World J Radiol* 2014;6:446-58.
 30. Giacometti Ceroni R, Bianchi L, Mondini A, Zagra L. Peri-prosthetic infections. When to avoid surgery. *Hip Int* 2012;22 Suppl 8:S75-8.
 31. Prendki V, Zeller V, Passeron D, Desplaces N, Mamoudy P, Stirnemann J, *et al.* Outcome of patients over 80 years of age on prolonged suppressive antibiotic therapy for at least 6 months for prosthetic joint infection. *Int J Infect Dis* 2014;29:184-9.
 32. Girdlestone GR. Discussion on the late results of operation for chronic painful hip. *Proc R Soc Med* 1926;19:48-9.
 33. Falahee MH, Matthews LS, Kaufer H. Resection arthroplasty as a salvage procedure for a knee with infection after a total arthroplasty. *J Bone Joint Surg Am* 1987;69:1013-21.
 34. Kuiper JW, Vos SJ, Saouti R, Vergroesen DA, Graat HC, Debets-Ossenkopp YJ, *et al.* Prosthetic joint-associated infections treated with DAIR (debridement, antibiotics, irrigation, and retention): Analysis of risk factors and local antibiotic carriers in 91 patients. *Acta Orthop* 2013;84:380-6.
 35. Byren I, Bejon P, Atkins BL, Angus B, Masters S, McLardy-Smith P, *et al.* One hundred and twelve infected arthroplasties treated with 'DAIR' (debridement, antibiotics and implant retention): Antibiotic duration and outcome. *J Antimicrob Chemother* 2009;63:1264-71.
 36. Muñoz-Mahamud E, Gallart X, Soriano A. One-stage revision arthroplasty for infected hip replacements. *Open Orthop J* 2013;7:184-9.
 37. Zahar A, Gehrke TA. One-stage revision for infected total hip arthroplasty. *Orthop Clin North Am* 2016;47:11-8.
 38. Moore AJ, Blom AW, Whitehouse MR, Goberman-Hill R. Deep prosthetic joint infection: A qualitative study of the impact on patients and their experiences of revision surgery. *BMJ Open* 2015;5:e009495.
 39. Berend KR, Lombardi AV Jr., Morris MJ, Bergeson AG, Adams JB, Sneller MA. Two-stage treatment of hip periprosthetic joint infection is associated with a high rate of infection control but high mortality. *Clin Orthop Relat Res* 2013;471:510-8.
 40. Beswick AD, Elvers KT, Smith AJ, Goberman-Hill R, Lovering A, Blom AW. What is the evidence base to guide surgical treatment of infected hip prostheses? systematic review of longitudinal studies in unselected patients. *BMC Med* 2012;10:18.
 41. Osmon DR, Berbari EF, Berendt AR, Lew D, Zimmerli W, Steckelberg JM, *et al.* Diagnosis and management of prosthetic joint infection: Clinical practice guidelines by the Infectious Diseases Society of America. *Clin Infect Dis* 2012;56:e1-e25.
 42. Li HK, Scarborough M, Zambellas R, Cooper C, Rombach I, Walker AS, *et al.* Oral versus intravenous antibiotic treatment for bone and joint infections (OVIVA): Study protocol for a randomised controlled trial. *Trials* 2015;16:583.