

***Salmonella* spondylodiscitis and epidural abscess successfully treated with unilateral biportal endoscopic discectomy and debridement: a rare case report**

Journal of International Medical Research
50(3) 1–10

© The Author(s) 2022

Article reuse guidelines:

sagepub.com/journals-permissions

DOI: 10.1177/03000605221085405

journals.sagepub.com/home/imr



Ta-Li Hsu¹ , Chia-Jui Yang^{2,3} and
Jwo-Luen Pao^{1,4} 

Abstract

Spinal epidural abscess (SEA) is a rare but severe infection with potentially devastating consequences. Epidural abscesses caused by *Salmonella* serogroup C2 are even rarer and tend to be more invasive with multidrug resistance. Early diagnosis, effective use of antibiotics and surgical intervention are the mainstay strategies for managing SEA, especially for more virulent and multidrug-resistant *Salmonella* infections. This case report presents a rare case of an elderly and fragile woman with *Salmonella* spondylodiscitis and an extensive epidural abscess, which were successfully treated with intravenous antibiotics and unilateral biportal endoscopic (UBE) debridement and drainage through four small surgical incisions. After surgery, her fever subsided, she regained consciousness and her low back pain dramatically improved. Follow-up magnetic resonance imaging showed complete resolution of the epidural abscess. At 6 months after surgery, the patient regained muscle strength, ambulated with a walker and had no recurrence of the infection. The UBE technique can effectively eradicate infection while minimizing surgery-related risks and complications. A multidisciplinary team is required to achieve a good outcome.

¹Department of Orthopaedic Surgery, Far Eastern Memorial Hospital, New Taipei City

²Department of Infectious Disease, Division of Internal Medicine, Far Eastern Memorial Hospital, New Taipei City

³School of Medicine, National Yang Ming Chiao Tung University, Taipei

⁴General Education Centre, Longhua University of Science & Technology, Taoyuan

Corresponding author:

Jwo-Luen Pao, Department of Orthopaedic Surgery, Far Eastern Memorial Hospital, No. 21, Sec. 2, Nanya South Road, Banqiao District, New Taipei 220.
Email: jwoluenpao@gmail.com



Keywords

Salmonella, spinal epidural abscess, minimally invasive, unilateral biportal endoscopic technique, endoscopic spine surgery

Date received: 1 November 2021; accepted: 17 February 2022

Introduction

Spinal epidural abscess (SEA) was first reported by Bergamaschi in 1820 and is more commonly seen in the sixth and seventh decades of life.¹ It is defined as the presence of an infection focus between the dura mater and the surrounding fatty tissue; and accumulation of inflammatory materials or pus is observed in this space.² It is a rare but serious disease, with an estimated incidence of 0.2–2.8 cases per 10 000 persons per year.³ The SEA can be life-threatening and has a reported mortality rate as high as 3%–25%.⁴ The most common pathogen causing SEA is *Staphylococcus aureus*.⁵ SEA caused by *Salmonella* species is extremely rare, with only a few cases reported in the literature.^{6,7} Among all the serogroups, *Salmonella* serogroup C2 is known to be more invasive than the other serogroups and has a multi-drug resistance rate of up to 83%.⁸

Early diagnosis and prompt treatment are critical in SEA. SEA should be suspected in patients with a typical triad of fever, back pain and neurological deficits.⁴ Early surgical intervention is very important in the management of SEA. In elderly patients with multiple comorbidities, decision-making with respect to conventional open surgery for debridement and drainage is a dilemma.⁹ A minimally invasive approach is a reasonable option to minimize the risks and morbidities associated with open surgery. Unilateral biportal endoscopic (UBE) spine surgery is a thriving, minimally-invasive technique that can provide effective decompression with minimal soft tissue injury.^{9,10}

This report described a rare case of *Salmonella* spondylodiscitis and an extensive epidural abscess in an elderly, fragile patient with failure of conservative treatment with intravenous antibiotics alone. The patient was salvaged from life-threatening sepsis after UBE debridement and drainage, antibiotic coverage, and multidisciplinary teamwork.

Case report

In August 2019, an 85-year-old female patient with multiple medical comorbidities, including diabetes mellitus, coronary artery disease (status post coronary artery graft bypass), chronic renal disease, urolithiasis, and colonic tubular adenoma (status post laparoscopic right hemicolectomy), presented to the emergency department of the Far Eastern Memorial Hospital, New Taipei City with fever (up to 39.5°C) and chills for 1 day. At triage, the patient had high fever up to 39.5°C, the pulse rate was 98 bpm, the respiratory rate was 20/min and the blood pressure was 165/75 mmHg. The patient denied any recent travel history or contact with other unwell individuals. The only notable physical finding was vague back pain at her right flank with a visual analogue scale (VAS) pain score of 6. The neurological examination showed essentially normal findings with no sensory deficits, motor weakness or sphincter dysfunction. The deep tendon reflexes were also normal with no Babinski sign or ankle clonus on both lower legs. The total white blood cell count was $8.94 \times 10^3/\mu\text{l}$. She also had pyuria (white blood cell

count, 88.8/high-power field; bacterial count: $3.47 \times 10^5/\text{ml}$) and an elevated serum C-reactive protein (CRP) level (15.6 mg/dl). Abdominal sonography showed no evidence of urinary tract calculi or abnormal fluid accumulation in the retroperitoneal space. The patient was admitted to the Department of Infectious Diseases, Far Eastern Memorial Hospital, New Taipei City with presumed urosepsis. An empirical broad-spectrum antibiotic was initiated (500 mg meropenem intravenous [i.v.] every 12 h). Blood and urine cultures yielded *Salmonella* serogroup C2 with multidrug resistance. The patient had a seizure-like event while on meropenem; thus, the antibiotic was changed to 250 mg doripenem i.v. every 12 h according to the susceptibility test.

The patient's fever gradually subsided to around 36°C after 2 weeks of antibiotic administration. However, her back pain worsened (VAS pain score increased from 6 to 8), gradually concentrated in the axial region and extended from the thoracolumbar junction to the sacral region. Simultaneously, she experienced conscious disturbance, progressive lower limb weakness (the manual muscle power of the bilateral quadriceps femoris muscles deteriorated from 5 to 3), urinary retention and loss of anal tone. Initial plain radiographs of the lumbar spine revealed intervertebral disc space narrowing at the L4–L5 level and erosion of the L5 superior endplate. Lumbar spine magnetic resonance imaging (MRI) demonstrated discitis at the L4–L5 intervertebral disc with a ventral epidural abscess extending from L1 to L4 (Figure 1a). Bacterial culture obtained from the computed tomography-guided biopsy of the L4–L5 intervertebral disc space was negative. However, repeated blood cultures also yielded *Salmonella* serogroup C2.

Progression of lower limb weakness was rapid, and the patient became paraplegic within the next 2 weeks, even under the

coverage of intravenous antibiotics. Surgical debridement and drainage were recommended; however, her family did not consent to the procedures because of concerns about the potential risks of general anaesthesia and traditional open surgery.

Despite the strong and sensitive intravenous antibiotics used against *Salmonella* infection, her back pain increased in severity (VAS pain score from 8 to 9), such that even moving her body in bed caused extreme pain. Consciousness disturbance, paraplegia and loss of anal tone showed no improvement. Leukocytosis ($11.23 \times 10^3/\mu\text{l}$) and elevated serum CRP level (12.86 mg/dl) suggested that the infection was still progressing. Repeated lumbar spine MRI 2 months after the prior MRI demonstrated progression of the infection and enlargement of the epidural abscess extending from T12 to S1 with more severe compression of the thecal sac (Figure 1b). Antibiotic treatment was changed to 1.5 MIU colistin i.v. every 12 h due to the poor response to the previous antibiotics. We were consulted for a second opinion regarding a surgical intervention. We suggested minimally-invasive surgical debridement and decompression using the UBE technique. The family consented for the UBE surgery, which was performed after 80 days of conservative treatment.

The UBE surgery was performed through two small surgical incisions through the deep fascia on the left side of the spinous process (Figure 2a). The paraspinal muscles were gently split using serial dilators to establish the portals. The cranial portal (5 mm) was used to insert the 30° endoscope and continuous inflow of normal saline; the caudal portal (10 mm) was used for outflow of the normal saline and passage of the surgical instruments.

The UBE laminotomy was first performed at L1–L2 via the posterior interlaminar approach to drain the epidural abscess.

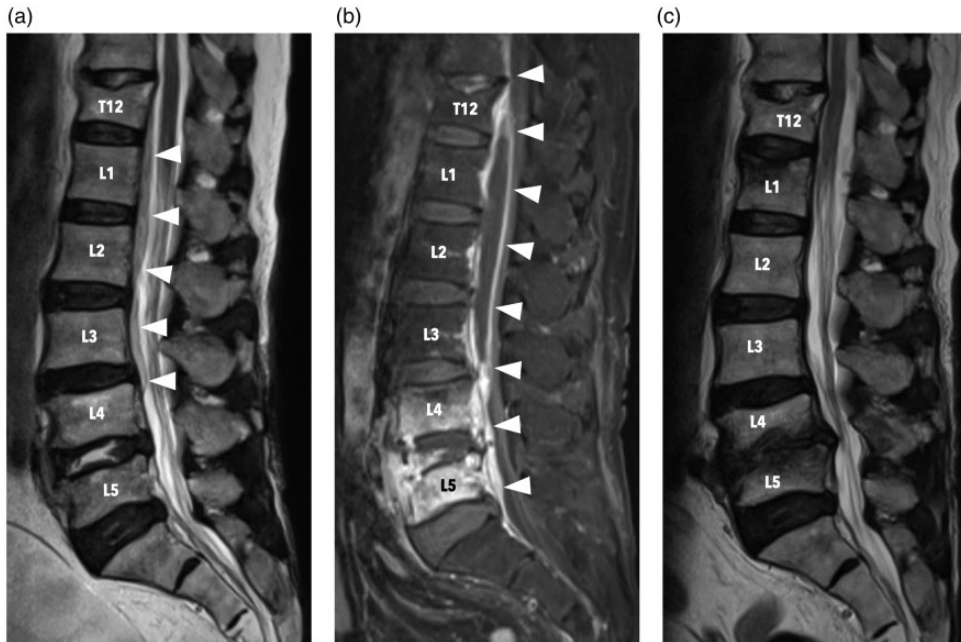


Figure 1. Serial magnetic resonance imaging (MRI) of the thoracolumbar spine of an 85-year-old female patient with multiple medical comorbidities that presented with fever and chills for 1 day. (a) Initial T2-weighted MRI without contrast showed discitis at L4/L5 with anterior soft tissue extension and an epidural abscess extending from L1 to L4 (white arrowheads). (b) Repeat T1-weighted MRI with contrast 2 months later showing spondylodiscitis at L4 and L5 and progression of the epidural abscess extending from T12 to S1 (white arrowheads) with severe thecal sac compression. (c) Follow-up T2-weighted MRI without contrast at 3 months after surgery showed resolution of the epidural abscess, expansion of the thecal sac and L4–L5 disc destruction.

By gently retracting the dura, a well-encapsulated epidural abscess was easily identified on the ventral side. A 20-gauge needle was used to aspirate the abscess and obtain a sample for bacterial culture. There was turbid fluid inside the abscess but no frank pus. The abscess was then incised, drained and irrigated with normal saline. A 1/8" closed suction drain tube was inserted into the epidural abscess. The placement of the drain tube was confirmed using fluoroscopy (Figures 2b and 2c). Thereafter, UBE discectomy and debridement were performed at L4–L5 via the posterior interlaminar approach. The disc space was aspirated to obtain a sample for the bacterial culture. Then, radical

discectomy and debridement of the L4–L5 disc were completed with curets and pituitary clamps. There was no frank pus inside the disc; however, necrotic tissue, fragmented disc materials and endplates were present. After thorough irrigation, two 1/8" closed suction drain tubes were placed into the disc space for drainage. The operation time was 3 h and the estimated blood loss was <10 ml.

After surgery, the patient was transferred to the intensive care unit for postoperative care and mechanical ventilation support. The patient became unconscious at approximately 1 week before the surgery and she regained consciousness 2 days after the surgery. The VAS score for back pain

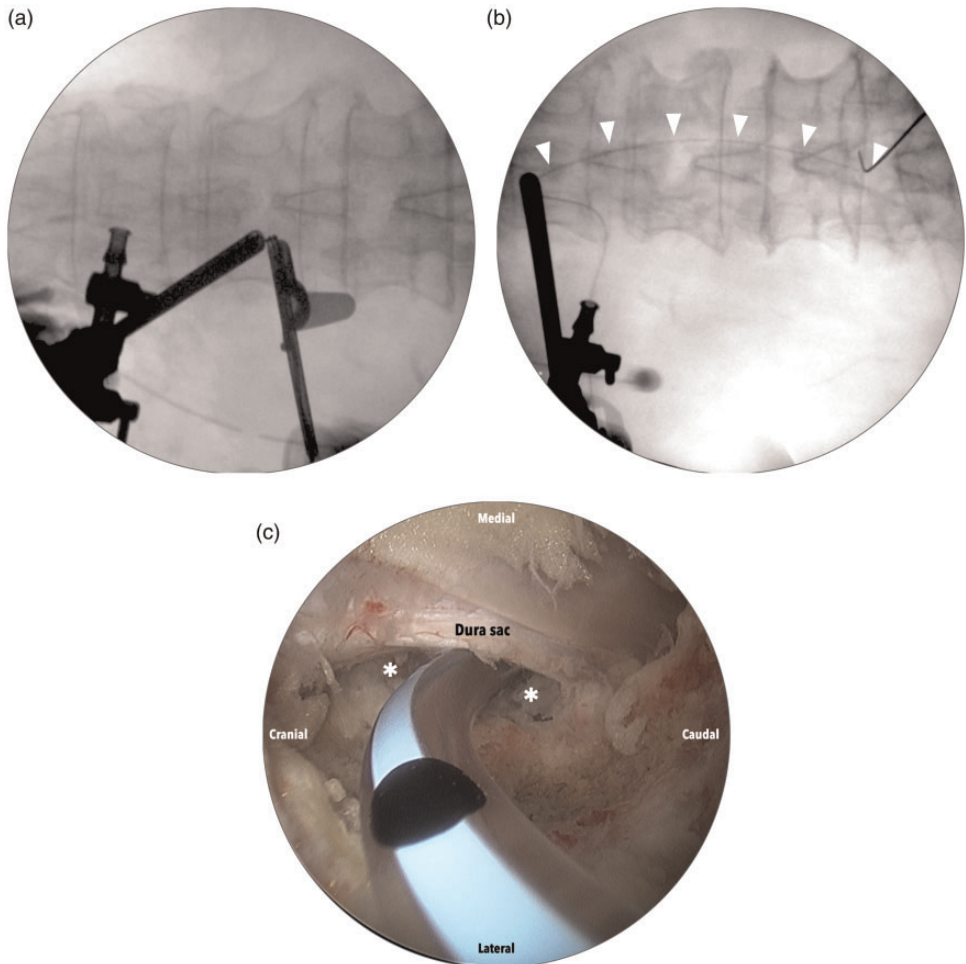


Figure 2. Intra-operative images of an 85-year-old female patient with multiple medical comorbidities that presented with fever and chills for 1 day. (a) Intra-operative fluoroscopic image showed the triangulation formed by the arthroscope in the surgeon's left hand and surgical instruments in the surgeon's right hand while performing the unilateral biportal endoscopic surgery. (b) An 1/8" drain tube (white arrowheads) was inserted through the L1–L2 laminotomy into the epidural abscess and placed deeply to the L4–L5 disc level, which was confirmed by fluoroscopy. (c) Intra-operative endoscopic photograph of the drain tube inserted into the abscess (asterisk) located in the ventral epidural space. The colour version of this figure is available at: <http://imr.sagepub.com>.

improved from 9 to 2 in 1 week and the pain medications were reduced to 37.5 mg/325 mg tramadol/acetaminophen oral twice daily. As soon as she regained consciousness, an intensive rehabilitation programme with an emphasis on respiratory care and strengthening exercises for changing

position. The endotracheal tube was removed 2 weeks later and she was moved from the intensive care unit to the ordinary ward after 24 days. With aggressive rehabilitation, she could change her position and sit on the bed independently. The drain tubes were removed after the drainage

amount decreased to <5 ml/day. Colistin was maintained for 4 weeks after the surgery (total of 5 weeks). The renal function was checked regularly with the serum creatinine levels maintained between 1.50 and 1.80 mg/dl. Cultures from the intraoperative tissue and abscess samples were negative. At 2 weeks after surgery, the CRP level decreased from 12.86 to 1.58 mg/dl and leukocytosis improved from 11.23 to $6.26 \times 10^3/\mu\text{l}$. An extensive rehabilitation programme was initiated. The manual muscle power of her bilateral quadriceps femoris improved gradually from 0/5 to 3/5 at approximately 8 weeks after surgery. Follow-up MRI of the lumbar spine at 3 months after surgery showed complete resolution of the epidural abscess (Figure 1c). At 6 months after surgery, the muscle power of all the lower limb muscles improved to at least 4/5 and she could ambulate using a walker. Although the patient was completely bed-ridden for such a long time, she had no pressure sores at all under careful nursing care. The infection specialist did not give up on the patient and sought the second surgical option using the UBE technique. The intensive care unit and rehabilitation team worked very hard to help her regain her respiratory function, muscle power and ambulatory ability. The patient and her family were extremely satisfied with the multidisciplinary teamwork and the treatment results.

This case report was approved by the Institutional Ethics Committee of the Far Eastern Memorial Hospital, New Taipei City (approval no. 110128-C). Verbal informed consent was obtained from the patient and it was confirmed that she understood that her diagnosis, data and treatment course would be used for publication of this case report. All of the patient's details were deidentified.

Discussion

Elderly patients or patients with multiple comorbidities and impaired immunity are susceptible to SEA, and common risk factors include diabetes mellitus, intravenous drug or alcohol abuse, human immunodeficiency virus infection, chronic renal disease, malignancy, and recurrent urinary, respiratory and skin infections.⁵ This current patient was 85 years old and had diabetes mellitus and chronic diseases involving at least three organ systems; thus, SEA should be one of the considerations if the patient presents with fever and lower back pain.

Spinal epidural abscess caused by *Salmonella* species is extremely rare, with only a few cases reported in the literature.^{6,7} Although typhoidal *Salmonella* is no longer an issue in our country with effective vaccines and successful public health measures, there are sporadic cases of non-typhoidal *Salmonella*. Most patients with non-typhoid *Salmonella* infection present with gastroenteritis or enteric fever, which is usually self-limiting. However, motile gram-negative bacilli may penetrate the intestinal blockade, leading to bacteraemia and focal metastatic infections, such as endovascular infection and osteomyelitis, especially in elderly patients with multiple comorbidities and impaired immunity.¹⁰ The history of hemicolectomy in the current patient may have also promoted recolonization of the offending bacteria from the intestine to the spine via the blood stream.¹⁰

Multidrug resistance is a serious and increasing problem as it threatens the efficacy of current antibiotic therapies in cases of life-threatening *Salmonella* infections.¹¹ Ampicillin, chloramphenicol and trimethoprim/sulfamethoxazole, which are first-line antimicrobial agents for *Salmonella* infection, are no longer considered in the initial treatment.¹² Not surprisingly, the culture

from the current patient's blood sample showed resistance to all of these first-line antibiotics and even resistance to the initial broad-spectrum empirical antibiotic. Although the antibiotic was promptly changed to an effective antibiotic, the infection was still out of control. Thus, surgical intervention to reduce bacterial load was indicated.

Considering the very high failure rate (up to 75%), increased risk of long-term paralysis (22%) and mortality risk (3%–25%) with conservative treatment for SEA, early surgical intervention within 36–72 h from the onset of neurological deficits has a significantly better prognosis.^{4,13} However, for an extensive SEA involving multiple spinal segments, a large surgical exposure and massive soft tissue dissection are required to accomplish multi-level laminotomy or long-segment laminectomy. Spinal instrumentation and fusion are necessary to maintain segmental stability. Sometimes, additional anterior surgeries may be required for radical debridement and reconstruction. A large amount of blood loss, extensive soft tissue damage and long operation time can burden older and fragile patients that are already in critically life-threatening sepsis. Considering the drawbacks of the traditional open surgery mentioned above and the risks of general anaesthesia for a fragile old woman, the patient's family declined the surgical treatment. That decision resulted in the extension of the SEA and deterioration of her clinical conditions.

Minimally-invasive spine surgery has undergone marked improvement and has become more feasible and popular in the past two decades.¹⁴ The advantages of minimally-invasive approaches include small surgical wounds, minimal blood loss, minimal soft tissue injury, less facet joint destruction, less approach-related

complications and rapid recovery.¹⁴ Based on the accumulated evidence in the literature, endoscopic spine surgery has demonstrated efficacy in managing various infectious diseases of the thoracolumbar spine.^{14–17} Early and late complications associated with spinal instrumentation, spinal fusion and anterior spine surgery can also be avoided.¹⁵ A previous study reported the successful treatment of 34 patients with spondylodiscitis, epidural abscess and psoas muscle abscess using a percutaneous endoscopic technique.¹⁶ Many of the patients were immunocompromised due to HIV infection.¹⁶ The authors recommended an early endoscopic biopsy, debridement, irrigation and drainage as the first-line treatment to obtain more tissue samples for histopathological examination and bacterial culture and to avoid late deformity resulting from bony destruction.¹⁶

Unilateral biportal endoscopic is a novel endoscopic technique that was developed to address various spinal conditions. In addition to its minimal invasiveness, the UBE technique has several advantages over other endoscopic techniques. This technique provides a magnified endoscopic surgical field, free handling of instruments with two hands and ergonomic settings for the operating surgeon. UBE has been used for a wide range of degenerative spine diseases, such as disc herniation and spinal canal stenosis, with high success rates.^{9,18}

The UBE technique is an excellent alternative surgical option for SEA. A previous study recommended early surgical intervention for patients with neurological deficits.¹⁷ In their series, the authors reported that radical debridement could be accomplished with minimal drilling of the lamina and facet joints.¹⁷ Segmental stability was well-preserved and no patient required spinal instrumentation or fusion.¹⁷ In the current case, the UBE technique was used

to drain the SEA via an L1–L2 laminotomy and to debride the discitis via another L4–L5 laminotomy. Instead of a large open incision for extensive multi-segment laminectomy, the current patient was successfully treated with four small surgical incisions, two small laminotomies and minimal soft tissue injury (Figure 3). With a clear surgical field, the drain tubes could be precisely inserted into the abscess and infected disc to ensure effective drainage. In addition, continuous saline irrigation during surgery is also beneficial for infection control.¹⁷ Therefore, it is important to obtain biopsy samples before irrigation. However, there were still some limitations for yielding pathogen cultures from the abscess and infected disc intraoperatively in the current patient because of the long duration of antibiotic treatment before the surgery.

Precautions for potential complications associated with general anaesthesia and preparation for postoperative care are equally important. The current patient

required mechanical ventilation support for 2 weeks and stayed in the intensive care unit for 24 days after the surgery. However, the results of the surgical treatment were encouraging. She regained consciousness within 2 days, her severe back pain dramatically improved within 2 weeks and her laboratory data quickly returned to the normal range with no recurrence of infection. With an extensive rehabilitation programme, which had been initiated as early as she was in the intensive care unit with emphasis on respiratory care, muscle strengthening exercises for changing position, stance and ambulation, her lower limb weakness gradually improved, and she could ambulate with a walker at 3 months after the surgery.

This case report had several limitations. First, it was a retrospective case review. Secondly, the treatment results of this rare case lack ability to generalize and to determine a cause–effect relationship.

In conclusion, surgical debridement and drainage should be performed as early as possible for SEA with neurological deficits,

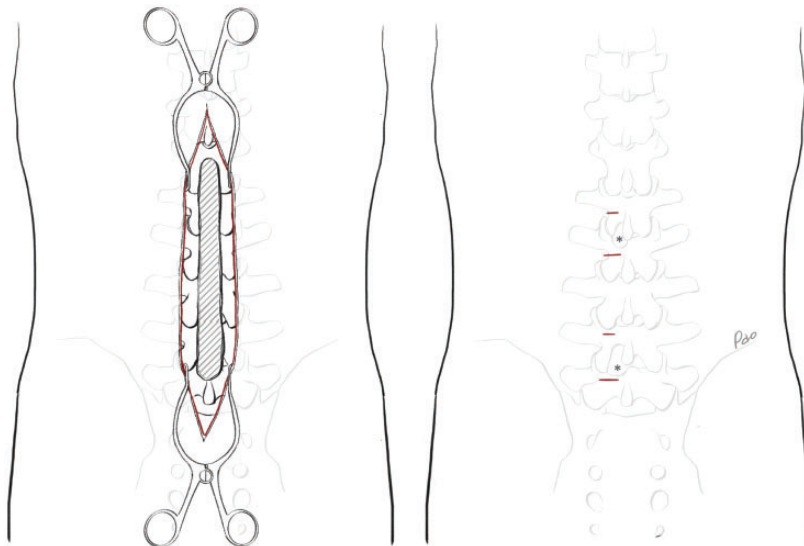


Figure 3. Schematic illustration showing the comparison between the multi-level laminectomy (slash area) with a large surgical incision in traditional open surgery and two small laminotomies (asterisks) with four small surgical incisions in unilateral biportal endoscopic surgery.

especially when the offending bacterium is a multidrug-resistant *Salmonella*. The UBE technique is an effective and ideal option to treat this type of infection with minimal surgery-related trauma. However, the patient's satisfactory recovery was attributed to good multidisciplinary teamwork including an infectious disease physician, orthopaedic spine surgeon, radiologist, pharmacist, physical therapist, respiratory therapist and nutritionist.

Author contributions

Ta-Li Hsu and Jwo-Luen Pao are the first co-authors and contributed equally to this work. Jwo-Luen Pao performed all surgeries and corrected the manuscript. Chia-Jui Yang reviewed the field of infectious disease. Ta-Li Hsu collected the data and prepared the manuscript. The authors read and approved the final manuscript.


Declaration of conflicting interest

The authors declare that there are no conflicts of interest.

Funding

The authors disclosed receipt of the following financial support for the research, authorship, and publication of this article: This study has received funding from Far Eastern Memorial Hospital, New Taipei City (no. FEMH-2022-C-047).

ORCID iDs

Ta-Li Hsu  <https://orcid.org/0000-0002-3662-4910>

Jwo-Luen Pao  <https://orcid.org/0000-0002-2000-5146>

References

- Arko L, Quach E, Nguyen V, et al. Medical and surgical management of spinal epidural abscess: a systematic review. *Neurosurg Focus* 2014; 37: E4.
- Han JW, Rim CD, Ahn SK, et al. Cervical Spinal epidural abscess due to *Salmonella* group D. *J Korean Neurosurg Soc* 2004; 36: 72–74.
- Reihsaus E, Waldbaur H and Seeling W. Spinal epidural abscess a meta-analysis of 915 patients. *Neurosurg Rev* 2000; 23: 175–204.
- Bond A and Manian FA. Spinal epidural abscess: a review with special emphasis on earlier diagnosis. *Biomed Res Int* 2016; 2016: 1614328.
- Darouiche RO. Spinal epidural abscess. *N Engl J Med* 2006; 355: 2012–2020.
- Khoo HW, Chua YY and Chen JL. *Salmonella typhi* vertebral osteomyelitis and epidural abscess. *Case Rep Orthop* 2016; 2016: 6798157.
- Demiraran Y, Dosoglu M, Yavuz C, et al. Spondylodiscitis and lumbar epidural abscess occurring after orthopedic epidural anesthesia: a case report. *Turk Neurosurg* 2006; 16: 208–211.
- Fuche FJ, Sow O, Simon R, et al. *Salmonella* Serogroup C: Current Status of Vaccines and Why They Are Needed. *Clin Vaccine Immunol* 2016; 23: 737–745.
- Pao JL, Lin SM, Chen WC, et al. Unilateral biportal endoscopic decompression for degenerative lumbar canal stenosis. *J Spine Surg* 2020; 6: 438–446.
- Ahmer BM and Gunn JS. Interaction of *Salmonella* spp. with the intestinal microbiota. *Front Microbiol* 2011; 2: 101.
- Olaitan AO, Dia NM, Gautret P, et al. Acquisition of extended-spectrum cephalosporin- and colistin-resistant *Salmonella enterica* subsp. *enterica* serotype Newport by pilgrims during Hajj. *Int J Antimicrob Agents* 2015; 45: 600–604.
- Pickering LK, Baker CJ and Kimberlin DW. *American Academy of Physicians Committee on Infectious Diseases*. Red book: report of the committee on infectious diseases. 29th ed. 2012.
- Epstein NE. Timing and prognosis of surgery for spinal epidural abscess: a review. *Surg Neurol Int* 2015; 6: S475–S486.
- Vaishnav AS, Othman YA, Virk SS, et al. Current state of minimally invasive spine surgery. *J Spine Surg* 2019; 5: S2–S10.
- Fu TS, Wang YC, Lin TY, et al. Comparison of percutaneous endoscopic surgery and traditional anterior open

- surgery for treating lumbar infectious spondylitis. *J Clin Med* 2019; 8: 1356.
16. Yu CH. Full-endoscopic debridement and drainage treating spine infection and psoas muscle abscess. *J Spine Surg* 2020; 6: 415–423.
 17. Kang T, Park SY, Lee SH, et al. Spinal epidural abscess successfully treated with biportal endoscopic spinal surgery. *Medicine (Baltimore)* 2019; 98: e18231.
 18. Kim N and Jung SB. Percutaneous unilateral biportal endoscopic spine surgery using a 30-degree arthroscope in patients with severe lumbar spinal stenosis. *Clin Spine Surg* 2019; 32: 324–329.