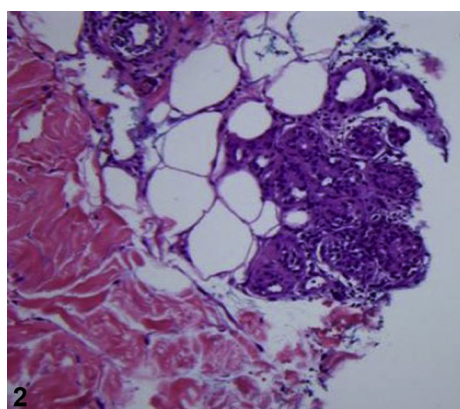
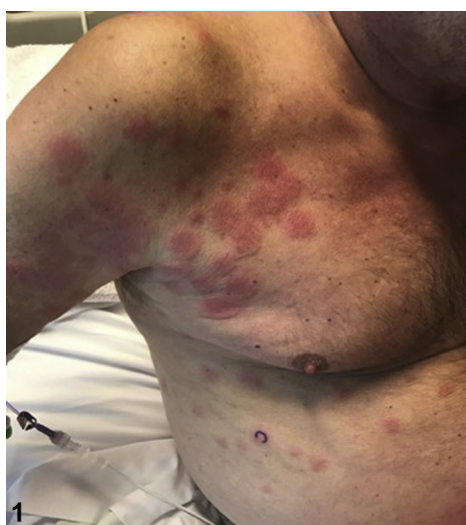

An eruption of erythematous plaques in a patient receiving chemotherapy



Christian Scheufele, DO, Rachel L. Giesey, DO, Robert M. Rothbaum, MD, Harib Ezaldein, MD, and Gregory R. Delost, DO
Cleveland, Ohio

Key words: acute myeloid leukemia (AML); cytarabine; neutrophilic dermatosis; neutrophilic eccrine hidradenitis (NEH).



CASE PRESENTATION

A 66-year-old man presented with unintentional weight loss, fatigue, easy bruising, and night sweats and was diagnosed with acute myeloid leukemia (AML). Induction chemotherapy with cytarabine and idarubicin was initiated. During his hospital stay, the patient developed pancytopenia and was started on acyclovir, micafungin, vancomycin, ciprofloxacin, and piperacillin-tazobactam. Eleven days after induction therapy, the patient experienced fever, chills, and a new skin eruption. Physical examination showed sharply demarcated, edematous and erythematous plaques with white surrounding halos involving the chest, back, abdomen, and lower extremities (Fig 1). A punch biopsy of a plaque was obtained (Fig 2).

Question 1: What is the most likely diagnosis?

A. Sweet syndrome

B. Drug reaction with eosinophilia and systemic symptoms (DRESS)

From the Department of Dermatology, University Hospitals Cleveland Medical Center, Cleveland.

Funding sources: None.

Conflicts of interest: None disclosed.

Correspondence to: Gregory R. Delost, DO, Department of Dermatology, UH Cleveland Medical Center, 11100 Euclid Ave, Lakeside 3500, Cleveland, OH 44106. E-mail: Gregory.Delost@UHhospitals.org, Gregorydelost@gmail.com.

JAAD Case Reports 2019;5:691-3.

2352-5126

© 2019 by the American Academy of Dermatology, Inc. Published by Elsevier, Inc. This is an open access article under the CC BY-NC-ND license (<http://creativecommons.org/licenses/by-nc-nd/4.0/>).

<https://doi.org/10.1016/j.jidcr.2019.06.005>

- C. Neutrophilic eccrine hidradenitis (NEH)
- D. Urticarial drug eruption
- E. Mycosis fungoides (MF)

Answers:

A. Sweet syndrome — Incorrect. Although Sweet syndrome is a neutrophilic dermatosis often associated with hematologic malignancies such as AML, it does not completely correlate with the involvement of the eccrine glands on histopathology.

B. DRESS — Incorrect. DRESS occurs 2 to 6 weeks after the administration of the offending agent and can resemble a morbilliform drug eruption, often involving greater than 50% body surface area. Leukocytosis with eosinophilia can be found on blood work. There is perivascular lymphocytic infiltrate on histology with eosinophils variably present.

C. NEH — Correct. NEH can occur in patients with malignancies such as AML in combination with certain chemotherapy agents, most commonly cytarabine. Erythematous and edematous plaques progress within 1 to 2 weeks of starting the offending agent and spontaneously resolve 1 to 2 weeks after cessation.¹⁻³

D. Urticarial drug eruption — Incorrect. This patient did not have the hallmark symptoms of rapid onset (due to the immunoglobulin E-mediated type I hypersensitivity), intensely pruritic plaques, or angioedema after administration of the offending agent.

E. MF — Incorrect. Although MF can present with a variety of morphologies, this morphology is not classic. It usually presents as scaly, thin, wrinkled patches in a bathing suit distribution. The histology also did not show any of the hallmark signs of MF such as Pautrier microabscesses, haloed lymphocytes, or hyperconvoluted intraepidermal lymphocytes.

Question 2: If this patient requires further chemotherapy, what is a potential treatment strategy to mitigate new lesions?

- A. Discontinue cytarabine
- B. Start low-dose methotrexate
- C. Avoid piperacillin-tazobactam
- D. Start dapsone before chemotherapy
- E. Start an oral retinoid

Answers:

A. Discontinue cytarabine — Incorrect. Although NEH will resolve spontaneously within 1 to 2 weeks of stopping chemotherapy, there is no indication to stop treatment for AML.^{1,4}

B. Start low-dose methotrexate — Incorrect. Methotrexate inhibits DNA synthesis by blocking the reduction of folate. Although methotrexate is useful in a variety of dermatologic diseases, its mechanism of action does not address the neutrophil-driven pathophysiology of NEH, nor has it ever been reported to be helpful in this condition.

C. Avoid piperacillin-tazobactam — Incorrect. This is unlikely to be a drug eruption because of the morphology of the eruption in this patient and the shorter time course between the administration of the antibiotic and the eruption than would be expected.

D. Start dapsone before chemotherapy — Correct. Dapsone is used in the treatment of many neutrophilic dermatoses because of its mechanism of action inhibiting myeloperoxidase and reducing the oxidant and free radical damage caused by neutrophils. There is descriptive evidence that dapsone can be used to suppress the outbreak of NEH in patients who require future chemotherapy cycles. However, the risks and benefits should be weighed before prescribing dapsone for a patient currently on chemotherapy because it can cause hemolysis and agranulocytosis.⁴

E. Start an oral retinoid — Incorrect. Oral retinoids can be used for treatment of advanced MF and recalcitrant Sweet syndrome. There is no evidence for using oral retinoids for prophylaxis in chemotherapy-induced NEH.

Question 3: What histopathologic findings best characterize this condition?

- A. Dermal neutrophilic invasion with leukocytoclasia without dermal edema or vessel wall necrosis
- B. Follicular plugging with a dense perifollicular mixed inflammatory infiltrate
- C. Neutrophils infiltrating the eccrine gland secretory coils and vacuolar degeneration of secretory cells
- D. Dense neutrophilic infiltrate of the dermis with sparing of the epidermis and leukocytoclasia
- E. Haloed, atypical lymphocytes within the epidermis, forming occasional intraepidermal aggregates

Answers:

A. Dermal neutrophilic invasion with leukocytoclasia without dermal edema or vessel wall necrosis — Incorrect. Leukocytoclasia without fibrinoid necrosis of vessel walls can be seen in neutrophilic urticarial dermatosis and would not be the expected finding in NEH. The eccrine glands are typically spared in this condition.

B. Follicular plugging with a dense perifollicular mixed inflammatory infiltrate — Incorrect. This finding is more characteristic of hidradenitis suppurativa and other disorders of follicular occlusion.

C. Neutrophils infiltrating the eccrine gland secretory coils and vacuolar degeneration of secretory cells — Correct. The diagnosis of NEH is histologic and is defined by a neutrophilic infiltrate in and around the eccrine glands with concurrent necrosis of the secretory cells, as seen in Fig 2.⁵

D. Dense neutrophilic infiltrate of the dermis with sparing of the epidermis and leukocytoclasia — Incorrect. Sweet syndrome has leukocytoclasia without evidence of vasculitis and a dermal neutrophilic infiltrate that spares the epidermis. The eccrine glands are typically spared.

E. Haloed, atypical lymphocytes within the epidermis, forming occasional intraepidermal

aggregates — Incorrect. The aggregates of haloed, atypical lymphocytes, or Pautrier microabscesses, are relatively uncommon in MF but would strongly suggest this diagnosis.

Abbreviations used:

AML: acute myeloid leukemia

DRESS: drug reaction with eosinophilia and systemic symptoms

MF: mycosis fungoides

NEH: neutrophilic eccrine hidradenitis

REFERENCES

1. Harrist TJ, Fine JD, Berman RS, Murphy GF, Mihm MC Jr. Neutrophilic eccrine hidradenitis. A distinctive type of neutrophilic dermatosis associated with myelogenous leukemia and chemotherapy. *Arch Dermatol.* 1982;118(4):263-266.
2. Smoller BR, Horn TD. Chemotherapy-induced drug eruptions. In: *Dermatopathology in Systemic Disease.* Oxford, UK: Oxford University Press; 2001.
3. Thorisdottir K, Tomecki KJ, Bergfeld WF, Andresen SW. Neutrophilic eccrine hidradenitis. *J Am Acad Dermatol.* 1993;28(5 Pt 1):775-777.
4. Shear NH, Knowles SR, Shapiro L, Poldre P. Dapsone in prevention of recurrent neutrophilic eccrine hidradenitis. *J Am Acad Dermatol.* 1996;35(5 Pt 2):819-822.
5. Nelson CA, Stephen S, Ashchyan HJ, James WD, Micheletti RG, Rosenbach M. Neutrophilic dermatoses: pathogenesis, Sweet syndrome, neutrophilic eccrine hidradenitis, and Behçet disease. *J Am Acad Dermatol.* 2018;79(6):987-1006.