


# A retrospective assessment of the clinical efficacy of different internal fixation methods in the treatment of distal fibula fractures in the elderly

Wenhai Zhao, MD<sup>a,\*</sup>, Qian Wang, PhD<sup>b</sup>, Zhenhai Cui, PhD<sup>a</sup>, Zhenshuang Yue, MD<sup>c</sup>, Zhongqing Hu, MD<sup>c</sup>, Linru Zeng, MD<sup>c</sup>, Dawei Xin, MD<sup>c</sup>, Yanghua Tang, MD<sup>c</sup>, Dezhi Tang, PhD<sup>b</sup> 

## Abstract

An ankle fracture is a fracture of the distal tibia or fibula that forms the ankle joint, usually associated with ligament and soft tissue injury, and is a common type of lower limb fracture and one of the most common types of fracture in the elderly. Although ankle fractures are one of the most common injuries seen by orthopedic trauma surgeons, there is no uniform protocol for the diagnosis and treatment of ankle fractures in the elderly, and there are many controversial indications for surgery. The aim of this study is to assess the clinical efficacy of different internal fixation methods in the treatment of distal fibular fractures in the elderly, in an effort to improve the rational selection and application of clinical acts. A retrospective analysis was performed on 68 cases of patients who suffered an ankle fracture and were treated with different internal fixation methods according to the fracture types and individual differences in distal fibula fractures. The postoperative therapeutic effect assessment was performed in terms of clinical examination, imaging evaluation, and AOFAS ankle-hind foot function scoring. There was no unhealed bone, ankle instability and loose/fractured internal fixation. Fracture healing time was 2.7 to 4.0 months (average 3.2 months). AOFAS score was  $88.3 \pm 6.2$ , of which, 34 excellent cases, 30 good cases, and 4 fair cases. Ankle activity dorsiflexion  $6^\circ \sim 18^\circ$ , average  $15^\circ$ ; plantar flexion  $26^\circ \sim 47^\circ$ , average  $37^\circ$ . A good clinical efficacy could be achieved from the most appropriate individualized internal fixation for distal fibula fractures of elderly patients.

**Abbreviations:** VAS = visual analogue scale.

**Keywords:** ankle fractures, distal fibula fractures, elderly patients, individualization, internal fixation

## 1. Introduction

An ankle fracture is a fracture of the distal tibia or fibula that forms the ankle joint, usually associated with ligament and soft tissue injury, and is a common type of lower limb fracture. With increasing participation in sport and an aging population, the occurrence rate of ankle fracture in older people has also been on an upward trajectory year after year.<sup>[1]</sup> According to a national survey on the incidence of ankle fractures in Denmark, the incidence of ankle fractures is 168.7 per 100,000 person-years and the most common type of fracture is the external ankle.<sup>[2]</sup> A Swedish epidemiological survey on ankle fractures showed that the annual incidence of ankle

fractures in the country was 71 per 100,000 person-years and that the increase in the incidence of fractures was mainly due to an increase in the number of elderly women.<sup>[3]</sup> Besides, the elderly are more prone to complications such as delayed healing, non-healing and even traumatic arthritis due to their poor physical condition and poor surgical treatment protocols.<sup>[4-7]</sup> This situation seriously affects the functional status and quality of life of elderly patients and increases the medical burden on society. However, there is no uniform protocol for the diagnosis and treatment of ankle fractures in the elderly, and there are many controversial indications for surgery. Therefore, this study evaluates the clinical efficacy of different internal fixation methods in the treatment of distal fibula fractures in the

WZ, QW, and ZC contributed equally to this work.

This study was sponsored by the Health Project Grant from the Science and Technology Department of Hangzhou City (2015B24) and The Xin-Ling Scholar Project of Shanghai University of Traditional Chinese Medicine (202023).

Informed consent was obtained from all individual participants included in the study.

Patients signed informed consent regarding publishing their data and photographs.

The authors have no conflicts of interest to disclose.

The datasets generated during and/or analyzed during the current study are available from the corresponding author on reasonable request.

This study has been approved by the Ethics Committee of Xiao Shan TCM Hospital.

<sup>a</sup> Department of Orthopedics, Affiliated Hospital to Changchun University of Chinese Medicine, Changchun, Jilin, China, <sup>b</sup> Department of Orthopedics, Longhua Hospital, Shanghai University of Traditional Chinese Medicine,

Shanghai, China, <sup>c</sup> Department of Orthopedics, Xiao Shan TCM Hospital, Hangzhou, Zhejiang, China.

\*Correspondence: Wenhai Zhao, Department of Orthopedics, Affiliated Hospital to Changchun University of Chinese Medicine, 130117 Changchun, Jilin, China (e-mail: 13301433@qq.com).

Copyright © 2022 the Author(s). Published by Wolters Kluwer Health, Inc. This is an open-access article distributed under the terms of the Creative Commons Attribution-Non Commercial License 4.0 (CCBY-NC), where it is permissible to download, share, remix, transform, and buildup the work provided it is properly cited. The work cannot be used commercially without permission from the journal.

How to cite this article: Zhao W, Wang Q, Cui Z, Yue Z, Hu Z, Zeng L, Xin D, Tang Y, Tang D. A retrospective assessment of the clinical efficacy of different internal fixation methods in the treatment of distal fibula fractures in the elderly. *Medicine* 2022;101:43(e30973).

Received: 26 March 2022 / Received in final form: 2 September 2022 / Accepted: 6 September 2022

<http://dx.doi.org/10.1097/MD.000000000030973>

elderly in order to improve the rational selection and application of clinical protocols.

## 2. Material and Method

### 2.1. Study design

This study has been approved by the Ethics Board of Xiao Shan TCM Hospital. This study is a retrospective research of patients who underwent individualized internal fixation for treatment of the distal fibula fractures of the elderly patients between May 2012 and April 2015 in our orthopedics department.

### 2.2. Inclusion and exclusion criteria

Inclusion criteria: age >60 years; distal fibula fracture revealed by imaging examination, which may complicate fracture or ligament injury in other parts of the ankle; tolerable to operative treatment.

Exclusion criteria: pathological fractures revealed by X-ray other than osteoporosis; previous ankle fracture or operative history, ankle deformity and ankle osteoarthritis; accompanied with the fracture in other parts of extremity; accompanied with a foot fracture and joint dislocation; open fractures.

### 2.3. General information

68 cases of patients who suffered ankle fractures and were subject to operative treatment in our hospital were selected, 37 males and 31 females; aged between 62 and 81 years, average 69.2 years. Causes of injury: 33 cases of sprain, 20 cases of traffic injury, and 15 cases of falling injury. Injury part: 32 cases in the left ankle, and 36 cases in the right ankle. Danis-Weber classification<sup>[8]</sup>: 19 cases of Weber A type, wherein, 14 cases complicating medial malleolus fracture; 31 cases of Weber B type, wherein, 10 cases complicating medial malleolus fracture, 4 cases triangular ligament rupture, 6 cases posterior malleolus fracture, and 5 cases distal tibiofibular syndesmosis split; 18 cases of Weber C type, wherein, 15 cases complicating medial malleolus fracture, 3 cases triangular ligament rupture, 8 cases posterior malleolus fracture and 18 cases distal tibiofibular syndesmosis split. Lauge-Hansen classification<sup>[9]</sup>: 22 cases of supination external rotation type, 18 cases of pronation external rotation type, 19 cases of supination adduction type, 9 cases of pronation adduction type. All were closed injuries, without complicated blood vessels or nerve injuries. 3 to 10 days from injury to operation, average 6.3 days. Complicated internal basic diseases: 13 cases of coronary heart disease, 38 cases of hypertension, 15 cases of diabetes, 5 cases of chronic bronchitis. At the same time, 21 cases were complicating two or above basic diseases.

### 2.4. Treatment methods

**2.4.1. Operative methods** The continuous epidural anesthesia was adopted in the operation. The patients were placed in the lateral decubitus position, and the incision was selected at the lateral or posterior lateral of the distal fibula. The distal fibula was fixed according to the fracture type, soft tissue conditions, bone characteristics and internal fixation features of the patients. Kirschner wire tension band fixation was selected for the avulsion fracture of the lateral malleolus. After the reduction of fracture, two Kirschner wires in the diameter of 1.0 to 1.2mm were taken and fixed vertically to fracture line, and then at the proximal end of the fracture, Kirschner wire in the diameter of 1.5mm was used to drill transversely. A steel wire in the diameter of 0.6mm was threaded through the bone hole and the Kirschner wire end, and the 8-shaped pressure fixation was performed. Kirschner wire parallel end

was cut off, and bending & counter-sunk head treatment was performed. Kirschner wire tension band fixation was performed on 7 patients in this group in total. For the transverse fracture of lateral malleolus, reduction was performed by towel clamp after the cleaning of fracture end, and 2 to 3 guide needles were fixed vertically to fracture line. The fracture reduction and the guide needle position were determined under the perspective of C-arm X-ray machine. When the length was satisfied, the hollow drill was taken to drill holes along the guide needle and the opening was expanded. 1 or 2 Herbert screw(s) (by Wright Company) in the diameter of 3.2mm with proper length was/were screwed in and the counter-sunk head at the end of parallel screw was performed. Herbert screw fixation was performed on 12 patients in this group in total. For oblique or spiral fractures at distal tibiofibular syndesmosis of the distal fibula, the anatomical distal fibula composite plate or anatomical distal fibula locking plate was selected after the reduction of fracture; and the anatomical locking plate was selected when the patient had significant osteoporosis. For oblique or spiral fractures above the distal tibiofibular syndesmosis, in most cases, the 1/3 tube plate, reconstruction plate, or anatomical distal fibula composite plate could be selected as fixation method after the reduction of fracture. However, in case of underweight patient, lack of thick soft tissue coverage on distal fibula or poor local soft tissue conditions, the thinner 1/3 tube plate or anatomical distal fibula composite plate was preferred. If the patient had significant osteoporosis, the locking plate was also preferred. Among the patients in this group, there were 5 cases of 1/3 tube fixation, 6 cases of reconstruction plate fixation, 17 cases of anatomical distal fibula composite plate fixation, 21 cases of anatomical distal fibula locking plate fixation. After the fractures of the lateral malleolus and the posterior malleolus are treated, they are changed into a supine position and fixed internal malleolus fracture. Appropriate internal fixation was selected for the fracture block at posterior malleolus or medial malleolus in accordance with the type of fracture.

**2.4.2. Postoperative treatment** The injured limb was elevated for placement, and the treatment to prevent infection, dehydration, and swelling was performed after the operation. On the second day after operation, if the pain was relieved, the functional exercise of flexion and extension activities for lower extremity joints could be performed. During 6 to 8 weeks after operation, the weight-bearing walk on the ground could be performed under the protection of walking brace (e.g., walking stick).

**2.4.3. Efficacy observation indices and methods.** Follow-up reexamination was performed at 1, 3, 6, and 12 months after operation, and the fracture healing and internal fixation conditions were observed by imaging examination.

The AOFAS ankle-hind foot function scoring system<sup>[10]</sup> was used to assess from pain (40 points), function (50 points) and alignment (10 points) these three aspects, with a total score of 100 points. 90 to 100 points: excellent; 75 to 89 points: good; 50 to 74 points: fair; <50 points: poor. Visual analogue scale (VAS)<sup>[11]</sup> was used to assess the degree of pain when patient actively moved ankle joint, 0 point: no pain; 3 points or less: slight pain, tolerable; 4 to 6 points: patient suffered pain and sleep was affected, but it was still tolerable; 7 to 10 points: patient suffered gradually strong pain, the pain was intolerable, and the appetite and sleep were affected.

**2.4.4. Statistical analysis** Due to the retrospective nature of this study, the sample size was not calculated. The SPSS19.0 software was used in statistical processing, and the measurement data were expressed in the form of mean  $\pm$  standard deviation ( $\bar{x} \pm s$ ). The One-way ANOVA was used in the comparison of fracture healing time, last follow-up's AOFAS score, VAS score, and ankle activity among the patients from different internal

fixation groups. Comparison between the groups was made by analyzing data with post hoc method. Multiple comparison between the groups was performed using the Tukey method. When  $P < .05$ , the difference was considered of statistical significance.

### 3. Results

This study included 68 patients who underwent individualized internal fixation for treatment of distal fibula fractures. Among the patients in this group, there were 12 cases of Herbert screw fixation, 7 cases of Kirschner wire tension band fixation, 5 cases of 1/3 tube plate fixation, 6 cases of reconstruction plate fixation, 17 cases of anatomical distal fibula composite plate fixation, 21 cases of anatomical distal fibula locking plate fixation. All patients were followed up for 12 to 26 months with an average of 17.7 months after the operation. Surgical incisions for different internal fixation groups were healed in the first intention, without infection and skin necrosis. There was no unhealed bone, ankle instability and loose/fractured fixation in all groups. Fracture healing time in different internal fixation groups was 2.7 to 4.0 months (average 3.2 months). In the last follow-up, AOFAS score was  $88.3 \pm 6.2$ , of which, 34 excellent cases, 30 good cases and 4 fair cases. Ankle activity dorsiflexion  $6^\circ \sim 18^\circ$ , average  $15^\circ$ ; plantar flexion  $26^\circ \sim 47^\circ$ , average  $37^\circ$ . There was no statistical significance on the difference in AOFAS score, VAS score and ankle activity between patients from different internal fixation groups ( $P > .05$ ), but there was statistical significance on the difference in fracture healing time between the Herbert screw and 1/3 tube plate groups ( $P < .05$ ). See Table 1. Typical cases were shown in Figures 1–3.

### 4. Discussion

#### 4.1. The selection of distal fibula internal fixation method for elderly patients with an ankle fracture

The distal fibula was the lateral structure of the ankle mortise, which was mainly to prevent lateral displacement of the talus, so the distal fibula was important for maintaining the stability of the ankle joint. If the fracture occurred at the distal fibula, the ankle mortise would broaden, as a result, the function of the fibula to the limit the lateral displacement of the talus was lost,<sup>[12]</sup> and improper treatment could result in instable ankle mortise and traumatic arthritis.<sup>[13]</sup> Therefore, the restoration of the normal anatomical mechanism and force line of distal fibula as well as a reasonable, effective and strong internal fixation

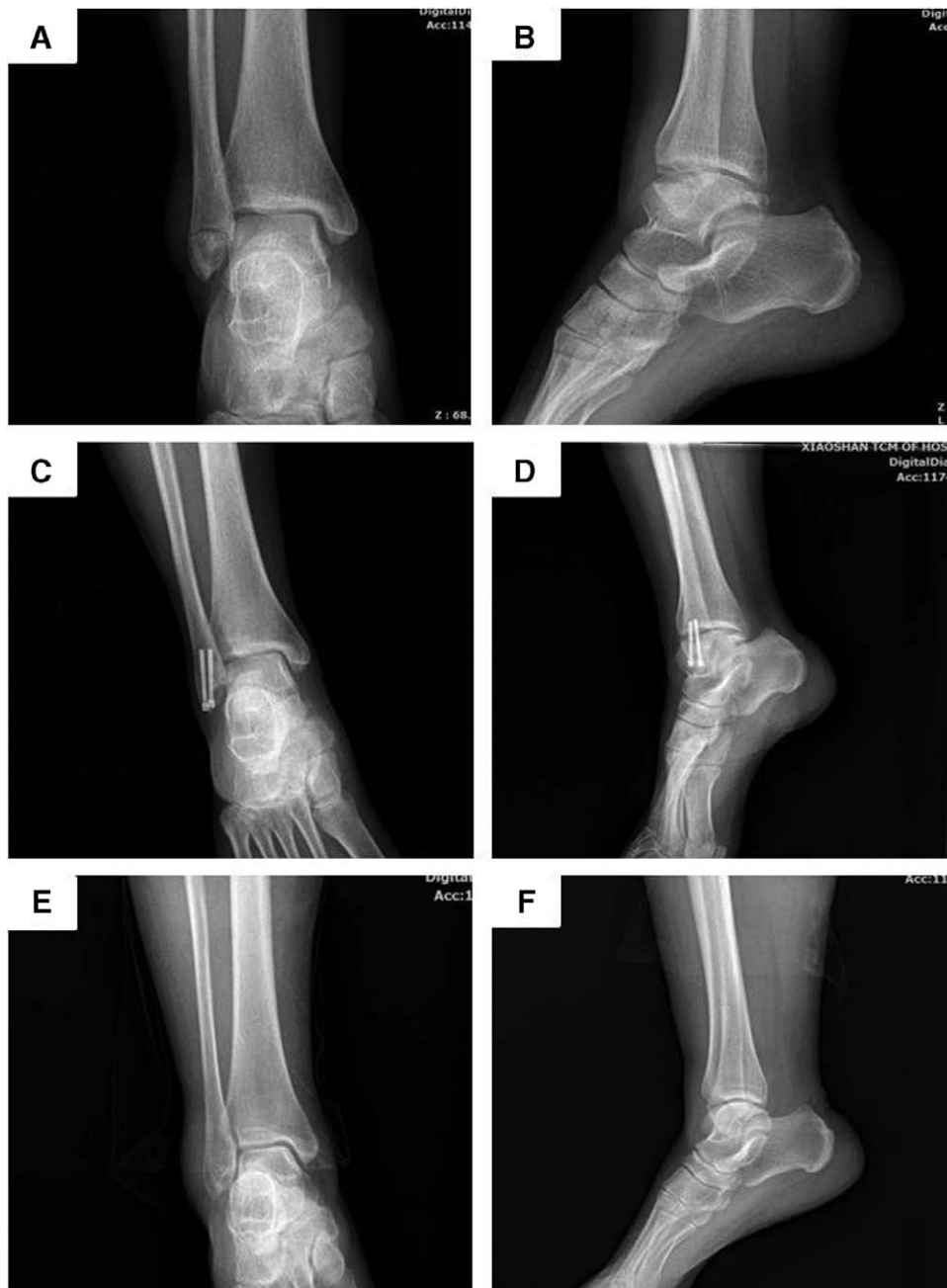were the main principle in treating the distal fibula in ankle fracture operation. At present, many internal fixation methods were available for the fracture of distal fibula,<sup>[10,14]</sup> and there was no uniform selection standard for internal fixation. Due to the poor skin elasticity and blood circulation in skin soft tissue, the elderly patients most suffered osteoporosis to a different extent, so in the process of ankle operation, the complications at the soft tissues around the incision and the loosening or break of internal fixation were common. Hence, in the selection of internal fixation, not only the good stability should be considered, but also the attention shall be paid to the interference of internal fixation materials on the skin soft tissues. Given the above clinical features, we believed that the fixation method for distal fibula fracture shall be individually selected on the basis of type of fracture, soft tissue conditions, bone characteristics and internal fixation features.

The fracture blocks were usually smaller in avulsion fractures of the lateral malleolus, which was difficult to fix the screws, so we preferred the Kirschner wire tension band fixation. However, the fracture blocks were relatively large and complete in transverse fracture of the lateral malleolus. Although the Kirschner wire tension band was also a choice, we still preferred Herbert screw fixation. It was mainly because that Herbert screw fixation had the advantages of a small incision, simple operation, less periosteum stripping, and bi-directional pressure at fixation ends,<sup>[15]</sup> and in addition, the counter-sunk head treatment was available, which could effectively avoid the interference of screw end on the soft tissue,<sup>[16]</sup> and could greatly reduce the complications of soft tissue, so Herbert screw fixation was particularly suitable when local soft tissue conditions were poor. A total of 12 patients in this group selected Herbert screw fixation. For fibula oblique or spiral fractures at the distal tibiofibular syndesmosis, if the bone was relatively good, the thinner anatomical distal fibula composite plate fixation was our major choice; however, if the patient had significant osteoporosis, it was recommended to select anatomical locking plate fixation, because the distal part of anatomical distal fibula locking plate was thinner and had good adhesion, which could reduce the interference on soft tissue, moreover, several screws could be locked and fixed from different angles, so the fixation strength was more reliable. Among the patients with such type of injury in this group, 13 patients selected anatomical distal fibula composite plate fixation, and 18 patients selected anatomical distal fibula locking plate fixation. For the fibula oblique or spiral fractures above the distal tibiofibular syndesmosis, the fracture line was relatively high, so in most cases, 1/3 tube plate, reconstruction plate and anatomical distal fibula composite plate could be used in principle, however, in our opinion, the fixation strength of the reconstruction

**Table 1**  
Comparison of effects among patients from different internal fixation groups.

Internal fixation methods	Number of cases	Bony healing time (mo)	AOFAS score (points)	VAS score (points)	Ankle dorsiflexion (°)	Ankle plantar flexion (°)
Herbert screw	12	2.92 ± 0.19	90.83 ± 3.66	2.04 ± 0.46	13.50 ± 3.50	34.50 ± 6.58
Kirschner wire tension band	7	3.00 ± 0.21	89.71 ± 4.15	2.11 ± 0.39	12.14 ± 4.74	36.71 ± 7.29
1/3 Tube plate	5	3.46 ± 0.37	90.40 ± 5.50	1.60 ± 0.34	13.40 ± 4.03	38.00 ± 7.68
Reconstruction plate	6	3.32 ± 0.31	90.50 ± 4.03	1.71 ± 0.53	12.83 ± 5.11	37.16 ± 8.13
Anatomical composite plate	17	3.15 ± 0.36	87.64 ± 6.67	1.98 ± 0.41	12.41 ± 3.90	33.76 ± 5.87
Anatomical locking plate	21	3.19 ± 0.29	85.62 ± 7.49	2.00 ± 0.46	12.80 ± 3.75	33.09 ± 5.52
F value	-	3.242	1.625	1.32	0.231	0.924
P value	-	.012	.617	.267	.948	.472

VAS = visual analogue scale.



**Figure 1.** Female, 62-years-old, right ankle fracture caused by sprain (type A of Weber classification). (1a, 1b) Preoperative AP and lateral X-ray films showed lateral malleolus transverse fracture, and the fracture block was complete. (1c, 1d) Postoperative AP and lateral X-ray at 4th month after operation showed the distal fibula fracture was fixed with two Herbert screws. (1e, 1f) At the 12th month after operation, the internal fixation device was removed. AP and lateral X-ray films showed fracture was healed and the function of ankle was well.

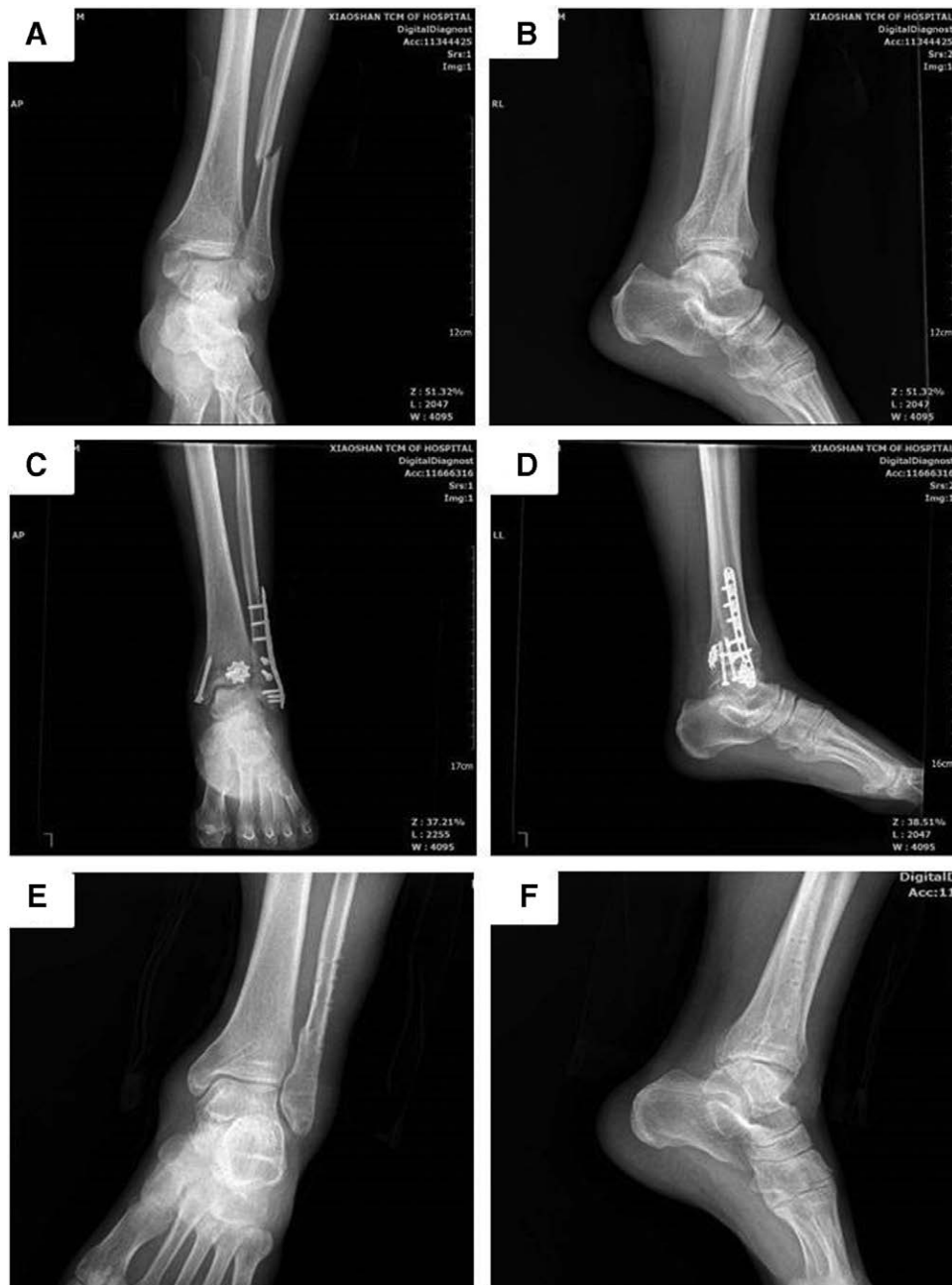plate and anatomical distal fibula composite plate was higher than that of 1/3 tube plate, so reconstruction plate and anatomical distal fibula composite plate were preferred; but in case of underweight patient, lack of thick soft tissue coverage on distal fibula or poor local soft tissue conditions, the thinner 1/3 tube plate or anatomical distal fibula composite plate was more suitable so as to reduce the interference of implant on the soft tissue. If the patient also had significant osteoporosis, the locking plate fixation was preferred. In this study, among the patients with such type of injury in this group in the study, 5 patients selected the 1/3 tube plate, 6 patients selected the reconstruction plate, 4 patients selected the anatomical distal fibula composite plate, and 3 patients selected the anatomical distal fibula locking plate.

In this study, there was no statistical significance on the difference in the comparison of AOFAS score, VAS score and ankle activity between patients from different internal fixation groups, but there was statistical significance on the difference in the comparison of fracture healing time, which was mainly caused by the difference on fracture parts.

#### 4.2. Focus on the role of ankle arthroscopy in the treatment of ankle fractures

Ankle fractures are a common type of lower limb fracture and anatomical reduction and strong internal fixation are still one of the main principles of fracture fixation to be followed.<sup>[17]</sup>





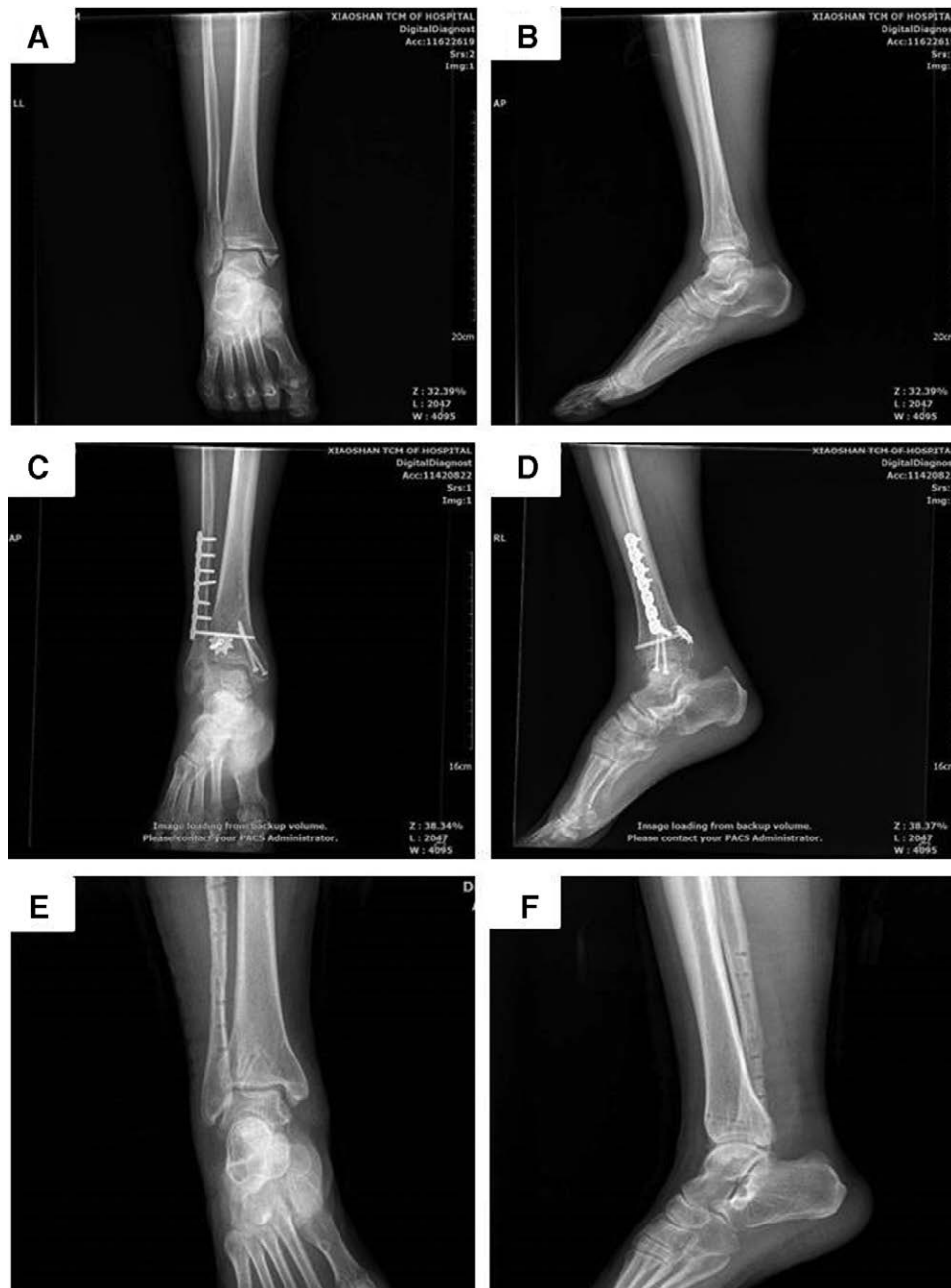**Figure 2.** Male, 66-years-old, left ankle fracture caused by sprain (type B of Weber classification). (2a, 2b) Preoperative AP and lateral X-ray films showed the distal fibula oblique fracture in distal tibiofibular syndesmosis, and accompanied with osteoporosis. (2c, 2d) Postoperative AP and lateral X-ray at the 1st month after operation showed the distal fibula fracture was fixed with an anatomical locking plate. (2e, 2f) At the 14th month after the operation, the internal fixation device was removed. AP and lateral X-ray films showed fracture was healed and the function of the ankle was well.

However, a large number of patients with acute ankle fractures still do not achieve the desired clinical outcome after fixation. The reason for this is not only due to poor fracture repositioning itself, but also due to unresolved ligament and cartilage lesions within the ankle joint. Ankle arthroscopy is showing great promise as a tool for diagnosing ligament ruptures and cartilage injuries within the ankle joint and guiding fracture reduction. Kwok Bill Chan et al suggest that ankle arthroscopy is useful in detecting and evaluating injured tibiofibular joint ligaments and intra-articular fractures, as well as detecting their repositioning.<sup>[18]</sup> Beat Hintermann et al found more anatomical abnormalities and structural changes than expected in patients with recurrent ankle sprains, including cartilage and medial and lateral ligament lesions, using ankle

arthroscopy.<sup>[19]</sup> Therefore, ankle arthroscopy is one of the tools we need to think about when treating acute complex ankle fractures.

**4.3. Don't ignore conservative treatment**

Although we emphasize the importance of individualized internal fixation surgical options in the treatment of distal fibular fractures depending on the patient's condition, we also place more emphasis on conservative treatment of fibular fractures. In principle, we recommend conservative treatment such as splints casts or functional braces for patients with stable fractures without displacement or with slight displacement. Better clinical feedback has been achieved in these clinics.



**Figure 3.** Male, 63-years-old, right ankle fracture caused by traffic accident (type C of Weber classification). (3a, 3b) Preoperative AP and lateral X-ray films showed the spiral fracture of the fibula above the distal tibiofibular syndesmosis. (3c, 3d) Postoperative AP and lateral X-ray at 2nd month after operation showed the distal fibula fracture was fixed with reconstruction plate. (3e, 3f) At the 15th month after the operation, the internal fixation device was removed. AP and lateral X-ray films showed fracture was healed, there was no distal tibiofibular joint split, and the function of ankle was well.

#### 4.4. Treatment notes

First, before the operation, the operative tolerance degree of the patient shall be comprehensively assessed on the basis of previous physical conditions, blood glucose and blood pressure, liver and kidney functions, water and electrolyte balance, arterial blood gas analysis and cardiopulmonary function, and the basic diseases shall be actively treated so as to reduce the risk of operation. Therefore, before the operation, the type of fracture, soft tissue conditions, bone and internal fixation characteristics shall be fully understood for a reasonable and correct choice of internal fixation.

Second, during operation, attention shall be paid to the protection of soft tissue, and the over-stretching, over-interference or excessive stripping of periosteum was not allowed so as to reduce the occurrence rate of soft-tissue complications and unhealed bone.

Third, in the event of Herbert screw fixation, after the reduction of fracture, two or above guide needles were fixed first, and then the screws at appropriate length shall be screwed in respectively so as to avoid the rotation of the fracture blocks. In addition, the attention shall also be paid to the counter-sunk head treatment for the screw end so as to reduce the interference on soft tissue. The screw front threads shall be all over the fracture line.

Final, in case of posterior placement of distal fibula plate, its position shall not be too low, and the integrity of the fibula myolemma tube shall be ensured as much as possible in order to avoid the potential wear of the plate or screws on fibula longus as well as to prevent the occurrence of peroneal tendon irritation.

## 5. Conclusion

In summary, while treating for ankle fractures in the elderly, to achieve better surgical results and avoid complications, such as soft tissue complications, internal fixation loosening, etc, the fixation of distal fibular should be based on fracture types and patient's individual differences (e.g., osteoporosis, skin, and soft tissue conditions) in the selection of internal fixation methods.

In view of the above findings, we believed that, in the operative treatment of elderly patients with an ankle fracture, a good clinical efficacy could be achieved from the individualized internal fixation for distal fibula fractures. However, there were also inadequacies in this study, such as small sample size, statistical bias and short follow-up time. In the future, we will take a randomized controlled trial to further confirm its effect.

## Acknowledgments

We thank the team for their cooperation.

## Author contributions

Conceived and designed the study: Wenhai Zhao, Yanghua Tang and Dezhi Tang. Data acquisition and interpretation of the article: Qian Wang. Analyzed the data: Yanghua Tang, Qian Wang, Zhenshuang Yue, Dawei Xin. Wrote the manuscript: Qian Wang, and Zhenhai Cui. Revised the manuscript: Dezhi Tang, Zhongqing Hu. Contributed funds/materials/analysis tools: Dezhi Tang, Linru Zeng, and Yanghua Tang. All the authors read and approved the final manuscript.

**Data curation:** Zhenshuang Yue, Zhongqing Hu, Dawei Xin.

**Formal analysis:** Zhenhai Cui, Dezhi Tang.

**Funding acquisition:** Yanghua Tang, Linru Zeng.

**Investigation:** Wenhai Zhao, Linru Zeng.

**Methodology:** Zhenhai Cui.

**Project administration:** Wenhai Zhao.

**Supervision:** Dezhi Tang.

**Writing – original draft:** Qian Wang, Zhenhai Cui.

**Writing – review & editing:** Yanghua Tang, Zhongqing Hu, Dezhi Tang.

## References

- [1] Srinath A, Matuszewski PE, Kalbac T. Geriatric ankle fracture: robust fixation versus hindfoot nail. *J Orthop Trauma* 2021;35(Suppl 5): S41–4.
- [2] Elsoe R, Ostgaard SE, Larsen P. Population-based epidemiology of 9767 ankle fractures. *Foot Ankle Surg* 2018; 24:34–9.
- [3] Thur CK, Edgren G, Jansson KÅ, et al. Epidemiology of adult ankle fractures in Sweden between 1987 and 2004: a population-based study of 91,410 Swedish inpatients. *Acta Orthop* 2012; 83:276–81.
- [4] Pearce O, Al-Hourani K, Kelly M. Ankle fractures in the elderly: current concepts. *Injury* 2020; 51:2740–7.
- [5] Gee CW, Dahal L, Rogers BA, et al. Ankle fractures in the elderly: an overlooked burden. *Br J Hosp Med* 2015; 76:564–9.
- [6] Konopitski A, Boniello AJ, Shah M, et al. Techniques and considerations for the operative treatment of ankle fractures in the elderly. *J Bone Joint Surg Am* 2019; 101:85–94.
- [7] Hsu RY, Ramirez JM, Blankenhorn BD. Surgical considerations for osteoporosis in ankle fracture fixation. *Orthop Clin North Am* 2019; 50:245–58.
- [8] Briet JP, Hietbrink F, Smeeing DP, et al. Ankle fracture classification: an innovative system for describing ankle fractures. *J Foot Ankle Surg* 2019; 58:492–6.
- [9] Boszczyk A, Fudalej M, Kwapisz S, et al. Ankle fracture - Correlation of Lauge-Hansen classification and patient reported fracture mechanism. *Forensic Sci Int* 2018; 282:94–100.
- [10] Knutsen AR, Sangiorgio SN, Liu C, et al. Distal fibula fracture fixation: biomechanical evaluation of three different fixation implants. *Foot Ankle Surg* 2016; 22:278–85.
- [11] Chiarotto A, Maxwell LJ, Ostelo RW, et al. Measurement properties of visual analogue scale, numeric rating scale, and pain severity subscale of the brief pain inventory in patients with low back pain: a systematic review. *J Pain* 2019; 20:245–63.
- [12] Lin CC, Lin KP, Huang CC, et al. Partially threaded headless screw may benefit adequate interfragmentary compression and reduced driving torque for small bone fixation. *J Orthop Surg* 2018; 26:2309499018760130.
- [13] Moss LK, Kim-Orden MH, Ravinsky R, et al. Implant failure rates and cost analysis of contoured locking versus conventional plate fixation of distal fibula fractures. *Orthopedics* 2017; 40:e1024–9.
- [14] Rodriguez EK, Kwon JY, Herder LM, et al. Correlation of AO and Lauge-Hansen classification systems for ankle fractures to the mechanism of injury. *Foot Ankle Int* 2013; 34:1516–20.
- [15] Velleman J, Nijs S, Hoekstra H. Operative management of AO type 44 ankle fractures: determinants of outcome. *J Foot Ankle Surg* 2017; 57:247–53.
- [16] Weber M, Ganz R. Malunion following trimalleolar fracture with posterolateral subluxation of the talus--reconstruction including the posterior malleolus. *Foot Ankle Int* 2003; 24:338–44.
- [17] Bible JE, Mir HR. External fixation: principles and applications. *J Am Acad Orthop Surg* 2015; 23:683–90.
- [18] Chan KB, Lui TH. Role of ankle arthroscopy in management of acute ankle fracture. *Arthroscopy* 2016; 32:2373–80.
- [19] Hintermann B, Boss A, Schäfer D. Arthroscopic findings in patients with chronic ankle instability. *Am J Sports Med* 2002; 30:402–9.