



OPEN ACCESS

# Postpartum bilateral lung transplantation in COVID-19 associated respiratory failure

Gayathri Devi Vadlamudi <sup>1</sup>, Madhurima Keerthy,<sup>1</sup> Gregory Goyert<sup>2</sup>

<sup>1</sup>Department of Obstetrics and Gynecology, Henry Ford Health System, Detroit, Michigan, USA  
<sup>2</sup>Department of Maternal Fetal Medicine, Henry Ford Health System, Detroit, Michigan, USA

**Correspondence to**

Dr Gayathri Devi Vadlamudi;  
gvadlamu@umich.edu

Accepted 30 April 2022

**SUMMARY**

In critically ill patients with COVID-19, established therapies in the setting of respiratory failure include invasive mechanical ventilation and extracorporeal membrane oxygenation (ECMO). This case report describes a pregnant woman in her 30s who was hospitalised at 35 weeks gestation with moderate COVID-19 disease. Her condition worsened following delivery, and she required intubation, maximum ventilatory support and ECMO. Because of the severe and irreversible nature of her lung disease, she ultimately underwent bilateral lung transplantation. This case showcases lung transplantation as an alternative life-saving option for patients with severe COVID-19 associated respiratory failure refractory to ECMO and mechanical ventilation. Further studies are needed to develop a multidisciplinary approach for patient selection for transplantation within the context of COVID-19 and to assess long-term outcomes.

**BACKGROUND**

As of March 2022, there have been 79.1 million cases of COVID-19 in the USA, with more than 955 000 deaths.<sup>1</sup> The WHO has previously reported that 5% of patients who are infected with the SARS-CoV-2 virus and contract COVID-19 become critically ill, and in these patients, the mortality rate is over 50%.<sup>2</sup> Extracorporeal membrane oxygenation (ECMO) has been used to treat critically ill patients with respiratory failure in the setting of COVID-19 that is refractory to invasive mechanical ventilation. Options are limited for patients who show no improvement with these measures.

**CASE PRESENTATION**

A woman in her 30s, gravida 1, para 0, with a medical history of ulcerative colitis presented in November 2020 at 35 weeks singleton gestation with headache, shortness of breath, cough, fever, chills, nausea and vomiting. She had not been vaccinated for COVID-19 at the time. On admission, her vital signs were notable for tachypnoea with a respiratory rate of 24 breaths per minute and hypertension with blood pressure of 157/88 mm Hg. Crackles were noted on examination. A PCR test for SARS-CoV-2 performed on admission was positive. Laboratory values were notable for hypokalaemia and hypomagnesaemia. There was no transaminitis or thrombocytopenia. Chest X-ray showed mild cardiomegaly with diffuse interstitial infiltrates. Venous duplex ultrasound showed no evidence of thrombosis in bilateral lower extremities.

**TREATMENT**

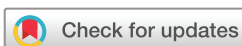The patient had increased work of breathing and was started on supplemental oxygen through nasal cannula. She received a 14-day course of dexamethasone and a 5-day course of remdesivir for treatment of COVID-19. Low dose heparin infusion was started for anticoagulation. She required up to 3 L/min of oxygen by nasal cannula to maintain oxygen saturations above 95%.

On hospital day (HD) 5, she developed severely elevated blood pressure and was diagnosed with pre-eclampsia with severe features. **Figure 1** displays a timeline of the patient's clinical course. She underwent induction of labour and vaginal delivery of a female neonate on HD 7. SARS-CoV-2 PCR testing of the neonate was negative.

Following delivery, the patient had occasional episodes of oxygen desaturation and was unable to be weaned off supplemental oxygen over the next few days. On HD 10, her oxygen saturations dropped to the low 80s and she was started on high-flow nasal cannula 40 L/min with 0.90 fraction of inspired oxygen. This was only able to be weaned to a minimum of 0.75 fraction of inspired oxygen over the next several days. She was started on broad spectrum antibiotics on HD 10 and received convalescent plasma infusions on HD 13 and 15. On HD 16, she became increasingly tachypnoeic, failed non-invasive ventilation and was intubated. Chest X-ray showed evidence of worsening bilateral pneumonia.

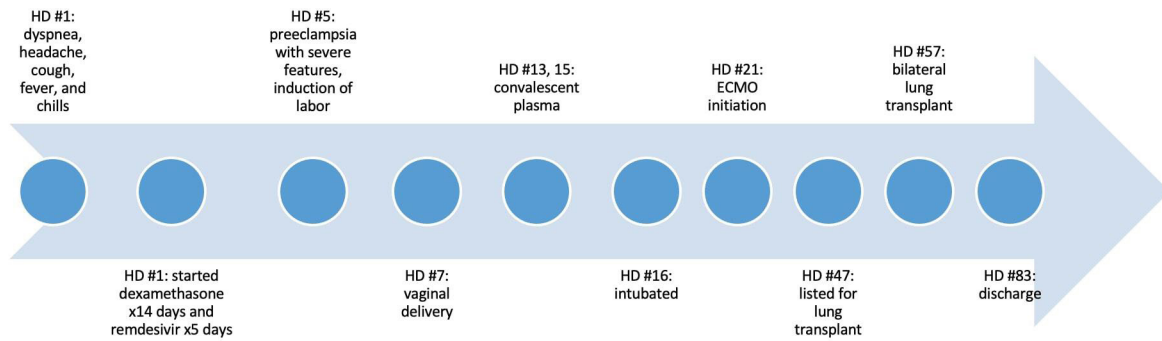
Over the next few days, she was intermittently positioned in the prone position in an attempt to improve oxygenation. She required the use of high positive end-expiratory pressures up to 20 mm Hg. With continued difficulties with ventilation and oxygenation despite the use of additional sedation and prone positioning, ECMO was considered. Risk stratification scores for ECMO patient selection predicted her clinical outcome to be poor, leading to initiation of venovenous ECMO on HD 21. Chest X-ray showed near complete opacification of the lungs with evidence of pulmonary oedema, pneumonia and pleural effusions (**figure 2**).

Despite maximal support with ECMO and mechanical ventilation, her oxygenation remained poor and she continued to have intermittent episodes of desaturation. She developed right-sided heart failure and shock liver. She required increasing ECMO flow rates in the setting of worsening lung compliance. On HD 33, she underwent initial evaluation for lung transplantation given the severe and irreversible nature of her lung disease. As part of pretransplant



© BMJ Publishing Group Limited 2022. Re-use permitted under CC BY-NC. No commercial re-use. See rights and permissions. Published by BMJ.

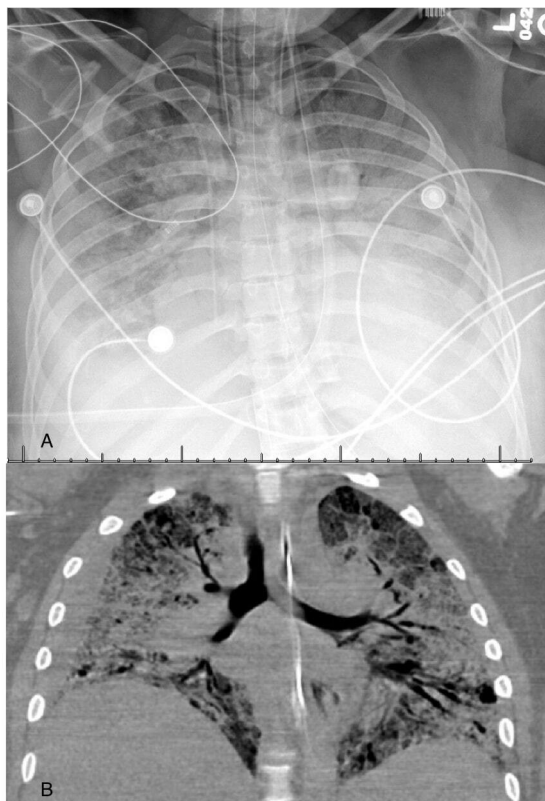
**To cite:** Vadlamudi GD, Keerthy M, Goyert G. *BMJ Case Rep* 2022;**15**:e249159. doi:10.1136/bcr-2022-249159



**Figure 1** Timeline of patient's clinical course. ECMO, extracorporeal membrane oxygenation; HD, hospital day.

evaluation, SARS-CoV-2 PCR testing was repeated and was negative. Pulmonary transplant, cardiothoracic surgery, infectious disease, intensive care, heart failure, psychology and social work teams were involved in the transplant evaluation.

Over the course of the admission, there were multiple instances of initiation of treatment for possible sepsis. This was suspected in the setting of the patient's respiratory failure with intermittent episodes of hypotension requiring the use of pressors, occasional fevers and increased cardiac output noted on monitoring. CT imaging on HD 35 showed diffuse consolidative groundglass opacities (figure 2). This was most consistent with COVID-19 associated pneumonia; however, the patient was treated for possible postinfectious organising pneumonia with high dose steroids, with no subsequent improvement. Antibiotics and antifungals initiated for sepsis



**Figure 2** Chest imaging findings. (A) Near complete opacification of lungs with evidence of pulmonary oedema, infection and pleural effusions on chest X-ray, hospital day 22. (B) Diffuse patchy consolidative and ground glass opacities, multifocal pneumonia, severe parenchymal disease and cysts seen on chest CT, hospital day 35.

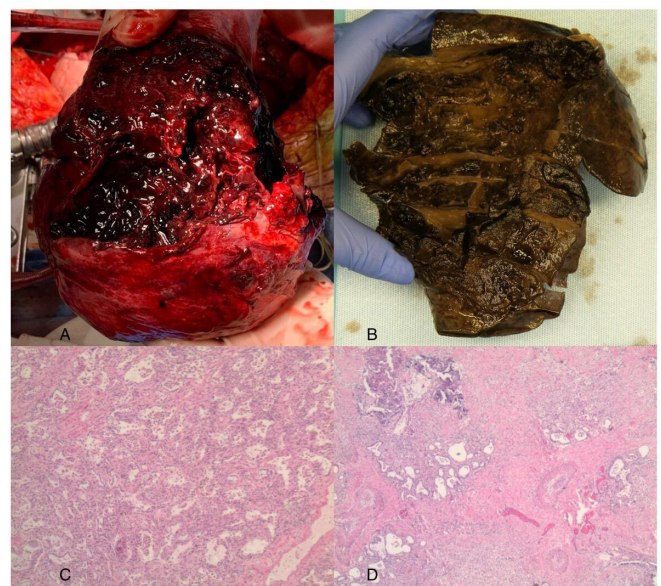
were all later discontinued after bacterial culture and PCR tests and fungal antigen tests resulted as negative.

The patient was listed for bilateral lung transplantation on HD 47. Severe pulmonary hypertension and right ventricular volume and pressure overload were noted on echocardiogram on HD 50. On HD 52, she experienced desaturations requiring urgent conversion to venoarterial ECMO.

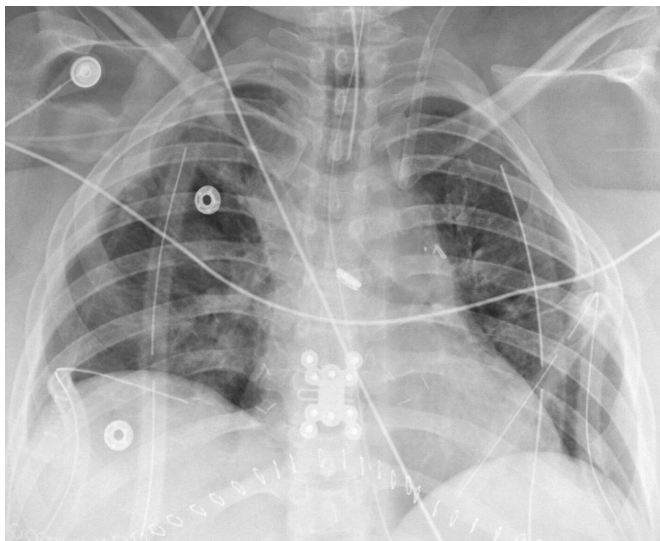On HD 57, she underwent bilateral lung transplantation. Intraoperative findings (figure 3) showed severely reduced lung size with no motion noted on ventilation. The right lung was noted to have ruptured in the central portion, with a large clot filling this space. Significant inflammation and adhesions were noted around the hilum. Histopathological inspection showed diffuse alveolar damage of both lungs, cystic bullous spaces, extensive haemorrhage, prominent follicular hyperplasia in hilar lymph nodes and mucous plugs in bronchial lumens.

**OUTCOME AND FOLLOW-UP**

Postoperatively, the patient recovered well. Postoperative imaging of the chest showed mild strand-like opacities in the



**Figure 3** Gross and pathological findings. (A) Intraoperative findings of ruptured haemorrhagic native lung. Used with permission of Dr Daizo Tanaka. (B) End stage changes of fibrotic lung. (C, D) Evidence of focal necrotic debris and pulmonary hypertension on pathology, H&E stain 2x (C) and 4x (D).



**Figure 4** Postoperative chest imaging findings. Mild strand-like opacities of bilateral lungs.

bilateral lungs (figure 4), which was noted to be a remarkable improvement from the pretransplant findings of diffuse opacification. She was weaned from mechanical ventilation and on HD 83 she was discharged to a rehabilitation facility. Bronchoscopy performed after 6 weeks showed patent bilateral anastomoses without granulation tissue, with no significant secretions or airway abnormalities. Surveillance with bronchoscopy and transbronchial lung biopsies at 1 month, 6 months, 9 months and 1 year post-transplant did not show evidence of rejection or infection. She completed pulmonary rehabilitation and has received full vaccination for COVID-19 with three doses.

## DISCUSSION

Pregnant patients with COVID-19 are more likely to require hospitalisation, intensive care unit admission and mechanical ventilation than the general population.<sup>3</sup> Prior studies have shown that COVID-19 may carry a higher mortality rate in the postpartum period than during pregnancy,<sup>4</sup> and that acute respiratory distress syndrome attributed to COVID-19 can have later onset than the typical 1 week period noted in the Berlin criteria.<sup>5</sup>

There are several established scoring systems for predicting outcomes of acute respiratory distress syndrome and stratifying the severity of lung injury to guide patient selection for ECMO. The case presented here showcases lung transplantation as an additional life-saving option for COVID-19 patients with acute respiratory distress syndrome refractory to ECMO and mechanical ventilation. Our patient demonstrated worsening lung compliance, required increasing ECMO flow rates, and had evidence of other organ damage including shock liver and right heart failure. A multidisciplinary selection committee deemed that due to the severity and irreversibility of her disease, she could not be expected to recover and that listing for lung transplantation was appropriate.

In the time since the case described in this report occurred, a second patient with COVID-19 has undergone bilateral lung transplantation at our institution in the immediate postpartum setting. In a literature search of management of COVID-19 associated respiratory failure, few case reports have described the use of lung transplantation. In the largest case series thus far by Bharat *et al*,<sup>6</sup> 12 patients from various institutions across

four countries were identified who underwent bilateral lung transplantation in the setting of COVID-19 associated acute respiratory distress syndrome. Histopathological evaluation of the explanted native lung tissue from these patients showed features of pulmonary fibrosis, which supports the findings of irreversible lung damage. Evidence from these cases suggests a time period of 4–6 weeks as sufficient to exclude the possibility of native lung recovery and supports the consideration of lung transplantation for COVID-19 associated respiratory failure in the absence of other organ system dysfunction.

To consider the option of lung transplantation for future patients with severe COVID-19, a multidisciplinary approach is needed to delineate appropriate candidates, with consideration of the limited availability of donor organs. The median survival of patients who undergo lung transplantation is 6.7 years,<sup>7</sup> with survival most affected by development of chronic lung allograft dysfunction. Further studies are needed to evaluate the likelihood of transplant rejection, the possibility of recurrence of SARS-CoV-2 infection of the allograft and long-term outcomes.

## Learning points

- ▶ Lung transplantation offers an alternative life-saving option for patients with severe COVID-19 associated respiratory failure refractory to established treatments.
- ▶ Pregnant women with COVID-19 may have higher mortality in the postpartum period than during pregnancy and later onset of acute respiratory distress syndrome when related to COVID-19.
- ▶ A multidisciplinary approach for patient selection for lung transplantation should be developed to create a standardised process for patients with COVID-19 who are not responding to other therapies.

**Acknowledgements** Karla Passalacqua, PhD, ELS, Stephanie Stebens, MLIS, AHIP, Shereen Zia, MD.

**Contributors** GDV, the corresponding author, identified the case for publication, reviewed the details of the case and drafted the article. MK and GG provided revisions to the article for approval for publication. GDV is responsible for the overall content as guarantor.

**Funding** The authors have not declared a specific grant for this research from any funding agency in the public, commercial or not-for-profit sectors.

**Competing interests** None declared.

**Patient consent for publication** Consent obtained directly from patient(s).

**Provenance and peer review** Not commissioned; externally peer reviewed.

**Open access** This is an open access article distributed in accordance with the Creative Commons Attribution Non Commercial (CC BY-NC 4.0) license, which permits others to distribute, remix, adapt, build upon this work non-commercially, and license their derivative works on different terms, provided the original work is properly cited and the use is non-commercial. See: <http://creativecommons.org/licenses/by-nc/4.0/>.

Case reports provide a valuable learning resource for the scientific community and can indicate areas of interest for future research. They should not be used in isolation to guide treatment choices or public health policy.

## ORCID iD

Gayathri Devi Vadlamudi <http://orcid.org/0000-0002-8387-9457>

## REFERENCES

- 1 Allen J, Almkhatar S, Aufrichtig A. Coronavirus world map: tracking the global outbreak. Available: <https://www.nytimes.com/interactive/2020/world/coronavirus-maps.html#countries> [Accessed 4 Mar 2022].

- 2 Ma X, Liang M, Ding M, *et al.* Extracorporeal membrane oxygenation (ECMO) in critically ill patients with coronavirus disease 2019 (COVID-19) pneumonia and acute respiratory distress syndrome (ARDS). *Med Sci Monit* 2020;26:e925364.
- 3 Thompson JL, Nguyen LM, Noble KN, *et al.* COVID-19-related disease severity in pregnancy. *Am J Reprod Immunol* 2020;84:e13339.
- 4 Takemoto MLS, Menezes MdeO, Andreucci CB, *et al.* The tragedy of COVID-19 in Brazil: 124 maternal deaths and counting. *Int J Gynaecol Obstet* 2020;151:154–6.
- 5 Li X, Ma X. Acute respiratory failure in COVID-19: is it "typical" ARDS? *Crit Care* 2020;24:198.
- 6 Bharat A, Machuca TN, Querrey M, *et al.* Early outcomes after lung transplantation for severe COVID-19: a series of the first consecutive cases from four countries. *Lancet Respir Med* 2021;9:487–97.
- 7 Bos S, Vos R, Van Raemdonck DE, *et al.* Survival in adult lung transplantation: where are we in 2020? *Curr Opin Organ Transplant* 2020;25:268–73.

Copyright 2022 BMJ Publishing Group. All rights reserved. For permission to reuse any of this content visit <https://www.bmj.com/company/products-services/rights-and-licensing/permissions/>  
BMJ Case Report Fellows may re-use this article for personal use and teaching without any further permission.

Become a Fellow of BMJ Case Reports today and you can:

- ▶ Submit as many cases as you like
- ▶ Enjoy fast sympathetic peer review and rapid publication of accepted articles
- ▶ Access all the published articles
- ▶ Re-use any of the published material for personal use and teaching without further permission

### Customer Service

If you have any further queries about your subscription, please contact our customer services team on +44 (0) 207111 1105 or via email at [support@bmj.com](mailto:support@bmj.com).

Visit [casereports.bmj.com](http://casereports.bmj.com) for more articles like this and to become a Fellow