



Contents lists available at ScienceDirect

International Journal of Surgery Case Reports

journal homepage: www.casereports.com

Testicular cavernous hemangioma associated with testicular torsion – case report and review of literature

N.F. Tepeneu^{a,b,*}, K. Krafka^a, S. Meglic^a, H. Rogatsch^c, G. Fasching^a

^a Department of Pediatric and Adolescent Surgery, General Hospital, Klagenfurt, Austria

^b University of Medicine and Pharmacy “Victor Babes”, Timisoara, Romania

^c Department of Pathology, General Hospital, Klagenfurt, Austria

ARTICLE INFO

Article history:

Received 13 April 2018

Received in revised form 15 June 2018

Accepted 21 June 2018

Available online 27 June 2018

Keywords:

Testicular torsion

Cavernous testicular hemangioma

Teenager

Case report

ABSTRACT

INTRODUCTION: Testicular neoplasms that are derived from connective tissue, blood vessels and musculature are uncommon and intra-testicular tumors of vascular origin are extremely rare; both are benign in nature. Testicular hemangioma is exceedingly rare and typically occurs in patients younger than 20 years, the age in which a primary germ cell tumor of the testis may present, necessitating a radical approach to management with orchidectomy, although potential conservative focal partial surgical excision is desirable. Hemangiomas of the testis have a similar sonographic and magnetic resonance imaging appearance to that of malignant tumors of the testis, especially seminoma.

The work has been reported in line with the SCARE criteria.

PRESENTATION OF CASE: We present a case of testicular torsion in a 15-year-old male patient who had a painful left testis for 6 days, no vomiting, no fever or dysuria.

With clinical suspicion of an old testicular torsion the patient was examined by ultrasound which confirmed the clinical diagnosis.

The patient underwent emergency surgical exploration. The left testis was found to be necrotic after a 360° testicular torsion and an orchiectomy was performed.

RESULTS: The postoperative course was uneventful. The patient was discharged on day 4 after surgery. Histology showed a complete ischemic infarction of the testicular parenchyma as part of a ruptured intratesticular cavernous hemangioma.

DISCUSSION AND CONCLUSION: Cavernous hemangioma is a rare tumor of the testicle in either childhood or adult period. The particularity of the presented case is the possible association of a cavernous intratesticular hemangioma with the torsion of the testis in a teenager. Clinicians and pathologists must be aware of the rare entity of testicular hemangiomas, as clinical examination and imaging studies do not often suffice to arrive at a correct diagnosis.

© 2018 The Authors. Published by Elsevier Ltd on behalf of IJS Publishing Group Ltd. This is an open access article under the CC BY-NC-ND license (<http://creativecommons.org/licenses/by-nc-nd/4.0/>).

1. Introduction

Testicular neoplasms that are derived from connective tissue, blood vessels and musculature are uncommon and intra-testicular tumors of vascular origin are extremely rare; both are benign in nature. Testicular hemangioma is exceedingly rare and typically occurs in patients younger than 20 years, the age in which a primary germ cell tumor of the testis may present, necessitating a radical approach to management with orchidectomy, although potential conservative focal partial surgical excision is desirable.

Hemangiomas of the testis have a similar sonographic and magnetic resonance imaging appearance with malignant tumors of the testis, especially seminoma.

The International Society for the Study of Vascular Anomalies (ISSVA) divided vascular anomalies into vascular tumors and vascular malformations. Vascular tumors arise mainly due to endothelial hyperplasia and they may regress spontaneously. Vascular malformations occur by localized defects of vascular morphogenesis, secondary to dysfunction in pathways regulating embryogenesis and they usually persist in adulthood [1]. In 2000, Mazal et al. reviewed the literature and identified four histopathological types of testicular hemangiomas: cavernous, histiocytoid, capillary and papillary endothelial hyperplasia [2].

Cavernous hemangiomas are diagnosed by dilated large vessels with thin walls. Their walls may be abnormal which may not confirm to arterial or venous morphology. Developmental arrest

* Corresponding author at: Department of Pediatric and Adolescent Surgery, General Hospital Klagenfurt, Feschnigstraße 11, 9020, Klagenfurt, Austria.

E-mail addresses: nftepeneu@yahoo.com (N.F. Tepeneu), karel.krafka@kabeg.at (K. Krafka), spela.meglic@kabeg.at (S. Meglic), hermann.rogatsch@kabeg.at (H. Rogatsch), guenter.fasching@kabeg.at (G. Fasching).

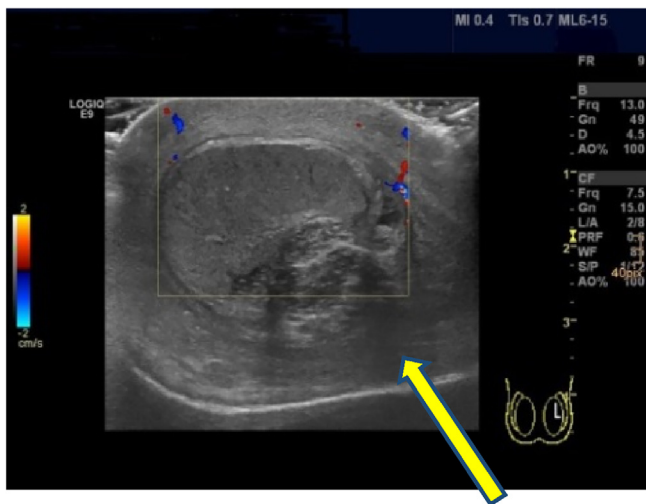


Fig. 1. The sonographic aspect of the left testicle without central perfusion and with an altered structure (GE Logiq E9 ultrasound equipment).

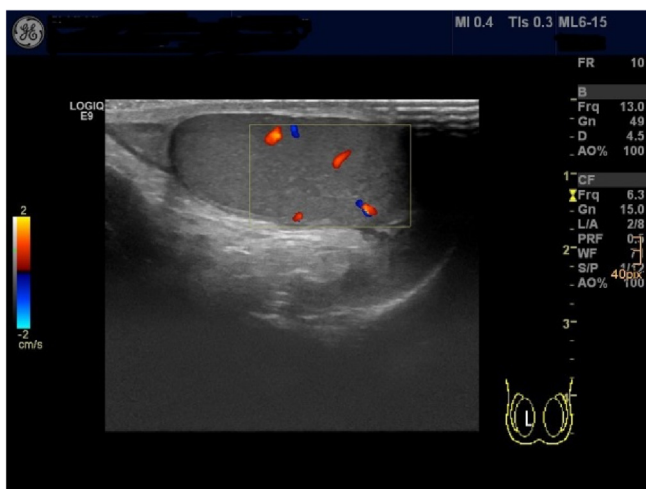


Fig. 2. For comparison the sonographic aspect of the healthy right testicle with central perfusion and with a normal structure.

during the stage of an undifferentiated capillary network has been postulated to result in a cavernous hemangioma.

This work has been reported in line with the SCARE criteria [3].

2. Presentation of case

We present a case of testicular torsion in a 15-year-old male patient who had a painful left testis for 6 days, no vomiting, no fever or dysuria.

With clinical suspicion of an old testicular torsion the patient was examined by ultrasound which confirmed the clinical diagnosis (Figs. 1 and 2).

The patient underwent emergency surgical exploration. The left testis was found to be necrotic after a 360 degree testicular torsion (Fig. 3) and an orchiectomy was performed.

The postoperative course was uneventful. The patient was discharged on day 4 after surgery. Histology showed a complete ischemic infarction of the testicular parenchyma as part of a ruptured intratesticular cavernous hemangioma (Figs. 4 and 5).

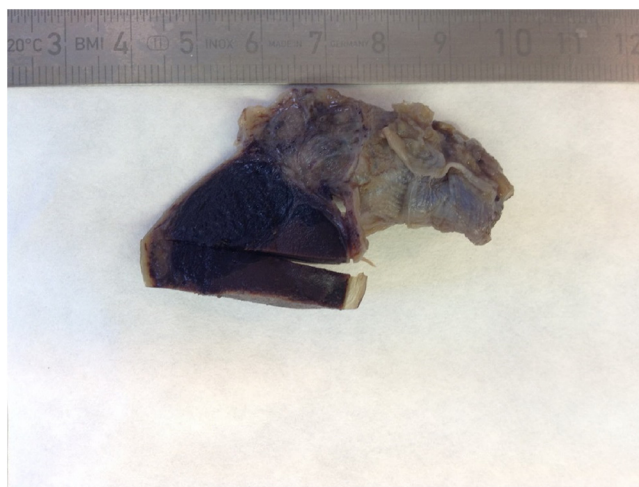


Fig. 3. The macroscopic aspect of the removed testicle and spermatic cord.

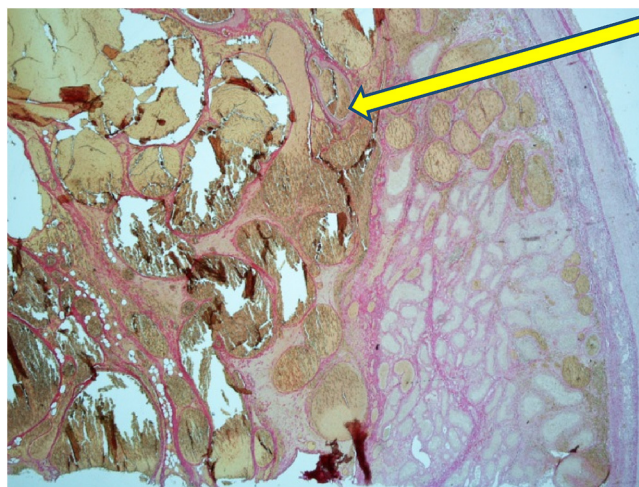


Fig. 4. Verhoeff–Van Gieson stain (20× magnification) – Histological aspect of the hemangioma.

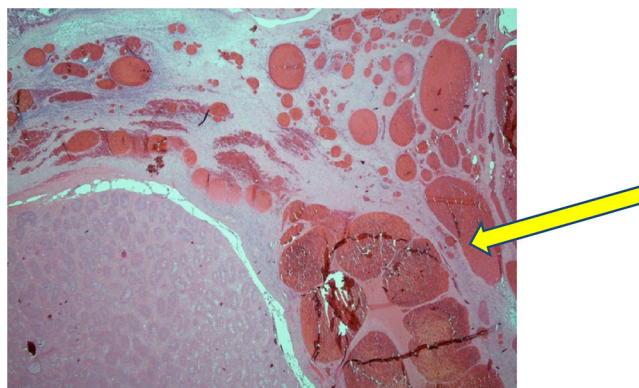


Fig. 5. Hematoxylin and eosin stain (20× magnification) – Histological aspect of the hemangioma.

3. Discussion

Hemangiomas of the soft tissues are the most common benign tumors of vascular origin. In the pediatric population, 60% of the hemangiomas are located in the head and neck, 25% in the trunk and 15% in the extremities [4].

Testicular hemangiomas are extremely rare and they occur in diverse age groups. Four histological types of benign vascular tumors are reported: cavernous haemangiomas, capillary haemangiomas, hystiocytoid and papillary endothelial hyperplasia. Cavernous hemangioma of the testis primarily presents during childhood [5]. Our case is a cavernous hemangioma of the testis. Intra-testicular form of hemangiomas is reported rarely, compared with extra-testicular genital hemangiomas. Unilateral testicular enlargement, with or without tenderness, is the main presenting symptom, which is similar to that of malignant testicular tumors on clinical presentation. Pain is an inconsistent feature [1,2,4–7]. Our patient presented with enlargement and pain in his left testis for 6 days. These could have been because of the intratesticular hemangioma, because of the torsion of the testis or both.

Rarely, testicular hemangioma can present with bleeding or ulceration. Spontaneous involution is not reported with this type of hemangioma and long term complications like infertility, hemorrhage and even necrosis can occur. It can be seen extending into the penis, anterior abdominal wall, perineum and pelvis [8,9]. An association with hemangiomas in other sites such as skin, liver, rectum and bladder has been reported by other authors [10,11].

Genital hemangioma may mimic an inguinal hernia, while subcutaneous location on the scrotum can be confused with a varicocele when it presents on the left side. Infarction associated with torsion of testis is usually analyzed with frozen section and histopathological sections are helpful only in confirming the diagnosis. All the cases of testicular cavernous hemangioma reported in the literature have run a benign course and there were no mentions of metastasis and recurrence following surgical excision [12].

Sometimes the growth of the testicular hemangioma can be rapid and it may clinically simulate an aggressive neoplasm [13].

On ultrasonogram testicular hemangiomas are often hypoechoic but sometimes hyperechoic or even heterogeneous [14–16]. When the tumor markers are negative, the presence of a mass with variably sized calcifications is highly suggestive of cavernous hemangioma. However, serum AFP, beta-hCG and LDH are raised only in half of the patients diagnosed with testicular malignancies. The differential diagnosis must include germ cell tumors (seminoma, teratoma), adenomatoid tumor, and sex-cord stromal tumors such as Sertoli cell tumor. The worldwide incidence of testicular cancer is estimated to have doubled in the last 40 years but significant variation exists between races and countries [13].

The management of testicular masses presenting in childhood is governed by the pubertal status of the patient. Prepubescent tumours are often benign, the commonest neoplasms being yolk sac tumours and teratomas. The proportion of benign tumours has been reported as 30–70% compared with only 5% in adults, and those that are malignant have a much lower incidence of metastasis. Hemangioma can be very similar to malignant testicular tumors on clinical presentation and also by sonography and magnetic resonance imaging. Clinical appearance and diagnostic exams are usually not sufficient for the definite diagnosis of testicular hemangioma and require a histopathological examination, although Tallen et al. reported that when combined with clinical symptoms in the case of childhood testicular neoplasms sonography predicted 75% of histologies. After including hormone and tumor marker levels, a correct preoperative diagnosis was made for all boys with germ cell, and for 75% of boys with sexcord stromal tumor [17]. Demonstration of intra-lesional blood flow can be made by Color Doppler studies; however lack of flow does not indicate the absence of cavernous hemangiomas, especially in the situation where a testicular torsion is also present.

Treatment options available for testicular hemangioma are surgical excision, laser fulguration, intralesional sclerotherapy and cryotherapy. If the surgeons and pathologists are aware of it, especially with negative tumor marker findings, tissue sparing surgical

treatment by means of tumor enucleation with preservation of the testis is possible if intraoperative frozen section examination can be performed. Frozen section must be performed especially if the neoplasm has significant vascular proliferation identified by Doppler sonography. Because of the benign nature of this pathology, preservation of the testis is possible if the diagnosis can be performed during the operation by frozen sections.

The principles of testicle-sparing surgery is well established for testicular tumours. If the diagnosis is not definitive, orchidectomy must be performed. Testis sparing surgery is commonly done in pre-pubescent tumors as the proportion of benign tumors is relatively higher than in adults [4,13].

Testicular hemangiomas can also present as testicular torsion or associated with testicular infarction [7]. To our knowledge there is no report in the English medical literature up to this date which associates a testicular cavernous hemangioma with a testicular torsion at the age of 15 years or below. There is a report of a young man 18 years of age with a cavernous hemangioma mimicking testicular torsion [18], and also a report of a man 22 years of age with a hemangioma and testicular torsion [7].

There is a high likelihood of spontaneous testicular torsion at the patients age. Intravaginal torsion most commonly occurs in adolescents. It is thought that the increased weight of the testicle after puberty, as well as sudden contraction of the cremasteric muscles (which inserts in a spiral fashion into the spermatic cord), is the impetus for acute torsion. Testicular torsion is favoured by enlargement of the testis associated with testicular malignancy, especially in adults. One study found a 64% association of testicular torsion with testicular malignancy [19]. This is thought to be secondary to a relative increase in the broadness of the affected testicle compared with its blood supply. However, in a review of 32 patients who had been diagnosed with testicular torsion, testicular cancer was found in 2 of the 20 patients who had undergone orchidectomy, a rate of 6.4% [20].

It is difficult to tell if the cavernous hemangioma of the testis, which was unknown before the beginning of the testicular pain, was the trigger for testicular torsion or if this was just an incidental postoperative finding. Enlargement of the testis due to the hemangioma may have triggered the torsion of the testis.

4. Conclusion

Cavernous hemangioma is a rare tumor of the testicle in either childhood or adult period. The particularity of the presented case is the possible association of a cavernous intratesticular hemangioma with the torsion of the testis in a teenager. Clinicians and pathologists must be aware of the rare entity of testicular hemangiomas, as clinical examination and imaging studies do not often suffice to arrive at a correct diagnosis.

Conflicts of interest

We have nothing to declare in any of these categories.

Funding

We have nothing to declare in any of these categories.

Ethical approval

There is ethical approval from the ethical committee of Land Kärnten number A20/18.

Consent

Written informed consent was obtained from the patient's parents for publication of this case report and accompanying images. A copy of the written consent is available for review by the Editor-in-Chief of this journal on request.

Author contribution

Tepeneu N.F. – writing of the paper, study concept and design.
Krafka K. – data collection.
Meglic S. – data collection.
Rogatsch H. – data analysis.
Fasching G. – study concept.

Registration of research studies

researchregistry3921.

Guarantor

Prim. Univ.-Doz. Dr. Günter Fasching, LL.M.

References

- [1] G.A. Talmon, S.M. Stanley, D.J. Lager, Capillary hemangioma of the testis, *Int. J. Surg. Pathol.* 19 (2011) 398–400.
- [2] P.R. Mazal, C. Kratzik, R. Kain, M. Susani, Capillary haemangioma of the testis, *J. Clin. Pathol.* 53 (August (8)) (2000) 641–642.
- [3] R.A. Agha, A.J. Fowler, A. Saetta, I. Barai, S. Rajmohan, D.P. Orgill, for the SCARE Group, The SCARE statement: consensus-based surgical case report guidelines, *Int. J. Surg.* 34 (2016) 180–186.
- [4] B. Ermis, A. Otken, B. Zulfikar, K. Yılmaz, M. Ilter, A. Sogut, Hemangiomas, *Turkiye Klinikleri J. Med. Sci.* 16 (1996) 423–426.
- [5] F.M. Mazzella, S.C. Sieber, V. Lopez, Histocytoid hemangioma of the testis: a case report, *J. Urol.* 153 (1995) 743–744.
- [6] D. Chavan, A.P. Javalgi, Scrotal hemangioma: a case report, *J. Clin. Diagn. Res.* 8 (12) (2014) ND03–ND04.
- [7] T. Minagawa, Y. Murata, Testicular cavernous hemangioma associated with intrascrotal testicular torsion: a case report, *Hinyokika Kyo* 55 (2009) 161–163.
- [8] R. Rastogi, Diffuse cavernous hemangioma of the penis, scrotum, perineum, and rectum: a rare tumor, *Saudi J. Kidney Dis. Transpl.* 19 (4) (2008) 614–618.
- [9] M. Froehner, P. Tsatalpas, M.P. Wirth, Giant penile cavernous hemangioma with intrapelvic extension, *Urology* 53 (1999) 414–415.
- [10] D. Keret, I. Kam, Y. Ben-Arieh, et al., Scrotal cavernous haemangioma with a family history of cutaneous angiomas, *J. R. Soc. Med.* 83 (1990) 402–403.
- [11] S. Yanai, H. Tsutsumi, T. Hotsubo, et al., Development of a testicular haemangioma after interferon therapy for hepatic haemangiomas: a case report, *Eur. J. Pediatr.* 156 (1997) 784–786.
- [12] B. Liu, J. Chen, J. Luo, F. Zhou, C. Wang, L. Xie, Cavernous hemangioma of the testis mimicking a testicular teratoma, *Exp. Ther. Med.* 6 (1) (2013) 91–92.
- [13] L.R. Bonetti, L. Schirosi, G. Sartori, M. Lupi, C. De Gaetani, N. Trani, A. Maiorana, Rapidly-growing hemangioma of the testicle clinically simulating an aggressive neoplasm. A case report, *Pathologica* 101 (June (3)) (2009) 123–125.
- [14] A. Suriawinata, A. Talerman, J.M. Vapnek, et al., Hemangioma of the testis: report of unusual occurrences of cavernous hemangioma in a fetus and capillary hemangioma in an older man, *Ann. Diagn. Pathol.* 5 (2001) 80–83.
- [15] G. Atkin, M. Miller, K.S. Clarkson, et al., Testicular capillary haemangioma in a child, *J. R. Soc. Med.* 94 (2001) 638–640.
- [16] R.J. Vital, L.A. de Mattos, L.R.M.F. de Souza, S. da Silva Figueirêdo, J. Szejnfeld, Sonographic findings in non-neoplastic testicular lesions, *Radiol. Bras.* 40 (1) (2007).
- [17] G. Tallen, P. Hernáiz Driever, P. Degenhardt, G. Henze, T. Riebel, High reliability of scrotal ultrasonography in the management of childhood primary testicular neoplasms, *Klin Padiatr.* 223 (May (3)) (2011) 131–137, <http://dx.doi.org/10.1055/s-0031-1271813>, Epub 2011 Apr 1.
- [18] S. Bharthi, N. Ap, Cavernous hemangioma of the testis mimicking as torsion of testis: a case report, *Ann. Pathol. Lab. Med.* (2018) C40–C42, <http://dx.doi.org/10.21276/apalm.1054>.
- [19] J.S. Barthold, Abnormalities of the testis and scrotum and their surgical management, in: W.S. McDougal, L.R. Kavoussi, A.C. Novick, A.W. Partin, C.A. Peters (Eds.), *Campbell–Walsh Urology*, 10th ed., WB Saunders, Philadelphia, PA, 2012, pp. 642–645.
- [20] S. Uguz, S. Yilmaz, A. Guragac, B. Topuz, E. Aydur, Association of torsion with testicular cancer: a retrospective study, *Clin. Genitourin. Cancer* 14 (February (1)) (2016) e55–e57.

Open Access

This article is published Open Access at [sciencedirect.com](https://www.sciencedirect.com). It is distributed under the [IJSCR Supplemental terms and conditions](#), which permits unrestricted non commercial use, distribution, and reproduction in any medium, provided the original authors and source are credited.