



Contents lists available at ScienceDirect

## Gynecology and Minimally Invasive Therapy

journal homepage: [www.e-gmit.com](http://www.e-gmit.com)

## Clinical images

Heterotopic pregnancy after *in vitro* fertilization in a patient with distal tubal hypoplasia

Ta-Sheng Chen, Meng-Hsing Wu\*

Department of Obstetrics and Gynecology, National Cheng Kung University Hospital, College of Medicine, National Cheng Kung University, Tainan, Taiwan

## ARTICLE INFO

## Article history:

Received 2 February 2017

Received in revised form

12 June 2017

Accepted 5 July 2017

Available online 21 July 2017

## Introduction

Heterotopic pregnancy is the condition that both intrauterine and ectopic pregnancy are present. It occurs rarely in a natural conception cycle, but more frequently in IVF, in which more than one embryo may be transferred,<sup>1,2</sup> even women with a history of salpingectomy.<sup>3</sup> It's a challenge for clinicians to confirm this diagnosis earlier. In general practice, ectopic pregnancy was rarely considered if intrauterine pregnancy was present. Therefore, diagnosis may be delayed until internal bleeding from ruptured ectopic sac was profound.<sup>4</sup> More worse, ascites resulted from hyperstimulated ovaries is hard to distinguish from internal bleeding in IVF patients.<sup>1</sup> Here we present a case of heterotopic pregnancy with congenital tubal hypoplasia that serial follow-up didn't reveal an abnormality until abdominal pain with hemoperitoneum was present.

## Case report

A 27-year-old pregnant woman, gravida 3, para 0, abortion 2, conceived through IVF came to our emergency room for sudden onset lower abdominal pain and vaginal bleeding. Reviewing past history, she has been trying to conceive for 3 years but not succeeded although one course of IVF and another frozen embryo transfer was performed. She didn't have any surgery before. Hysterosalpingogram has revealed bilateral blocked tubes with

hydrosalpinx in other clinic and then transferred to our hospital for consultation and further management. Therefore, diagnostic laparoscopy and transvaginal oocytes retrieval had been performed simultaneously. In the surgery, the distal part of right fallopian tube wasn't visible (Fig. 1), although right ovary was in situ. Correspondingly, left ovary and fallopian tube were visible after adhesiolysis was done. After the surgery, three embryos were frozen and then transferred in another menstruation cycle (31 days prior to abdominal pain). Serial check-up revealed one intrauterine pregnancy growing up gradually. The ultrasonographic diameter was 2.0 cm, just measured 4 days prior to the abdominal pain.

In emergency department, she presented with tachycardia (heart rate 101 bpm) and low blood pressure (96/68 mmHg). Her hemoglobin level was 12.1 g/dl but ultrasonography has uncovered much fluid in the cul-de-sac and Morrison's pouch. Under the impression of internal bleeding, emergent diagnostic laparoscopy was indicated. However, the situation is complicated by the existence of intrauterine pregnancy. Therefore, risk of abortion was informed. The laparoscopy had found ruptured ectopic sac over right interstitial part of the fallopian tube (Fig. 2). Correspondingly, the left side adnexa was normal. The right side remnant tube was then removed gently and the edge was then sealed by bipolar electrocautery. The abdomen was then washed by saline completely to prevent peritoneal irritation caused by residual blood. In order to prevent threatened abortion, oral and intramuscular injected progesterone for luteal support were given as well. After removal of ectopic sac by laparoscopy, the vaginal spotting stopped and the patient discharged 3 days later. The pregnancy has kept going smoothly without complication. She then gave birth to a term baby at 39 weeks of gestational age.

## Discussion

There are several treatment options for ectopic pregnancy.<sup>5</sup> Non-surgical treatment includes local or systemic methotrexate injection. Local potassium chloride injection with or without systemic methotrexate was also pointed out. However, when heterotopic pregnancy was considered, methotrexate isn't a good choice because of the toxicity for the intrauterine pregnancy.<sup>6</sup> Potassium chloride injection or hyperosmolar glucose is effective but may result in persistent trophoblastic tissue in situ throughout the

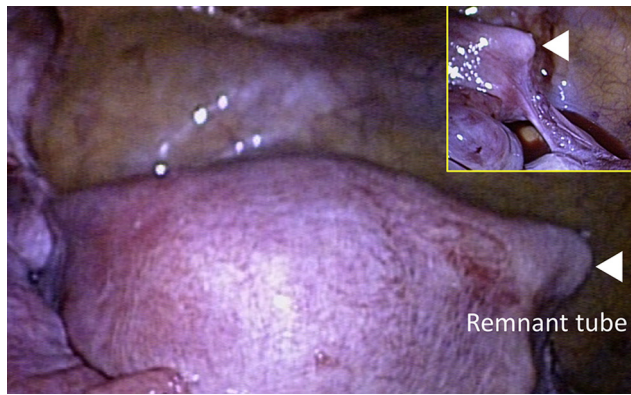
The authors have no conflicts of interest relevant to this article.

\* Corresponding author. Department of Obstetrics and Gynecology, National Cheng Kung University Hospital, College of Medicine, National Cheng Kung University, 138 Sheng-Li Road, 70428 Tainan, Taiwan.

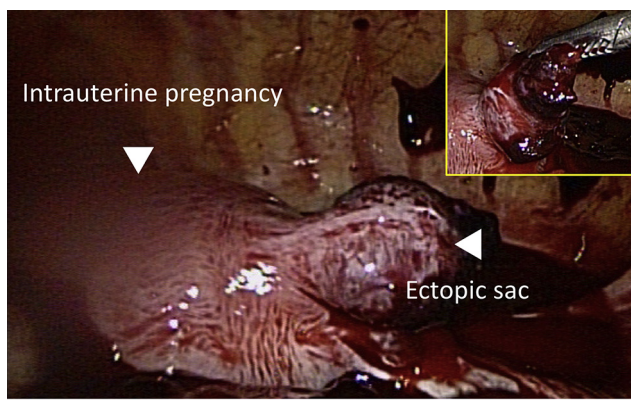
E-mail address: [mhwu68@mail.ncku.edu.tw](mailto:mhwu68@mail.ncku.edu.tw) (M.-H. Wu).

<http://dx.doi.org/10.1016/j.gmit.2017.07.001>

2213-3070/Copyright © 2017, The Asia-Pacific Association for Gynecologic Endoscopy and Minimally Invasive Therapy. Published by Elsevier Taiwan LLC. This is an open access article under the CC BY-NC-ND license (<http://creativecommons.org/licenses/by-nc-nd/4.0/>).



**Fig. 1.** Suspected congenital tubal hypoplasia over right fallopian tube.



**Fig. 2.** Ectopic gestational sac is located in right remnant tube.

duration of the surviving intrauterine pregnancy. Therefore, surgical resection of the ectopic sac is preferred. There is no consensus regarding laparoscopy or laparotomy is the best method. Although Vilos et al reported a heterotopic pregnancy receiving laparoscopy with subsequent growth retardation of the surviving intrauterine pregnancy,<sup>7</sup> there are emerging review articles and case series verified the safety of laparoscopy during pregnancy.<sup>1,8</sup> In our case, laparoscopic salpingectomy was done smoothly and the patient discharged 3 days after the surgery without any perinatal complication.

The outcome of surviving intrauterine pregnancy is good. Gorka et al reported 80 heterotopic pregnancies that 25 patients had miscarriages, and 50 and 5 patients delivered infants at term and preterm, respectively.<sup>1</sup> Another earlier reports also mentioned 8 IUP survived in total 13 cases<sup>8</sup> and 9 of 17 patients,<sup>2</sup> respectively. Therefore, it's reasonable to preserve the intrauterine pregnancy in heterotopic pregnancy. In addition, to prevent threatened abortion after surgery, we had prescribed progesterone for luteal support to stabilize the intrauterine pregnancy.

The actual incidence of adnexal abnormality is hard to determine because patients are usually asymptomatic. Vaiarelli et al<sup>9</sup> has reviewed the literatures reporting adnexal abnormalities. In the 29 patients collected, most of them are absent unilateral ovary and fallopian tube. Only 2 cases are absent unilateral fallopian tube but ipsilateral ovary is present. Another 2 cases are absent unilateral ovary but ipsilateral fallopian tube is present. Three possible causes were proposed: (1) previous asymptomatic ovarian torsion leads to ischemia. Ipsilateral ovary and fallopian tube were degenerated after that; (2) development defect of Müllerian duct or gonad; (3) vascular anomaly of one side adnexa that leads to ischemia and

degeneration. Acien et al<sup>10</sup> has proposed an embryological-clinical classification system to classify female genital tract malformation. Our patient didn't fit in any category. Therefore, the possible cause of absent right fallopian tube may be vascular accident.

Female infertility may be resulted from ovary, tubal factor, uterine problems, endometriosis,<sup>11</sup> etc. Surgery can correct pelvic anatomy and discontinue inflammation caused by endometriosis. In previous study, we had reported 23 patients received simultaneous laparoscopy and transvaginal oocytes retrieval.<sup>12</sup> Pelvic pathologic conditions, such as endometriosis or hydrosalpinx, could be uncovered and corrected after oocytes retrieval immediately. In addition, with the advance of embryo vitrification, it's also possible to transfer the embryo at the best time, after endometriosis or other pathology was corrected by laparoscopy. Simultaneous procedure (laparoscopy and transvaginal oocytes retrieval) is still a controversial practice, but it may save cost and time with avoiding repeated anesthesia. In this case, laparoscopy is indicated according to hydrosalpinx inferred by hysterosalpingogram study. Although no hydrosalpinx was seen in the laparoscopic examination, if yes, bilateral salpingectomy may improve pregnancy outcome. The laparoscopic examination has revealed right distal tubal hypoplasia in this case. The following heterotopic pregnancy may be prevented if we cauterized or cut the remnant tube immediately.<sup>13</sup>

With the help of assisted reproductive technology, more women with endometriosis or tubal anomalies could get pregnant. However, rare types of ectopic pregnancies may become more common likewise. Clinician should be alert to abdominal pain when women with infertility received assisted reproductive technology, especially when heterotopic pregnancy is highly suspected.

## References

- Barrenetxea G, Barinaga-Rementería L. Heterotopic pregnancy: two cases and a comparative review. *Fertil Steril.* 2007;87(2). <http://dx.doi.org/10.1016/j.fertnstert.2006.05.085>. 417.e9–417.e15.
- Rizk B, Tan SL, Morcos S, et al. Heterotopic pregnancies after in vitro fertilization and embryo transfer. *Am J Obstet Gynecol.* 1991;164(1 Pt 1):161–164.
- Khoo F, Tan TY, Tan HH. Laparoscopic resection of cornual heterotopic pregnancy after in vitro fertilization and embryo transfer leading to successful live birth. *Gynecol Minim Invasive Ther.* 2014;3(3):93–96. <http://dx.doi.org/10.1016/j.gmit.2014.08.002>.
- Fernandez H, Gervaise A. Ectopic pregnancies after infertility treatment: modern diagnosis and therapeutic strategy. *Hum Reprod Update.* 2004;10(6):503–513. <http://dx.doi.org/10.1093/humupd/dmh043>.
- Siraj SHM, Wee-Stekly WW, Chern BSM. Heterotopic pregnancy in a natural conception cycle presenting as acute abdomen: a case report and literature review. *Gynecol Minim Invasive Ther.* 2014;3(3):100–102. <http://dx.doi.org/10.1016/j.gmit.2014.02.005>.
- Sentilhes L, Bouet P-E, Gromez A, Poilblanc M, Lefebvre-Lacoeuille C, Descamps P. Successful expectant management for a cornual heterotopic pregnancy. *Fertil Steril.* 2009;91(3). <http://dx.doi.org/10.1016/j.fertnstert.2008.09.072>. 934.e11–934.e13.
- Vilos GA. Laparoscopic resection of a heterotopic cornual pregnancy followed by term vaginal delivery. *J Am Assoc Gynecol Laparosc.* 1995;2(4):471–473. [http://dx.doi.org/10.1016/S1074-3804\(05\)80073-8](http://dx.doi.org/10.1016/S1074-3804(05)80073-8).
- Louis-Sylvestre C, Morice P, Chapron C, Dubuisson JB. The role of laparoscopy in the diagnosis and management of heterotopic pregnancies. *Hum Reprod.* 1997;12(5):1100–1102. <https://www.ncbi.nlm.nih.gov/pubmed/9194674>.
- Vaiarelli A, Luk J, Patrizio P. Ectopic pregnancy after IVF in a patient with unilateral agenesis of the fallopian tube and ovary and with endometriosis: search of the literature for these associations. *J Assist Reprod Genet.* 2012;29(9):901–904. <http://dx.doi.org/10.1007/s10815-012-9819-6>.
- Acien P, Acien MI. The history of female genital tract malformation classifications and proposal of an updated system. *Hum Reprod Update.* 2011;17(5):693–705. <http://dx.doi.org/10.1093/humupd/dmr021>.
- Yan L, Li M, Zhang B-Q, et al. Effect of ovarian dermoid cyst excision on ovarian reserve and response: insights from in vitro fertilization. *Gynecol Minim Invasive Ther.* 2016;5(4):161–165. <http://dx.doi.org/10.1016/j.gmit.2016.01.005>.
- Chen M-L, Lee K-C, Yang C-T, Hung K-H, Wu M-H. Simultaneous laparoscopy for endometriotic women undergoing in vitro fertilization. *Taiwan J Obstet Gynecol.* 2012;51(1):66–70. <http://dx.doi.org/10.1016/j.tjog.2012.01.013>.
- Kalidindi M, Shahid A, Odejinmi F. Expect the unexpected: the dilemmas in the diagnosis and management of interstitial ectopic pregnancy—case report and literature review. *Gynecol Minim Invasive Ther.* 2016;5(1):35–37. <http://dx.doi.org/10.1016/j.gmit.2015.09.006>.