

Giant scrotal fibrolipoma

Ioannis Mykoniatis,¹ Linda Metaxa,²
Vasilios Nikolaou,¹ Chrysa Filintatzi,³
Dimitrios Kikidakis,¹ Petros Sountoulides¹

¹Urology Department, General Hospital of Veria; ²Radiology Department, AHEPA University Hospital, Thessaloniki; ³Pathology Laboratory, General Hospital of Veria, Greece

Abstract

Fibrolipoma, an infrequent histological subtype of lipoma, is considered a benign mesenchymal neoplasm. Fibrolipoma of the scrotum is an even more rare entity. We report a case of a 55-year-old male complaining for a slow-growing, painless mass in his left hemiscrotum. Imaging with ultrasonography and magnetic resonance imaging was inconclusive regarding the nature of the tumor and the tumor was excised, sparing the testis. The surgical specimen was a well-defined, yellowish white, solid, and firm mass, measuring 19.5×7×5 cm. There was no cytological atypia or mitosis and no lipoblasts recognized. On immunohistochemistry, MDM2 and CDK4 were not expressed. The histopathology report was fibrolipoma of the scrotum. To the best of our knowledge, this is only the fourth case of fibrolipoma originating from the scrotal components, spermatic cord or testis that has been reported in the English literature.

Introduction

Fibrolipoma is an extremely rare benign tumor. It is classified as a benign mesenchymal tumor of the paratesticular structures, with main representatives of this category being the lipoma, the leiomyoma, the lymphangioma and the hemangioma.¹

Herein we report a rare case of scrotal fibrolipoma presenting as a slow-growing, painless mass.

Case Report

A 55-year-old male was referred to our department for a palpable, slow-growing, painless mass in his left hemiscrotum. The patient admitted that the mass had progressively increased in size during the last 6 years without however causing pain or other symptoms. The patient's medical history was significant

for BPH and diabetes mellitus. At clinical examination, a painless, large, solid, mass was palpated in the left hemiscrotum extending to the perineal region, without being clearly distinguished on palpation from the surrounding scrotal components. The inguinal lymph nodes were not palpable. Laboratory tests were normal and serum markers for testicular cancer (β -HCG, AFP, LDH) were within normal limits.

Ultrasonography showed a large (5×6 cm), hyperechoic scrotal mass separated from the ipsilateral testis. A pelvic magnetic resonance imaging (MRI) was scheduled in order to better define the nature of the mass. MRI confirmed the presence of a mass in the left hemiscrotum extending up to the base of the corpus cavernosum. The mass showed a high T1 signal intensity characteristic of fat-containing tumors (both benign and malignant) and was clearly separated from the ipsilateral testicle. The signal intensity was heterogeneously high in T2 sequences as well (Figures 1 and 2). The finding was considered indicative of a benign tumor with the differential diagnosis also including a liposarcoma of the scrotum. A routine chest X-ray was normal and the patient having been informed about the, albeit small but present, possibility of malignancy agreed to undergo surgical exploration of the scrotum and excision of the mass.

An inguinal incision extending into the left hemiscrotum was carried out and the scrotum was entered revealing a solid vascularized mass. The mass was remote from the testis and epididymis and was completely extirpated with relative ease from the adjacent structures sparing the testis and epididymis. The patient's postoperative course was uneventful and he was discharged on the 2nd postoperative day. He is healthy and free from local relapse at 6 months.

Macroscopically, the specimen consisted of a well-defined, solid, yellowish white, mass, 19.5×7×5 cm in dimensions, surrounded by a thin fibrous capsule. Under microscopy, the presence of mature adipocytes among fibrous substrate was evident (Figure 3). No cellular atypia, mitotic activity, lipoblasts, or necrosis was observed. No smooth muscles were recognized using the Azan stain. In immunohistochemistry the tumor cells were negative for desmin, α -smooth muscle antigen, p53 protein, CD34, MDM2 and CDK4.

The pathology report was fibrolipoma with extensive mucoid degeneration.

Discussion

Primary paratesticular tumors are rare, accounting for merely 7% to 10% of all intrascrotal masses.¹ Among malignant tumors, the most common histotype is liposar-

Correspondence: Petros Sountoulides, Agiou Evgeniou streey, 55133, Thessaloniki, Greece. Tel.: +30.694.469.6849. E-mail: sountp@hotmail.com

Key words: Fibrolipoma; scrotum; testis.

Contributions: the authors contributed equally.

Conflict of interest: the authors declare no potential conflict of interest.

Received for publication: 9 April 2015.

Revision received: 16 July 2015.

Accepted for publication: 18 July 2015.

This work is licensed under a Creative Commons Attribution NonCommercial 3.0 License (CC BY-NC 3.0).

©Copyright I. Mykoniatis et al., 2015
Licensee PAGEPress, Italy
Rare Tumors 2015; 7:6001
doi:10.4081/rt.2015.6001

coma (46.4%), followed by leiomyosarcoma (LMS, 20%).² Fibrolipoma is one of the most infrequently reported histological subtypes of lipoma and is characterized by the presence of prominent bundles of mature fibrous tissue traversing the fatty lobules.²

Intrascrotal tumors provide a diagnostic challenge for urologists. A thorough history, physical examination and the use of imaging techniques are keys to the diagnosis. In cases of paratesticular masses, as the one in our case, ultrasonography is very helpful in identifying the location of the mass in relation to the scrotal components but not so for distinguishing benign from malignant lesions.³ Although ultrasound remains the imaging modality of choice, MRI is helpful in resolving dilemmas found at U/S and narrowing the differential diagnostic range. At the end of the day however, surgical excision of the mass followed by microscopy and immunohistochemistry of the tumor will provide the definite diagnosis.

Regarding the clinical features of the tumor, in our case the benign nature of the mass was highly probable as benign scrotal lesions usually present as slowly enlarging, asymptomatic or mildly symptomatic, palpable but not fixed masses. On the contrary, malignant tumors of the scrotum are more likely to grow large in months or even weeks.

Lipoma is the most common benign tumor of the paratesticular area, usually arising from the spermatic cord. Liposarcoma should be considered in the differential diagnosis in the case of rapid growth of a tumor exceeding 10 cm.⁴ In the case presented, although imaging was informative regarding the origin and the non-invasive behavior of the tumor, it proved inaccurate in excluding the presence of

liposarcoma. By and large, a liposarcoma is depicted on ultrasound as a hyperechoic, solid, usually large extratesticular mass although its sonographic features can be variable and non-specific.⁴ MRI is certainly more accurate with fat being easily recognized, although one should keep in mind that it may be difficult to

differentiate low grade liposarcoma from benign lipoma based solely on MRI findings.⁵ Although lipoma is readily identified on MRI, owing to its characteristic signal intensity, high and low on T1 and fat-suppressed T1-weighted images respectively,⁶ in our case MRI was not helpful in differentiating between

fibrolipoma and liposarcoma.

The final diagnosis therefore rests on the histopathological examination. Our case differs from classic lipoma since the tumor was composed of both adipose tissue (35%) and collagenous fibrous tissue (65%) as in the case described by Terada *et al.*⁷ The possibility of a well-differentiated liposarcoma was excluded due to the absence of cellular atypia, mitotic activity, necrosis and invasion. Moreover the absence of lipoblasts combined with the negative expression of MDM2 and CDK4 on immunohistochemistry were strongly suggestive of a benign tumor and not a liposarcoma.^{7,8}

Regarding the natural history of fibrolipomas, although histologically benign, postoperative follow-up is suggested.

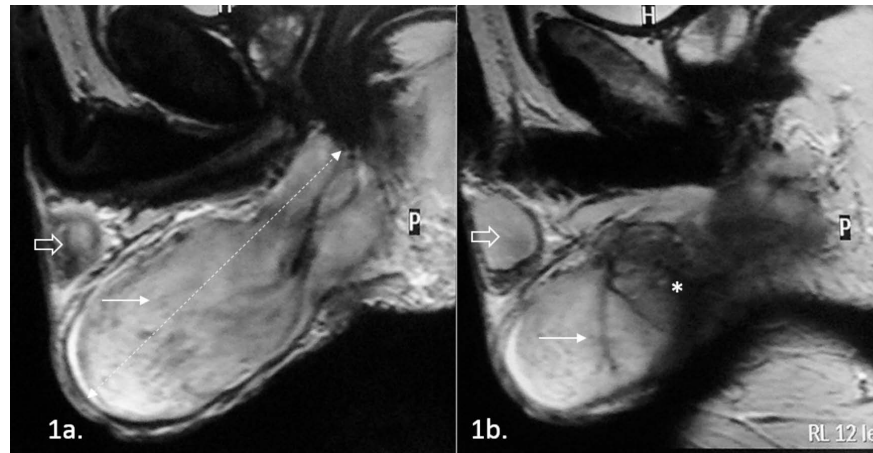


Figure 1. Magnetic resonance imaging of the scrotum. The T2-TSE images, in sagittal plain, show the extension of the mass (arrow) from the base of the corpus cavernosum posteriorly, to the posterior-inferior edge of the left testicle (open arrow). The mass demonstrates a heterogeneously high T2 signal intensity, surrounded by a thin low signal intensity capsule and is clearly separated from the ipsilateral testicle (open arrow). Although the capsule seems intact, the mass is not clearly distinguished from the posterior scrotal structures (*).

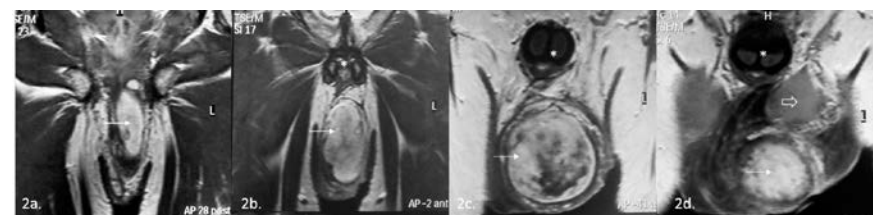


Figure 2. Magnetic resonance imaging of the scrotum. The T1-TSE images, in coronal plain, show a solid, lobulated mass (arrow) in the left hemiscrotum extending from the base of the corpus cavernosum (*) posteriorly, to the posterior-inferior edge of the left testicle (open arrow). The mass demonstrates a heterogeneously high T1 signal intensity, surrounded by a thin low signal intensity capsule and is clearly separated from the ipsilateral testicle (open arrow). The high T1 signal intensity is characteristic of fat-containing tumors (both benign and malignant).

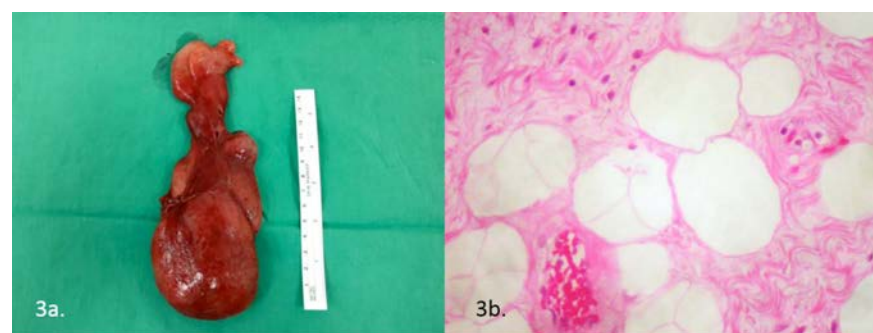


Figure 3. a) Gross appearance of the surgical specimen. The tumor measures 19.5x7x5 mm, and is covered by a thin fibrous capsule. b). Microscopic appearance of the tumor under H&A stain. The tumor is composed of mature adipose and collagenous fibrous tissue.

Conclusions

Scrotal fibrolipomas are extremely rare, benign paratesticular tumors. To our knowledge the case described here is the fourth scrotal fibrolipoma that has been reported in the literature.^{7,9,10} Surgical excision is the treatment of choice. There is no evidence that scrotal fibrolipomas differ in terms of management and prognosis from other variants of lipoma.

References

- Galosi AB, Scarpelli M, Mazzucchelli R, et al. Adult primary paratesticular mesenchymal tumors with emphasis on a case presentation and discussion of spermatic cord leiomyosarcoma. *Diagn Pathol* 2014;6:90.
- Rodríguez D, Barrisford GW, Sanchez A, et al. Primary spermatic cord tumors: disease characteristics, prognostic factors, and treatment outcomes. *Urol Oncol* 2014;32:e19-25.
- Rosai J, ed. Tumors of adipose tissue. In: Rosai and Ackerman's surgical pathology. Vol. 2. Philadelphia: Mosby; 2004. pp 2275-2285.
- Kryvenko ON, Rosenberg AE, Jorda M, Epstein JI. Dedifferentiated liposarcoma of the spermatic cord: a series of 42 cases. *Am J Surg Pathol* 2015;39:1219-25.
- Muglia V, Tucci S Jr, Elias J Jr, et al. Magnetic resonance imaging of scrotal diseases: when it makes the difference. *Urology* 2002;59:419-23.
- Tsili AC, Giannakis D, Sylakos A, et al. MR imaging of scrotum. *Magn Reson Imaging Clin N Am* 2014;22:217-38.
- Terada T. Giant fibrolipoma of the spermatic cord. *Pathol Int* 2010;60:330-2.

8. Binh MB, Sastre-Garau X, Guillou L, et al. MDM-2 and CDK4 immunostainings are useful adjuncts in diagnosing well differentiated and dedifferentiated liposarcomas subtypes: a comparative analysis of 559 soft tissue neoplasms with genetic data. *Am J Surg Pathol* 2005;29:1340-7.
9. Huben RP, Scaff JE, Schellhammer PF. Massive intrascrotal fibrolipoma. *J Urol* 1983;129:154-5.
10. Hegele A, Olbert P, Roessler M, et al. Inguinal fibrolipoma of the spermatic cord: Discrepancy between clinical and histopathologic findings. *Urol Int* 2003;71:435-6.