


ORIGINAL ARTICLE

Spinal fixation after laminectomy in pigs prevents postoperative spinal cord injury

Emma M. H. Slot¹  | Bart de Boer² | Saskia Redegeld³ | Sander van Thoor³ | Nizar Moayeri¹ | Willem-Bart Slooff¹ | Irene A. Schaafsma⁴ | Björn Meij⁴ | Tristan P. C. van Doormaal^{1,5}

¹Department of Neurology and Neurosurgery, University Medical Center Utrecht, Utrecht, The Netherlands

²Department of Neurosurgery, Elizabeth TweeSteden Hospital, Tilburg, The Netherlands

³Brain Technology Institute, Utrecht, The Netherlands

⁴Department of Clinical Sciences, Faculty of Veterinary Medicine, Utrecht University, Utrecht, The Netherlands

⁵Department of Neurosurgery, Clinical Neuroscience Center, University Hospital Zurich, Zurich, Switzerland

Correspondence

Emma M. H. Slot, Department of Neurology and Neurosurgery, University Medical Center Utrecht, Heidelberglaan 100, 3584 CX, Utrecht, The Netherlands. Email: e.m.h.slot-4@umcutrecht.nl

Funding information

This research was supported by a research grant from ZonMw (114024064).

Abstract

Background: A safe, effective, and ethically sound animal model is essential for pre-clinical research to investigate spinal medical devices. We report the initial failure of a porcine spinal survival model and a potential solution by fixating the spine.

Methods: Eleven female Dutch Landrace pigs underwent a spinal lumbar interlaminar decompression with durotomy and were randomized for implantation of a medical device or control group. Magnetic resonance imaging (MRI) was performed before termination.

Results: Neurological deficits were observed in 6 out of the first 8 animals. Three of these animals were terminated prematurely because they reached the predefined humane endpoint. Spinal cord compression and myelopathy was observed on postoperative MRI imaging. We hypothesized postoperative spinal instability with epidural hematoma, inherent to the biology of the model, and subsequent spinal cord injury as a potential cause. In the subsequent 3 animals, we fixated the spine with Lubra plates. All these animals recovered without neurological deficits. The extent of spinal cord compression on MRI was variable across animals and did not seem to correspond well with neurological outcome.

Conclusion: This study shows that in a porcine *in vivo* model of interlaminar decompression and durotomy, fixation of the spine after lumbar interlaminar decompression is feasible and may improve neurological outcomes. Additional research is necessary to evaluate this hypothesis.

KEYWORDS

fixation, interlaminar decompression, medical device model, spinal cord injury

1 | INTRODUCTION

A validated and ethically sound animal model is essential for preclinical research to investigate the safety and efficacy of biotechnological solutions, such as a sealant to prevent cerebrospinal fluid (CSF) leakage after spinal surgery.

Although there are differences in the loads applied to quadrupedal spine and human spine, various animal models have successfully been used in spine research.^{1,2} Most common are dog, goat, sheep, and pig models.³⁻⁵ Depending on the aim of the study, one species may be more suitable than another.⁵ Along with factors such as housing and costs, it is important to recognize anatomical

This is an open access article under the terms of the Creative Commons Attribution-NonCommercial-NoDerivs License, which permits use and distribution in any medium, provided the original work is properly cited, the use is non-commercial and no modifications or adaptations are made.

© 2022 The Authors. *Animal Models and Experimental Medicine* published by John Wiley & Sons Australia, Ltd on behalf of The Chinese Association for Laboratory Animal Sciences

differences in the parameters of interest between species in deciding which animal model is best suited for a specific study. In sheep for instance, similarity to the human spine in gross anatomy is greatest for the thoracic and lumbar spine, whereas the trend in vertebral body height is markedly different compared to humans, as this is greatest in the cervical spine of sheep.^{6,7} The majority of surgical models in the current body of literature focus on spinal fusion.

Canine models are common for spinal fusion or laminectomy studies, of the cervical as well as lumbar spine.⁸⁻¹² On the other hand, dogs that are kept as companion animals frequently undergo spinal surgeries including laminectomies and spinal fixation for spinal disorders similar to humans.¹³ Since dogs are companions to humans, their use as experimental animals is increasingly less accepted, which complicates the use of this species.⁴

Goat models have been extensively studied for anterior cervical discectomy and fusion.¹⁴ Lumbar spinal studies in goats are less common.⁴ Lumbar spine surgery, including instrumentation, is frequently performed in sheep models. Porcine models are also often used in lumbar spine surgery, in particular for minimally invasive techniques.¹⁵⁻¹⁸ Both the ovine and porcine model have been used in intradural spinal implant studies as well.¹⁹⁻²¹ It is argued that the porcine animal model is best suited for lumbar spinal research, including implantation, spinal fusion, and instrumentation studies, because the porcine spine closely resembles the human spine, especially for the thoracic and lumbar segments.^{2,5,6} However, this does not take into account that mature pigs are more difficult to handle than some other species due to their size and specific husbandry.⁴

Other studies have shown that the porcine spine is a representative model for the human spine, and it is often used for training of surgical techniques and preclinical testing.^{2,22} However, this mostly involves instrumentation techniques (i.e., titanium low contact dynamic compression plate for anterior fusion) and minimally invasive surgery.²³ Although a porcine model is preferable for dural research,²⁴ an *in vivo* porcine model for interlaminar decompression with durotomy has not been extensively researched.

The aim of this study is to share our learning points in an *in vivo* porcine model for interlaminar decompression that was originally designed for a medical device test study.

2 | METHODS

This medical device test study was approved by the animal experiment committee (DEC) Utrecht, the Utrecht Animal Welfare Body (IVD), and the Central Animal Experiments Committee affiliated to the Dutch National Institute for Public Health and the Environment (Approval No. AVD1150020184784). The definition of the humane endpoint is reported in Supplementary Material I. The authors followed the ARRIVE guidelines.

2.1 | Original study design

Eleven female Dutch Landrace pigs, with a mean (\pm standard deviation [SD]) body weight of 78.3 (\pm 4.5) kg underwent interlaminar decompression, followed by durotomy and closure of the dura with sutures. Mean body weight at the end of the study was 78.4 (\pm 3.0) kg. No inclusion or exclusion criteria were applied. The pigs were randomized into 2 groups and, in addition to sutures, the experimental group ($n = 8$) received a dura sealant patch (DSP), whereas the control group ($n = 3$) did not. Randomization was performed using sealed envelopes. We did not control for confounders. The animals were housed in groups in a dedicated animal laboratory facility and were acclimatized for at least 7 d preoperatively. Two neurosurgeons (T.P.C. vD. and B. dB.) performed the surgeries between November 2018 and May 2019. The surgeons were blinded to group allocation until directly after dural closure.

2.2 | Anesthesia and surgical procedure

The surgical procedure and MRI were performed under general anesthesia. Intravenous midazolam (0.2 mg/kg) and ketamine (10 mg/kg) were used as premedication, after which anesthesia was induced with thiopental (3–8 mg/kg) and atropine (0.05 mg/kg). Propofol (4.5 mg/h) and remifentanyl (0.0066 mg/h) intravenously were used for continuous sedation.

The animal was positioned in ventral recumbency. A routine approach was made to the dorsal thoracolumbar spine. Pigs have a variable number of thoracic vertebrae. Therefore, the upper level was defined as the last thoracic vertebrae-L1.²⁵ Interlaminar decompression (ILD) was performed at the lumbar spine (Figure S1A,B, Supplementary Material II). An interlaminar opening of 2 cm (length) \times 1 cm (width) (minimum) was made by partially removing the spinous processes, laminae, and the ligamentum flavum. A durotomy of 1.5 cm was made on all operated levels throughout the study. The dura was sutured with coated polyglactin 910 (Vicryl 5.0 RB 1 Plus, Ethicon, Somerville, USA) at all operated levels in all control

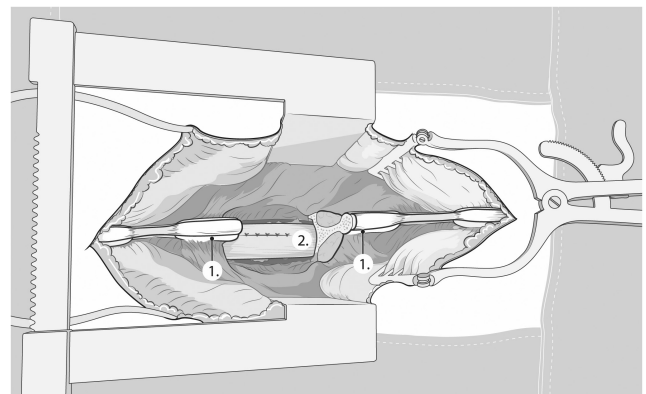


FIGURE 1 Intraoperative dorsal view of ILD at one level (L1-2), showing sutured durotomy. 1, spinous process; 2, dura mater. Scientific illustration by Amanda Gautier

and experimental animals. The DSP (length 2 cm × width 1 cm) was applied on all operated levels in all experimental animals. Figure 1 shows an image of the surgical model.

ILD and durotomy were performed at 3 levels for pigs 1–4 (last thoracic vertebrae–L1, L1–2, L3–4, L5–6, L5/6–S1). Due to advancing insights based on the postoperative outcome, the procedure was adapted for animals 5–11. The number of levels of ILD and durotomy was reduced to 2 levels for pigs 5 and 6 (L3–4 and L5–6 and L2–3 and L4–5, respectively) and 1 level for pigs 7–11 (L4–5, L5–6, L1–2, L2–3, and L3–4, respectively).

The DSP was applied on all operated levels in experimental animals: pigs 1, 2, and 4 (9 levels), pig 6 (2 levels), pigs 7 and 8 (2 levels), and pigs 9 and 11 (2 levels) (Figure S1D, Supplementary Material II). Pigs 3 (3 levels), 5 (2 levels), and 10 (1 level) served as control animals and did not receive a DSP.

Further adaptations were made for animals 7–11. In pigs 7–11, a low vacuum wound drain (wound drainage system 40 ml CH6, Medinorm GmbH, Spiesen-Elversberg, Germany) was introduced following ILD, durotomy, and application of the DSP. The wound drain was kept in place for at least 1 d until it was no longer productive, with a maximum of 3 d postoperatively. In pigs 9–11, the spine was stabilized using 2 14.5-cm Lubra plates (Veterinary Orthopedic Implants Inc, St. Augustine, USA) (Figure 2A) and complementary screws 0.75 inch (Veterinary Orthopedic Implants Inc, St. Augustine, USA) (Figure 2B). Figure 3 shows an intraoperative view of the application of the Lubra plates (Figure S2, Supplementary Material II shows operative view before and after application of the Lubra plates). All products used during the procedure are reported in Supplementary Material II (Table S1).

2.3 | Postoperative procedures

After surgery, the pigs were housed solitary in stables. Clinical observations were performed daily by trained laboratory animal caretakers in consultation with the veterinarian. Observations were noted on a standardized scoring list (Supplementary Material III). This scoring list was created to collect the outcomes for the medical device test study for which this model was originally used. If neurological deficit was observed, an explanation of the observed deficit was reported.

Postoperatively, the pigs received 1 dose of 0.4 mg/kg meloxicam (Metacam, Boehringer Ingelheim, Ingelheim am Rhein,

Germany) intramuscularly or intravenously for the first 3 d. Oral antibiotic treatment amoxicillin/clavulanic acid (Synulox, Pfizer Animal Health, Louvain-la-Neuve, Belgium) 1 dose of 10 mg/kg daily as well as local antibiotic treatment with neomycine/procaine benzylpenicillin (Neopen, Intervet Productions, Aprilia, Italy): 100 mg/ml at the intravenous access and surgical wound was administered for 7 d.

2.4 | Magnetic resonance imaging

Before termination, MRI was performed under anesthesia using a Philips Ingenia 1.5T MRI scanner (Philips, Eindhoven, the Netherlands). The pigs were positioned in sternal recumbency, and the following sequences of the thoracic and lumbar spinal axis were performed: T1-weighted (T1W), T2W, flair, and T1W with contrast. A board-certified veterinary radiologist (I.S.), blinded for group allocation, evaluated the MRI for signs of spinal cord compression (SCC) and myelopathy.

The dorsal to ventral diameter of the normal spinal cord closest to the cranial section of maximum compression was measured on transverse T2W images. Also, the dorsal to ventral diameter of the spinal cord at the level of maximum compression was measured. The degree of SCC was calculated as normal spinal cord dorsal to ventral diameter minus spinal cord diameter at maximum compression divided by normal spinal cord diameter multiplied by 100%.²⁶ The severity of compression was defined as follows: no compression: 0%; mild: <25%; moderate: 25%–50%; and severe: >50%.²⁷ At the level

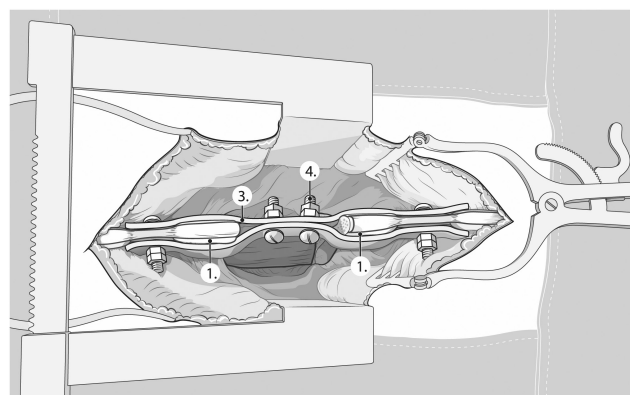


FIGURE 3 Intraoperative dorsal view of 2 Lubra plates applied to the lumbar spine after ILD. 1, spinous process; 3, Lubra plate; 4, screw. Scientific illustration by Amanda Gautier



FIGURE 2 (A) Lubra plate 14.5 cm with holes to accommodate screw placement and (B) screw, washer, and nut for Lubra plates (0.75 inches long), retrieved from: <https://voieurope.com/lubra-plates-medium-pair-14cm/> and <https://voieurope.com/screw-with-washer-nut-for-lubra-plates-3-4-inch-long/>

of the conus medullaris, the measurement was not performed because the natural anatomical diameter of the spinal cord decreased at this location.

Indication of spinal cord myelopathy was evaluated by measuring the trajectory length of hyperintensity of the spinal cord parenchyma (lesion[s]) on sagittal T2W images in millimeter (mm) at each operated level. The length of the vertebral body L5 was measured from cranial endplate to caudal endplate in mm. The extent of the lesion(s) was defined as the ratio between the length of the lesion(s) (hyperintensity on sagittal T2W images) and the length of the vertebral body L5.²⁸

Directly after MRI, the animals were euthanized with an overdose of pentobarbital 220 mg/kg (Euthanimal 40%, Alfasan, Woerden, Netherlands) at day 7 (± 1) postoperatively. A humane endpoint allowed for earlier termination.

3 | RESULTS

3.1 | Clinical outcome

Six out of 11 animals had neurological deficits postoperatively (Table 1). In the animals operated on 3 levels (1–4), 3 out of 4 had neurological deficits postoperatively. Pig 1 had complete paralysis of the hind legs and pigs 2 and 4 severe paresis of the hind legs. These animals were terminated before the study end because the humane endpoint was reached. Pig 3 recovered without postoperative complications.

The subsequent 2 animals (5–6) were operated on 2 levels. Pigs 5 and 6 suffered from paresis of the hind legs with ability to stand and walk with support. In animals 7 and 8, ILD was performed on one level and a wound drain was added to the surgical protocol to reduce compression of the spinal cord by postoperative edema and wound fluid. Delayed paresis of the hind legs was present in pig 7 at day 6. Pig 8 recovered well and returned to normal ambulation.

The final 3 animals (9–11) were operated on 1 level with a wound drain and fixation of the spine by Lubra plates. These animals all recovered well and returned to normal ambulation. Blood analysis and figures of the surgical wounds are presented in Supplementary Material II (Table S2 and Figure S3, respectively).

3.2 | MRI outcome

Severe SCC was present in 2 animals (8, 9) (Figure 4). Moderate compression of the spinal cord was present in 7 animals (1–3, 5–7, 10) (Figure 4, Table 1). The remaining 2 animals (4 and 11) had mild compression (Table 1). Evidence of myelopathy (hyperintensity of the spinal cord parenchyma on T2) was seen on MRI in all animals (Table 1). The mean lesion-length-to-vertebral-length ratio was 1.9 (range 0.7–3.3). The 4 highest lesion-length-to-vertebral-length ratios were found in the 4 out of 6 animals with neurological deficits (Table 1). The Lubra plates and fixation material dorsal to the spinal

canal allowed sufficient visualization of the spinal cord and dura mater on MRI. The figures of the MRIs of all animals are included in Supplementary Material IV (Figures S1–S4).

4 | DISCUSSION

This article describes the learning curve of using a porcine spinal model with interlaminar decompression to test spinal medical devices. It was noted that fixation of the spine in a porcine *in vivo* model is feasible and may prevent neurological deficits. A total of 6 animals that had not received spinal fixation after decompressive laminectomy developed neurological deficits postoperatively, whereas none of the animals in which the spine was fixated showed postoperative neurological deficits.

To our knowledge, no other *in vivo* studies have reported multilevel decompressive surgery in a porcine model. The high body weight of the pig model may be a predisposing factor to the assumed increased mobility of the spine after laminectomy, since a similar multilevel laminectomy model in dogs was not complicated by neurological deficits.^{12,14} Interlaminar decompression on multiple levels potentially destabilizes the porcine spine in an *in vivo* model, with severe neurological deficits as a result. Postoperative X-ray imaging of the spine to confirm this theory was, however, not performed in this study. Also, it remains inconclusive from the current study whether stability of the spine is maintained if ILD is restricted to one level, and if ILD is performed on multiple levels with fixation.

Spinal instability after decompressive surgery is a well-known problem, and various surgical techniques have been developed to reduce destabilization. A biomechanical study in an *ex vivo* porcine model concluded that intervertebral displacement of the lumbar spine after laminectomy on one level is greater compared with bilateral laminotomy.²⁹ Another study in an *ex vivo* porcine model showed that overall stability after muscle-preserving ILD on one level can be maintained.³⁰ A recent *in vivo* study to test an intradural spinal cord stimulation device in pigs showed successful recovery of 6 animals after simple one-level laminectomy.¹⁹ These results indicate that stability of the spine could be maintained after decompressive surgery on one level without fixation.

ILD on multiple levels with fixation of the spine has not been performed in this study, it is thus uncertain if surgery on multiple levels with fixation would be safe. The first 6 animals had interlaminar decompression on multiple levels (2 or 3), which resulted in neurological deficits in 5 out of 6 animals. Subsequently, 2 animals were operated on one level, yet neurological deficits occurred in one of these animals as well. Therefore, we performed an ILD on one level with fixation of the spine with Lubra plates in the last 3 animals, which all recovered without deficits. No intraoperative complications occurred throughout the study. It was, however, apparent during the surgery that the durotomy led to severe decompression of the spinal cord. Although hemostasis was achieved during surgery, we believe the decompression of the spinal cord to

TABLE 1 Overview of study design and clinical outcome in 11 pigs that underwent lumbar interlaminar decompression (ILD), durotomy, and dura sutures

Pig #	Levels ILD	DSP	Wound drain	Fixation	Neurological deficits	Termination (d)	Maximal degree of SCC on MRI	Maximal SCC on MRI (%)	Lesion length (mm)	Lesion length to vertebral length ratio
1	3	Yes	No	No	Paralysis both hind legs	3 ^a	Moderate	L1-2: 27 L3-4: 8 L5-6: 17	L1-2: 52 L3-4: 29 L5-6: 26	3.2
2	3	Yes	No	No	Paralysis both hind legs	1 ^a	Moderate	T-L1: 10 L3-4: 7 L5-6: 28	T-L1: 37 L3-4: 20 L5-6: 16	2.2
3	3	No	No	No	None	8 ^b	Moderate	T-L1: 27 L3-4: 8 L5-S1: NA	T-L1: 38 L3-4: 0 L5-S1: 0	1.2
4	3	Yes	No	No	Severe paresis both hind legs, not ambulatory	4 ^a	Mild	T-L1: 4 L3-4: 20 L6-S1: NA	T-L1: 21 L3-4: 40 L6-S1: 0	1.9
5	2	No	No	No	Paresis both hind legs, ambulatory	6	Moderate	L3-4: 34 L5-6: 37	L3-4: 85 L5-6: 17	3.1
6	2	Yes	No	No	Paresis both hind legs, ambulatory	6	Moderate	L2-3: 39 L4-5: 31	L2-3: 72 L4-5: 33	3.3
7	1	Yes	Yes	No	Delayed paresis of hind legs (day 6), ambulatory	7	Moderate	L4-5: 38	L4-5: 32	0.9
8	1	Yes	Yes	No	None	7	Severe	L5-6: 62	L5-6: 25	0.7
9	1	Yes	Yes	Yes	None	7	Severe	L2-3: 56	L2-3: 64	2.0
10	1	No	Yes	Yes	None	7	Moderate	L1-2: 43	L1-2: 58	1.8
11	1	Yes	Yes	Yes	None	7	Mild	L3-4: 22	L3-4: 34	1.0

Abbreviations: DSP, dura sealant patch; NA, not applicable; SCC, spinal cord compression.

^aClinical condition on day of termination, as this was prior to day 7 due to reaching the humane endpoint.^bAnimal was terminated 1 d later to allow termination of the next animal in which the humane endpoint was reached.

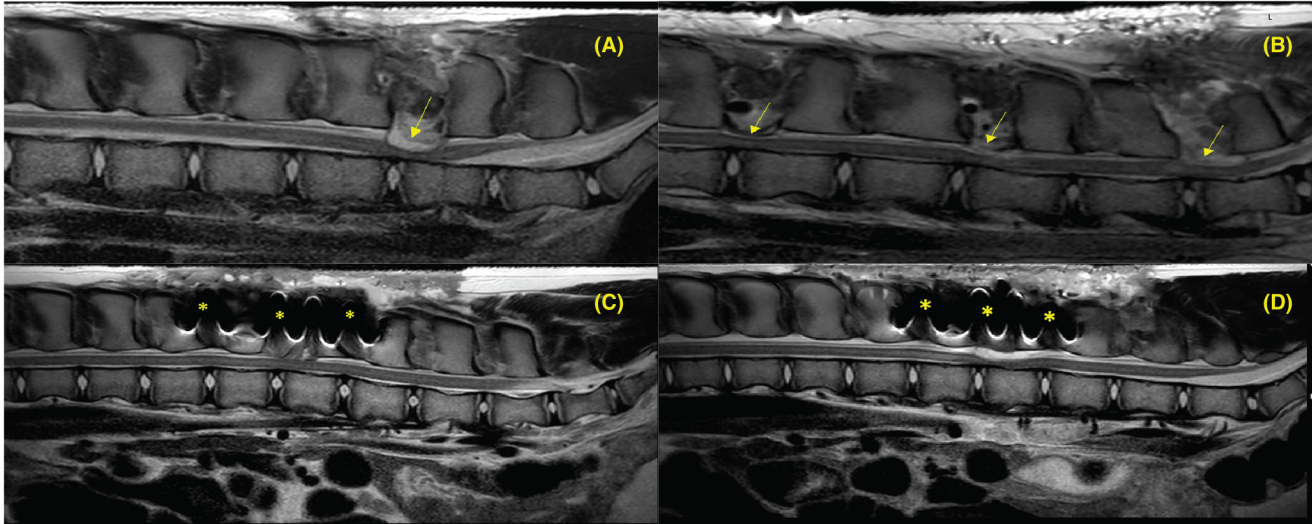


FIGURE 4 (A) Postoperative MRI of the spine (pig 7) showing significant compression (arrow) of the spinal cord at level L4-5. (B) Postoperative MRI of the spine (pig 1) showing compression (arrows) of the spinal cord at the 3 operated levels, that is, last L1-L2, L3-4, and L5-L6. (C, D) Postoperative MRI of the spine (pigs 9 and 10) showing moderate compression on the operated level, L2-3 and L1-2, respectively. Artefacts (*) due to the screws used for fixing the Lubra plates still facilitate assessment of the spinal cord and dura

have increased the risk for epidural hematoma postoperatively. The extent of compression was variable across animals operated on one or multiple levels and with and without fixation and did not seem to correspond well with neurological outcome. This is consistent with a previous study that found no association between SCC estimated on MRI and pre- or postoperative neurological status.²⁶ Thus, it may be hypothesized that the spinal cord injury occurred immediately after surgery when the animals awakened and tried to stand and walk, while their core spinal muscles were not completely functional. This may have resulted, also due to their high body weight, in vertebral subluxations at the laminectomy sites injuring the spinal cord and evoking myelopathy. Once the core spinal muscles regained their full tension, the spinal segment at the laminectomy site was stable again, leaving no evidence of spinal instability on MRI but resulting in myelopathy in all animals. Findings on MRI of hyperintensity of the spinal cord parenchyma on T2 in all animals confirmed this hypothesis. Since animal activity after surgery varied, this may have been one of the contributing factors to varying spinal cord compression on MRI. A study in dogs with presumed ischemic spinal myelopathy²⁸ showed that a lesion-length-to-vertebral-length ratio of >2.0 is 100% sensitive to predict unsuccessful neurological outcome. In our study, 4 out of 6 pigs with neurological deficit had ratios >2.0 , whereas none of the animals without neurological deficit had ratios >2.0 . The pigs with fixation of the spine showed a lesser (mean lesion-length-to-vertebral-length ratio 1.6 vs. 2.0 in animals without fixation) extent of spinal myelopathy. The measurements of the length of hyperintensity of the spinal cord parenchyma on T2-weighted images are likely susceptible for high interobserver variability as the transition from normal to abnormal spinal cord tissue is poorly defined.

Another factor that may have contributed to improved neurological outcome is the use of a wound drain. A wound drain was left in

place for at least 24 h in the last 5 animals, which reduces compression of the spinal cord caused by postoperative edema and wound fluid.

Although the biomechanical aspects of the native spine in quadrupeds have been studied in a previous study and did not seem to be different from the biomechanics of bipeds,⁵ the situation may be different for the quadruped spine after laminectomies. For this, experience is available in the veterinary literature, especially studies in dogs that undergo surgical procedures similar to humans for spinal disorders. Dogs that present with spinal lumbar fractures and spinal column instability after high impact forces (hit by car or fall from a height) are effectively treated by spinal fixation with Lubra plates to restore spinal stability, allow fracture healing, and prevent secondary spinal cord injury.³¹ The Lubra plates that were used in this study were also obtained from a veterinary company specialized in implants for companion animals. Fixation of the spine with pedicle screws and connecting rods has been performed successfully in canines,³² however, the Lubra plates allowed better postoperative imaging of the dura, which was necessary for the medical device test study this model was intended for. Furthermore, their limited availability for animal use and the high costs of human implants make this technique less suitable for a medical device test model.

Whilst our initial medical device study could not be completed as planned, the present study does lay the foundation for future porcine model studies for medical device testing. We have adapted the surgical technique according to the clinical outcomes and developed a feasible surgical porcine model. Furthermore, housing, handling, availability, and societal acceptance of this species in research are favorable. Especially, the latter is an advantage over the use of a canine model for this purpose.

This study was limited by several factors. Firstly, this study was not designed to compare the neurological outcomes of different

surgical techniques. Multiple factors have been altered throughout the study based on advancing insights to protect postoperative animal welfare, as directed by the national ethical standards for animal experiments. Postoperative imaging was not included in the working protocol to evaluate the surgical technique (i.e., no X-ray was performed to assess spinal instability). Furthermore, 2 animals (3 and 8) operated without fixation of the spine (one on multiple levels, another on one level) recovered without neurological deficit. Therefore, no definitive conclusions can be made based on these results. Secondly, a small number of animals were operated with fixation of the spine by Lubra plates. As the surgical protocol was altered throughout the study, the spine was fixated with Lubra plates in the final 3 animals only. ILD on multiple levels with fixation of the spine has not been performed in this study, it is thus uncertain if surgery on multiple levels with fixation would be safe. Similarly, we only performed ILD on one level without fixation of the spine in 2 animals. Lastly, there was insufficient financial support to continue this study to further compare surgical techniques or the clinical outcomes related to the medical device this study was initially designed to test for.

This porcine model for ILD with fixation of the spine provides a useful basis for further preclinical research into the development of innovative surgical devices. In addition, sharing the lessons learned throughout the current study may contribute to reducing unnecessary animal suffering and research. Further research, with a larger sample size, is necessary to evaluate our hypothesis that fixation of the spin in a porcine *in vivo* model of interlaminar decompression and durotomy improves neurological outcomes.

5 | ACKNOWLEDGMENTS

None.

CONFLICT OF INTEREST

T.P.C. van Doormaal is a consultant for Polyganics B.V.

AUTHOR CONTRIBUTIONS

Study Design: TvD, SR, SvT, BM, ES. Data collection: SR, SvT, ES. Surgery/surgical consultation: TvD, BdB, NM, WS, BM. Radiology assessment: IS. First draft of the manuscript: ES. All authors reviewed and approved the final version of the manuscript.

ETHICS APPROVAL

This study was approved by the animal experiment committee (DEC) Utrecht, the Utrecht Animal Welfare Body (IVD), and the Central Animal Experiments Committee affiliated to the Dutch National Institute for Public Health and the Environment approved this study (Approval No. AVD1150020184784).

DATA AVAILABILITY STATEMENT

The video recordings of the surgical procedures performed in this study are available upon reasonable request.

ORCID

Emma M. H. Slot  <https://orcid.org/0000-0002-4296-1331>

REFERENCES

1. Aziz HN, Galbusera F, Bellini CM, et al. Porcine models in spinal research: calibration and comparative finite element analysis of various configurations during flexion-extension. *Comp Med*. 2008;58(2):174-179.
2. Busscher I, Ploegmakers JJW, Verkerke GJ, Veldhuizen AG. Comparative anatomical dimensions of the complete human and porcine spine. *Eur Spine J*. 2010;19:1104-1114.
3. Wilke HJ, Kettler A, Lutz C. Are sheep spines a valid biomechanical model for human spines? *Spine*. 1997;22(20):2365-2374.
4. Drespe IH, Polzhofer GK, Turner AS, Gauer JN. Animal models for spinal fusion. *Spine J*. 2005;209S-216S.
5. Smit TH. The use of a quadruped as an *in vivo* model for the study of the spine- biomechanical considerations. *Eur Spine J*. 2002;11:137-144.
6. Sheng SR, Wang XY, Xu HZ, Zhu GQ, Zhou YF. Anatomy of large animal spines and its comparison to the human spine: a systematic review. *Eur Spine J*. 2010;19(1):46-56.
7. Wilke HJ, Kettler A, Wenger KH, Claes LE. Anatomy of the sheep spine and its comparison to the human spine. *Anat Rec*. 1997;247(4):542-555. doi:10.1002/(SICI)1097-0185(199704)247:4<542::AID-AR13>3.0.CO;2-P
8. Cook SD, Reynolds MC, Whitecloud TS. Evaluation of hydroxyapatite graft materials and canine cervical spine fusions. *Spine*. 1986;11:305-309.
9. Emery SE, Brazinski MS, Koka A, et al. The biological and biomechanical effects of irradiation on anterior spinal bone grafts in a canine model. *J Bone Joint Surg Am*. 1994;76:540-548.
10. Fuller DA, Stevenson S, Emery SE. The effects of internal fixation on calcium carbonate: ceramic anterior spinal fusion in dogs. *Spine*. 1996;21:2131-2136.
11. Smith KR, Hunt TR, Asher MA, Anderson CH, Carson WL, Robinson RG. The effect of a stiff implant on the bone mineral content of the lumbar spine in dogs. *J Bone Joint Surg*. 1991;73A:115-123.
12. Quist JJ, Dhert WJ, Meij BP, et al. The prevention of peridural adhesions. A comparative long-term histomorphometric study using a biodegradable barrier and a fat graft. *J Bone Joint Surg Br*. 1998;80(3):520-526. doi:10.1302/0301-620x.80b3.8010
13. Sharp NJH, Wheeler SJ. *Diagnosis and Surgery. Small Animal Spinal Disorders*. 2nd ed. Elsevier Mosby; 2005.
14. Zdeblick TA, Cooke ME, Wilson D, Kunz DN, McCabe R. Anterior cervical discectomy, fusion and plating. *Spine*. 1993;18(4):1974-1983.
15. Sucato DJ, Hedequist D, Zhang H, et al. Recombinant human bone morphogenetic protein-2 enhances anterior spinal fusion in a thoracoscopically instrumented animal model. *J Bone Joint Surg Am*. 2004;86-A:752-762.
16. Olinger A, Pistorius G, Lindemann W, et al. Effectiveness of a hands-on training course for laparoscopic spine surgery in a porcine model. *Surg Endosc*. 1999;13:118-122.
17. Mühlbauer M, Ferguson J, Losert U, et al. Experimental laparoscopic and thoracoscopic discectomy and instrumented spinal fusion: a feasibility study using a porcine model. *Minim Invasive Neurosurg*. 1998;41:1-4.
18. Hildebrandt U, Pistorius G, Olinger A, Menger MD. First experience with laparoscopic spine fusion in an experimental model in the pig. *Surg Endosc*. 1996;10:143-146.
19. Holland MT, Seaman SC, Woodroffe RW, et al. *In vivo* testing of a prototype intradural spinal cord stimulator in a porcine model. *World Neurosurg*. 2020;137:e634-e641. doi:10.1016/j.wneu.2020.02.100

20. Gibson-Corley KN, Oya H, Flouty O, et al. Ovine tests of a novel spinal cord neuromodulator and dentate ligament fixation method. *J Investig Surg*. 2012;25:366-374.
21. Guiho T, Azevedo Coste C, Delleci C, et al. An intermediate animal model of spinal cord stimulation. *Eur J Translat Myol*. 2016;26:150-154.
22. Regelsberger J. Surgery of the brain and spinal cord in a porcine model. In: Janowski M, ed. *Experimental Neurosurgery in Animal Models. Neuromethods*. Vol 116. Humana Press; 2016.
23. Olinger A, Vollmar B, Hildebrandt U, Menger MD. Experimental development and validation of a technique for lumboendoscopic anterior fusion of lumbar spine fractures. Comparison of endoscopic and open surgery in a live porcine model. *Surg Endos*. 2000;14:844-848.
24. Kinaci A, Bergmann W, Bleys RL, van der Zwan A, van Doormaal TP. Histologic comparison of the dura mater among species. *Comp Med*. 2020;70(2):170-175.
25. Rohrer GA, Nonneman DJ, Wiedmann RT, Schneider JF. A study of vertebra number in pigs confirms the association of vertnin and reveals additional QTL. *BMC Genet*. 2015;16:129.
26. Penning V, Platt SR, Dennis R, Cappello R, Adams V. Association of spinal cord compression seen on magnetic resonance imaging with clinical outcome in 67 dogs with thoracolumbar intervertebral disc extrusion. *J Small Animal Pract*. 2006;47:644-650.
27. Provencher M, Habin A, Moore SA, Cook L, Phillips G, da Costa RC. Kinematic magnetic resonance imaging for evaluation of disc-associated cervical spondylomyelopathy in Doberman Pinschers. *J Vet Intern Med*. 2016;30:1121-1128.
28. De Risio L, Adams V, Dennis R, McConnell FJ, Platt SR. Association of clinical and magnetic resonance imaging findings with outcome in dogs suspected to have ischemic myelopathy: 50 cases (2000–2006). *J Am Vet Med Assoc*. 2008;233(1):129-135.
29. Tai CL, Hsieh PH, Chen WP, Chen LH, Chen WJ, Lai PL. Biomechanical comparison of lumbar spine instability between laminectomy and bilateral laminotomy for spinal stenosis syndrome - an experimental study in porcine model. *BMC Musculoskelet Disord*. 2008;9:84. doi:[10.1186/1471-2474-9-84](https://doi.org/10.1186/1471-2474-9-84)
30. Hasegawa K, Kitahara K, Shimoda H, Hara T. Biomechanical evaluation of destabilization following minimally invasive decompression for lumbar spinal canal stenosis. *J Neurosurg Spine*. 2013;18:504-510.
31. Krauss MW, Theyse LFH, Tryfonidou MA, Hazewinkel HAW, Meij BP. Treatment of spinal fractures using Lubra plates. A retrospective clinical and radiological evaluation of 15 cases. *Vet Comp Orthop Traumatol*. 2012;25(4):326-331. doi:[10.3415/VCOT-11-07-0096](https://doi.org/10.3415/VCOT-11-07-0096)
32. Lewchalermwong P, Suwanna N, Meij BP. Canine vertebral screw and rod fixation system: design and mechanical testing. *Vet Comp Orthop Traumatol*. 2018;31(2):95-101. doi:[10.3415/VCOT-17-03-0040](https://doi.org/10.3415/VCOT-17-03-0040)

SUPPORTING INFORMATION

Additional supporting information may be found in the online version of the article at the publisher's website.

How to cite this article: Slot EMH, de Boer B, Redegeld S, et al. Spinal fixation after laminectomy in pigs prevents postoperative spinal cord injury. *Anim Models Exp Med*. 2022;5:153–160. doi:[10.1002/ame2.12213](https://doi.org/10.1002/ame2.12213)