

## CT Imaging of a Pancreatic Pseudocyst: Clinical and Anatomic Implications

Lisa Podgurski, Gloria Hou, and Kitt Shaffer, M.D., Ph.D.

We report the case of a 42-year-old man with a large pancreatic pseudocyst, the presence of which was not suspected upon initial presentation. This case provides an example of when imaging may be useful for the detection of pancreatitis and its complications. It also demonstrates classic pseudocyst localization to the lesser sac and left anterior pararenal space. The unusually large size of this pseudocyst provides a clear delineation of retroperitoneal fascial planes and an illustration of possible clinical consequences of mechanical obstruction by pseudocyst.

### Case Report

A 42-year-old man presented to the Emergency Department complaining of 4 days of diffuse abdominal pain and non-bilious, non-bloody vomiting in the setting of alcohol ingestion. The pain was constant in the suprapubic area and radiated superiorly throughout the abdomen. The pain was exacerbated when lying down and 30 minutes after eating. Liquids were tolerable if taken slowly. The patient

---

Citation: Podgurski L, Hou G, Shaffer K. CT Imaging of a Pancreatic Pseudocyst: Clinical and Anatomic Implications. *Radiology Case Reports*. [Online] 2007;2:107.

Copyright: © Lisa Podgurski. This is an open-access article distributed under the terms of the Creative Commons Attribution-NonCommercial-NoDerivs 2.5 License, which permits reproduction and distribution, provided the original work is properly cited. Commercial use and derivative works are not permitted.

Abbreviations: CT, computed tomography

Lisa Podgurski (Email: [lisa\\_podgurski@hms.harvard.edu](mailto:lisa_podgurski@hms.harvard.edu)) and Gloria Hou (Email: [gloria\\_hou@hms.harvard.edu](mailto:gloria_hou@hms.harvard.edu)) at Harvard Medical School, Boston, MA, USA.

Kitt Shaffer, M.D., Ph.D. (Email: [kshaffer@challiance.org](mailto:kshaffer@challiance.org)), is in the Department of Radiology, Cambridge Health Alliance and Harvard Medical School, Cambridge, MA, USA.

The authors would like to thank Dr. Janet Baum (Department of Radiology, Cambridge Health Alliance) for her generous help in editing the manuscript.

Published: December 9, 2007

DOI: 10.2484/rcr.v2i4.107

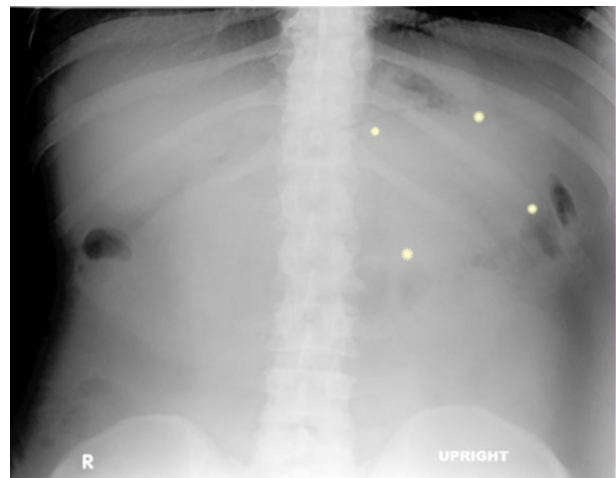


Figure 1. Upright plain film at the time of first admission. Although the image of the abdomen was unrevealing on initial read, later inspection identified the suggestion of increased gastrocolic separation in the left upper quadrant (region marked by stars). This separation between the stomach and the transverse colon is consistent with a fluid collection in the lesser sac.

## CT Imaging of a Pancreatic Pseudocyst: Clinical and Anatomic Implications

reported fevers, chills, and diaphoresis, but denied sick contacts. He drank on average 12 beers per day for the past 10 years. His last alcoholic drink was 4 days prior to presentation. His only past medical history was an episode of pancreatitis 5 years prior to this admission. He does not see a primary care physician, and takes no medications.

On physical exam, the patient was afebrile, tachycardic, and normotensive. His sclerae were anicteric, and his abdomen was large but nontender. There was no flank discoloration or ecchymosis. Neurologic exam was normal. Extremities were without edema. Laboratory investigation revealed hyponatremia, hypochloremia, an elevated lipase of 73 (normal range 10-50) and a mildly elevated AST of 77 (normal range 8-34 U/L). Amylase and ALT were within normal limits. Albumin and total protein were low. A plain film of the abdomen was read at the time as unremarkable (Figure 1). In retrospect, further scrutiny of this image suggests an increased separation between the stomach and the transverse colon, the so-called “gastrocolic separation sign,” suggesting the presence of a space-occupying lesion, which might have been interpreted as a distended stomach.

The patient was admitted overnight for electrolyte repletion and rehydration, and kept NPO while his pain persisted. He was monitored for signs of alcohol withdrawal, but exhibited only mild tremulousness. The patient’s symptoms and hyponatremia were attributed to alcohol abuse and possible pancreatitis. Repeat labs on the last hospital day showed a lipase of 70 (normal range 10-50). On discharge, he was advised to stop drinking alcohol and to advance his diet slowly.

The patient’s next contact with medical providers was two months later, when he presented to the Emergency Department with increasing abdominal distension, early satiety, generalized pruritis, decreased energy, and decreased bulk in his face and upper body, all developing over the previous 3-4 weeks. The patient had discontinued his alcohol consumption after his previous admission, both because of the doctors’ recommendation and because of a strong pain in his epigastric area radiating down to the periumbilical area when he drank. In the 4 days prior to this presentation to the Emergency Department, he had also noticed swelling in his ankles. Otherwise, he was actually starting to feel better, and had felt

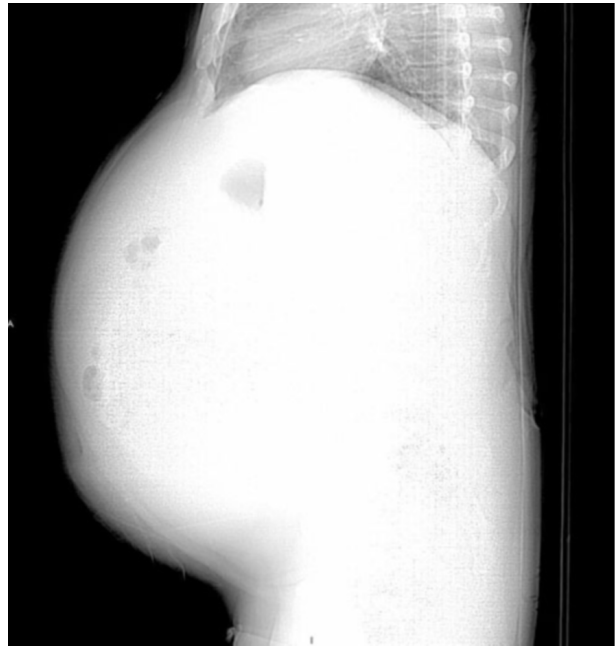


Figure 2. Scout image from the second admission. The contour of the abdomen suggests massive, tense abdominal distension.

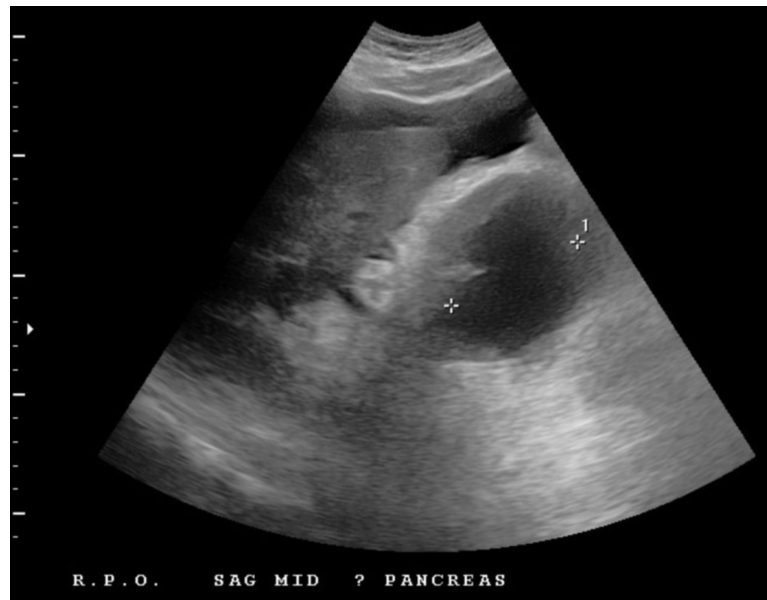


Figure 3. Ultrasound of the right upper quadrant/epigastric region demonstrates a hypochoic collection in the region of the head of the pancreas. The suggestion of a tissue wall separates this collection from the ascites fluid in the abdomen.

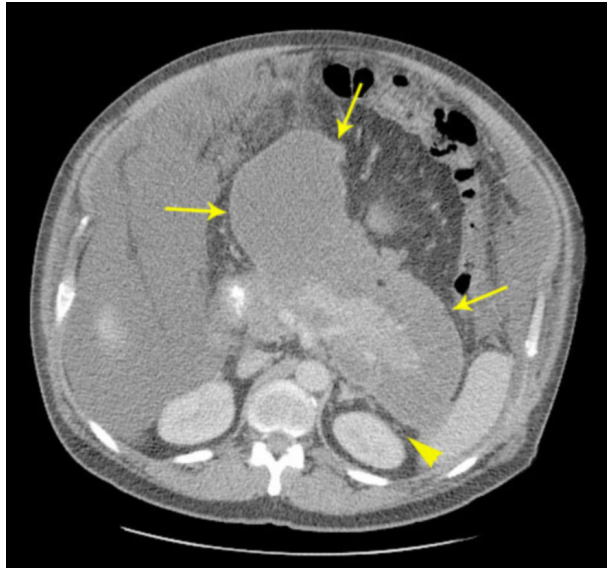


Figure 4. Axial CT slice of the upper abdomen at admission reveals pseudocyst surrounding the pancreas (area of higher attenuation). Despite the anterior spread, pseudocyst continuity with the space posterior to the pancreas confirms the retroperitoneal location of the fluid collection. Pseudocyst boundaries are indicated by thin arrows; note the thin rim suggesting a walled-off collection. The arrowhead highlights the integrity of Gerota's fascia and the perirenal fat, localizing the pseudocyst in the left anterior pararenal space in this region.

well enough to drink 5 alcoholic drinks each day in the two days preceding admission.

On exam, he was jaundiced and had a decreased physical build compared to two months prior in addition to a large tense abdomen (Figure 2). He was afebrile and slightly hypertensive. On abdominal exam, shifting dullness was present, but there was no tenderness to palpation. No palmar erythema, spider angiomas, caput medusae, or asterix was present. He had bilateral pitting edema to the knees. Laboratory findings included elevated liver enzymes, low albumin, markedly elevated alkaline phosphatase, elevated direct and total bilirubin, anemia, and thrombocytosis. Lipase was within normal limits. Of note, AST and ALT were less elevated, and albumin was higher than on previous admission, when the patient had exhibited neither abdominal distension nor lower extremity edema. Coagulation studies were within normal limits. Amylase was low, and the viral hepatitis panel was nega-

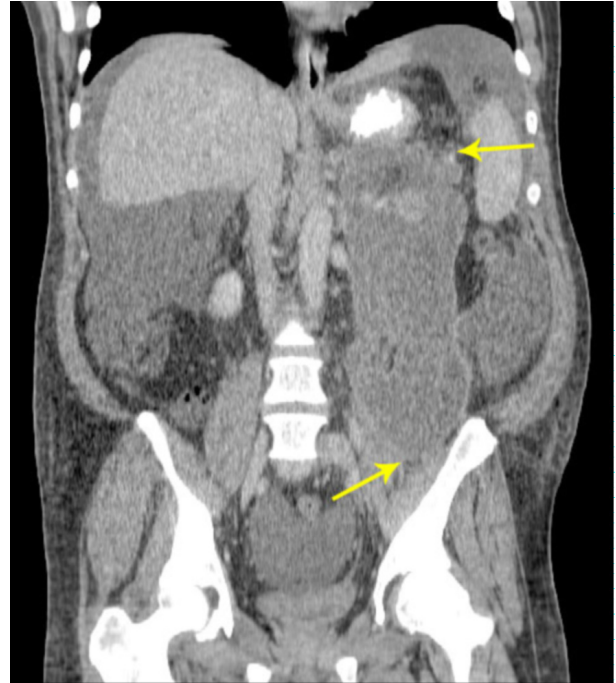


Figure 5. Coronal reconstruction, revealing the body of the pseudocyst in the left anterior pararenal space, extending from the level of the stomach down inferiorly to the iliac crest.

tive. Tumor markers AFP, CEA, and CA19-9 were within normal limits.

Ultrasound with Doppler revealed marked ascites and a poorly-visualized hypochoic cystic lesion in the region of the pancreatic head (Figure 3).

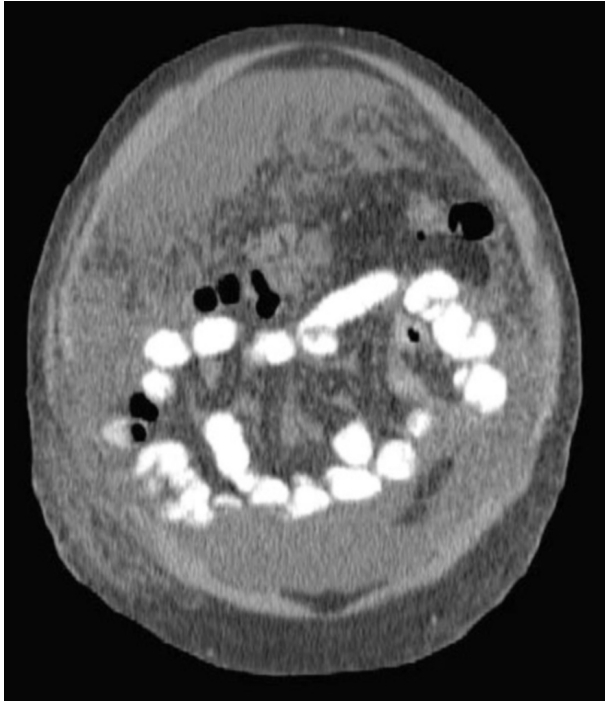
Abdominal CT showed a small liver consistent with mild cirrhosis, but no nodularity was present. CT also revealed a large peri-pancreatic cystic structure, measuring 20 by 8 centimeters in its largest anterior-posterior dimension (Figure 4) and extending from the pancreas inferiorly to the level of the iliac crest (Figure 5).

Quicktime movies of CT sagittal and coronal reconstructions (Series A and Series B) illustrated the size and orientation of this massive collection.

The pseudocyst exerted a compressive effect on the stomach (Figure 6) and on the duodenum (Figure 7).

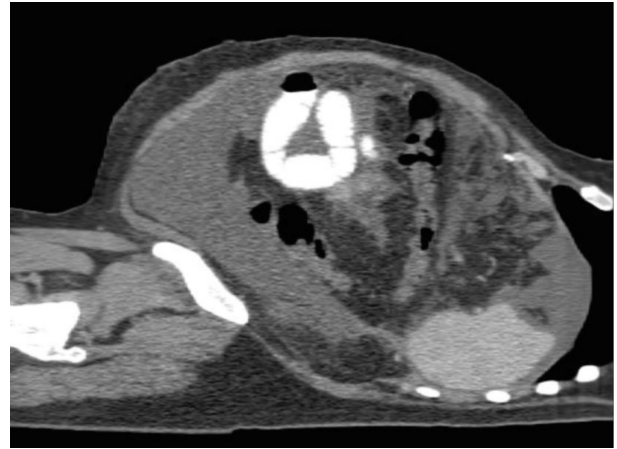
Sagittal reconstruction revealed pseudocyst distention of the lesser sac, extending anteriorly into the gastrocolic ligament (Figure 8) such that pseudocyst surrounded the stomach both anteriorly and posteriorly.

## CT Imaging of a Pancreatic Pseudocyst: Clinical and Anatomic Implications



Series A. QuickTime movie of coronally reformatted CT. Note the boundaries of the collection and the suggestion of loculations within it.

The pseudocyst was found in the left anterior pararenal space but not in the perirenal space; Figure 4 demonstrates that Gerota's fascia and the perirenal fat remain intact. Moderate left hydronephrosis was also seen; the presence of pseudocyst contiguous with the left psoas muscle was consistent with compression of the ureter in this region (Figure 9, Series C).



Series B. QuickTime movie of sagittally reformatted CT. Note the boundaries of the collection and the suggestion of loculations within it.

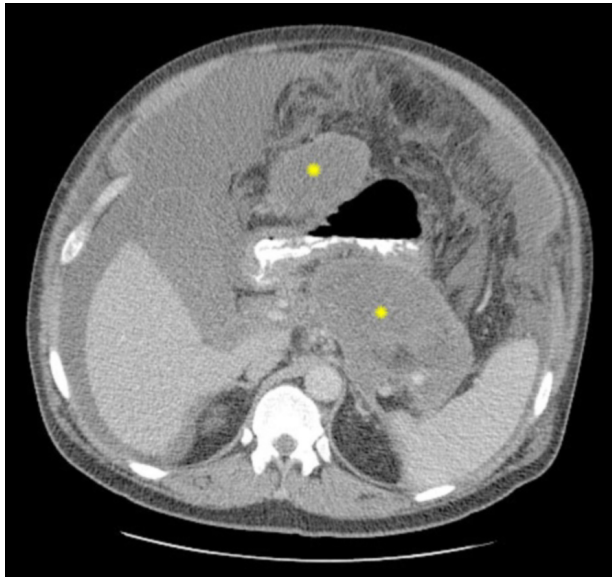


Figure 6. CT at the level of gastric emptying into the duodenum, with the pseudocyst (\*) visibly compressing the stomach anteriorly and posteriorly.

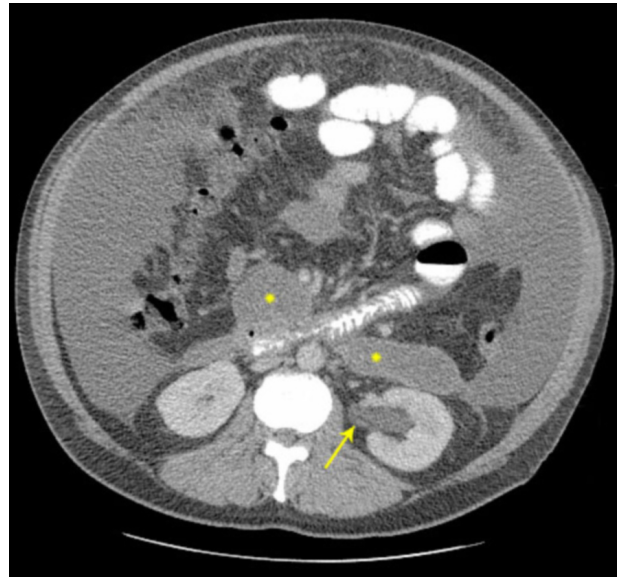


Figure 7. Continuing pseudocyst (\*) at the level of the retroperitoneal duodenum. Also note hydronephrosis at the left renal pelvis (arrow).

## CT Imaging of a Pancreatic Pseudocyst: Clinical and Anatomic Implications

Diagnostic paracentesis was conducted. Clear yellow ascitic fluid containing inflammatory cells and blood was aspirated, but the fluid was low in amylase and was sterile. CT-guided percutaneous drainage of the pancreatic cystic structure revealed a large volume of brown fluid with many red blood cells (132,000 cells/mm<sup>3</sup>) and high amylase and LDH content (244 U/L and 7,875 IU/L, respectively). These findings were consistent with a pancreatic pseudocyst. Cytologic analysis of the pseudocyst fluid did not reveal any malignant cells. After percutaneous drainage and diuresis with furosemide and spironolactone, the patient's abdominal distension (Figure 10) and lower extremity edema decreased significantly with corresponding improvement in his appetite. Prior to drainage, pseudocyst compression of the inferior vena cava was present (Figure 11).

Laboratory tests following drainage and diuresis showed improving trends in liver enzymes, bilirubin, and alkaline

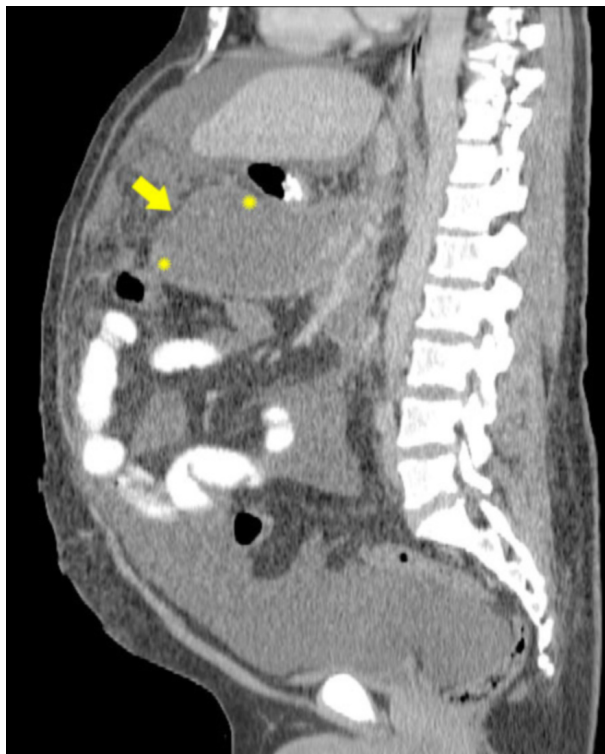


Figure 8. This sagittal CT reconstruction shows the distended lesser sac pressed anteriorly by the presence of the pseudocyst. (Arrow marks the anteriorly displaced gastrocolic ligament. Stars at the pseudocyst border demonstrate the proximity of the pseudocyst to the transverse colon inferiorly and the stomach superiorly.)

phosphatase levels. Repeat CT scan prior to discharge showed a smaller pseudocyst. At admission, the portion of the pseudocyst anterior to the pancreas measured 10.8 cm by 10.5 cm; at discharge, it measured 6.4 cm by 6.3 cm. The patient was discharged with instructions to follow up with a primary care physician and a surgeon for possible endoscopic retrograde cholangiopancreatography (ERCP) and surgical excision. Two months after discharge, he continues to feel well and denies any recent worsening of abdominal distension or lower extremity edema. He has returned to work, and denies any alcohol use at this time.

### Discussion

#### *Introduction*

Pancreatic pseudocysts are collections of fluid enclosed by fibrous wall that may arise in association with acute or chronic pancreatitis, pancreatic trauma, or pancreatic duct obstruction. Alcohol-related pancreatitis is the most common cause. Pancreatic pseudocysts usually present with upper abdominal pain aggravated by food intake and are often associated with anorexia and weight loss [1]. Our patient's symptoms, history of alcoholism, and chronology (worsening symptoms 4 weeks after an episode of pancreatitis) were all typical for pancreatic pseudocyst.

It is important to rule out pancreatic necrosis before diagnosing a pseudocyst since the solid debris found in pancreatic necrosis frequently leads to failed endoscopic attempts at drainage as well as secondarily infected collections [2]. Pancreatic necrosis is defined as the presence of focal areas of non-viable pancreatic parenchyma that comprise greater than 30% of the pancreas. It often appears to replace, rather than to surround, the pancreas, and is often associated with fat necrosis. It is also often associated with an irregular wall because of the presence of solid debris [3]. Since our patient's fluid collection appears to surround the pancreas and to be encapsulated by a regular wall (Figure 4), it is likely that pancreatic pseudocyst is his main issue. However, pancreatic necrosis cannot be ruled out, as an MRI was not obtained. MRI may be more sensitive for the detection of pancreatic necrosis than CT [4].

#### *The Role of Imaging in Diagnosis*

During his second hospital admission, our patient presented with ascites in the context of chronic alcohol abuse, immediately suggesting the diagnosis of alcoholic cirrhosis. A pseudocyst was not initially suspected, perhaps because he had not been definitively diagnosed with pancreatitis on the previous admission. On the previous admission, the

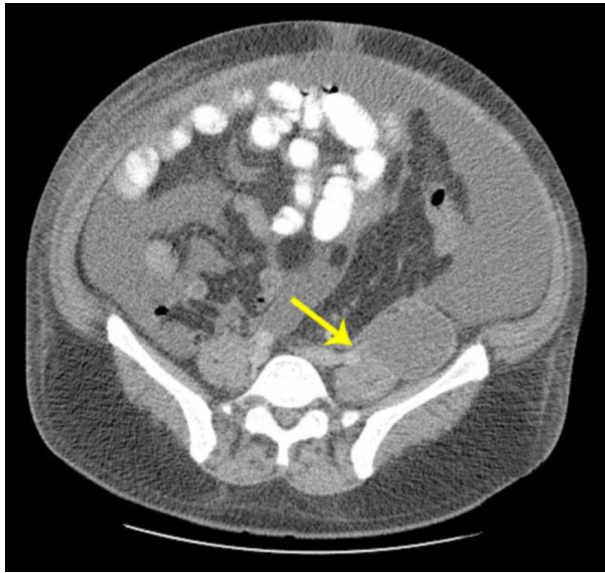
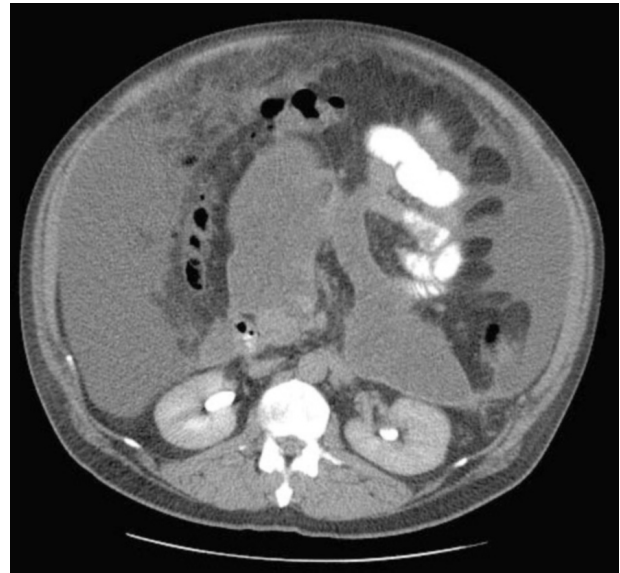

Figure 9. Single axial CT slice taken from series C, demonstrating the pseudocyst abutting the anterior surface of the psoas muscle in the region of the left ureter. The arrow indicates the region of interest in series C.



Series C. QuickTime movie of axial CT series, showing continuation of the pseudocyst to the iliac crest. The pseudocyst is contiguous with the psoas muscle at the level of the ureter, which is consistent with ureteral compression causing left-sided hydronephrosis.

patient had a normal amylase and only a slightly elevated lipase level; a tendency exists to use the degree of amylase or lipase elevation to determine the severity of pancreatitis. However, this approach warrants caution—patients with mild elevations of amylase or lipase can still have severe acute pancreatitis. In particular, amylase levels tend to be lower in alcohol-induced acute pancreatitis [5].

Imaging may have been useful during the patient's first hospitalization, both for confirming the diagnosis of pancreatitis and for assessing the patient for complications of this condition, including peri-pancreatic fluid collections. According to the guidelines established by the International Symposium held in Atlanta in 1992, an initial CT examination should be "performed in (a) patients in whom the clinical diagnosis is in doubt; (b) patients with hyperamylasemia and severe clinical pancreatitis, abdominal distention, tenderness, high fever ( $>102^{\circ}$ ), and leukocytosis; (c) patients with a Ranson score of  $>3$  or an APACHE score  $>8$ ; (d) patients who do not manifest rapid clinical improvement within 72 hours of initiation of conservative medical therapy; and (e) patients who demonstrate clinical improvement during initial medical therapy but then manifest an acute change in clinical status indicating a developing complication (e.g., fever,

pain, inability to tolerate oral intake, hypotension, falling hematocrit" [6]. These guidelines were motivated by the documented utility of contrast-enhanced CT in detecting acute pancreatic disease and its complications; specifically, contrast enhancement enables differentiation between enhancing pancreas and nonenhancing fluid collections [7]. Our patient's initial presentation with suprapubic abdominal pain radiating diffusely throughout the abdomen was not typical for pancreatitis, yet he did have a past medical history of pancreatitis. With this unclear presentation, CT imaging was indicated.

If CT was avoided in the interest of minimizing radiation exposure or cost, an ultrasound might have been a good second choice. Our patient's pseudocyst was first detected during his second admission via ultrasound as a poorly visualized hypoechoic mass at the pancreatic head. Though ultrasound is indicated early in the initial presentation of acute pancreatitis to rule out cholelithiasis as an etiology, it is less sensitive than CT for detection of pancreatitis and its complications since it is limited by body habitus, ascites, and bowel gas overlying the pancreas [8,9].

In a case like ours in which neither ultrasound nor CT was conducted initially, there are subtle signs that may be found on a simple plane film of the abdomen. As noted

## CT Imaging of a Pancreatic Pseudocyst: Clinical and Anatomic Implications

above, the KUB in this case seems to show the gastrocolic separation sign, but other signs of this nature exist as well. Other findings suggestive of acute pancreatitis on abdominal x-ray include small bowel ileus, colon dilation, obscure psoas margin, increased epigastric soft tissue density, gastric greater curvature distortion, duodenal ileus, pleural effusion, and pancreatic calcification [10]. If one or more of these signs is present in the setting of suspected pancreatitis, CT imaging is warranted for further evaluation.

### *Anatomic Considerations*

Pseudocysts can exert a mass effect and have been noted to obstruct the urinary system, the vena cava, the common bile duct, and other parts of the gastrointestinal tract. Our patient's large pseudocyst was implicated in all these obstructive complications. He had inferior vena cava

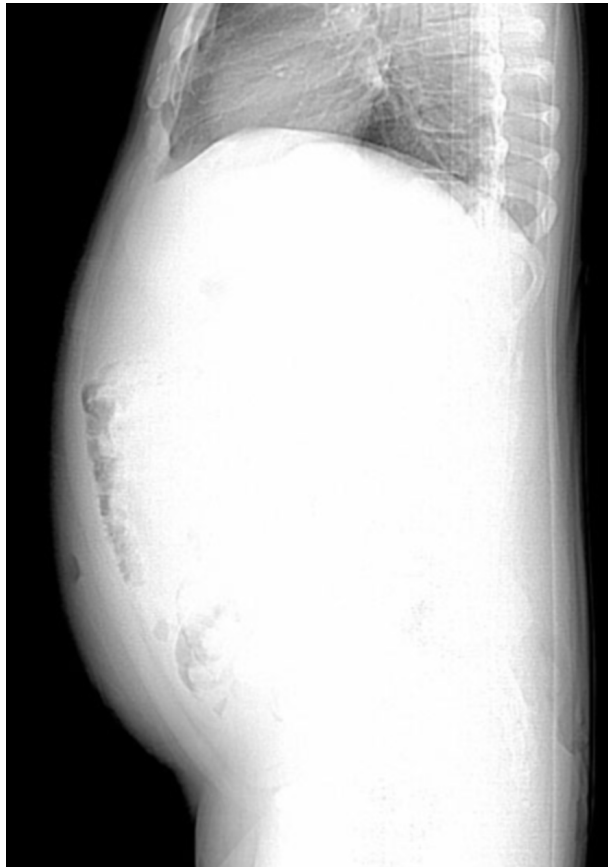

Figure 10. Scout image taken at discharge. Compare with Figure 2, taken at admission. The change in abdominal contour demonstrates reduced abdominal distension after diuresis, diagnostic paracentesis, and percutaneous pseudocyst drainage.

compression, which led to bilateral lower extremity edema [11]. He also had gastric outlet and duodenal obstruction, which have been associated with nausea, vomiting, and weight loss in case reports [12,13]. Although statistically more likely to be due to hepatic dysfunction, the patient's jaundice may also be a consequence of obstruction by pseudocyst [14]. Since our patient's jaundice resolved with pseudocyst drainage, it is likely that pseudocyst compression of the common bile duct was present and was a causative factor in his hyperbilirubinemia. The presence of a conjugated hyperbilirubinemia in our patient is also consistent with an obstructive etiology (hepatic dysfunction would be more likely to produce a predominantly unconjugated bilirubin excess).

In addition to illustrating the numerous obstructive consequences of pseudocysts, our patient's case also provides an illustration of the planes in the retroperitoneal space. The abdominal x-ray from the first admission demonstrated a soft tissue density separating the stomach and the colon, the so-called "gastrocolic separation sign." This finding most likely represents an acute fluid collection surrounding the pancreas protruding into the lesser sac. The gastrocolic separation sign has been associated with acute pancreatitis, with one study reporting an incidence as high as 49% in acute pancreatitis [15].

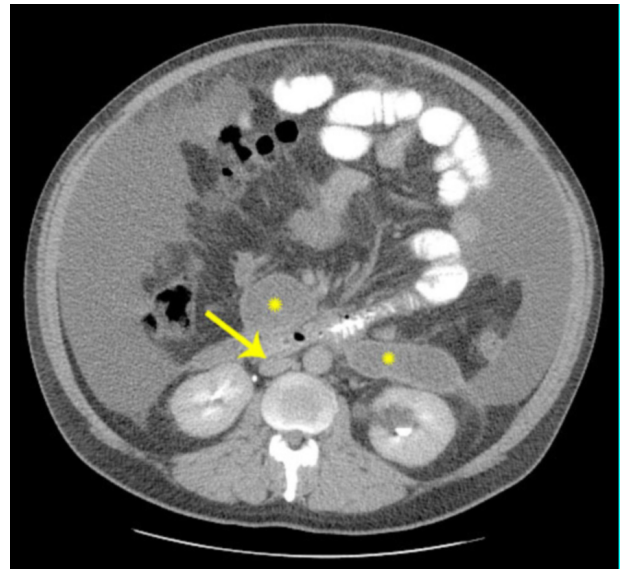


Figure 11. Axial image suggesting indirect compression of the inferior vena cava (arrow) by the pseudocyst (\*) via compression of the duodenum against the vessel. This compression offers an explanation for the patient's bilateral lower extremity edema on presentation.

## CT Imaging of a Pancreatic Pseudocyst: Clinical and Anatomic Implications

Pancreatic pseudocysts are most frequently found extending into the lesser sac, but also commonly spread to the left anterior pararenal space. The anterior pararenal space contains the pancreas, the retroperitoneal portions of the duodenum, the ascending colon, and the descending colon. The anterior pararenal space is bounded by the parietal peritoneum anteriorly, the anterior renal fascia posteriorly, and the lateroconal fascia laterally [16,17]. Fluid collections in the anterior pararenal space tend to be vertically oriented, as our patient's was [18]. Pancreatic pseudocysts only very rarely extend behind the anterior pararenal space into the perirenal space, which is bounded by the anterior and posterior renal fascia, or Gerota's fascia. With concurrent involvement of the anterior pararenal space and sparing of the perirenal space, the hyperlucent perirenal fat is outlined by fluid density and by Gerota's fascia, which is often thickened due to inflammation [19]. The massive dimensions of our patient's pseudocyst clearly demonstrate these anatomic relationships by filling potential spaces, making the fascial planes visibly distinct.

### Conclusion

Our patient's case is illustrative clinically and anatomically. His clinical presentation serves as a reminder of the important role imaging can play in evaluating patients with pancreatitis for possible complications; in this patient, imaging at the time of first admission would have permitted much earlier detection of his pseudocyst. The case also exemplifies the clinical consequences of mechanical obstruction by pseudocysts, serving to expand the differential of symptoms such as jaundice, pruritis, and early satiety. In addition, the physical size and localization of our patient's pancreatic pseudocyst offers a demonstration of retroperitoneal anatomy by making the fascial planes in this region visually apparent.

### References

1. Pitchumoni CS, Agarwal N. Pancreatic pseudocysts: When and how should drainage be performed? *Gastroenterol Clin North Am.* 1999 Sep;28(3):615-39. [PubMed]
2. Baron TH, Morgan DE, Vickers SM, Lazenby AJ. Organized pancreatic necrosis: Endoscopic, radiologic, and pathologic features of a distinct clinical entity. *Pancreas.* 1999 Jul;19(1):105-8. [PubMed]
3. Baron TH, Morgan DE. The diagnosis and management of fluid collections associated with pancreatitis. *Am J Med.* 1997 June;102(6):555-63. [PubMed]
4. Morgan DE, Baron TH, Smith JK, Robbin ML, Kenney PJ. Pancreatic fluid collections prior to intervention: Evaluation with MR imaging compared with CT and US. *Radiology.* 1997 Jun;203(3):773-8. [PubMed]
5. Lankisch PG, Burchard-Reckert S, Lehnick D. Underestimation of acute pancreatitis: Patients with only a small increase in amylase/lipase levels can also have or develop severe acute pancreatitis. *Gut.* 1999 Apr;44(4):542-544. [PubMed]
6. Balthazar EJ, Freeny PC, van Sonnenberg E. Imaging and intervention in acute pancreatitis. *Radiology.* 1994 Nov; 193(2): 297-306. [PubMed]
7. Balthazar EJ. Acute pancreatitis: Assessment of severity with clinical and CT evaluation. *Radiology.* 2002 Jun;223(3):603-13. [PubMed]
8. McCain AH, Berkman WA, Bernardino ME. Pancreatic sonography: Past and present. *J Clin Ultrasound.* 1984 Jul-Aug;12(6):325-332. [PubMed]
9. Baron TH, Morgan DE. The diagnosis and management of fluid collections associated with pancreatitis. *Am J Med.* 1997 June;102(6):555-63. [PubMed]
10. Rifkind KM, Lawrence LR, Ranson JH. Acute pancreatitis. Initial roentgenographic signs. *NY State J Med.* 1976 Nov;76(12):1968-72. [PubMed]
11. Browman MW, Litin SC, Binkovitz LA, Mohr DN. Pancreatic pseudocyst compressed the inferior vena cava and resulted in edema of the lower extremities. *Mayo Clin Proc.* 1992 Nov;67(11):1085-8. [PubMed]
12. Rheingold OJ, Walker JA, Barkin JS. Gastric outlet obstruction due to a pancreatic pseudocyst: report of two cases. *Am J Gastroenterol.* 1978 Jan;69(1):92-6. [PubMed]
13. Aranha GV, Prinz RA, Greenlee HB, Freeark RJ. Gastric outlet and duodenal obstruction from inflammatory pancreatic disease. *Arch Surg.* 1984 Jul;119(7):833-5. [PubMed]



## CT Imaging of a Pancreatic Pseudocyst: Clinical and Anatomic Implications

14. Cho HG, Min HY, Jang DS, et al. Two cases of chronic pancreatitis with pseudocyst complicated by obstructive jaundice. *Yonsei Med J.* 2000 Aug;41(4):522-7. [PubMed]

15. Moreno G, Rivera HH. Evaluation of the gastrocolic space in 100 cases of acute pancreatitis. *Radiology.* 1976 Mar;118(3):535-8. [PubMed]

16. Raptopoulos V, Kleinman PK, Marks S, Snyder M, Silverman PM. Renal fascial pathway: Posterior extension of pancreatic effusions within the anterior pararenal space. *Radiology.* 1986 Feb;158(2):367-74. [PubMed]

17. Griffin JF, Sekiya T, Isherwood I. Computed tomography of pararenal fluid collections in acute pancreatitis. *Clin Radiol.* 1984 May;35(3):181-4. [PubMed]

18. Hunziker RJ. Pathologic effusions localized to the anterior pararenal space: An in vivo demonstration. *Gastrointest Radiol.* 1978 Oct 1;3(4):411-4. [PubMed]

19. Casolo F, Bianco R, Franceschelli N. Perirenal fluid collection complicating chronic pancreatitis: CT demonstration. *Gastrointest Radiol.* 1987;12(2):117-120. [PubMed]