



Prolonged oral sildenafil use-induced Mondor disease: a case report

Han Sol Chung, You Ho Mun

Department of Emergency Medicine, Yeungnam University College of Medicine, Daegu, Korea

Penile Mondor disease (MD) is a palpable, painful, subcutaneous induration caused by superficial dorsal penile vein thrombosis. We report a case of penile MD that was suspected to be related to prolonged oral sildenafil use. A 46-year-old man visited our emergency department with sustained penile pain and swelling that began 7 hours after sexual intercourse. He had used oral sildenafil intermittently for 11 years and engaged in sexual intercourse the previous night after taking sildenafil. Examination revealed no evidence of intercourse-related trauma to the genital area or an increase in penile skin temperature. However, penile swelling and tenderness over the protruding dorsal penile vein were noted. A color Doppler ultrasound examination was performed immediately, which showed hyperchoic thrombosis in the right superficial dorsal penile vein that was dilated, with soft tissue swelling and no detectable flow signal in the thrombotic lesion. The patient was diagnosed as having penile MD. The patient was treated conservatively. Some reports have indicated the involvement of sildenafil in thrombogenesis. Physicians should be aware that prolonged oral sildenafil use may be associated with penile MD.

Keywords: Mondor disease; Sildenafil citrate; Venous thrombosis

Introduction

Mondor disease (MD) is a palpable, painful, subcutaneous induration caused by superficial venous thrombosis [1,2]. In 1939, the first report involved a female patient with symptoms in the thoracoepigastric region. Penile MD was first reported in 1958 [2,3]. MD is rare and its etiology remains to be established. However, a relationship with Virchow's triad is strongly suspected [1,3]. Moreover, rare cases of MD related to oral contraceptives have been reported [4]. Sildenafil, also known as Viagra, is currently used for the management of male erectile dysfunction and has been approved for the treatment of pulmonary hypertension [5]. We report a case of penile MD that was suspected to be related to prolonged oral sildenafil use.

Case

Ethical statements: This study was approved by the Institutional Review Board (IRB) of Yeungnam University Hospital (IRB No: 2022-03-033). Written informed consent was obtained for publication of this case report and accompanying images.

A 46-year-old man visited the emergency department (ED) with sustained penile pain and swelling that began 7 hours after sexual intercourse. He had a history of hypertension, gastroesophageal reflux disease, and posttraumatic stress disorder. He had used oral sildenafil intermittently for 11 years for erectile dysfunction, and

Received: March 25, 2022 • **Revised:** April 7, 2022 • **Accepted:** April 11, 2022

Corresponding author: You Ho Mun, MD

Department of Emergency Medicine, Yeungnam University College of Medicine, 170 Hyeonchung-ro, Nam-gu, Daegu 42415, Korea

Tel: +82-53-620-4321 • Fax: +82-53-623-8030 • E-mail: zezec@naver.com

Copyright © 2022 Yeungnam University College of Medicine, Yeungnam University Institute of Medical Science

This is an Open Access article distributed under the terms of the Creative Commons Attribution Non-Commercial License (<http://creativecommons.org/licenses/by-nc/4.0/>) which permits unrestricted non-commercial use, distribution, and reproduction in any medium, provided the original work is properly cited.

the night prior to arrival at the ED, he had engaged in sexual intercourse after taking sildenafil. No clinical signs of intercourse-related trauma to the genital area were observed. The following morning, he noted a sustained, painful penile erection with swelling. Using a visual analogue scale, the patient's pain intensity was scored at approximately 2 points. His initial vital signs were as follows: blood pressure, 100/60 mmHg; heart rate, 110 beats/min; respiratory rate, 20 breaths/min; and body temperature, normal. He reported no urinary symptoms and declined biochemical laboratory tests. On physical examination, the penis was swollen, with no increase in skin temperature. He complained of tenderness over the dorsal penile vein area and a mild protrusion was noted (Fig. 1). The differential diagnosis included suspected unidentified priapism, soft tissue infection, or penile fracture, and an ED ultrasound examina-

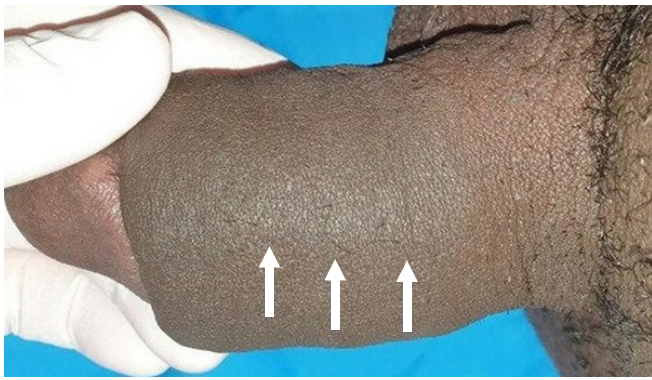


Fig. 1. Photo of the penis. Arrows indicate a slight protrusion of the superficial dorsal vein with mild swelling of the penis. No erythema is present.

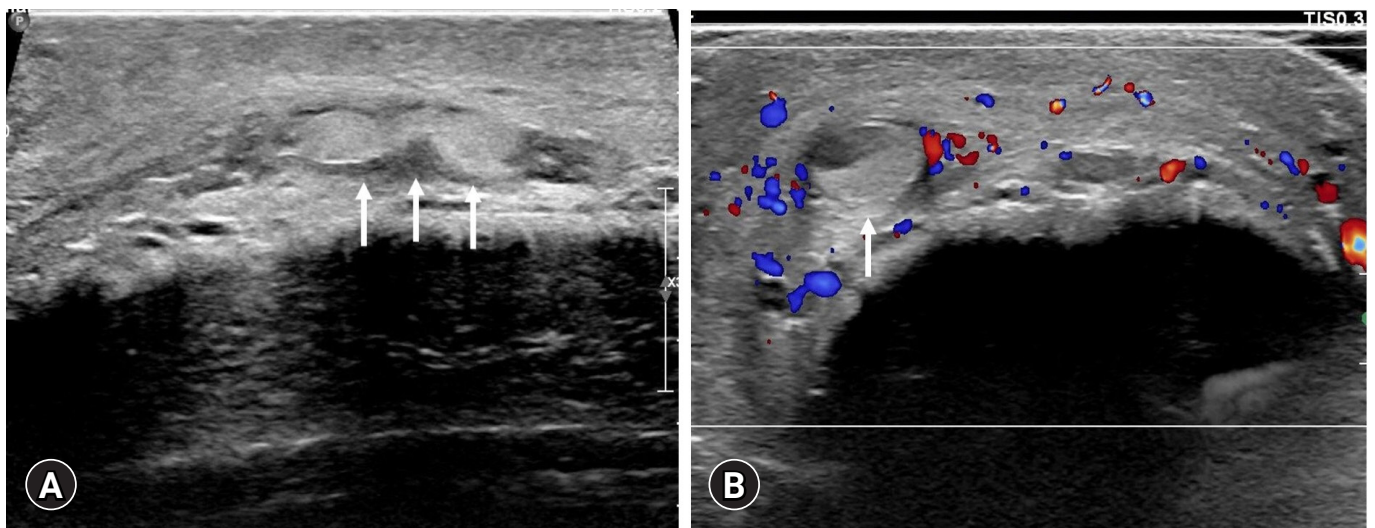


Fig. 2. Penile ultrasonography and color Doppler ultrasound imaging. (A) Ultrasonography shows thrombosis (arrows) in the penile superficial dorsal vein. (B) Color Doppler ultrasound indicates the absence of a flow signal (blue or red signal) in the thrombotic lesion (arrow). Imaging results support the diagnosis of penile Mondor disease.

tion was performed. No abnormal disruption of the tunica albuginea was noted in the penile shaft. However, a dilated vein with hyperechoic thrombosis was observed in the right superficial dorsal vein of the penis with soft tissue swelling. Moreover, the absence of flow signal in the thrombotic lesion was identified on the color Doppler ultrasound image (Fig. 2). Following ED-administered pain management, he was advised to avoid sexual intercourse and was discharged from the ED with a prescription for nonsteroidal anti-inflammatory medication. A follow-up appointment at the Department of Urology in outpatient clinic was made to determine whether surgical thrombectomy would be required. During the next 2 weeks of outpatient follow-up, the patient's symptoms improved.

Discussion

MD is a rare, painful, superficial venous thrombosis that has been reported to predominantly occur in the chest wall or penis [2]. Penile MD comprises venous thrombosis of the dorsal superficial penile vein and is typically benign and self-limiting. However, its pathophysiology remains unclear [1]. Virchow's triad, involving vascular wall injury, venous stasis, and hypercoagulation, has been reported to cause venous thrombosis [1]. The most likely cause of penile MD is vascular wall injury, which is one factor in Virchow's triad, due to lengthening or splitting of the vessel from prolonged vigorous sexual activity, typically within 24 to 48 hours [3]. Hypercoagulation due to protein S, protein C, and antithrombin III deficiency has also been reported to cause penile thrombosis [6]. Di-

Table 1. Previous reports of sildenafil-associated vascular thrombosis

Study	Symptom	Site of thrombus	Supposed mechanism
Rufa et al. [5]	Bilateral blurred vision	Superior sagittal sinus Right transverse and sigmoid sinus	Vascular insufficiency and stasis Platelet aggregation activation
Kim et al. [8]	Right side weakness	Left middle cerebral artery	Sildenafil-induced transient arrhythmic cardiac embolism
Karti et al. [9]	Bilateral blurred vision Headache	Right transverse and sigmoid sinus Jugular vein	Platelet aggregation activation

agnosis is possible through a detailed history, physical examination, and color Doppler ultrasound [1]. Penile MD is most frequently treated conservatively, and patients are advised to avoid sexual activity and to take nonsteroidal anti-inflammatory medication. However, in rare cases, thrombectomy can be proposed in chronic forms of penile MD or in forms resistant to treatment (persistence of the symptomatology and absence of permeabilization of the vein at 6 weeks) [1,7]. Antibiotics are prescribed if there is evidence of infection, such as superficial cellulitis or a sexually transmitted disease [3].

Sildenafil acts by blocking phosphodiesterase-5, an enzyme that promotes the breakdown of cyclic guanosine monophosphate (cGMP), causing relaxation of the corpora cavernosa and penile arteriolar smooth muscle. Owing to the localized vasodilatory effect of the nitric oxide–guanosine monophosphate pathway, the U.S. Food and Drug Administration has approved its use in the treatment of pulmonary hypertension [5]. However, sildenafil has been reported to have various adverse effects, including venous thrombosis. Table 1 shows previous reports on the association between venous thrombosis and oral sildenafil [5,8,9]. According to previous reports, the mechanisms of vascular thrombosis may be due to vascular stasis and/or platelet aggregation resulting from long-term sildenafil use. cGMP can inhibit platelet aggregation. Initially, cGMP causes platelets to clump to seal a wound and later reverses this action to stop an excessive build-up of cells that might then block a blood vessel. Sildenafil-enhanced intracellular cGMP activates cGMP-dependent protein kinase (PKG) [10]. PKG promotes von Willebrand factor-induced activation of human platelets [11]. Rufa et al. [5] suggested that the chronic use of sildenafil causes high cGMP levels, which might interfere with normal endothelial function. Moreover, sildenafil lowers systolic blood pressure by 8 to 10 mmHg owing to its vascular relaxation effect, which could be the cause of vascular insufficiency [12]. Decreased blood flow owing to blood vessel relaxation may be an additional cause of thrombus formation.

Penile MD is not life-threatening, but it can negatively affect a patient's quality of life. Considering the adverse effects of sildenafil, prolonged oral administration could cause abnormal venous thrombosis of the superficial dorsal penile vein. It is also reason-

able to consider that sildenafil can cause penile MD in men with other risk factors, such as penile vascular wall injury due to vigorous sexual activity. We believe that long-term use of sildenafil causes genital vascular thrombosis, and further studies are needed to support the development of optimal guidelines for long-term use.

Notes

Conflicts of interest

No potential conflict of interest relevant to this article was reported.

Funding

None.

Author contributions

Conceptualization, Data curation, Formal analysis and Investigation: YHM, HSC; Writing-original draft: YHM; Writing-review & editing: YHM, HSC.

ORCID

Han Sol Chung, <https://orcid.org/0000-0003-2193-9060>

You Ho Mun, <https://orcid.org/0000-0003-0585-8674>

References

1. Amano M, Shimizu T. Mondor's disease: a review of the literature. *Intern Med* 2018;57:2607–12.
2. Laroche JP, Galanaud J, Labau D, Van Kien AK, Brisot D, Boge G, et al. Mondor's disease: what's new since 1939? *Thromb Res* 2012;130(Suppl 1):S56–8.
3. Walsh JC, Poimboeuf S, Garvin DS. A common presentation to an uncommon disease: Penile Mondor's disease: a case report and literature review. *Int Med Case Rep J* 2014;7:155–7.
4. Kadioglu H, Yildiz S, Ersoy YE, Yücel S, Müslümanoğlu M. An unusual case caused by a common reason: Mondor's disease by oral contraceptives. *Int J Surg Case Rep* 2013;4:855–7.
5. Rufa A, Cerase A, Monti L, Dotti MT, Giorgio A, Sicurelli F, et

- al. Recurrent venous thrombosis including cerebral venous sinus thrombosis in a patient taking sildenafil for erectile dysfunction. *J Neurol Sci* 2007;260:293–5.
6. Al-Mwalad M, Loertzer H, Wicht A, Fornara P. Subcutaneous penile vein thrombosis (penile Mondor's disease): pathogenesis, diagnosis, and therapy. *Urology* 2006;67:586–8.
 7. Sasso F, Gulino G, Basar M, Carbone A, Torricelli P, Alcini E. Penile Mondors' disease: an underestimated pathology. *Br J Urol* 1996;77:729–32.
 8. Kim KK, Kim DG, Ku YH, Lee YJ, Kim WC, Kim OJ, et al. Bilateral cerebral hemispheric infarction associated with sildenafil citrate (Viagra) use. *Eur J Neurol* 2008;15:306–8.
 9. Karti DT, Karti O, Aktert D, Gokcay F, Celebisoy N. Sildenafil-related cerebral venous sinus thrombosis and papilledema: a case report of a rare entity. *Neurol Sci* 2017;38:1727–9.
 10. Haslam RJ, Dickinson NT, Jang EK. Cyclic nucleotides and phosphodiesterases in platelets. *Thromb Haemost* 1999;82:412–23.
 11. Li Z, Xi X, Gu M, Feil R, Ye RD, Eigenthaler M, et al. A stimulatory role for cGMP-dependent protein kinase in platelet activation. *Cell* 2003;112:77–86.
 12. Zusman RM, Morales A, Glasser DB, Osterloh IH. Overall cardiovascular profile of sildenafil citrate. *Am J Cardiol* 1999;83(5A):35C–44C.