

---

Case Report

# Continuous Glucose Monitoring to Diagnose Hypoglycemia Due to Late Dumping Syndrome in Children After Gastric Surgeries

Hannah Chesser,<sup>1</sup> Fatema Abdulhussein,<sup>1</sup> Alyssa Huang,<sup>1,2</sup> Janet Y. Lee,<sup>1,3</sup> and Stephen E. Gitelman<sup>1</sup>

<sup>1</sup>Division of Pediatric Endocrinology, Department of Pediatrics, University of California, San Francisco, San Francisco, CA 94143, United States; <sup>2</sup>Division of Endocrinology and Diabetes, Department of Pediatrics, University of Washington, Seattle Children's Hospital, Seattle, Washington, WA 98145, United States; and <sup>3</sup>Division of Endocrinology and Metabolism, Department of Medicine, University of California, San Francisco, San Francisco, CA 94143, United States

**ORCID numbers:** 0000-0002-0724-4310 (H. Chesser); 0000-0003-0603-5485 (A. Huang); 0000-0002-3563-8843 (J. Y. Lee); 0000-0003-4186-4107 (S. E. Gitelman).

**Abbreviations:** BG, blood glucose; CGM, continuous glucose monitoring; GERD, gastroesophageal reflux disease; GI, gastrointestinal; GLP-1, glucagon-like peptide-1; G-tube, gastrostomy tube; POC, point-of-care.

Received: 4 September 2020; Editorial Decision: 9 December 2020; First Published Online: 2 January 2021; Corrected and Typeset: 19 January 2021.

## Abstract

Gastrostomy tubes (G-tubes) and Nissen fundoplication are common surgical interventions for feeding difficulties and gastroesophageal reflux disease in children. A potential yet often missed, complication of these procedures is dumping syndrome. We present 3 pediatric patients with postprandial hypoglycemia due to late dumping syndrome after gastric surgeries. All patients received gastrostomy tubes for feeding intolerance: 2 had Nissen fundoplication for gastroesophageal reflux disease, and 1 had tracheoesophageal repair. All patients underwent multiple imaging studies in an to attempt to diagnose dumping syndrome. Continuous glucose monitoring (CGM) was essential for detecting asymptomatic hypoglycemia and glycemic excursions occurring with feeds that would have gone undetected with point-of-care (POC) blood glucose checks. CGM was also used to monitor the effectiveness of treatment strategies and drive treatment plans. These cases highlight the utility of CGM in diagnosing postprandial hypoglycemia due to late dumping syndrome, which is infrequently diagnosed by imaging studies and intermittent POC blood glucose measurements.

**Key Words:** late dumping syndrome, continuous glucose monitoring, reactive hypoglycemia, postprandial hypoglycemia, hyperinsulinemic hypoglycemia, pediatrics

Gastrostomy tubes (G-tubes) and Nissen funduplications are increasingly employed to treat feeding intolerance and gastroesophageal reflux disease (GERD) in children. Removing the barrier function of the pylorus or reducing gastric volume can lead to undigested food rapidly entering the small intestine, which can result in dumping syndrome [1]. The symptoms of dumping syndrome are classified as early and late, which can occur together or in isolation. Early dumping syndrome typically occurs within the first hour after eating with gastrointestinal and vasomotor symptoms including nausea, vomiting, abdominal cramping, sweating, tachycardia, and dizziness. Late dumping syndrome, also referred to as reactive or postprandial hyperinsulinemic hypoglycemia, typically occurs 1 to 3 hours after eating and manifests as hypoglycemia due to a hyperinsulinemic response. Exaggerated secretion of glucagon-like peptide 1 (GLP-1) has been implicated as a key mediator of postprandial hypoglycemia in late dumping syndrome [2].

The diagnosis of late dumping syndrome can be particularly elusive in children. The signs and symptoms may go unrecognized, especially in younger children. In addition, recurrent episodes of hypoglycemia may result in hypoglycemia unawareness [3], compounding the challenges in making the diagnosis. Further complicating the diagnosis is the lack of consensus guidelines for diagnosing dumping syndrome in the pediatric population.

Herein, we present a case series of 3 children with postprandial hypoglycemia due to late dumping syndrome. Although imaging studies did not indicate dumping syndrome, continuous glucose monitoring (CGM) proved to be a useful adjunctive study for both the diagnosis and assessment of the effectiveness of therapy.

## Case Series

The patients presented to our institution between 2015 and 2019. [Table 1](#) summarizes the clinical characteristics of the patients. Two of the patients received a Nissen fundoplication for GERD and one patient underwent gastroesophageal repair for tracheoesophageal fistula. All patients had feeding intolerance manifested by frequent vomiting and aspiration, for which a G-tube was placed. CGM (Dexcom; San Diego, California) devices were placed on the patients to better evaluate the glycemic patterns associated with feeds. Dexcom G4, G5, and G6 devices were used and calibrated per industry recommendations. The data stored by the CGM devices were uploaded to Dexcom Clarity or Tidepool, a web-based cloud software system for collecting and visualizing diabetes device data [4].

## Patient 1

A 9-month-old full-term male infant with a history of poor growth and severe GERD status post-Nissen fundoplication and G-tube placement presented with labile blood glucoses (BG) ranging from 50 to 200 mg/dL. Loose stools occurred after G-tube feeds and, in retrospect, the child seemed fatigued after feeds. He had a previous hospitalization at age 8 months for hypoglycemia; however, no critical sample was captured, and a nuclear medicine gastric emptying study was normal.

He was again hospitalized for extensive workup of glucose lability at 9 months of age. Physical exam was unremarkable with an alert and interactive infant with normal phallus and no midline defects. It was difficult to capture the timing of the hypoglycemia with POC blood glucose monitoring, so a CGM device was placed. He underwent a 16-hour fast and then demonstrated physiologic, ketotic hypoglycemia and a blunted glucose response to glucagon, with a lack of counter-regulatory cortisol rise ([Table 2](#)). Subsequent anterior pituitary workup, including a cosyntropin stimulation test, was normal. Given the postprandial hyperglycemia and hypoglycemia, there was suspicion for glycogen storage disease type 0 (GSD0). Liver ultrasound was normal. He underwent mixed-meal tolerance tests with a high carbohydrate load (Enfamil) both by mouth and by G-tube, which did not elicit the characteristic rise in lactate levels seen in GSD0. However, CGM profiles revealed postprandial hyperglycemia (serum BG 180-250 mg/dL) within the first hour of feeds, followed by a drop in glucose levels (serum BG 50-60 mg/dL) about 2 hours later ([Fig. 1A](#)). He completed a second nuclear medicine gastric emptying study that was normal.

Despite the imaging study results, his clinical picture and CGM profiles showing a pattern of glycemic dysregulation were most consistent with postprandial hypoglycemia due to late dumping syndrome. Dietary modifications with the addition of complex carbohydrates and more frequent, smaller enteral feeds were not tolerated. Acarbose prior to large meals was initiated with improved blood glucose values. He was discharged home with a CGM device and instructions to treat hypoglycemia with small volumes of juice. By 10 months old, he required an increase in his acarbose dose prior to meals due to persistent hypoglycemia. His G-tube was removed at 22 months of age, and he had no further episodes of hypoglycemia and his dumping syndrome was presumed to be resolved.

## Patient 2

An 8-month-old term male infant with a history of chronic aspiration, severe GERD, and hypotonia status post-Nissen

**Table 1.** Patient Characteristics

Patient	Age at presentation (months)	Past medical history	Surgery (age at surgery)	Feeding regimen at presentation	Diagnostic test	Imaging studies (result)	Glucose monitoring	Treatment
1	8-9	FTT, GERD	G-tube and Nissen fundoplication (6 months)	Oral and enteral	MMTT	Nuclear medicine study × 2 (normal)	Inpatient: CGM Outpatient: Glucometer	Acarbose prior to meals
2	9	Chronic aspiration, hypotonia, GERD	G-tube and Nissen fundoplication (7 months)	Enteral	OGTT	Gastric emptying study × 2 (severely delayed gastric emptying) Upper GI study (normal)	Inpatient: CGM Outpatient: CGM	Feeding manipulation Acarbose prior to bolus feeds unsuccessful Cornstarch with bolus feeds unsuccessful
3	13	Esophageal atresia and distal tracheoesophageal fistula (EA-TEF type C)	G-tube and tracheoesophageal repair and dilations (0 months)	Enteral	MMTT	Gastric emptying study (normal)	Inpatient: CGM Outpatient: Glucometer	Feeding manipulation Cornstarch with bolus feeds

Abbreviations: CGM, continuous glucose monitoring; FTT, failure to thrive; MMTT, mixed-meal tolerance test; OGTT, oral glucose tolerance test.

fundoplication and G-tube placement was hospitalized with feeding intolerance, dehydration, and asymptomatic hypoglycemia (serum BG 43 mg/dL). Physical exam showed mild hypotonia, no midline defects, and a normal phallus. Loose stools occurred after bolus G-tube feeds. The hypoglycemia was attributed to prolonged fasting, and the patient was discharged home with instructions to treat hypoglycemia with small volumes of juice. At home, he continued to have asymptomatic hypoglycemia, with self-monitoring blood glucose levels as low as 40 mg/dL.

At age 12 months, he was readmitted for workup of ongoing hypoglycemia. Intermittent blood glucose monitoring did not capture the timing of hypoglycemia in relation to feeds, so a CGM device was placed. Enteral feeds were changed to continuous overnight with intermittent boluses during the day. Metabolic workup and single nucleotide polymorphism (SNP) array were unremarkable. An upper gastrointestinal (GI) study showed the G-tube balloon in the antrum but away from the pylorus. He did not develop hypoglycemia during an 11-hour fast. Four hours after a 50-gram glucose load was given via G-tube, his serum blood glucose fell to 31 mg/dL with associated tachycardia, sweating, and tremors. Critical labs showed hyperinsulinemic hypoglycemia with a lack of counter-regulatory cortisol rise, though subsequent cosyntropin stimulation test was normal (Table 2). His postprandial hyperinsulinemic hypoglycemia was attributed to late dumping syndrome.

Subsequent monitoring with CGM revealed that hypoglycemia persisted after bolus G-tube feeds. A gastric emptying study showed severely delayed gastric emptying (liquid half-emptying time of 370 minutes; upper limit of normal 45-60 minutes). Acarbose and cornstarch prior to bolus feeds were unsuccessful in preventing hypoglycemia. Erythromycin was trialed for gastroparesis but discontinued when it worsened hypoglycemia. Feeds were lengthened to continuous enteral feeds, which improved blood glucose values.

At 19 months old, he was switched to a gastrojejunostomy (GJ) tube due to multiple G-tube malfunctions and gastroparesis. CGM was used to guide feeding adjustments. Continuous G-tube feeds, with short breaks, were transitioned to J-tube feeds. After oral intake of 5 to 10 g of carbohydrates was introduced, CGM trends revealed dysglycemia classic for late dumping syndrome, with postprandial hyperglycemia (180-300 mg/dL) about 1 hour after oral intake followed by hypoglycemia (48-65 mg/dL) 3 hours later (Fig. 1B). Occasional hypoglycemia after oral intake is ongoing and is treated with a small volume of cherry syrup via G-tube.

### Patient 3

A 13-month-old male with repaired esophageal atresia and distal tracheoesophageal fistula type C requiring esophageal

**Table 2. Critical Labs, Glucagon Stimulation Test, and Additional Labs**

Patient	Timing of critical labs	Critical labs <sup>a</sup>	Glucagon stimulation test <sup>b</sup>	Diabetes screening	Cosyntropin stimulation test <sup>d</sup>
1	16 hours into fast	Serum BG 46 mg/dL Insulin < 1.0 ng/mL C-peptide 0.1 ng/mL βHB 4.12 mmol/L FFA 1.12 mmol/L Cortisol 2 (4-19 ug/dL) GH 6.1 (2-10 ng/mL)	Blunted BG rise: 0 min = 50 mg/dL 40 min = 55 mg/dL	HgbA1c 4.8% Negative β cell Autoantibodies <sup>c</sup>	Cortisol: 0 min = 10 ug/dL 60 min = 27 ug/dL
2	4 hours after a 50 g glucose load	Serum BG 31 mg/dL Insulin 1.9 mU/L C-peptide 1.7 ng/mL βHB 0.12 mmol/L FFA 0.32 mmol/L Cortisol 4 (4-19 ug/dL) GH 6.0 (2-10 ng/mL)	Stimulated BG rise: 0 min = 50 mg/dL 27 min = 126 mg/dL	HbA1c 4.7%	Cortisol: 0 min = 2 ug/dL 60 min = 27 ug/dL
3	2 hours after bolus G-tube feed	Serum BG 15 mg/dL Insulin 35.9 mU/L βHB 0.15 mmol/L FFA 0.1 mmol/L Cortisol 2 (4-22 ug/dL)	Stimulated BG rise: 0 min = 15 mg/dL 28 min = 108 mg/dL	HbA1c 4.8%	Cortisol: 0 min = 10 ug/dL 60 min = 35 ug/dL

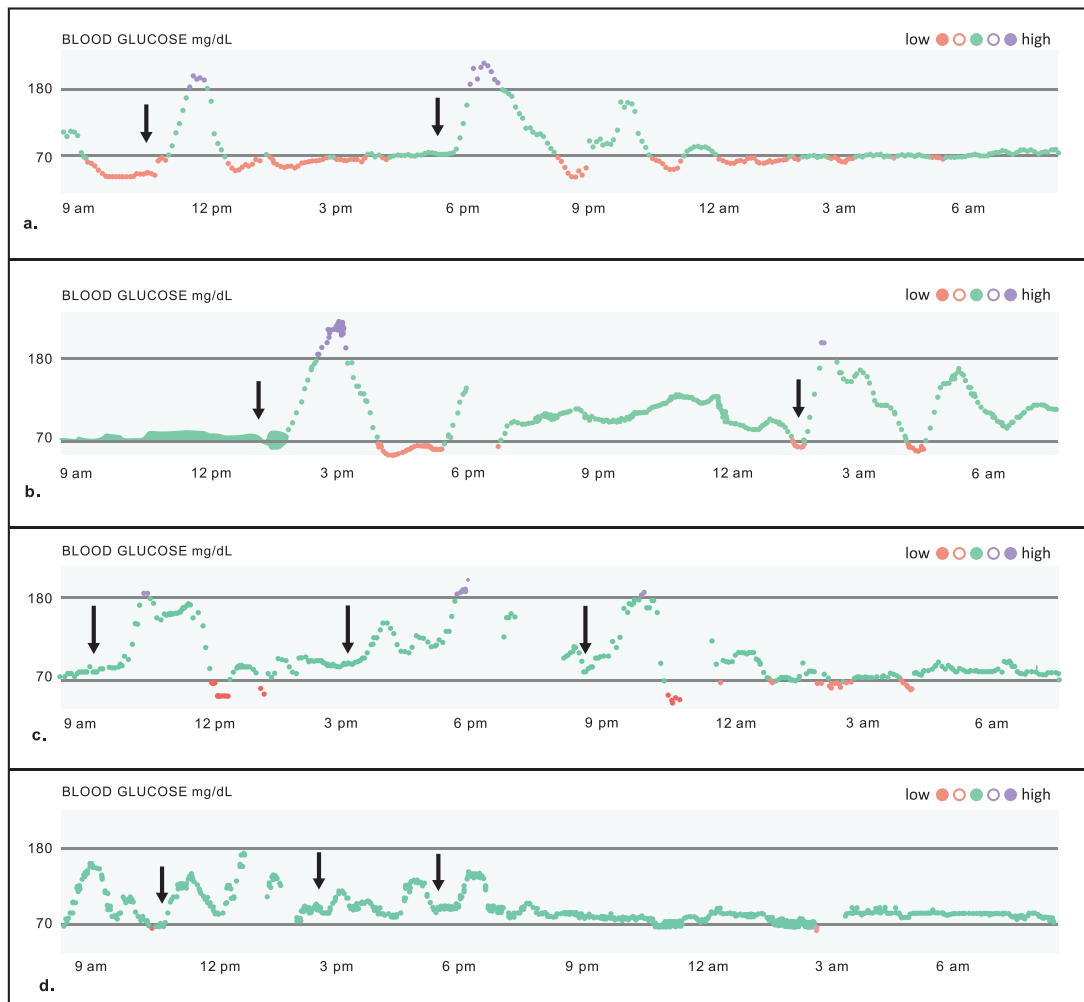
Abbreviations: BG, blood glucose; CGM, continuous glucose monitoring; FFA, free fatty acids; GH, growth hormone; βHB, β hydroxybutyrate; min, minute

<sup>a</sup>Reference ranges for critical labs obtained from Ferrara et al., 2016 [5]. Hyperinsulinism is defined as detectable insulin (>0 mU/L), detectable C-peptide ≥ 0.5 ng/ml, suppressed βHB < 1.8 mM, and suppressed FFA < 1.7 mM.

<sup>b</sup> Stimulated rise for a glucagon stimulation test is a rise in BG ≥ 30mg/dl in 30 minutes [5]

<sup>c</sup>β-cell autoantibodies (insulin autoantibody, islet cell antibody, islet cell antigen 512 antibody, zinc transport 8 antibody, and GAD-65 autoantibody) were run at Quest Diagnostics Nichols Institute, San Juan Capistrano, CA solely for the purpose of patient clinical care.

<sup>d</sup>Cosyntropin stimulation test reference range is a 60 min cortisol value of ≥18 ug/dL [6].



**Figure 1.** Continuous glucose monitoring (CGM) profiles. **A-D**, Continuous glucose monitoring (CGM) profiles with feeds. Arrows indicate time of meals. **A**, Patient 1 CGM profile with hyperglycemia followed by hypoglycemia after oral feeds (CGM software: Tidepool). **B**, Patient 2 CGM profile with hyperglycemia followed by hypoglycemia after oral feeds (CGM software: Tidepool). **C**, Patient 3 CGM profile with hyperglycemia followed by hypoglycemia after bolus G-tube feeds (CGM software: Tidepool). **D**, Patient 3 CGM profile after cornstarch and feeding manipulation, with normoglycemia (CGM software: Tidepool).

dilations for strictures and G-tube placement for oral aversion presented with a hypoglycemic seizure. The serum BG was noted to be 17 mg/dL and occurred 2 hours after a bolus G-tube feed. He had previously been evaluated at 8 and 9 months of age for seizure-like activity. Video electroencephalography was unremarkable and the episodes were attributed to Sandifer syndrome, a manifestation of GERD characterized by abnormal and dystonic movements of the head, neck, and trunk [7]. During one admission, he had a serum BG of 52 mg/dL and follow-up POC BG of 89 mg/dL.

During this admission at 13 months of age, intermittent blood glucose monitoring did not capture his asymptomatic hypoglycemia episodes, so a CGM device was placed. Abdominal radiograph, upper GI series, gastric emptying scan, and glucose tolerance testing did not fulfill existing diagnostic criteria for either early or late dumping syndrome [1]. CGM profiles revealed hyperglycemia to BG

200 to 300 mg/dL at 1 hour after bolus feeds, followed by hypoglycemia 2 hours after feeds (Fig. 1C). CGM expedited the attainment of a critical sample, notable for hyperinsulinemic hypoglycemia to serum BG 15 mg/dL with a lack of counter-regulatory cortisol rise, and glucagon stimulation test with a robust glycemic response (Table 2). A subsequent cosyntropin stimulation test was normal (Table 2). A fasting study confirmed physiologic, ketotic hypoglycemia after 16.5 hours, and his postprandial, hyperinsulinemic hypoglycemia was attributed to late dumping syndrome. CGM showed normoglycemia on smaller daytime bolus enteral feeds and overnight continuous enteral feeds (Fig. 1D), and the child was discharged home with a glucometer and instructions to treat hypoglycemia with small volumes of juice.

He was subsequently readmitted for feeding adjustments, and CGM safely guided these changes. At 18 months

of age, cornstarch was added to daytime intermittent bolus feeds. After several months, his mother discontinued cornstarch due to normal POC BGs at home. At 29 months of age, CGM again revealed postprandial hyperglycemia to BG 200 to 300 mg/dL followed by asymptomatic hypoglycemia to BG 35 mg/dL at 1.5 to 2 hours after feeds, which would have likely been missed with intermittent home POC BG monitoring. He was able to maintain normoglycemia with oral feeds, and his enteral feeds were discontinued. At 32 months of age, his G-tube was removed, and he experienced no further hypoglycemic episodes or seizure-like activity.

## Discussion

Postprandial hypoglycemia due to late dumping syndrome can occur after Nissen fundoplication and other gastric surgeries, but it is difficult to detect in young children. Previous authors have encouraged a low threshold for glucose monitoring if a child has feeding difficulties after gastric procedures, citing the wide variability in clinical presentations of dumping syndrome in children [8, 9]. After initiating an asymptomatic hypoglycemia screening program, one institution noted that nearly a quarter of children who underwent fundoplication developed postprandial hypoglycemia within one week. Only half of these children exhibited other symptoms of dumping syndrome [10].

We have presented cases of 3 young children who required multiple hospitalizations to diagnose and manage postprandial hypoglycemia, which was ultimately attributed to late dumping syndrome. Prior to being diagnosed with dumping syndrome, one child presented with seizures, which were misattributed to Sandifer syndrome. The seizures were likely caused by undiagnosed hypoglycemia. In each case, there was evidence of asymptomatic hypoglycemia and blunted counter-regulatory hormonal responses, with low counter-regulatory cortisol but subsequently normal cosyntropin stimulation testing. These observations highlight the challenges in diagnosing late dumping syndrome in a younger pediatric population, particularly infants and toddlers, who have limited ability to communicate. Parents and health care providers may miss subtle signs of hypoglycemia, even with intermittent glucose monitoring. Further complicating this scenario is the rapid development of hypoglycemia unawareness, in which profound and recurrent hypoglycemia blunts neuroglycopenic symptoms and counter-regulatory responses [3, 11]. Thus, based on the prior experiences of other institutions, [8–10] and the cases described herein, we suspect that postprandial hypoglycemia due to late dumping syndrome is underdiagnosed,

and is more prevalent than previously recognized. Even when diagnosed, we suspect that there are significant delays in diagnosis, as noted with our case series.

In approaching the diagnosis, one must consider the differences between early and late dumping syndrome. Closely monitoring for the timing or presence of vasomotor and gastrointestinal symptoms (early dumping syndrome) or reactive hypoglycemia (late dumping syndrome) in the hours following a glucose load can aid diagnosis [12]. Adult consensus guidelines define an increase in hematocrit >3% or a rise in heart rate >10 beats per minute by 30 minutes after the start of a modified oral glucose tolerance test as diagnostic of early dumping syndrome. The development of a blood glucose level <50 mg/dL, about 1 to 3 hours after the glucose load, is diagnostic of late dumping syndrome [13]. In our cases, none of the patients displayed signs or symptoms of gastrointestinal upset or vasomotor symptoms that would be characteristic of early dumping syndrome. This highlights the importance of understanding that early and late dumping syndrome can occur in isolation of one another.

Furthermore, as pathophysiology of late dumping syndrome is hormonal, imaging modalities may not detect the diagnosis [12]. Reactive hypoglycemia is triggered by accelerated delivery of a carbohydrate load into the small intestine, with resultant hormonal dysregulation, including hyperglycemia and a hyperinsulinemic response followed by a precipitous fall in serum glucose [2]. In all of our cases, gastric imaging studies, including gastric emptying studies, upper GI studies, and nuclear medicine studies, had low diagnostic yield. The imaging studies were either normal or displayed results contrary to what would be expected in dumping syndrome. Thus, the pursuit of multiple imaging studies led to a delay in diagnosis, extension of hospitalization, and heightened family frustration.

Given the dynamic nature of glycemic changes postprandially during dumping syndrome, it is not surprising that intermittent use of glucometer testing failed to identify the pattern of glycemic excursions characteristic of dumping syndrome in our cases. CGM was essential for diagnosis of late dumping syndrome by revealing the dynamic glycemic excursion, with hyperglycemia following by hypoglycemia, after feeds (Fig. 1, A-C). Critical samples showing a hyperinsulinemic response after a glucose load, in 2 of the cases, corroborated this diagnosis (Table 2).

CGM was also useful to guide therapeutic interventions that included feeding manipulations, cornstarch, and acarbose. First-line treatment of postprandial hypoglycemia due to late dumping syndrome includes the use



of dietary modification with more frequent or continuous feeds and dietary supplementation with fiber, cornstarch, or gelling agents. Second-line therapy is acarbose, an alpha glucosidase inhibitor that blunts carbohydrate breakdown. Somatostatin analogues are reserved for patients who do not respond to dietary adjustments and acarbose [14]. CGM enabled safe modification of the feeding and medication regimens of the 3 patients described herein (Fig. 1D). CGM also enabled families to identify and intervene on hypoglycemic episodes that may have gone unnoticed with traditional POC glucometer use. In the event of hypoglycemia, families were instructed to give a small quantity of rapid-acting glucose. Early hypoglycemia intervention is particularly important in young children as recurrent hypoglycemia is associated with poor long-term neurocognitive outcomes [15]. Thus, our cases contribute to a growing body of evidence that supports the use of CGM to diagnose and manage reactive hypoglycemia [16-19].

We conclude that because of the variable results in imaging studies and the rapid development of hypoglycemia unawareness in children, CGM should be the first line in evaluating children that may have hypoglycemia after gastric procedures. Abnormal blood glucoses may be missed with intermittent glucometer checks, and postprandial hypoglycemia in children with a history of gastric surgery is likely underdiagnosed. Clinicians should maintain a high index of suspicion for dumping syndrome when evaluating children with a history of gastric surgeries, even if the child exhibits no or few clinical symptoms. CGM can help with earlier diagnosis of dumping syndrome and can reveal the characteristic pattern of glycemic dysregulation. Furthermore, it can be used to efficiently evaluate the effectiveness of various treatments and feeding regimens.

## Acknowledgments

**Financial support:** Research reported in this publication was supported by the National Institute of Diabetes and Digestive and Kidney Diseases (award number T32DK007161 awarded to HC, AH, and JYL) and the Eunice Kennedy Shriver National Institute of Child Health & Human Development (award number F32HD098763 awarded to JYL) of the National Institutes of Health. The content is solely the responsibility of the authors and does not necessarily represent the official views of the National Institutes of Health.

## Additional Information

**Correspondence:** Stephen E. Gitelman, MD, UCSF, Global Health & Clinical Sciences, Mission Hall, 550 16<sup>th</sup> Street, 4<sup>th</sup> Floor, Box 0434, San Francisco, CA 94143, USA. Email: [stephen.gitelman@ucsf.edu](mailto:stephen.gitelman@ucsf.edu).

**Disclosures:** H.C., F.A., A.H., J.Y.L., and S.E.G. have no relevant financial interests to disclose.

**Data Availability:** Data sharing is not applicable to this article as no datasets were generated or analyzed during the current study.

## References

1. Tack J, Arts J, Caenepeel P, De Wulf D, Bisschops R. Pathophysiology, diagnosis and management of postoperative dumping syndrome. *Nat Rev Gastroenterol Hepatol*. 2009;6(10):583-590.
2. Calabria AC, Charles L, Givler S, De León DD. Postprandial hypoglycemia in children after gastric surgery: clinical characterization and pathophysiology. *Horm Res Paediatr*. 2016;85(2):140-146.
3. Thornton PS, Stanley CA, De Leon DD, et al.; Pediatric Endocrine Society. Recommendations from the pediatric endocrine society for evaluation and management of persistent hypoglycemia in neonates, Infants, and Children. *J Pediatr*. 2015;167(2):238-245.
4. Neinstein A, Wong J, Look H, et al. A case study in open source innovation: developing the Tidepool Platform for interoperability in type 1 diabetes management. *J Am Med Inform Assoc*. 2016;23(2):324-332.
5. Ferrara C, Patel P, Becker S, Stanley CA, Kelly A. Biomarkers of Insulin for the Diagnosis of Hyperinsulinemic Hypoglycemia in Infants and Children. *J Pediatr*. 2016;168:212-219.
6. Peechakara S, Bena J, Clarke NJ, et al. Total and free cortisol levels during 1 µg, 25 µg, and 250 µg cosyntropin stimulation tests compared to insulin tolerance test: results of a randomized, prospective, pilot study. *Endocrine*. 2017;57(3):388-393.
7. Mindlina I. Diagnosis and management of Sandifer syndrome in children with intractable neurological symptoms. *Eur J Pediatr*. 2020;179(2):243-250.
8. Bufler P, Ehringhaus C, Koletzko S. Dumping syndrome: a common problem following Nissen fundoplication in young children. *Pediatr Surg Int*. 2001;17(5-6):351-355.
9. Samuk I, Afriat R, Horne T, Bistritzer T, Barr J, Vinograd I. Dumping syndrome following Nissen fundoplication, diagnosis, and treatment. *J Pediatr Gastroenterol Nutr*. 1996;23(3):235-240.
10. Calabria AC, Gallagher PR, Simmons R, Blinman T, De León DD. Postoperative surveillance and detection of postprandial hypoglycemia after fundoplasty in children. *J Pediatr*. 2011;159(4):597-601.e1.
11. Bellini F, Sammiceli L, Ianni L, Pupilli C, Serio M, Mannelli M. Hypoglycemia unawareness in a patient with dumping syndrome: report of a case. *J Endocrinol Invest*. 1998;21(7):463-467.
12. Gys B, Plaeke P, Lamme B, et al. Heterogeneity in the definition and clinical characteristics of dumping syndrome: a review of the literature. *Obes Surg*. 2019;29(6):1984-1989.
13. Scarpellini E, Arts J, Karamanolis G, et al. International consensus on the diagnosis and management of dumping syndrome. *Nat Rev Endocrinol*. 2020;16(8):448-466.
14. van Beek AP, Emous M, Laville M, Tack J. Dumping syndrome after esophageal, gastric or bariatric surgery: pathophysiology, diagnosis, and management. *Obesity Reviews*. 2017;18(1):68-85.
15. Muukkonen L, Männistö J, Jääskeläinen J, Hannonen R, Huopio H. The effect of hypoglycaemia on neurocognitive

- outcome in children and adolescents with transient or persistent congenital hyperinsulinism. *Dev Med Child Neurol*. 2019;61(4):451-457.
16. Ueda K, Mizumoto H, Shibata H, Miyauchi Y, Sato M, Hata D. Continuous glucose monitoring for suspected dumping syndrome in infants after Nissen fundoplication. *Pediatr Int*. 2013;55(6):782-785.
17. Buscemi S, Mattina A, Genova G, Genova P, Nardi E, Costanzo M. Seven-day subcutaneous continuous glucose monitoring demonstrates that treatment with acarbose attenuates late dumping syndrome in a woman with gastrectomy for gastric cancer. *Diabetes Res Clin Pract*. 2013;99(1):e1-e2.
18. Morikawa M, Hara Y, Nakazawa Y, Inaba Y, Motobayashi M. Usefulness of continuous glucose monitoring for prevention and early detection of hypoglycemia caused by a ketogenic diet and late dumping syndrome. *Pediatr Neurol*. 2019. doi:[10.1016/j.pediatrneurol.2019.12.002](https://doi.org/10.1016/j.pediatrneurol.2019.12.002).
19. Kishimoto M, Noda M. Verification of glycemic profiles using continuous glucose monitoring: cases with steroid use, liver cirrhosis, enteral nutrition, or late dumping syndrome. *J Med Invest*. 2015;62(1-2):1-10.