

Endoscopic Management of the Ascending Colon Perforation Secondary to a Rare-Earth Magnets Ingestion in a Pediatric Patient

Sandra Mabel Camacho-Gomez, MD¹, James Meredith Noel, MD¹, and Robert Adam Noel, MD¹

¹*Division of Pediatric Gastroenterology, Department of Pediatrics, Baylor College of Medicine at The Children's Hospital of San Antonio, San Antonio, TX*

ABSTRACT

Rare magnets (neodymium magnets) are high-powered magnets known to cause intestinal perforation if the intestinal mucosa is trapped in between 2 or several magnets. A bowel perforation in pediatric patients secondary to magnets is usually managed with a surgical intervention that might require enterectomy. We report a case of an 11-year-old boy who presented with abdominal pain and a finding on abdominal x-ray of radiopaque foreign bodies located in the ascending colon. He underwent colonoscopy with a finding of embedded magnets with a colonic perforation. The colonoscopy revealed embedded magnets in the colonic mucosa that were colonoscopically removed, and then, the perforated site was successfully managed with endoclipping of the perforation site in the ascending colon.

INTRODUCTION

Rare magnets (neodymium magnets) are high-powered magnets known to cause intestinal perforation if intestinal mucosa is caught in between magnets.¹ Other complications of magnet ingestion include bleeding, peritonitis, intestinal fistulas, volvulus, small bowel obstruction, or large intestinal resection leading to short bowel syndrome and possible death.² The bowel perforation in pediatric patients is usually managed with a surgical intervention that might require enterectomy.³ Herein, we report a case of a boy presented with abdominal pain and an incidental finding on an abdominal x-ray of radiopaque foreign bodies located in the ascending colon consistent with embedded magnets, who underwent colonoscopy with magnets removal and a finding of colonic perforation. The colonoscopy revealed the embedded magnets in the colonic mucosa, managed successfully with the removal of the magnets, followed by endoscopic clipping of the perforation site in the ascending colon.

CASE REPORT

An 11-year-old previously healthy boy presented with complaints of persistent sharp, intermittent pain in the right and left lowers quadrants of his abdomen with a 1-day history of symptoms. His abdominal pain was accompanied by nausea, but no vomiting or fever. He had a history of constipation that required emergency department visits. On physical examination, the patient had tenderness localized to the right upper abdomen without rebound, with a negative Rovsing sign. A complete blood count, hepatic enzyme, and pancreatic enzyme levels were normal. Our patient demonstrated neutrophilia (79%), with an elevated C-reactive protein of 4.9 mg/dL. An abdominal x-ray was performed, which demonstrated a 1.6 × 0.4 cm radiopaque foreign body located within the right midabdomen, which seemed to be associated with the ascending colon with possible involvement of the loop of small bowel without evidence of free air (Figure 1). These foreign bodies consisted of 3 small round densities connected end to end. Moderately formed stool was scattered throughout the colon on the x-ray. The patient revealed accidentally swallowing 3 rare-earth magnets 3 days before. He was behaviorally and neurodevelopmentally appropriate for age.

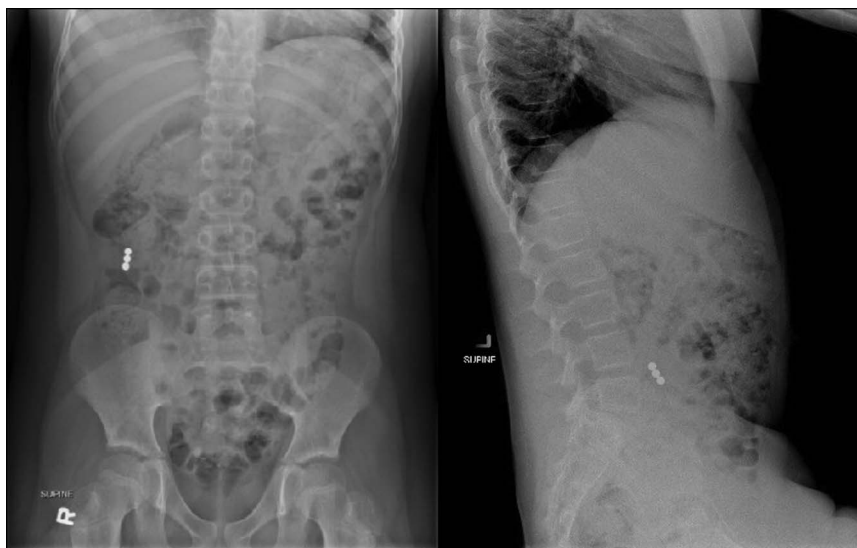

Figure 1. Anteroposterior and lateral abdominal x-ray showing foreign bodies located within the right midabdomen.

A nasogastric tube was placed for a bowel cleanout. During the hospital course, the abdominal pain was stable. The day after admission, a repeat abdominal x-ray showed the foreign body stagnant in position, and the decision was made to discontinue the bowel cleanout and proceed to colonoscopy with foreign body removal. This decision was made because of an effective cleanout and the concern for perforation with rare-earth magnets.

The water exchange technique and minimal CO₂ insufflation were used during the procedure. The colonoscopy revealed an embedded foreign body in the ascending colonic mucosa with perforation (Figure 2). A Roth net was used to grasp one magnet, and during an attempt to retrieve it, the second and the third magnets followed the first magnet into the lumen of the colon

(Figure 3). The third magnet was suspected to be in the small bowel because small intestine villi were observed while retrieving it. The magnets were placed in the colon, and the perforated colon was examined (Figure 4). We decided to place endoclips to approximate the colonic mucosal and submucosal borders, and a total of 5 endoclips were needed (Figure 5). Then, we successfully retrieved the magnets from the patient's colonic lumen (Figure 6). Surgical specialists were present throughout the procedure for consideration of operative management, and they were involved since admission.

After the procedure, the patient was asymptomatic, with regular bowel movements. C-reactive protein trended down to 2.98 mg/dL, and the white blood cells normalized. Post-procedure, abdominal and pelvic computed tomographies with

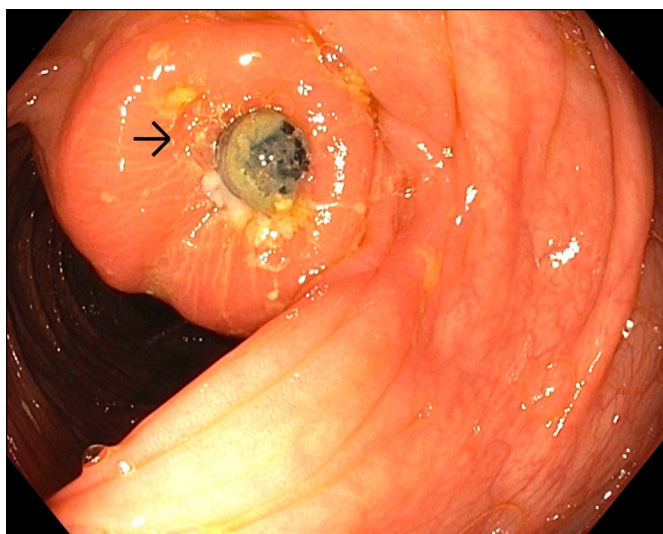


Figure 2. Foreign bodies embedded in the ascending colonic mucosa, the arrow is pointing the small intestine villi.

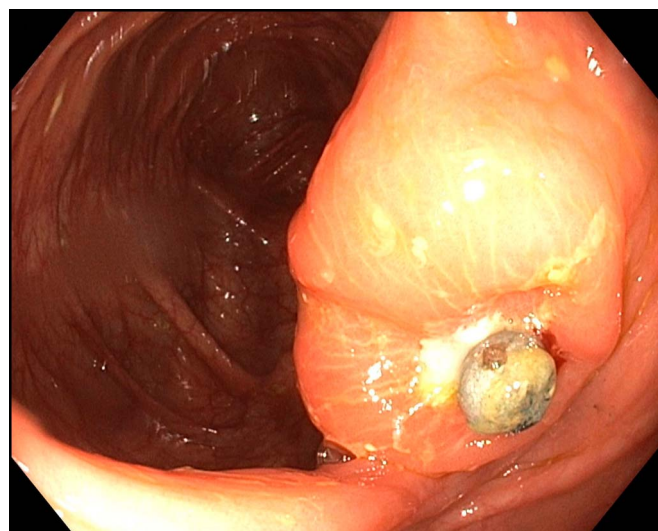


Figure 3. Magnets attracted in the luminal surface.

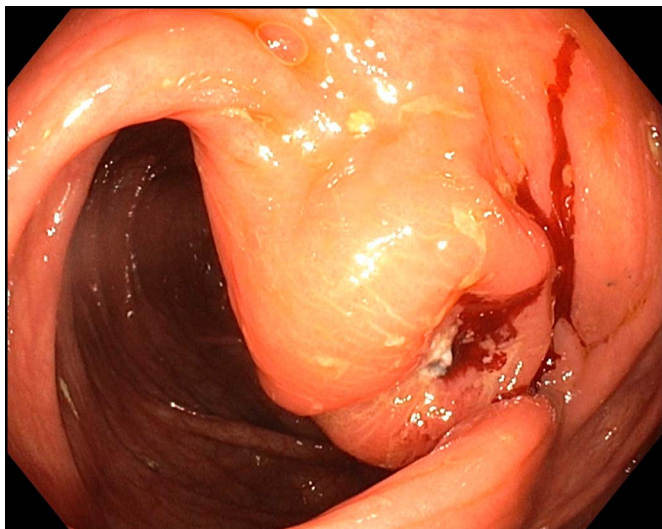


Figure 4. Perforated colonic mucosa.

oral and IV contrast were obtained to further evaluate for complications of the bowel perforation. The contrast studies showed no contrast leakage, no evidence of pneumoperitoneum, or enteric fistula. Systemic antibiotic (piperacillin/tazobactam) was initiated intraoperative, and he completed 10 days of oral antibiotics at home. During a follow-up period of 3 weeks, he was seen and remained asymptomatic, with no complications. He was continued on a stool softener for his constipation.

DISCUSSION

Ingestion of a foreign body is a common diagnosis in the pediatric population that may include coins, batteries, and jewelry.³ Children are usually less than 3 years.⁴ Management of the foreign body depends on the location, type, size of the foreign body, and the age and symptoms of the patient but

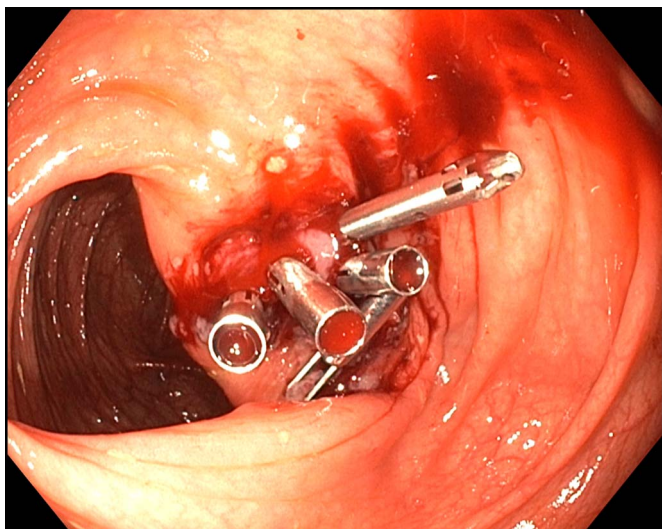


Figure 5. Apposition of the mucosa with 5 endoclips.

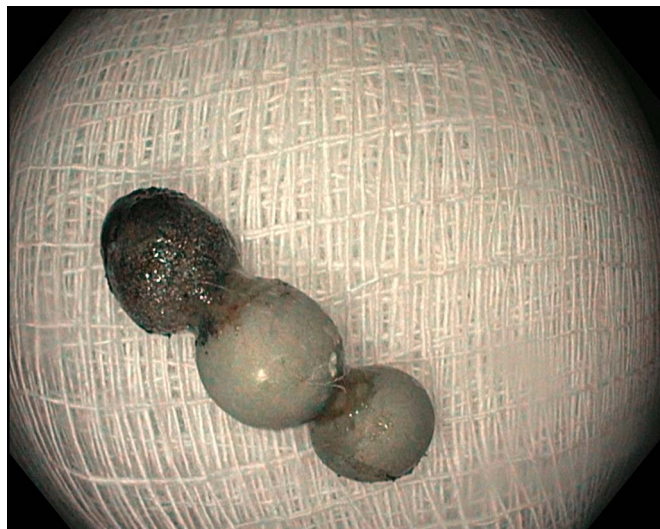


Figure 6. Three magnets retrieved.

usually pass through the gastrointestinal tract.⁴ However, magnets can attract each other across the bowel wall and can result in pressure necrosis, obstruction, perforation, and fistula formation increasing the risk of surgical intervention to 69.7%.² We suspect that in the patient, the magnets draped in between the mucosa of the ascending colon and the mucosa of the small intestinal mucosa causes erosion and necrosis, we were able to observe small bowel villi protruding in the colonic mucosa during the colonoscopy. The clinical manifestations of perforation include abdominal pain, nausea, vomiting, fever, peritonitis, anorexia, abdominal distention, and inconsolable crying in toddlers.⁵

Consumer Product Safety Commission has become aware of toy products containing rare-earth magnets that pose health hazards to children and issued a ban in 2009 on the sale of rare-earth magnets to children younger than 14 years.¹ The Consumer Product Safety Commission also prohibited magnets and magnets components that are loose and are swallow sized in toys for children younger than 14 years of age.¹ Hussain et al created an algorithm that uses the number, location, and timing of the ingestion of the magnets.⁶ For magnets beyond the stomach, it is advisable to remove them by enteroscopy or colonoscopy if the patient is asymptomatic, and there are no signs of obstruction or perforation on x-ray, with the consultation of the pediatric surgery team.⁶ After the progression of magnets on a serial abdominal x-ray is recommended.⁶ However, it is uncommon to find the presence of subdiaphragmatic free air on an abdominal radiograph in patients with foreign body perforation of the intestine caused by progressive impaction across bowel loops.⁷

There are no guidelines that describe the management of incidental bowel perforation during endoscopy in a pediatric patient. Conservative management with nil per os, nutritional support, and intravenous antibiotics should be performed

in the selected populations who do not exhibit signs of peritonitis or abdominal sepsis.^{8,9} Most of the perforated gastrointestinal tract in the pediatric population is managed with a surgical approach.² Novel endoscopic approaches have led to decreasing morbidity, improved quality of life, and decreased cost associated with surgical repair of the perforations.^{8,10,11} Endoscopic clipping has emerged as a technique that enables the gastroenterologist to manage colonic perforations, with a success rate of 81.7 % in an adult population.^{11,12} The experimental data demonstrated that the apposition of the mucosa and submucosa in the colonic wall created with endoclips is sufficient to provide an environment for wound healing.¹³

The use of clipping for perforation requires endoscopic experience and the availability of endoscopic equipment.¹⁴ It should be limited for defects less than 10 mm, adequate bowel preparation, and patient medical stability.¹⁴ To minimize leakage because of gravity, the colonoscopist should perform an adequate washing of the area, aspirate the fecal fluid, and change the patient position so that the lesion is placed as high as possible.¹⁴ Nevertheless, colonic perforations >30 mm have been managed with over-the-scope clip accompanied by conservative management.¹⁵ For perforations, more than 10 mm in size and located at an angulated part, Angsuwatcharakon et al described a technique with an endoscopic band ligation.¹⁶ Other novel methods for large colonic perforation include the application of polyglycolic acid sheet, fibrin glue, and covered metal stent.^{17,18}

There is no consensus for the management of colonic perforation with endoscopy intervention in a pediatric population. Conservative management should be an option in asymptomatic patients who are clinically stable and who have negative signs of obstruction on the abdominal x-ray. Any closure of this type should also be performed after consultation with the surgeon. The confidence and expertise of the endoscopist and the location, appearance of the defect, and the presence of appropriate endoscopic tools need to be taken into consideration before initiating endoscopic management.

DISCLOSURES

Author contributions: SM Camacho-Gomez wrote the manuscript and performed the literature review. JM Noel edited the manuscript. RA Noel edited the manuscript and is the article guarantor.

Financial disclosure: None to report.

Informed consent was obtained for this case report.

Received January 17, 2020; Accepted May 21, 2020

REFERENCES

1. Consumer Product Safety Commission (CPSC). *CPSC Warns High-Powered Magnets and Children Make a Deadly Mix*. (<https://www.cpsc.gov/Newsroom/News-Releases/2012/cpsc-warns-highpowered-magnets-and-children-make-a-deadly-mix>) (2011). Accessed May 5, 2019.
2. De Roo AC, Thompson MC, Chounthirath T, et al. Rare-earth magnet ingestion-related injuries among children. *Clin Pediatr (Phila)*. 2013;52(11):1006–13.
3. Tavaréz MM, Saladino RA, Gaines BA, et al. Prevalence, clinical features and management of pediatric magnetic foreign body ingestions. *J Emerg Med*. 2013;44:261–8.
4. Kay M, Wyllie R. Pediatric foreign bodies and their management. *Curr Gastroenterol Rep*. 2005;7(3):212–9.
5. Lin XK, Wu DZ, Lin XF, Zheng N. Intestinal perforation secondary to ingested foreign bodies: A single-center experience with 38 cases. *Pediatr Surg Int*. 2017;33:605–8.
6. Hussain S, Bousvaros A, Gilger M, et al. Management of ingested magnets in children. *J Pediatr Gastroenterol Nutr*. 2012;55:239–42.
7. Coulter B, Tancredi MH, Ramboux A. Spiral CT and multi-detector-row CT diagnosis of perforation of the small intestine caused by ingested foreign bodies. *Eur Radiol*. 2004;14:1918–25.
8. Sagawa T, Kakizaki S, Iizuka H, et al. Analysis of colonoscopic perforations at a local clinic and a tertiary hospital. *World J Gastroenterol*. 2012;18:4898–904.
9. Iqbal CW, Chun YS, Farley DR. Colonoscopic perforations: A retrospective review. *J Gastrointest Surg*. 2005;9(9):1229–35.
10. Shin DK, Shin SY, Park CY, et al. Optimal methods for the management of iatrogenic colonoscopic perforation. *Clin Endosc*. 2016;49(3):282–8.
11. Chan WK, Roslani AC, Law C, et al. Clinical outcomes and direct costings of endoluminal clipping compared to surgery in the management of iatrogenic colonic perforation. *J Dig Dis*. 2013;14:670–67.
12. Kim JS, Kim BW, Kim JJ, et al. Endoscopic clip closure versus surgery for the treatment of iatrogenic colon perforations developed during diagnostic colonoscopy: A review of 115,285 patients. *Surg Endosc*. 2013;27:501–50.
13. Raju GS, Pham B, Xiao SY, et al. A pilot study of endoscopic closure of colonic perforations with endoclips in a swine model. *Gastrointest Endosc*. 2005;62:791–5.
14. Taku K, Sano Y, Fu KI, et al. Iatrogenic perforation at therapeutic colonoscopy: Should the endoscopist attempt closure using endoclips or transfer immediately to surgery? *Endoscopy*. 2006;38:428.
15. Gubler C, Bauerfeind P. Endoscopic closure of iatrogenic gastrointestinal tract perforations with the over-the-scope clip. *Digestion*. 2012;85:302–7.
16. Angsuwatcharakon P, Thienchanachaiya P, Pantongrag-Brown L, Rerknimitr R. Endoscopic band ligation to create an omental patch for closure of a colonic perforation. *Endoscopy*. 2012;44:E90–1.
17. Sakaguchi Y, Tsuji Y, Yamamichi N, et al. Successful closure of a large perforation during colorectal endoscopic submucosal dissection by application of polyglycolic acid sheets and fibrin glue. *Gastrointest Endosc*. 2016;84:374–5.
18. Kim AW, Lee WH, Kim JS, et al. Successful management of colonic perforation with a covered metal stent. *Korean J Intern Med*. 2013;28:715–7.

Copyright: © 2020 The Author(s). Published by Wolters Kluwer Health, Inc. on behalf of The American College of Gastroenterology. This is an open-access article distributed under the terms of the Creative Commons Attribution-Non Commercial-No Derivatives License 4.0 (CCBY-NC-ND), where it is permissible to download and share the work, provided it is properly cited. The work cannot be changed in any way or used commercially without permission from the journal.