

# Technique to Fix the Stubborn Deviated Caudal Septum with an Internal Bone Graft Splint

Adnan G. Gelidan, MD, FRCSC,  
FACS

**Background:** Septoplasty, especially of the caudal portion, during cosmetic rhinoplasty is a crucial step in achieving satisfactory straight outcomes for the bony cartilaginous infrastructure and the skin envelope. Many methods are available, which range from septal mucosal resection to internal splinting by bone in a batten fashion; a power tool is usually used. This study describes a simple technique using a nonpower tool to correct the stubborn deviated caudal septum, with a thin available bone.

**Methods:** Patients who underwent cosmetic open septorhinoplasty for crooked nose deformity and did not respond to the traditional septoplasty techniques were included. Bony splint was harvested from the bony septum and fixed to the caudal septum using an 18-gauge needle to create holes to fix the bony splint to the caudal septum through horizontal matrix sutures to correct septal deviation.

**Results:** Six rhinoplasty patients who had significant caudal septal deviation and did not respond to the traditional techniques of septoplasty were included in this study. The patients were successfully treated by using an internal bony batten splint to correct the deviation. No postoperative complications were noted, and none of the patients required a revision surgery.

**Conclusions:** Bony batten graft is not a new concept. It involves correcting the resistant caudal septum deviation by splinting it internally by using power tools and drills to create the holes to fix the bony splint graft. Using an 18-gauge needle to drill the hole is a simple, quick, and effective technique to correct and straighten the septum for resistant cases. (*Plast Reconstr Surg Glob Open* 2021;9:e3921; doi: 10.1097/GOX.0000000000003921; Published online 20 December 2021.)

## INTRODUCTION

A deviated nasal septum causing a functional nasal airway obstruction and a crooked nasal cosmetic appearance is a common complaint in plastic surgery clinics. The deviated nasal infrastructure will reflect significantly on the overlying lower and upper lateral cartilages and skin envelope, which leads to major cosmetic concerns.<sup>1-3</sup> Nasal septum deviation can result from acquired, iatrogenic, and congenital factors.<sup>4,5</sup> Restoring the deviated septum, especially the caudal part, during open septorhinoplasty is crucial to achieving excellent outcomes. The presence of severe septal deviation, clinically and radiologically, is

a high prognosticator for difficult rhinoplasty, which can involve both the posterior or caudal nasal septum, and can be difficult to correct—even surgically.<sup>6</sup>

A straight house infrastructure is mandatory for a well-aligned building. A similar concept is applicable to cosmetic rhinoplasty. A straight bony and cartilaginous infrastructure is required to guarantee a straight and well-aligned external envelope of the upper and lower cartilages and external skin envelope.<sup>1-3</sup>

Many septoplasty procedures have been described to address the bony and cartilaginous septum, either through intracorporeal or extracorporeal techniques. Some of these approaches require the use of a power tool to create holes to fix the resected bony septum as an internal batten graft.<sup>7,8</sup>

In this article, the author presents a simple technique of open septorhinoplasty using the thin bony component of the septum to correct the stubborn deviated caudal septum by using a nonpower tool. Stubborn deviated caudal

From the Department of Surgery, King Khalid University Hospital, King Saud University, Riyadh, Saudi Arabia.

Received for publication May 14, 2021; accepted September 8, 2021.

Copyright © 2021 The Author. Published by Wolters Kluwer Health, Inc. on behalf of The American Society of Plastic Surgeons. This is an open-access article distributed under the terms of the [Creative Commons Attribution-Non Commercial-No Derivatives License 4.0 \(CCBY-NC-ND\)](#), where it is permissible to download and share the work provided it is properly cited. The work cannot be changed in any way or used commercially without permission from the journal.

DOI: 10.1097/GOX.0000000000003921

**Disclosure:** The author has no financial interest to declare in relation to the content of this article. This study was supported by the College of Medicine Research Center, Deanship of Scientific Research at King Saud University, Riyadh, Saudi Arabia.

septum cases that cannot be fixed using common septoplasty techniques were fixed with a simple technique, which involves the use of 10 surgical blades and 18-gauge needles to shape and fashion the native resected bone parts of the deviated septum (Vomer, or perpendicular plate of the ethmoid) as an internal batten graft to splint the caudal septum, without power tools. This technique is sufficient to straighten the septum in selected cases, and can be easily performed during open septorhinoplasty.

## METHODS

### Patient Information

This retrospective study included patients who had significant caudal septum deviation despite the use of the common septoplasty techniques and required an additional maneuver to address this stubborn septal deviation over the last 12 months. Demographic data, history of trauma, airway nasal obstruction symptoms, esthetic concerns, computed tomography scan findings, septoplasty technique, site of the bone graft site, size of bone graft, number of drilled holes, number of fixation sutures, graft location, distance from the caudal septum, type of suture, location of the concave or convex aspect of the graft, distance from the caudal septum, and outcomes were documented.

All patients who underwent open septorhinoplasty for crooked nose deformity due to severe caudal septum deviation were included and considered eligible for the study. Ethical approval was obtained from the institutional review board of King Saud University Medical City (Project No. E-20-4841). Informed consent was obtained from all patients.

### Operative Technique

All surgeries were performed by the author after obtaining patient consent, under general/local anesthesia: local anesthesia xylocaine (1%) with epinephrine (1:100000) and tranexamic acid (5 mL) was injected into the skin and sub-mucoperichondrial plane, and the nasal cavity was then packed with epinephrine (1 mL) mixed with normal saline (20 mL) for 8 min. External open approach rhinoplasty was performed through a short V trans-columellar and infra-cartilaginous elevated incision, and the septum was approached by dissecting the caudal-most part of the septum between the two medial crura with a pair of sharp scissors and a Cottle elevator in the sub-mucoperichondrial plane bilaterally, separating it from the upper lateral cartilage and nasal floor around the anterior nasal spine till the entire cartilaginous and bony septum were completely exposed. After assessing the deviated septum, a 1- to 1.5-cm L strut of the caudal and dorsal septum was preserved to maintain the nasal infrastructure stability and external nasal support by performing cartilage excision, preferably in one piece; then, the bony septum was assessed for deviation. If a deviation was observed, correction was performed by resecting the premaxilla-maxilla crest, vomer, or perpendicular plate of the ethmoid bone in one large piece, if possible (Fig. 1). A stubborn septum

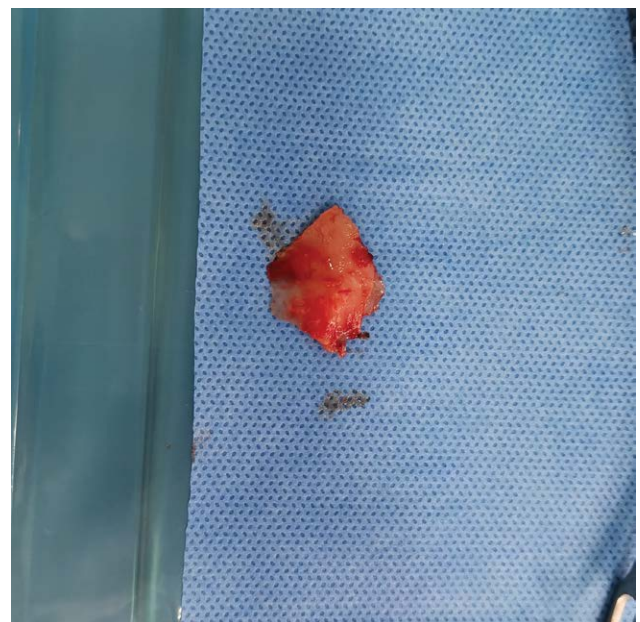### Takeaways

**Question:** How do you treat persistent deviation of caudal septum after using a traditional septoplasty technique?

**Findings:** Correction of persistent stubborn caudal septum deviation causing a crooked nose is possible with an internal bony batten graft internal splint harvested from the resected bony septum.

**Meaning:** The use of a bony batten graft for internal splinting is useful in patients with crooked deviated nose and functional airway obstruction due to a deviated nasal septum, especially the caudal portion. This out-of-the-box approach lessens the deviation and corrects the crooked deformity.

was diagnosed when all simple common septoplasty techniques, such as excision, scoring, suturing, or spreader grafting, failed to straighten the caudal septum. For such cases, an additional step is needed; therefore a batten bone graft was used to splint the caudal septum using the thin excised blocks of the vomer and ethmoid bone, thereby straightening and strengthening the caudal septum. The vomer and ethmoid bone are usually thin and can be modified into a rectangular-shaped graft to match the required size, approximately 10–12 mm in length and 6–8 mm in width, using a 10-size surgical blade (Fig. 2). Then, four to six holes were created by using a hand-held 18-gauge needle twisting maneuver to drill the bone without any power tools (Figs. 3–5). The maximum area of the deviation was visualized (Fig. 6), and the batten bone graft was positioned and fixed on the convex or concave side, 3–5 mm posterior and inferior to its edge, with two to three polydioxanone (PDS) 5/0 horizontal matrix sutures passed through the holes and the native septum to hold




**Fig. 1.** Vomer harvested from the bony septum.

it in a straighter position and to overcome the cartilage memory effect (Fig. 7). The remaining rhinoplasty steps of plication of the medial crura tip, cephalic trimming, and wound closure +/- osteotomy are needed. Dressing splints and nasal packs were also applied. Figures 8 and 9 show the technique for male and female patients, respectively.

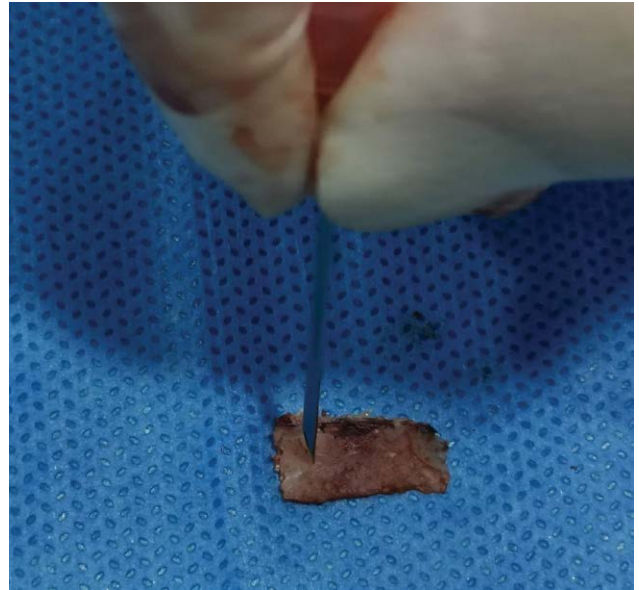
## RESULTS

### Demographic Data

A total of six patients (three men and three women) were included in this study. The mean age was 30.16 years (range: 20–57 years). None of the patients had any significant previous medical history. All patients had functional nasal obstruction, and all had cosmetic concerns regarding a part of their nose. Four patients had a history of trauma. All patients were assessed radiologically by computed tomography, which showed that the scans should have a variable degree of septal deviation and rotation S shape deformity. All patients underwent open septorhinoplasty with septoplasty and submucosal septal resection, preserving 1.2–1.5 cm of the dorsal and caudal septum. Spreader flaps (n = 2) and spreader grafts (n = 4) were used; cephalic trimming was performed in all patients (men: 6 mm; women: 5 mm). All patients underwent an internal osteotomy. Two patients underwent Weir excision. In all patients, the bone internal splint was harvested from the vomer or the perpendicular plate of the ethmoid bone. Five patients had four drilled holes with two horizontal matrix sutures, and one patient had six drilled holes with three 5/0 PDS horizontal matrix sutures of 5/0 PDS. The graft was fixed 4 mm posterior to the caudal septum on the concave side. All patients were functionally and cosmetically satisfied with the final outcomes.



**Fig. 2.** Vomer bone shaped into rectangular design using a 10 surgical blade.



**Fig. 3.** Drilling hole in the vomer using 18-gauge needle with a twisting maneuver.

### Postoperative Course

No postoperative complications were observed. All external and internal splints and sutures were removed on postoperative days 7–10. At the final 6-months follow-up, patients were satisfied due to the complete resolution of the functional airway obstruction and extremely satisfied with the esthetic outcomes. None of the patients required revision surgery, and none of the patients requested revision surgery.


## DISCUSSION

Our study shows that the use of an 18-gauge needle to drill the hole is a simple, quick, and effective technique for correction and straightening of the septum, which should always be considered when simple septoplasty techniques are unsuccessful.

Anatomically, the nasal septum consists of a bony part, formed by the premaxillary crest, vomer, and perpendicular plate of the ethmoid bone, which is thin and easy to drill, and a cartilaginous component, formed by the quadrangular cartilage and the membranous septum, which is more caudal toward the nasal tip.<sup>9,10</sup>

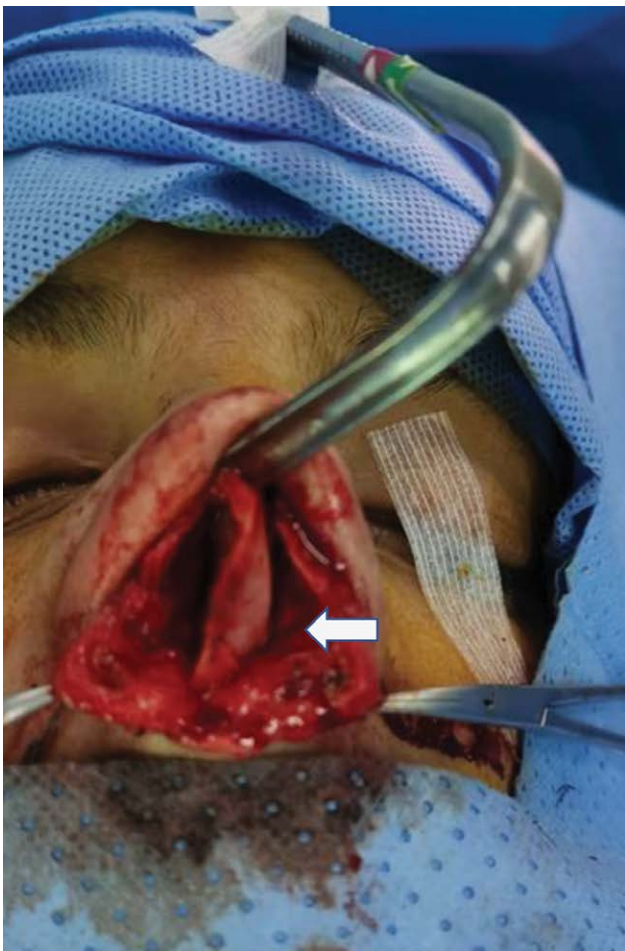

**Fig. 4.** The 18-gauge needle through the vomer bone.

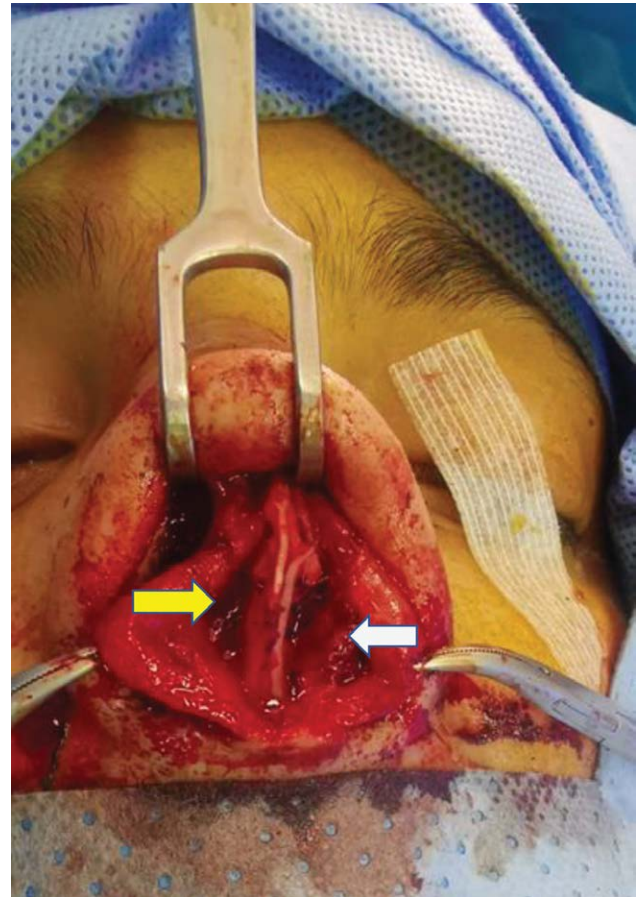


**Fig. 5.** Two holes drilled (white arrows show the second of the manual drilled holes in the bony septum).

Many septoplasty techniques (either intracorporeal or extracorporeal septoplasty techniques) have been reported. In 1966, Padovan et al were the first to perform septoplasty in conjunction with open rhinoplasty, followed by Goodman et al, who described a systematic approach to correct the septum during open rhinoplasty in 1973.<sup>7,8,11,12</sup> Sometimes, the cartilaginous part of the septum, especially the caudal septum, may resist correction due to a memory component of its cartilage, which is reflected in the functional and cosmetic outcomes, which are crucial



**Fig. 6.** Deviated caudal septum (indicated by the white arrow).



**Fig. 7.** Corrected caudal septum after internal bone batten graft fixed with two horizontal mattress sutures. The yellow arrow shows the native caudal septum after correction. The white arrow shows the bony batten sutured to the caudal septum.

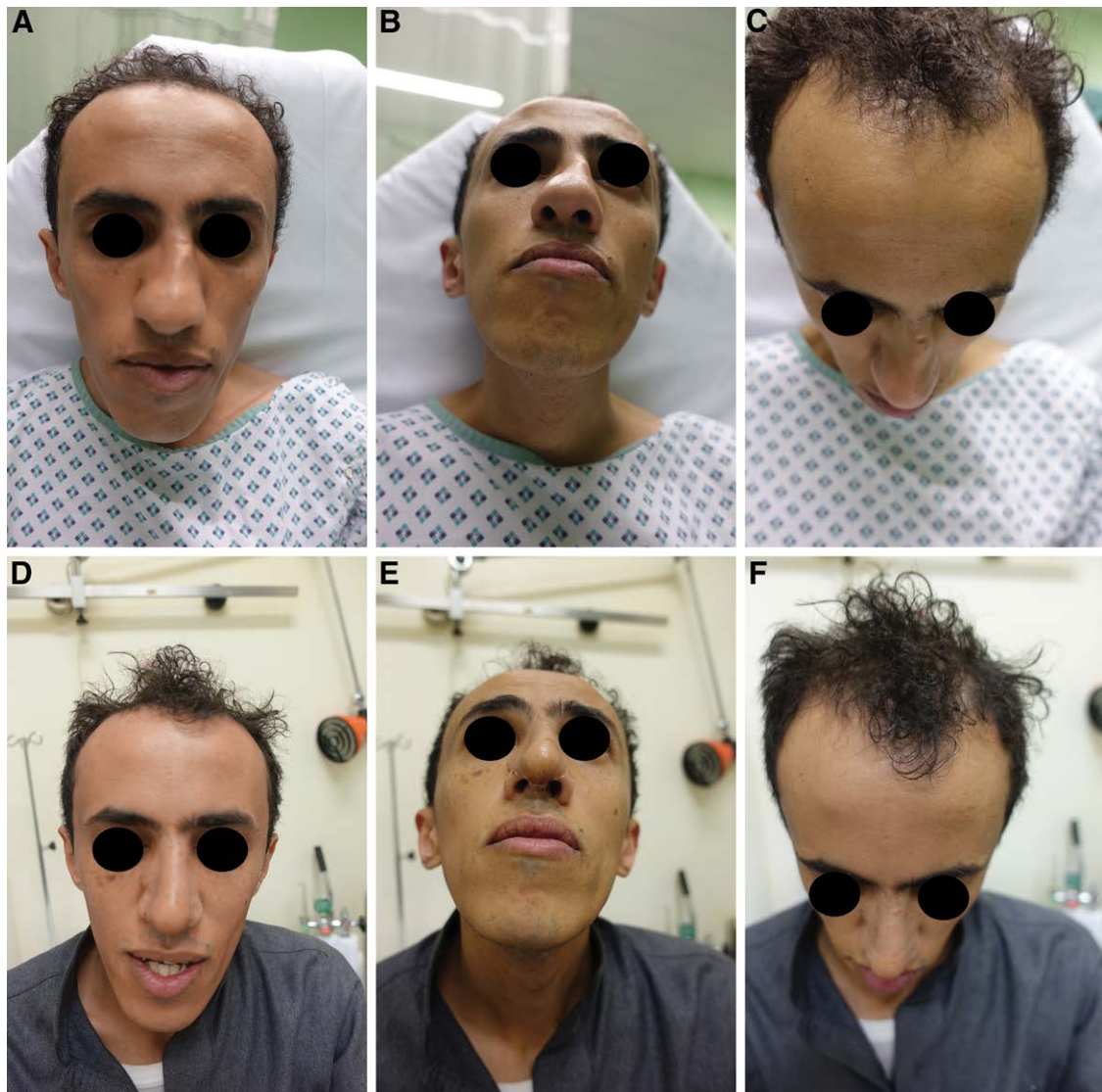when performing the rhinoplasty, thus requiring a more aggressive septoplasty technique.<sup>13</sup>

Bony batten graft is not a new concept. Many studies have reported the use of a batten septal graft as an internal splint.<sup>14,15</sup> In 1956, Digman first described the use of a splinting graft for correcting and straightening the deviated septum.<sup>16</sup>

Many native tissues, mainly those harvested from the nasal septum during excisional septoplasty, can be used as a splint to straighten the caudal septum, if needed. In secondary septoplasty, distant grafts may be used. Hussein et al used one large piece of septal cartilage to splint the entire caudal and dorsal septum during open septorhinoplasty.<sup>17</sup>

Chung et al used a septum with a batten graft to correct septal and caudal deviation and demonstrated a significant improvement in symptoms.<sup>14</sup> Kim et al utilized a resected bony septum of variable sizes to straighten the caudal septum as a bony batten bone graft to straighten the caudal septum, and holes were drilled for fixation using power drilling tools, yielding excellent outcomes.<sup>15</sup>

Using power tools to shape and drill holes is the most common technique used to fashion the batten



**Fig. 8.** A 26-year-old male presented with the complaints of nasal deformity, crooked nose, and functional breathing concerns seeking cosmetic rhinoplasty. A–C, Preoperative views with posttraumatic right nasal deviation. D–F, Postoperative views of the patient's face after 10 days, showing consistent satisfactory results.

bone graft for internal splinting. Such tools are not available in all hospitals and private plastic surgery centers because they are expensive, and the whole process is time-consuming. Because of the thin nature of the septal bony component, shaping the bone with 10 surgical blades and drilling holes using an 18-gauge needle by hand in a twisting motion is a simple, efficient, and fast technique that can be performed in any surgical facility. Many studies have described the use of a batten graft, including the concept of a cartilage or bone graft as an internal splint to straighten the caudal septum.<sup>16,17</sup>

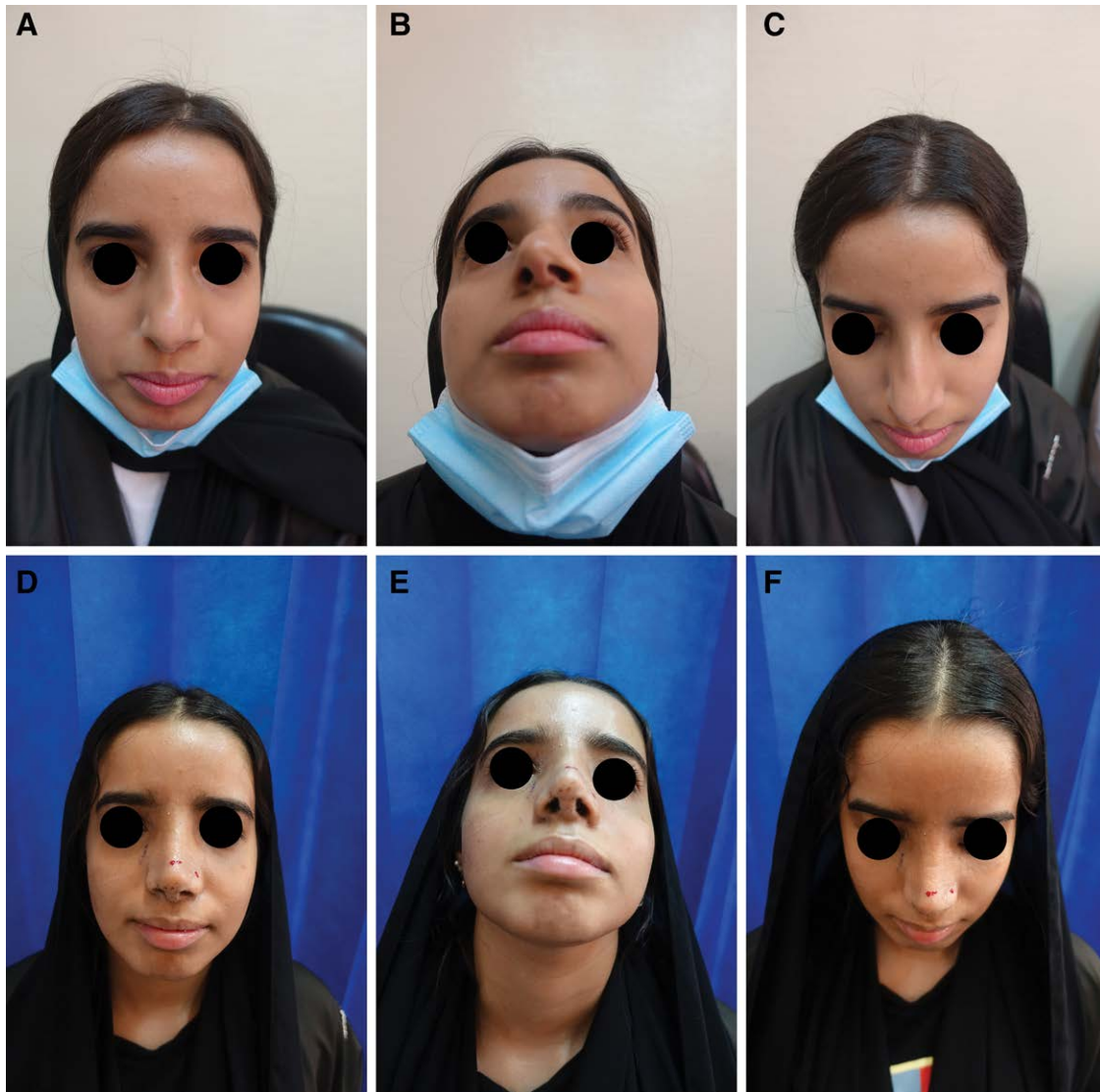Shaping and creating a bony batten graft for internal splinting is easy, and holes that are enough to fit two to three horizontal sutures can be made with ease, thus correcting the functional element of the septal obstruction and straightening the deviated septum,

especially in the caudal component. Furthermore, this will reflect on the cosmetic outcomes of the rhinoplasty, which will be enhanced by correcting the cartilaginous infrastructure.

This simple out-of-the-box technique is sufficient to straighten the caudal septum, eliminate functional septal obstruction, and improve the cosmetic element, which is a critical step in accomplishing excellent cosmetic rhinoplasty. The technique should always be kept in the surgeon's armamentarium for septoplasty reconstruction ladder even in cosmetic rhinoplasty when all simpler techniques fail.

## CONCLUSIONS

The use of a bony batten graft for internal splinting is useful in patients with a crooked deviated nose and functional airway obstruction due to a deviated nasal septum,



**Fig. 9.** A healthy 25-year-old woman presented with the complaints of nasal deformity, crooked nose, and functional breathing concerns seeking cosmetic rhinoplasty. A–C, Preoperative views with posttraumatic right nasal deviation. D–F, Postoperative views of the patient's face after 10 days, showing consistent satisfactory results.

especially the caudal portion, who require an out-of-the-box approach to correct the stubborn septum. Using a bone batten graft for internal splinting is very beneficial in reducing deviation and correcting crooked deformity. Typically, a power tool is used to drill holes. However, because of the thin nature of the septal bony component, shaping the bone with a 10-size surgical blade and drilling the holes using a hand-held 18-gauge needle twisting maneuver is a simple, effective, efficient, and fast technique that can be performed in any surgical facility. Furthermore, this technique does not increase the operative time and yields excellent functional and esthetic outcomes. Therefore, surgeons should always keep this technique in mind for septoplasty reconstruction, even in cosmetic rhinoplasty, in cases where all simple septoplasty techniques fail. It usually requires a power tool for creating the holes, but because

the septal bone is thin and easy to drill, using an 18-gauge needle is a simple and fast technique that can be used by all plastic surgeons, and it will not increase operative time and will yield excellent outcome in correcting the functional and aesthetic concerns.

*Adnan G. Gelidan, MD, FRCSC, FACS*  
 Department of Surgery  
 King Khalid University Hospital  
 King Saud University  
 7488 Riyadh  
 3316 Saudi Arabia  
 E-mail: [adnangelidan@gmail.com](mailto:adnangelidan@gmail.com)

#### PATIENT CONSENT

*The patients provided written consent for the use of their images.*

## REFERENCES

1. Parrila C, Artuso A, Gallus R, et al. The role of septal surgery in cosmetic rhinoplasty. *ACTA Otorhinolaryngologica Italica*. 2013;33:146–153.
2. Nease CJ, Deal RC. Septoplasty in conjunction with cosmetic rhinoplasty. *Oral Maxillofacial Surg Clin N Am*. 2012;24:49–58.
3. El-Wafa AM, Emara S. Deviated nose: a systematic approach for correction. *Plast Reconstr Sur Glob Open*. 2020;8:e3078.
4. Teixeira J, Certal V, Chang ET, et al. Nasal septal deviations: a systematic review of classification systems. *Plast Surg Int*. 2016;2016:7089123.
5. Foda HT. The role of septal surgery in management of the deviated nose. *Plast Reconstr Surg*. 2005;115:406.
6. Surowitz J, Lee MK, Most SP. Anterior septal reconstruction for treatment of severe caudal septal deviation: clinical severity and outcomes. *Otolaryngol Head Neck Surg*. 2015;153:27–33.
7. Fettman N, Sanford T, Sindwani R. Surgical management of deviated septum: techniques in septoplasty. *Otolaryngol Clin Noth Am*. 2009;42:241–252.
8. Persichetti P, Toto V, Signoretti M, et al. The correction of nasal septal deviations in rhinoplasty. *Ann Oral Maxillofacial Surg*. 2013;1:13.
9. Straatsma B, Straatsma C. The anatomical relationship of the lateral nasal cartilage to nasal bone and the cartilaginous nasal septum. *Plast Reconstr Surg*. 1951;8:443–455.
10. Neskey D, Eloy JA, Casiano RR. Nasal, septal, and turbinate anatomy and embryology. *Otolaryngol Clin N Am*. 2009;42:193–205.
11. Goodman WS. Septo-rhinoplasty: surgery of the nasal tip by external rhinoplasty. *J Laryngol Otol*. 1980;94:485–494.
12. Goodman WS, Charbonneau PA. External approach to rhinoplasty. *Laryngoscope*. 1974;51:299–316.
13. Jin HR, Lee JY, Shin SO, et al. Key maneuvers for successful correction of deviated nose in Asians. *Am J Rhinol*. 2006;20:609–614.
14. Chung YS, Seol JH, Choi JM, et al. How to resolve the caudal septal deviation? Clinical outcomes after septoplasty with bony batten grafting. *Laryngoscope*. 2014;124:1771–1776.
15. Kim D, Nam SH, Al-harethy S, et al. Surgical outcomes of bony batten to correct caudal septal deviation in septoplasty. *JAMA Facial Plas Surg*. 2017;19:470–475.
16. Digman R. Correction of nasal deformities due to defect of the septum. *Plast Reconstr Sur*. 1956;18:291–304.
17. Hussein WK, Bazak R. Batten graft septoplasty: evaluation of a preferred technique. *Egyptian J Ear Nose Throat Allied Sci*. 2015;16:223–229.