

Intraoperative Arachnoid Plasty Has Possibility to Prevent Chronic Subdural Hematoma after Surgery for Unruptured Cerebral Aneurysms

Kenji YAGI,^{1,2} Shinsuke IRIE,¹ Toru INAGAKI,¹ Yosuke ISHII,¹ Osamu SAITO,¹ Tejin LEE,¹ Hiroshi NAKAGAWA,¹ Koji SAITO,¹ and Shinji NAGAIRO^{1,2}

¹Department of Neurosurgery, Kushiro Kojinkai Memorial Hospital, Kushiro, Hokkaido;

²Department of Neurosurgery, Graduate School of Health Biosciences, Tokushima University, Tokushima, Tokushima

Abstract

Some patients develop chronic subdural hematomas (CSDHs) after the clipping/coating of unruptured aneurysms. The risk factors are not well understood and while no preventive methods are currently available, arachnoid plasty (ARP) may intercept the development of postoperative CSDH. We investigated the risk factors for CSDH and the usefulness of ARP to prevent postoperative CSDH. Between January 2009 and June 2013, 393 patients underwent 416 aneurysm surgeries via the pterional approach at Kushiro Kojinkai Memorial Hospital. Of these, 394 aneurysms (371 patients) were included in this study. Using multivariate analysis we evaluated the relationship between the patient demographics and clinical characteristics, and the development of postoperative symptomatic CSDH. We also studied the effect of ARP performed during aneurysm surgery. We found that symptomatic CSDH developed after 20 (5.1%) of the 394 operations; it was addressed by burr hole surgery and evacuation/irrigation. Male gender, advanced age, and oral anticoagulant therapy were significant risk factors for CSDH. Additive ARP, performed in the course of 132 surgeries (33.5%) was found to be a significant negative risk factor. The incidence of CSDH was significantly lower in patients who had undergone ARP than in patients who had not undergone it (0.8% vs. 7.3%, $p < 0.01$). We first report that ARP is useful for the prevention of CSDH in patients treated by aneurysm surgery.

Key words: arachnoid plasty, unruptured aneurysm, chronic subdural hematoma, clipping

Introduction

Chronic subdural hematoma (CSDH) may be seen several weeks after head trauma. Predisposing risk factors include advanced age, male gender, heavy alcohol consumption, brain atrophy, antiplatelet therapy, anticoagulant therapy, and intracranial arachnoid cysts.^{1–4} While the reported incidence of post-craniotomy CSDH is low (0.3–1.5%),^{2,5,6} 1.7–4.1% of patients treated by aneurysm surgery develop CSDH.⁵ Although the highest incidence is seen after surgery for unruptured aneurysms, few studies have investigated this issue^{5,7} and there are currently no strategies to prevent postoperative CSDH.

Subdural effusion due to cerebrospinal fluid (CSF) leakage through the breached arachnoid membrane is thought to initiate the development of CSDH

after aneurysm surgery.^{5,6,8} Under the hypothesis that arachnoid plasty (ARP), a procedure to close the arachnoid membrane, may help to prevent postoperative development of CSDH we retrospectively investigated the benefits of intraoperative ARP in patients undergoing aneurysm surgery. We also assessed the risk factors for developing postoperative CSDH.

Methods and Materials

Between January 2009 and June 2013, 393 patients underwent 416 operations via the pterional approach to address unruptured cerebral aneurysms at Kushiro Kojinkai Memorial Hospital. We reviewed their surgical and clinical records to determine the incidence of postoperative CSDH after clipping/coating of cerebral aneurysms via the pterional approach. Of the 416 operations, 10 cases were performed in the

course of removing brain tumors or arteriovenous malformations; 3 cases underwent treatment for CSDH within 6 months before aneurysm surgery; these 13 cases were excluded from our retrospective study.

Our strategy for surgery via the pterional approach was to dissect and open the Sylvian fissure widely to avoid extensive retraction and iatrogenic brain damage. After clipping the aneurysm, in the 138 surgeries, we performed additive ARP. In the absence of standard indications for ARP, its appropriateness in individual cases was determined by the operating neurosurgeon. Different ARP techniques have been suggested.^{9–11} Ours is simple; the widely-opened Sylvian fissure is covered with thin strips of absorbable gelatin sponge (Gelfoam®, Pfizer Japan Inc., Tokyo) and closed with fibrin glue (Beriplast® P Combi-Set, CSL Behring LLC, Tokyo or Bolheal®, Astellas Pharma Inc., Tokyo) (Fig. 1) After ARP, artificial CSF (ARTCEREB® irrigation and perfusion solution for cerebrospinal surgery, Otsuka Pharma Factory Inc., Naruto, Tokushima) is infused into the closed subarachnoid space through a catheter inserted into the Sylvian fissure. Immediately after withdrawing the catheter, the hole in the artificial membrane is closed with a small piece of absorbable gelatin sponge.

Patients were followed in our hospital and/or associated hospitals and clinics. Those with symptomatic CSDH and significant brain shift underwent burr hole surgery and hematoma drainage with or without irrigation. Patients with symptomatic CSDH and no history of head trauma within 6 months after aneurysm clipping were recorded as manifesting postoperative CSDH. All patient data were reviewed to record the incidence of CSDH and to rule out the likelihood of its postoperative occurrence. Patients who did not manifest postoperative CSDH for 6 months, and patients without progressive CSDH or

subdural effusion on radiological studies during at least 3-month postoperative follow-up were recorded as CSDH-free.

Hypertensive patients were defined as those with a systolic blood pressure > 140 mmHg and/or a diastolic blood pressure > 90 mmHg and patients on anti-hypertensive drugs. Dyslipidemic patients were defined as patients with a low-density lipoprotein cholesterol level > 140 mg/dl, a high-density lipoprotein cholesterol level < 40 mg/dl, and/or patients taking lipid-lowering drugs. Patients were classified as diabetic if their level of glycosylated hemoglobin A1c exceeded 6.5% or if they were treated with insulin and/or oral hypoglycemic drugs. Patients were considered current smokers if they had smoked tobacco within the past year and as daily drinkers if they consumed alcoholic beverages every day. We also recorded patients treated with peroral antiplatelet or anticoagulant drugs within 3 months after their aneurysm surgery.

The lesion site was recorded [middle cerebral artery (MCA), internal carotid artery (ICA), and deep site] according to its depth; the anterior communicating artery (AcomA), anterior cerebral artery (ACA), and basilar artery (BA) were considered deep sites. The MCA was considered to be closest to the convexity, followed by the ICA, and then by deep-sited aneurysms. When the operated aneurysms were located at more than two sites, the deepest site was recorded as the surgical site.

Statistical analyses were performed with StatView 5.0 (SAS institute Inc., NC, USA). For univariate analysis we used the Fisher exact test, the χ^2 test, or the Student's *t*-test. When the univariate *p* value was less than 0.2, the variables were considered for multivariate assessment by logistic regression analysis. Differences of *p* < 0.05 were considered significant. Numerical data are expressed as the mean \pm standard deviation.

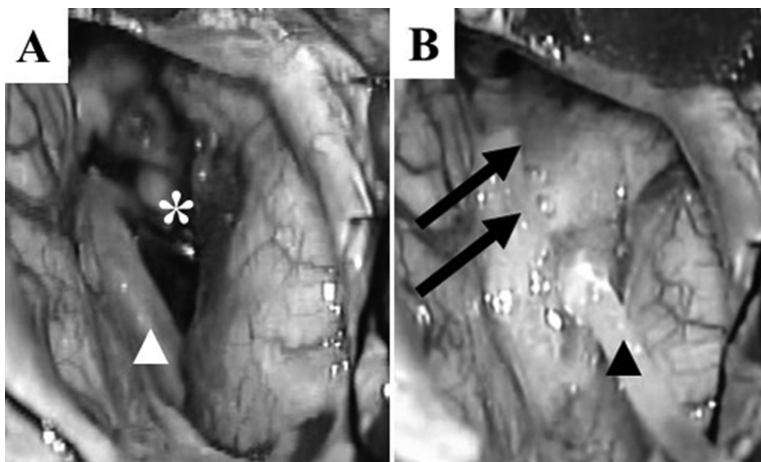


Fig. 1 Intraoperative photographs of arachnoid plasty (ARP). The Sylvian fissure (*) is opened wide for clipping of the cerebral aneurysm (A) and then closed and covered by ARP (B). After inserting a catheter (black arrowhead) into the subarachnoid space, the Sylvian fissure is covered with an artificial arachnoid membrane (arrow) made of fibrin glue and pieces of absorbable gelatin sponge. This is followed by the infusion of artificial cerebrospinal fluid (CSF) into the subarachnoid space through the catheter. After withdrawing the catheter, the hole in the artificial membrane is closed with a small piece of absorbable gelatin sponge (white arrowhead: Sylvian vein).

Results

Of the 416 aneurysm surgeries performed between January 2009 and June 2013, 13 were excluded from this study and 9 were lost to follow-up; 6 underwent ARP and 3 did not. The remaining 394 procedures (371 patients) were available for analysis; 382 were followed up for 6 months or until the manifestation of symptomatic CSDH, and in the other 12 the potential development of CSDH was ruled out because there was no evidence of significant subdural effusion/CSDH on computed tomography/magnetic resonance imaging (CT/MRI) studies performed more than 3 months postoperatively. The demographics and baseline characteristics of the 371 patients who underwent 394 procedures and their clinical characteristics are shown in Table 1. ARP was added to 132 aneurysm surgeries (33.5%) and no severe adverse events were associated with ARP, e.g., allergic reactions, occurred.

Symptomatic CSDH, developed after 20 operations (5.1%), was addressed by burr hole surgery performed from 1 month to 5 months after the initial operation (mean 8.3 ± 2.8 weeks) and evacuation/irrigation. The symptoms were weakness/gait disturbance (12/20, 60%), headache (8/20, 40%), disorientation/drowsiness (3/20, 15%), and dizziness (2/20, 10%). All 20 CSDHs were unilateral; 17 (85%) were ipsilateral to the pterional approach, the other 3 were contralateral.

As shown in Table 1, the significant risk factors for postoperative CSDH, assessed by univariate analysis, were male gender, anticoagulant therapy, and surgery without ARP.

Next, multivariate analysis was performed to identify risk factors for postoperative CSDH and to determine whether ARP prevented CSDH. We entered factors with a p value < 0.20 by univariate analysis as the variables; male gender, advanced age, dyslipidemia, postoperative administration of anticoagulants, and intraoperative ARP were included. Male gender, age, and postoperative administration of anticoagulants were significant risk factors (Table 2). And ARP was found to be a significant negative risk factor. As shown in Fig. 2, the incidence of postoperative CSDH was significantly lower after procedures that included ARP (0.8% vs. 7.3%, $p < 0.01$).

In the absence of standard indications for ARP, the decision to perform intraoperative ARP was made by the operating neurosurgeon who took into account the patient's risk factors for CSDH. Age, a significant risk factor for postoperative CSDH, was significantly higher in patients who underwent ARP

Table 1 Demographic, baseline, and clinical characteristics

	Total procedures n = 394 (%)	CSDH		p value
		No n = 374 (%)	Yes n = 20 (%)	
Demographics and baseline characteristics				
Males	92 (23.4)	80 (21.4)	12 (60.0)	< 0.01
Age (years)	62.9 ± 9.7	62.7 ± 9.8	66.4 ± 7.4	< 0.101
Hypertension	264 (67.0)	250 (66.8)	14 (70.0)	0.770
Dyslipidemia	173 (43.9)	167 (44.7)	6 (30.0)	0.198
Diabetes mellitus	41 (10.4)	41 (11.0)	0 (0)	0.248
Smoking	111 (28.2)	104 (27.8)	7 (35.0)	0.486
Daily alcohol drinkers	63 (16.0)	59 (15.8)	4 (20.0)	0.541
Clinical characteristics				
Multiple aneurysms	51 (12.9)	49 (13.1)	2 (10.0)	> 0.999
Aneurysm location				
MCA	155 (39.3)	148 (39.6)	7 (35.0)	0.870
ICA	139 (35.3)	132 (35.3)	7 (35.0)	
Deep site	100 (25.4)	94 (25.1)	6 (30.0)	
Duration of surgery (min)	209 ± 95	208 ± 94	225 ± 110	0.228
Number of clips used	2.2 ± 1.0	2.2 ± 1.1	1.9 ± 0.9	0.228
Antiplatelet therapy	73 (18.5)	68 (18.2)	5 (25.0)	0.391
Anticoagulant therapy	8 (2.0)	5 (1.3)	3 (15.0)	< 0.01
ARP	132 (33.5)	131 (35.0)	1 (5.0)	< 0.01

ARP: arachnoid plasty, CSDH: chronic subdural hematoma, ICA: internal carotid artery, MCA: middle cerebral artery.

Table 2 Multivariate analysis of risk factors for postoperative CSDH

Variables	OR (95% CI)	p value
Male	8.22 (2.90–23.3)	< 0.01
Age	1.08 (1.01–1.15)	0.019
Use of anticoagulants	22.4 (2.59–193)	< 0.01
Dyslipidemia	0.487 (0.167–1.42)	0.187
ARP	0.064 (0.008–0.538)	0.011

ARP: arachnoid plasty, CI: confidence interval, CSDH: chronic subdural hematoma, OR: odds ratio.

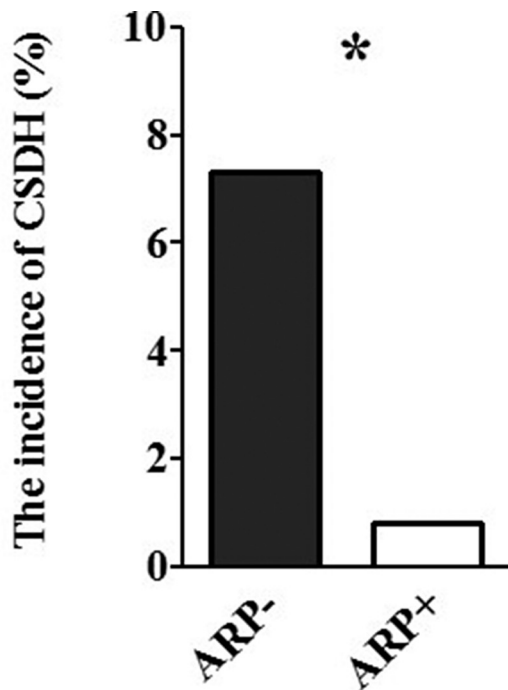


Fig. 2 The incidence of postoperative chronic subdural hematoma (CSDH) was significantly lower after aneurysm surgery with ARP than without it (* $p < 0.01$).

(64.5 ± 9.0 vs. 62.0 ± 9.9 , $p < 0.016$); in patients who received anticoagulant or antiplatelet therapy the rate of ARP was higher than in those who did not (50% vs. 32.2%, $p < 0.45$ and 38.4% vs. 32.4%, $p < 0.330$) but the difference was not statistically significant. Slightly fewer females than males underwent ARP (male 30.4% vs. female 34.4%, $p < 0.51$).

Discussion

CSDH after aneurysmal surgery is a common complication whose evacuation requires additional surgical intervention. Although some of the risk factors for postoperative CSDH are known,^{5,7} there have been no means to prevent its occurrence. We first document that ARP effectively inhibits the development of postoperative CSDH.

The mechanisms underlying the development of traumatic/spontaneous and post-craniotomy CSDH are not completely understood. In traumatic CSDH, CSF leakage through the arachnoid membrane torn by the head injury is thought to initiate its development. This is followed by subdural bleeding due to stretching of the bridging vein, and by the formation of a capsular membrane over the hematoma. CSF leakage through the inner- and bleeding from the outer membrane result in CSDH development and enlargement.^{2,5,12}

They may also play a role in CSDH after aneurysmal surgeries. This hypothesis is supported by the finding that subdural fluid collection was a significant predictor of postoperative CSDH in patients operated for unruptured aneurysms.^{5,8} Our observation that 85% of CSDH were ipsilateral when the aneurysms were addressed via the pterional approach also supports this hypothesis. The low incidence of CSDH after surgeries for ruptured cerebral aneurysms may be attributable to brain swelling.⁵ Mino et al.¹¹ reported that in patients treated for ruptured cerebral aneurysms, ARP suppressed subdural effusion. We suggest that the CSDH-suppressing effect of ARP in patients undergoing surgery for unruptured aneurysms may be due to blocking of the pathway of CSF leaks into the subdural space.

Inamasu et al.⁷ and Ohno et al.⁵ also identified advanced age and male gender as significant risk factors for CSDH after aneurysm surgery as well as for traumatic/spontaneous CSDH. While patients treated with antiplatelet or anticoagulant therapy have been reported to be at risk for traumatic/spontaneous CSDH,^{1,3,4} this type of treatment has not previously been identified as a risk for CSDH after aneurysm surgery. In our series, only patients subjected to clipping of unruptured aneurysms who also received anticoagulants were at significantly higher risk for postoperative CSDH. While patients treated with antiplatelet therapy had a higher incidence of postoperative CSDH, there was no statistically significant difference. Additional studies are underway to determine whether postoperative antiplatelet treatment poses a risk for the development of CSDH in patients treated by aneurysm surgery.

In our series the incidence of postoperative CSDH was 5.1% after clipping surgery for unruptured aneurysms. In patients who underwent the pterional approach without ARP it was 7.3% and thus higher in our than earlier series (2%),^{5,7} possibly because our study included more high-risk patients: they were older, and the number of patients receiving antiplatelet and anticoagulant therapy was higher.

Our study has some limitations. It was retrospective and there were differences in the background of our patients and the surgical procedures performed with and without ARP. As there is no standard indication for ARP, the decision to perform the procedure in the course of aneurysm surgery in patients at high risk for CSDH was made by the operating neurosurgeon. ARP was more frequently performed in patients known to be at risks for the development of postoperative CSDH and the incidence of postoperative CSDH was effectively reduced in that patient subgroup.

We used fibrin glue and gelatin sponges for ARP. These agents are widely used in neurosurgery and are considered safe.^{11,13)} None of our patients experienced severe adverse events although rare allergic reactions to these materials, e.g., aseptic meningitis and anaphylactic shock, requiring the administration of steroids have been reported.^{14,15)}

Based on our findings, we suggest that older male patients with aneurysms who had been treated with anticoagulant drugs should be considered candidates for additive ARP to prevent the development of postoperative CSDH. A double-blind randomized study is needed to confirm the protective effect of ARP against CSDH in patients subjected to aneurysm surgery.

Conclusion

Our retrospective study is the first to document the protective effect of intraoperative ARP against postoperative CSDH in patients undergoing aneurysm surgery.

Financial and Material Support

None.

Conflicts of Interest Disclosure

The authors report no conflict of interest concerning the materials or methods used in this study or the findings reported in this manuscript.

References

- 1) Aspegren OP, Astrand R, Lundgren MI, Romner B: Anticoagulation therapy a risk factor for the development of chronic subdural hematoma. *Clin Neurol Neurosurg* 115: 981–984, 2013
- 2) Mori K, Maeda M: Risk factors for the occurrence of chronic subdural haematomas after neurosurgical procedures. *Acta Neurochir (Wien)* 145: 533–539; discussion 539–540, 2003
- 3) De Bonis P, Trevisi G, de Waure C, Sferrazza A, Volpe M, Pompucci A, Anile C, Mangiola A: Antiplatelet/anticoagulant agents and chronic subdural hematoma in the elderly. *PLoS ONE* 8: e68732, 2013
- 4) Baechli H, Nordmann A, Bucher HC, Gratzl O: Demographics and prevalent risk factors of chronic subdural haematoma: results of a large single-center cohort study. *Neurosurg Rev* 27: 263–266, 2004
- 5) Ohno T, Iihara K, Takahashi JC, Nakajima N, Satow T, Hishikawa T, Nagata I, Yamada K, Miyamoto S: Incidence and risk factors of chronic subdural hematoma after aneurysmal clipping. *World Neurosurg* 80: 534–537, 2013
- 6) Tanaka Y, Mizuno M, Kobayashi S, Sugita K: Subdural fluid collection following craniotomy. *Surg Neurol* 27: 353–356, 1987
- 7) Inamasu J, Watabe T, Ganaha T, Yamada Y, Nakae S, Ohmi T, Imizu S, Kaito T, Ito K, Nishiyama Y, Hayashi T, Sano H, Kato Y, Hirose Y: Clinical characteristics and risk factors of chronic subdural haematoma associated with clipping of unruptured cerebral aneurysms. *J Clin Neurosci* 20: 1095–1098, 2013
- 8) Koizumi H, Fukamachi A, Nukui H: Postoperative subdural fluid collections in neurosurgery. *Surg Neurol* 27: 147–153, 1987
- 9) Nagata K: A proposal of the arachnoid closure for the prevention of postoperative subdural hygroma: a new appliance of mesh-and glue technique. *Surg Cereb Stroke (Jpn)* 28: 25–30, 2000
- 10) Nishimura S, Fujita T, Hiroyuki S, Hori E, Mino M, Michiharu N: Chronic subdural hematoma and remote cerebellar hemorrhage developing after unruptured aneurysmal surgery. *Surg Cereb Stroke (Jpn)* 37: 350–356, 2009
- 11) Mino Y, Hirashima Y, Hamada H, Masuoka T, Yamatani K, Takeda S, Masuda R, Nogami K, Endo S: Effect of arachnoid plasty using fibrin glue membrane after clipping of ruptured aneurysm on the occurrence of complications and outcome in the elderly patients. *Acta Neurochir (Wien)* 148: 627–631; discussion 631, 2006
- 12) Watanabe S, Shimada H, Ishii S: Production of clinical form of chronic subdural hematoma in experimental animals. *J Neurosurg* 37: 552–561, 1972
- 13) Gazzeri R, Galarza M, Neroni M, Alfieri A, Giordano M: Hemostatic matrix sealant in neurosurgery: a clinical and imaging study. *Acta Neurochir (Wien)* 153: 148–154; discussion 155, 2011
- 14) Wakamoto H, Miyazaki H, Orii M, Ishiyama N, Akiyama K, Konohana I: [Aseptic meningitis as a complication caused by an allergic reaction after microvascular decompression: two case reports]. *No Shinkei Geka* 30: 1331–1335, 2002
- 15) Kanazawa R, Sato S, Iwamoto N, Teramoto A: Allergic reaction following arachnoid plasty with a fibrin sealant. *Neurol Med Chir (Tokyo)* 50: 608–610, 2010

Address reprint requests to: Kenji Yagi, MD, PhD, Department of Neurosurgery, Kushiro Kojinkai Memorial Hospital, 101-212 Aikokku, Kushiro, Hokkaido 085-0062, Japan.
email: kenji-yagi@mail.goo.ne.jp