




Contents lists available at ScienceDirect

Clinical Parkinsonism & Related Disorders

journal homepage: www.elsevier.com/locate/prdoa

Progressive dystonia as a presenting manifestation of GM1 gangliosidosis



Keywords:

Dystonia
Genetics
GM1 Gangliosidosis
Musculoskeletal

A 16-year-old female started having difficulty in speaking at 7 years of age with strained and effortful speech. 1 year later she began to walk with abnormal posturing of left lower limb with flexion at knee and plantarflexion at ankle joint. Initially, this would occur only while walking and used to disappear on sitting or supine position. 6 years into the illness she started having dystonic posturing of right lower limb with inability to straighten her legs. 4 years prior to the presentation she started having abnormal posturing of both upper limbs whenever she used to button/unbutton or hold a pen while writing. Her disability worsened to the extent that she used to walk by crawling over the ground with both hands placed on the floor. At the time of presentation, she could not straighten her legs even in supine position. She also had intermittent deviation of face to left side while speaking with turning of the neck to left side. Family members also noticed that she has become slow in all her daily activities. Birth and developmental history were normal. General physical examination showed BMI of 18.4 kg/m² with normal neck: length ratio. She had long fingers with hepatomegaly. She also had non correctable thoracic scoliosis with concavity to left side. Central Nervous System Examination revealed generalized dystonia. She exhibited facial grimacing, dystonic speech, cervical dystonia in the form of torticollis, with dystonia affecting hands and feet. Her both lower limbs were flexed at knee and hip joint and she could barely stand on her own (Video 1). She scored 26/30 on MMSE (Mini Mental Status Examination) losing points in calculation and attention (100–7). Fundus revealed mild temporal pallor. On motor system examination, there was rigidity in all four limbs with normal power. Deep tendon reflexes were 2+.

Wilson's work up was negative. MRI brain revealed hyperintensities in posterior part of putamen bilaterally (Fig. 1A and B). MRI of the spine showed anomalous shape and morphology of vertebral bodies in the form of decreased height in the posterior aspect of the vertebra and T2 hypo intensity of the intervertebral discs and femoral heads with secondary osteoarthritic changes. Nerve conduction studies were normal. CSF analysis, Serum lactate and serum ammonia were within normal limits. Liquid chromatography and Mass spectrometry for disorders of amino acid, organic acid and fatty acid oxidation was also normal.

Her younger brother was also affected with a similar illness with onset at 5 years of age (video 2). However, in addition he had spastic quadriplegia which on further evaluation revealed presence of craniovertebral junction anomalies in the form of atlantoaxial dislocation,

atlantooccipital assimilation with basilar invagination and abnormal shape of vertebrae. (Fig. 2A, B, C, D).

In view of progressive dystonia, musculoskeletal involvement and autosomal recessive inheritance, a possibility of lysosomal storage disorder was kept.

Clinical exome sequencing revealed a compound heterozygous pathogenic variant in Exon 3 of GLB1 gene {c.276 G > A (p.W92)} clinching the diagnosis of GM1 gangliosidosis. Genetic sequencing in his younger brother also revealed similar heterozygous {c.276 G > A (p.W92)} variant in GLB1 gene. Patient showed marginal improvement with levodopa and trihexiphenidyl.

GM1 gangliosidosis is a rare autosomal recessive lysosomal storage disorder which occurs due to beta-D-galactosidase deficiency [1]. It occurs due to mutations in GLB1 gene present on chromosome 3. Over 150 genetic variants with GLB1 mutations have been identified in GM1 gangliosidosis. The compound heterozygote state is responsible for the same pathogenic variants being present in more than one phenotype [2,3]. Deficiency of lysosomal enzyme results in generalized accumulation of glycoproteins, sphingolipids and keratan sulphate leading to various neurological and skeletal manifestations. Three phenotypes of GM1 gangliosidosis have been described (infantile, juvenile and adult onset) [4]. Type 3 disease (adult onset) usually manifests in the first decade but can occur as late as 4th decade. Majority of these patients survive beyond the second decade. It presents with predominant neurological involvement vis a vis Morquio B disease which has predominant skeletal involvement [4,5]. Most common presentation is with generalized dystonia and severe speech disorder often progressing to anarthria. Dystonia is the most common movement disorder and parkinsonism occurs in around 50% cases [4,5]. These patients have prominent facial dystonia affecting upper and lower face with normal eye movements. Bony abnormalities are mild ranging from flattened vertebral bodies, short stature and scoliosis. However, other skeletal changes described in infantile and juvenile GM1 gangliosidosis include dysostosis multiplex with thickened calvaria, pectus carinatum, J-shaped enlarged sella-turcica, hypoplastic/anteriorly beaked thoracolumbar vertebra and acetabular dysplasia with flat femoral heads [6]. MRI brain shows classical symmetrical hyperintensities in bilateral posterior putamen corresponding to neuronal loss and gliosis in the striatum [7]. Bone Marrow examination can demonstrate foam cells with wrinkled tissue appearance of the cytoplasm [4].

The classical phenotype of the mutation {c.276 G > A (p.W92)} has been described previously in the literature. It usually presents as infantile or juvenile form. Various manifestations include developmental delay, hypotonia, seizures, cherry red spot, hepatosplenomegaly, coarse facial features, vertebral changes and dysostosis. The juvenile form usually presents with dysarthria, ataxia, dystonia and stiffness [8]. Craniovertebral junction anomalies can occur in GLB1 related disorders especially in mucopolysaccharidosis IVB but they are not described in the pathogenic variant {c.276 G > A (p.W92)} to the best of our knowledge [9].

Treatment is largely supportive. Levodopa and trihexiphenidyl have been used with marginal benefit in various case series. Deep

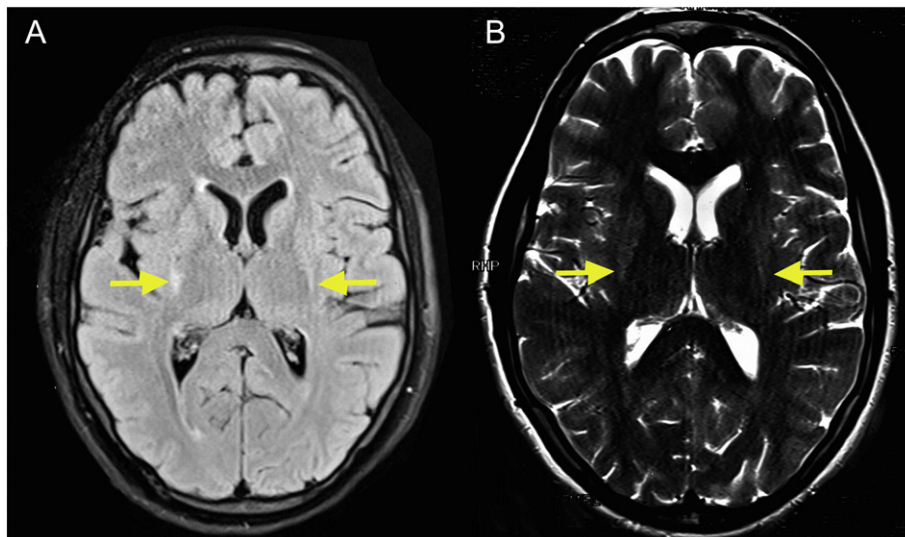


Fig. 1. A and B: MRI brain showing hyperintensities in bilateral posterior putamen on FLAIR and T2W images.

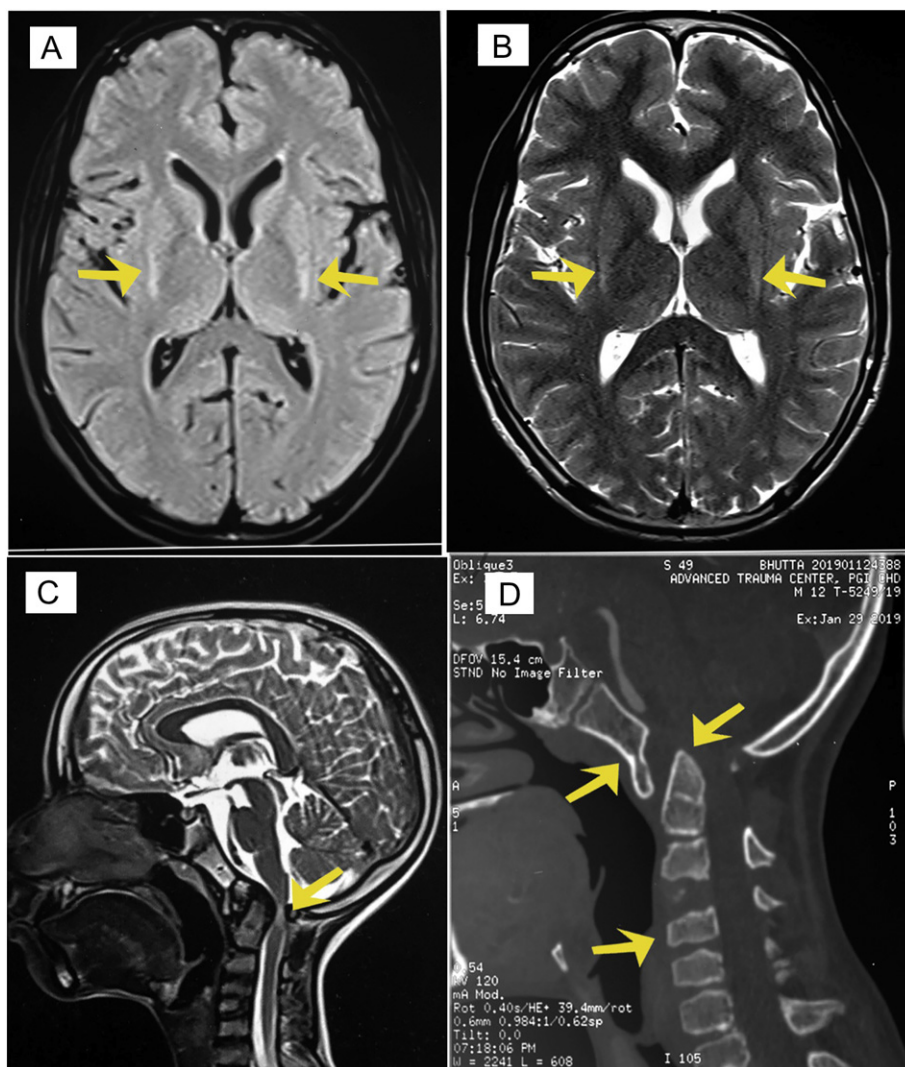


Fig. 2. A and B: MRI brain of the sibling showing hyperintensities in bilateral posterior putamen on FLAIR and T2W images. C: T2W MRI sagittal image demonstrating cervicomedullary compression. D: CT Craniovertebral junction demonstrating atlanto-occipital assimilation, basilar invagination and abnormal shape of vertebrae (arrows).

brain stimulation has also been tried with 20% improvement in functional status [10].

To conclude, GM1 gangliosidosis should be considered in a young patient with symptomatic generalized dystonia and speech disorder. Posterior putaminal hyperintensities on MRI brain may aid in the diagnosis. Our present case highlights the possibility of a severe case of craniovertebral junction anomaly in the presence of the typical features of the disease and adds to the phenotype of c.276G > A (p.W92) mutation.

Supplementary data to this article can be found online at <https://doi.org/10.1016/j.prdoa.2019.09.003>.

Author contribution

Dr. Sahil Mehta: Author Contribution: Drafting the article, analysis, interpretation of the data; manuscript preparation.

Dr. Aastha Takkar Kapila: Author Contribution: Drafting the article and revising its intellectual content.

Dr. Sucharita Ray: Author Contribution: Revision of manuscript.

Dr. Nandita Prabhat: Author Contribution: Manuscript preparation, Preparation of video and images.

Dr. Kamalesh Chakravarty: Author contribution: Manuscript revision and intellectual content.

Dr. Vivek Lal: Author Contribution: Drafting the article and revising its intellectual content.

Financial disclosures

None.

Declaration of competing interest

None.

References

[1] J.E. Goldman, D. Katz, I. Rapin, D.P. Purpura, K. Suzuki, Chronic GM1 gangliosidosis presenting as dystonia: I. clinical and pathological features, *Ann. Neurol.* 9 (1981) 465–475.

- [2] R. Santamaria, M. Blanco, A. Chabas, D. Grinberg, L. Vilageliu, Identification of 14 novel GLB1 mutations, including five deletions, in 19 patients with GM1 gangliosidosis from South America, *Clin. Genet.* 71 (2007) 273–279.
- [3] A. Caciotti, S.C. Garman, Y. Rivera-Colon, E. Procopio, S. Catarzi, L. Ferri, et al., GM1 gangliosidosis and Morquio B disease: an update on genetic alterations and clinical findings, *Biochim. Biophys. Acta* 1812 (2011) 782–790.
- [4] U. Muthane, Y. Chickabasaviah, C. Kaneski, S.K. Shankar, G. Narayanappa, R. Christopher, S.S. Govindappa, Clinical features of adult GM1 gangliosidosis: report of three Indian patients and review of 40 cases, *Mov. Disord.* 19 (2004) 1334–1341.
- [5] E. Roze, E. Paschke, N. Lopez, T. Eck, K. Yoshida, A. Maurel-Ollivier, D. Doummar, C. Caillaud, D. Galanaud, T. Billette de Villemeur, M. Vidailhet, A. Roubergue, Dystonia and parkinsonism in GM1 type 3 gangliosidosis, *Mov. Disord.* 20 (2005) 1366–1369.
- [6] Y. Suzuki, E. Nanba, J. Matsuda, K. Higaki, A. Oshima, β -galactosidase deficiency (β -galactosidosis) and GM1 gangliosidosis and Morquio B disease, in: D. Valle, A.L. Beaudet, B. Vogelstein, K.W. Kinzler, S.E. Antonarakis, A. Ballabio, K. Gibson, G. Mitchell (Eds.), *The Online Metabolic and Molecular Bases of Inherited Disease (OMMBID)*, McGraw-Hill, New York, NY, 2014.
- [7] J. Campdelacreu, E. Munoz, B. Gomez, T. Pujol, A. Chabas, E. Tolosa, Generalized dystonia with an abnormal magnetic resonance imaging signal in the basal ganglia: a case of adult-onset GM1 gangliosidosis, *Mov. Disord.* 17 (2002) 1095–1097.
- [8] A.M. Bidchol, A. Dalal, R. Trivedi, A. Shukla, S. Nampoothiri, V.H. Sankar, et al., Recurrent and novel GLB1 mutations in India, *Gene*. 567 (2015) 173–181.
- [9] D.I. Zafeiriou, S.P. Batziou, Brain and spinal MR imaging findings in mucopolysaccharidoses: a review, *AJNR Am. J. Neuroradiol.* 34 (2013) 5–13.
- [10] E. Roze, S. Navarro, P. Cornu, M.L. Welter, M. Vidailhet, Deep brain stimulation of the globus pallidus for generalized dystonia in GM1 type 3 gangliosidosis: technical case report, *Neurosurgery*. 59 (2006), E1340.

Sahil Mehta*

Aastha Takkar Kapila

Sucharita Ray

Nandita Prabhat

Kamalesh Chakravarty

Vivek Lal

Department of Neurology, Post Graduate Institute of Medical Education and Research (PGIMER), Chandigarh, India

*Corresponding author.

E-mail address: mehtasahilpgi@gmail.com. (S. Mehta)